RABBI ZIDNI ILMA

RABBI INNI LIMA ANZALTA ILAYYA MIN KHAYRIN FAQEER

OSPE AND SS

Muscles:foot

- Plantarflexion:
  - Gastrocnemius
  - Soleus
  - Plantaris (minor – proprioception)
  - Flexor dig, halluc long, halluc brev
- Dorsiflexion:
  - Tibialis Anterior
  - Extensor Hallucis Longus
  - Extensor Digitorum Longus

- Psoas minor – 40-70% of people don't have this muscle
- Bicep: strong supinator
- Brachialis :strong flexor
- Pronator quadratus:strong pronation

- PTH is produced by the parathyroid glands in response to low serum calcium, and it increases bone resorption to release calcium into the bloodstream
- Calcitonin is produced by the thyroid gland in response to high serum calcium, so it opposes the action of PTH, promoting bone formation and decreasing bone resorption
- Vit D promotes calcium absorption in the gut, so it increases serum calcium, promoting bone formation and decreasing bone resorption

- 1) Osteogenesis Imperfecta: collagen 1 (dec FORMATION)
- 2) Osteopetrosis/Marble: carbonic anhydrase 2 OR chloride channel 7 (dec RESORPTION)
- 3) Osteomalacia/Rickets: vit D (dec MINERALIZATION)
- 4) Osteoporosis: osteoblasts lose function with age OR low estrogen (inc RESORPTION)
- 5) Paget: osteoclasts work without signals (inc REMODELING both RESORPTION & FORMATION)

- Scurvy: vit C
- Osteogenesis Imperfecta: COL1A1,COL1A2 Collagen 1
- Ehler Danlos: lysyl oxidase
- Menkes: Cu
- Marfan: fibrillin 1

- Scurvy: bleeding gums
- Osteogenesis Imperfecta: bone, teeth, blue sclera
- Ehler Danlos: hypermobile skin and joints
- Menkes: orange hair, epilepsy
- Marfan: heart, tall, long fingers

- Atp hydrolysis: cocked
- Myosin binds to actin (high energy config.) adp and pi still attached
- Adp and pi released: powerstroke
- Atp binds: myosin detaches (low energy config.)

- Origin: lateral border of rib 1

- continues from **subclavian artery**

- End: lower border of teres major muscle

- continues to form **brachial artery**

- Detach: ATP bind
- Cocked/Move Back: ATP hydrolysed
- Reattach: ADP & Pi obtained
- Powerstroke: release ADP & Pi
- Detach: ATP bind

- The apex of the axilla/axillary inlet is formed by **the coracoid process & superior border of scapula, clavicle & first rib**
- The lateral wall of the axilla is formed by **the intertubercular groove of humerus**
- The medial wall of the axilla is formed by **ribs, intercostal muscles & serratus anterior**
- The anterior wall of the axilla is formed by **pectoralis major, pectoralis minor & subclavius muscles**
- The posterior wall of the axilla is formed by **scapula, subscapularis, teres major & latissimus dorsi**
- Biceps reflex ic c6
- Upper limb bud: 26/27 day

- Lower limb bud: 28 day
- Fifth week: hand and foot plates
- Sixth week: digital rays
- Eighth week: fingers and toes form

- Medial cutaneous nerve of arm is the most medial branch of brachial plexus and shortest

- Radial nerve is the largest branch of brachial plexus

- calbindin in intestine
- calmodulin in smooth muscle
- calsequestrin in skeletal muscle

- Increase in Width- appositional growth
- Increase in height/length- Interstitial growth

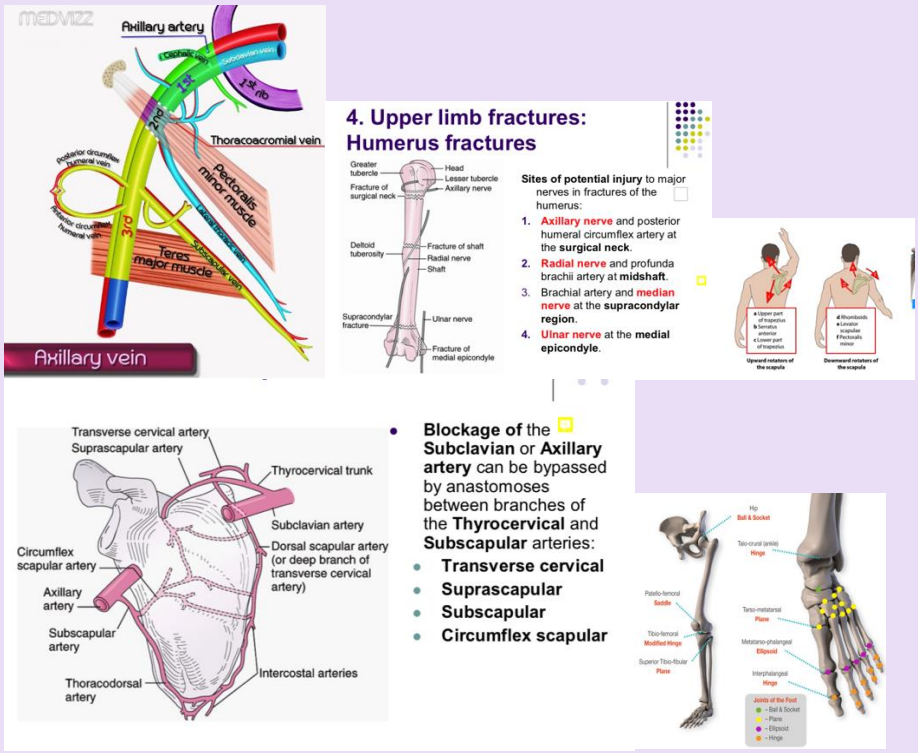

.

Neurotoxin — cobra, krait
Hemotoxin — viperidae
Myotoxin — sea snake

Krait and russell's viper is much more toxic than that of cobra

SIX OF THE PRINCIPLES OF MEIDCAL ETHICS

1-Beneficence	Act In The Best Interest Of Humanity.
2-Non-maleficence	Do No Harm
3-Autonomy	Patient's Right To Refuse Or Choose [Consent]
4-Justice	Treatment On The Merit Of Illness
5-Dignity	Patient And Doctor Both To Be Respected
6-Confidentiality	The ' Trust' / Not be Shared against the will

ADVANTAGES OF CT

COMPARED WITH X-rays, U/S & MRI

- Better Soft Tissue Contrast Resolution than X rays & usually Ultrasound.
- CT is best for Intestinal Tract Evaluation (though not so "dynamic" as fluoroscopy.)
- Easier & Quicker than MRI but not always better tissue contrast resolution
- Best for detection & characterization of CALCIFICATION.

DISADVANTAGES OF CT

- Ionizing Radiation
- Relatively high cost.
- Relatively poor tissue contrast when compared with MRI despite the use of oral and IV contrast

- Shenton line: is an imaginary curved line along the inferior border of the superior pubic ramus (superior border of the obturator foramen) and along the inferomedial border of the neck of femur. This line should be continuous and smooth.

Interruption of the Shenton line can indicate:
1. Developmental dysplasia of the hip (DDH)
2. Fractured neck of femur

MRI

ADVANTAGES

magnet, radio waves, computer

- Non-Ionizing
- Non-Invasive
- Painless
- Excellent soft tissue imaging with high contrast sensitivity.
- Axial, sagittal, coronal and oblique images obtained without repositioning of the patient.
- No bony artifacts.

DISADVANTAGES

- Expensive
- Available in large set ups only
- Needs trained staff
- Claustrophobia
- Long scanning time
- Movements artifacts
- Absolutely contraindicated in patients with cardiac pacemaker and cerebral aneurysm clips.

MRI Sequences

- T_1 Weighted Images (T_1WI) depict Normal Anatomy at its best.
- T_2 Weighted Images (T_2WI) picks up Pathology better than T_1.
- Proton Density images (PDI) evaluates Meniscal tear & articular cartilage
- Short-tau inversion recovery (STIR) images evaluates Bone Marrow Edema by suppressing the marrow fat.
- Post contrast T_1 Weighted images (Post-Gd T_1WI) detects lesions (tumor/metastasis, abscess)

CONTRAINDICATIONS FOR DIAGNOSTIC MAMMOGRAPHY

low dose xrays

- Women under 35 years of age, due to the density of the breast and radiation sensitivity of the breast tissue.
- Pregnancy, due to exposure to radiation.
- Breastfeeding due to density and exposure to radiation. Lactating breasts are more sensitive to radiation.

FLUOROSCOPY

- Fluoroscopy is a type of medical imaging.
- When the X-ray beam is used with a video , the technique is called fluoroscopy. So it shows a continuous X-ray image on a monitor, much like an X-ray movie.
- This allows physicians to visualize the movement of a body part or contrast agent through the body in real time. So it is a dynamic study.

used in barium studies & angioplasty - swallow Ba to see GIT

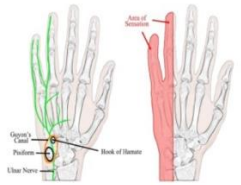

1. CONVENTIONAL ANGIOGRAPHY / DIGITAL SUBTRACTION ANGIOGRAPHY (DSA)

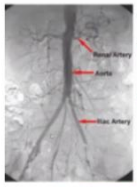

- It is done under the flouroscopy.
- DSA is now regarded as the "conventional" way of getting imaging of the arteries.
- The site to be investigated is numbed with a local anaesthetic. And the artery to be investigated is then injected with contrast, which then outlines the arteries beyond.

2. COMPUTED TOMOGRAPHY ANGIOGRAPHY (CTA)

- CT can now be used to generate an angiogram. This can be displayed as a 3-dimensional image.
- Like a DSA, contrast is injected, but instead of injecting into the artery, the injection is made into a vein in the arm. The arteries anywhere in the body can then be outlined.

3. MAGNETIC RESONANCE ANGIOGRAPHY (MRA)

- An MR scan uses a magnetic field to generate images.
- Contrast (gadolinium) is injected into a vein of the arm. Any arteries in the body can then be viewed as a 2 or 3-dimensional image. The image on a computer can be rotated and viewed from any angle.

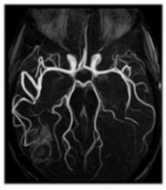

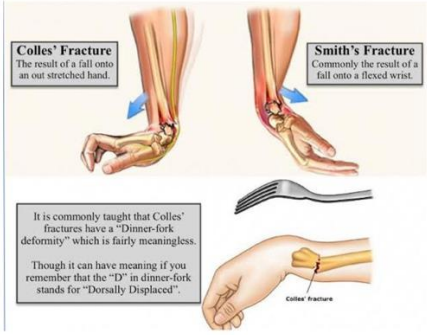

ULTRASOUND

- It is also called sonography, uses sound waves to develop ultrasound images of the inside of body. An instrument called a transducer emits high-frequency sound, inaudible to human ears, and then records the echoes as the sound waves bounce back to determine the size, shape, and consistency of soft tissues and organs.This information is relayed in real time to produce images on a computer screen.

ADVANTAGES OF ULTRASOUND

- Non-Ionizing imaging modality.
- Widely accessible
- Relatively inexpensive
- Portable
- Painless and do not require needles or cuts.
- Ultrasound captures images of soft tissues that don't show up well on X-rays.
- Real time assessment
- Guide procedures (injections, aspiration, biopsies)

DISADVANTAGES

- Operator dependent
- Poor images in obesity
- Bowel gases.
- Calcification/bone

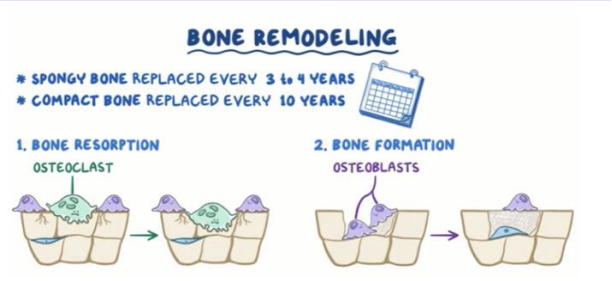

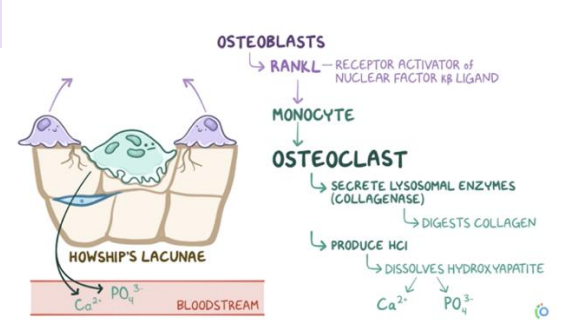

THINGS THAT AFFECT REMODELING:

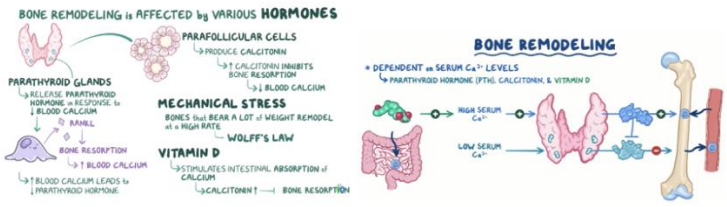

- **PTH** is produced by the *parathyroid glands* in response to low serum calcium, and it increases bone resorption to release calcium into the bloodstream
- **Calcitonin** is produced by the *thyroid gland* in response to high serum calcium, so it opposes the action of PTH, promoting bone formation and decreasing bone resorption
- **Vit D** promotes calcium absorption in the *gut*, so it increases serum calcium, promoting bone formation and decreasing bone resorption.

.Na channels blocked by tetrodotoxin
.Potassium channels blocked by tetraethylammonium
.Mylinated fiber velocity 100m/s
.Unmyelinated fiber velocity 0.25m/s
.Procaine, tetracaine are used in anesthetics, they block activation gate of sodium
.Veratrine and low Ca both increase Na permeability 7:32 pm

Blossom

Blossom
.Na channels blocked by tetrodotoxin
.Potassium channels blocked by tetraethylammonium
.Mylinated fiber velocity 100m/s...

Important points @unaiza @Buttercup @Bliss @Bubbles 7:32 pm

Curare drug competitively inhibits acetylcholine receptors 7:34 pm

Botulinum toxin decreases the quantity of acetylcholine release by nerve terminals 7:44 pm

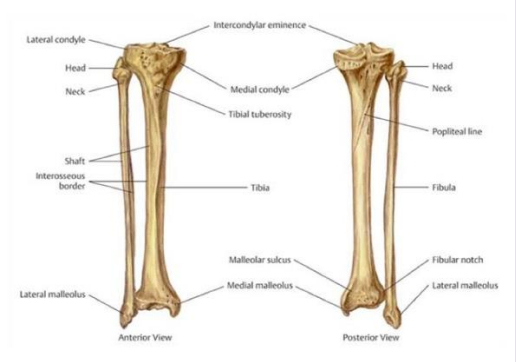

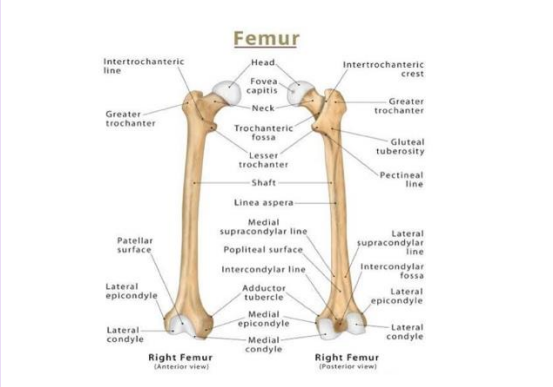

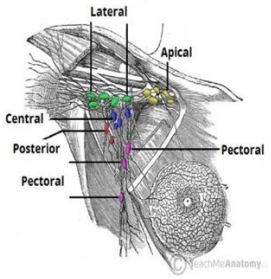
Lateral
Apical
Central
Posterior
Pectoral
Pectoral

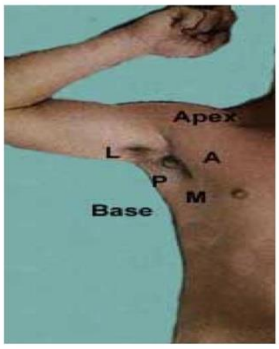
Apex
L
A
P
M
Base

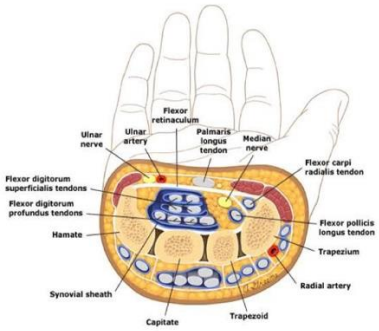
Flexor retinaculum
Ulnar nerve
Ulnar artery
Palmaris longus tendon
Median nerve
Flexor carpi radialis tendon
Flexor digitorum superficialis tendons
Flexor digitorum profundus tendons
Flexor pollicis longus tendon
Hamate
Trapezium
Radial artery
Synovial sheath
Capitate
Trapezoid

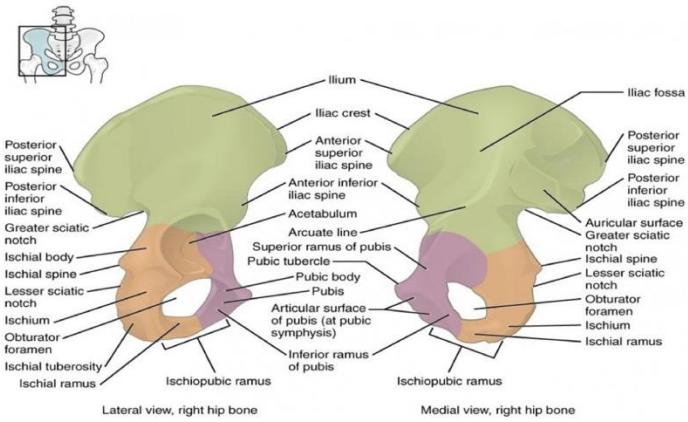
Ilium
Iliac crest
Anterior superior iliac spine
Anterior inferior iliac spine
Acetabulum
Arcuate line
Superior ramus of pubis
Pubic tubercle
Pubic body
Pubis
Articular surface of pubis (at pubic symphysis)
Inferior ramus of pubis
Posterior superior iliac spine
Posterior inferior iliac spine
Greater sciatic notch
Ischial body
Ischial spine
Lesser sciatic notch
Ischium
Obturator foramen
Ischial tuberosity
Ischial ramus
Ischiopubic ramus
Lateral view, right hip bone
Iliac fossa
Posterior superior iliac spine
Posterior inferior iliac spine
Auricular surface
Greater sciatic notch
Ischial spine
Lesser sciatic notch
Obturator foramen
Ischium
Ischial ramus
Ischiopubic ramus
Medial view, right hip bone

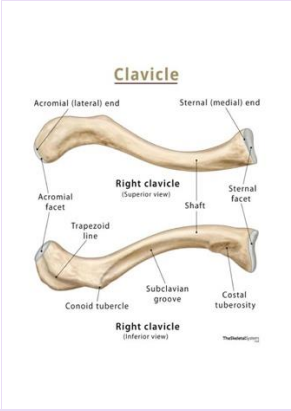
Clavicle
Acromial (lateral) end
Sternal (medial) end
Right clavicle
(Superior view)
Acromial facet
Sternal facet
Shaft
Trapezoid line
Conoid tubercle
Subclavian groove
Costal tuberosity
Right clavicle
(Inferior view)

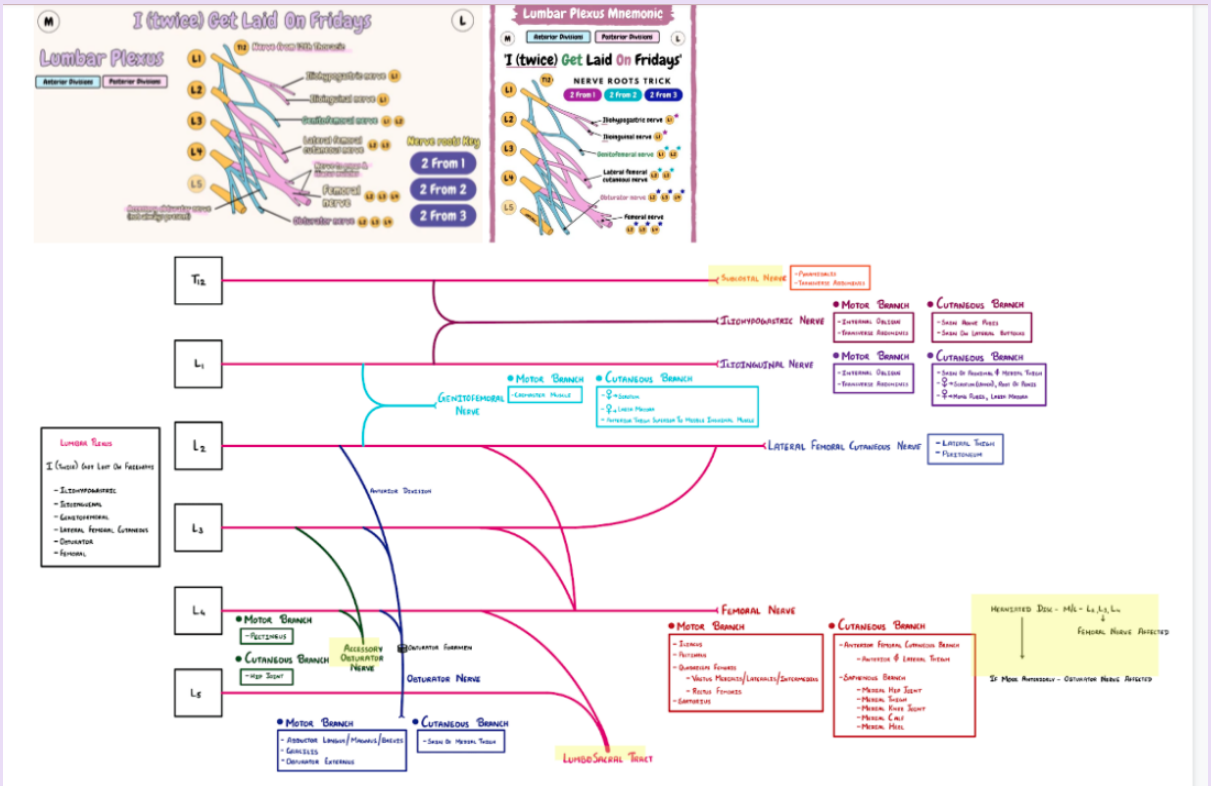
I (twice) Get Laid On Fridays
Lumbar Plexus
Anterior Division
Posterior Division
Nerve roots trick
2 from 1
2 from 2
2 from 3
Lumbar Plexus Mnemonic
NERVE ROOTS TRICK
Iliohypogastric nerve
Ilioinguinal nerve
Genitofemoral nerve
Lateral femoral cutaneous nerve
Obturator nerve
Femoral nerve
Motor Branch
Cutaneous Branch
Genitofemoral Nerve
Lateral Femoral Cutaneous Nerve
Femoral Nerve
Accessory Obturator Nerve
Obturator Nerve
Lumbosacral Trunk

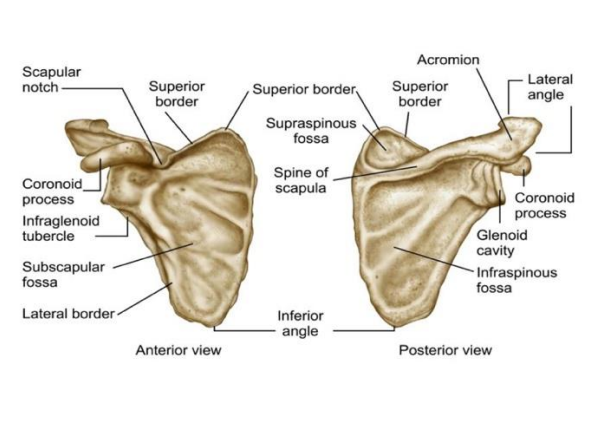

- The **patellar reflex** is tested by tapping the patellar ligament with a reflex hammer to elicit extension at the knee joint. Both afferent and efferent limbs of the reflex arch **are** in the **femoral nerve (L2-L4).**
- **Knee jerk reflex:** tests spinal nerves **L2-L4.**

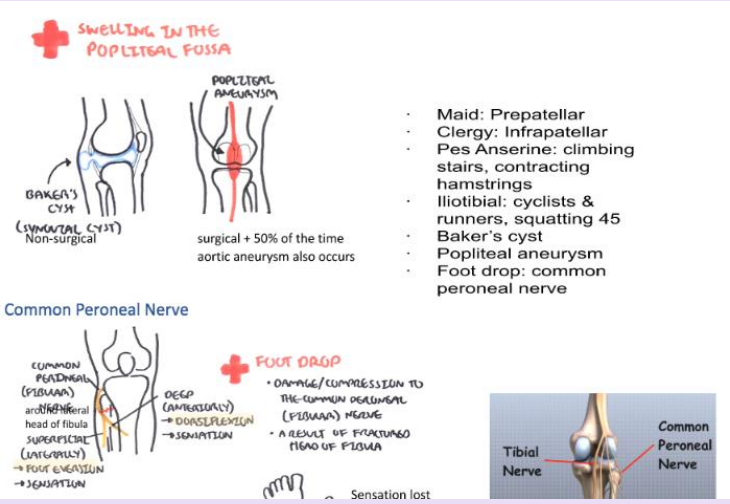

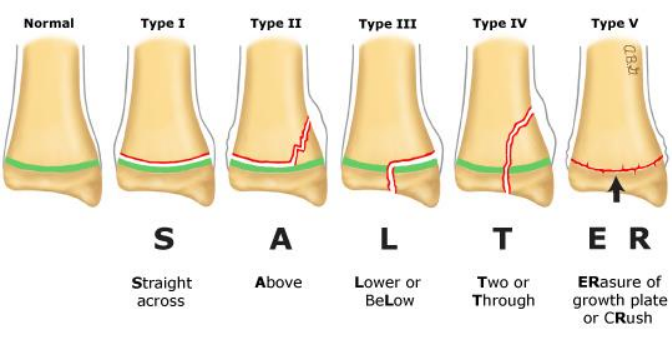

Angle of inclination/Neck-shaft angle: 120-135°

- Coxa valga: >135
- Coxa vara: <120

Torsion angle/femoral neck anteversion/angle of declination: 10-15°

- Femoral anteversion: >15 (intoeing gait)
- Femoral retroversion: <10

Upper Border: concave & horizontal
Lower Border: straight & oblique

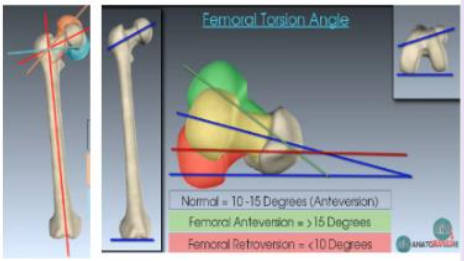

Bone-specific alkaline phosphatase (ALP)

- One of the isoenzymes (types) of ALP; it is associated with osteoblast cell function, the type of cell involved in bone formation.
- It is thought to have a role in bone mineralization;
- It is recommended that the test be performed at baseline before starting osteoporosis therapy and again 3 to 6 months later; results may be affected by the level of liver ALP.

- P1NP marker for formation
- C telopeptide is marker for resorption

1. Bone malignancy: Serum Ca: ↑ , Serum ALP: ↑↑ , Serum phosphate: ↑
2, Osteoporosis: Serum Ca: N, Serum ALP: N, Serum phosphate: N
3. Paget's disease: Serum Ca: N, Serum ALP: ↑↑, Serum phosphate: N
4. Vitamin D deficient osteomalacia: Serum Ca: N or ↓, Serum ALP: ↑↑, Serum phosphate: N or ↓

Intracapsular Ligaments (visible during flexion & posterior view)

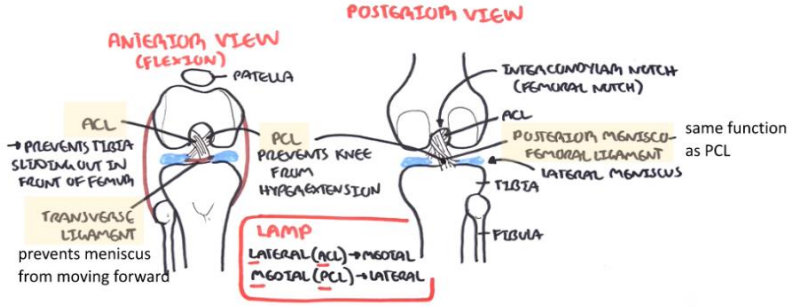

- TL: medial to lateral meniscus
- ACL: lateral femur to anteromedial tibia [Anterior Drawer Test]
- PCL: medial femur to posterolateral tibia [Posterior Drawer Test]
- PMFL: medial femur to posterior lateral meniscus

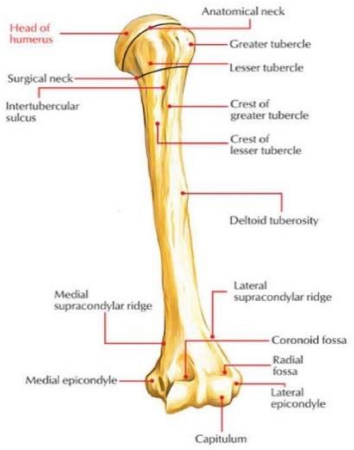

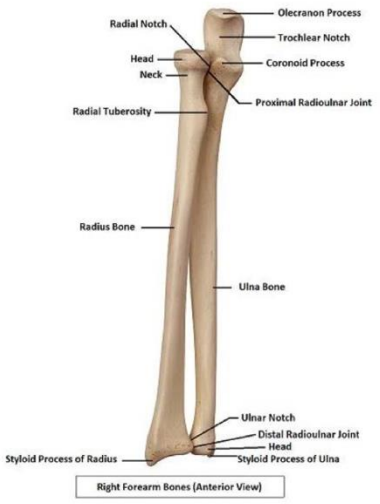

Nerve Injuries
APE HAND
WRIST DROP
CLAW HAND
Median Nerve Injury
Radial Nerve Injury
Ulnar Nerve Injury

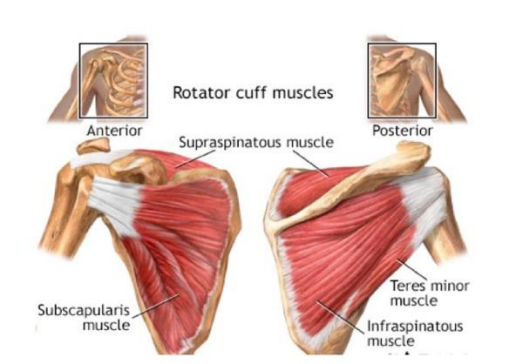
Rotator cuff muscles
Anterior
Posterior
Supraspinatous muscle
Subscapularis muscle
Teres minor muscle
Infraspinatous muscle

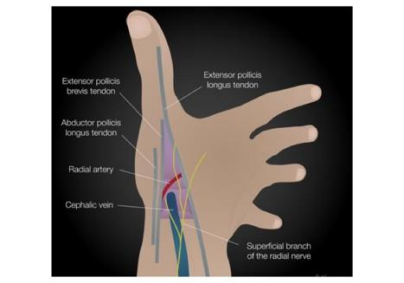
Extensor pollicis brevis tendon
Extensor pollicis longus tendon
Abductor pollicis longus tendon
Radial artery
Cephalic vein
Superficial branch of the radial nerve

Bennett's Fracture

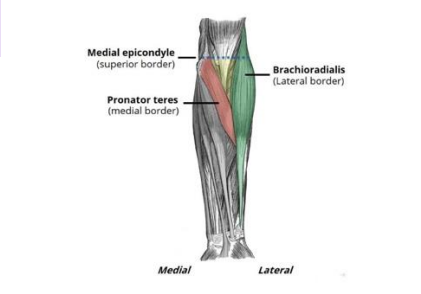
Medial epicondyle (superior border)
Pronator teres (medial border)
Brachioradialis (Lateral border)
Medial
Lateral

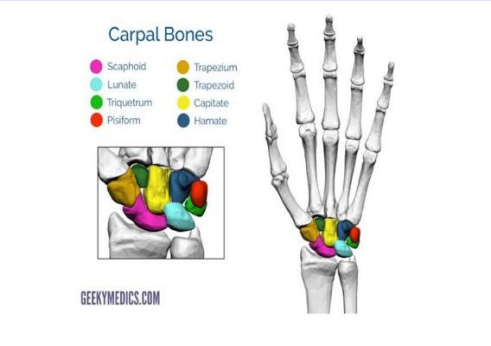
Carpal Bones
Scaphoid
Lunate
Triquetrum
Pisiform
Trapezium
Trapezoid
Capitate
Hamate
GEEKYMEDICS.COM

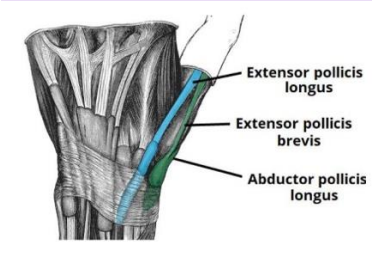
Extensor pollicis longus
Extensor pollicis brevis
Abductor pollicis longus

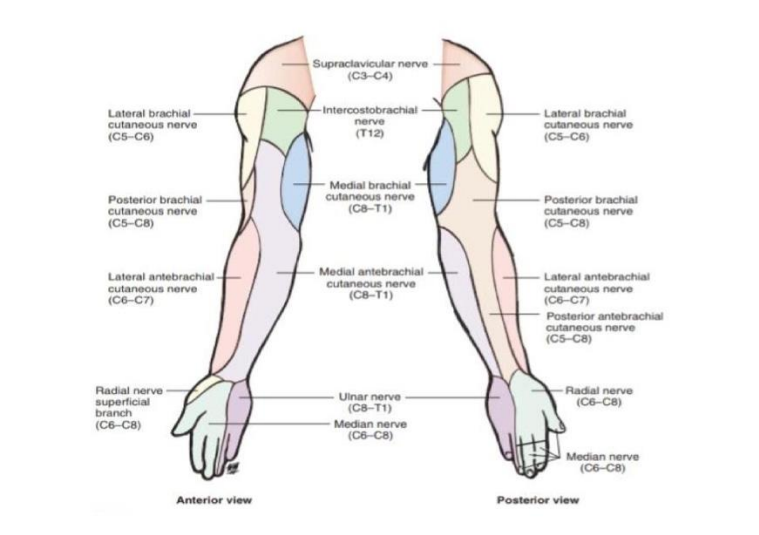
Supraclavicular nerve (C3–C4)
Lateral brachial cutaneous nerve (C5–C6)
Intercostobrachial nerve (T12)
Lateral brachial cutaneous nerve (C5–C6)
Medial brachial cutaneous nerve (C8–T1)
Posterior brachial cutaneous nerve (C5–C8)
Posterior brachial cutaneous nerve (C5–C8)
Lateral antebrachial cutaneous nerve (C6–C7)
Medial antebrachial cutaneous nerve (C8–T1)
Lateral antebrachial cutaneous nerve (C6–C7)
Posterior antebrachial cutaneous nerve (C5–C8)
Radial nerve superficial branch (C6–C8)
Ulnar nerve (C8–T1)
Median nerve (C6–C8)
Radial nerve (C6–C8)
Median nerve (C6–C8)
Anterior view
Posterior view

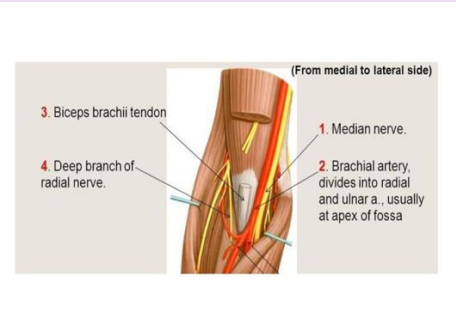
(From medial to lateral side)
3. Biceps brachii tendon
4. Deep branch of radial nerve.
1. Median nerve.
2. Brachial artery, divides into radial and ulnar a., usually at apex of fossa

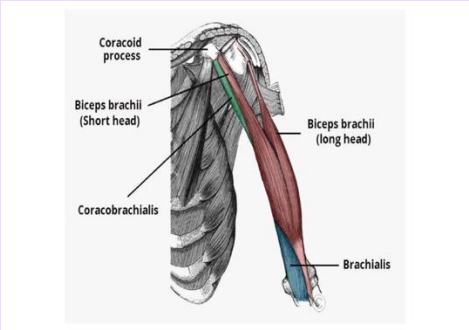
Coracoid process
Biceps brachii (Short head)
Biceps brachii (long head)
Coracobrachialis
Brachialis

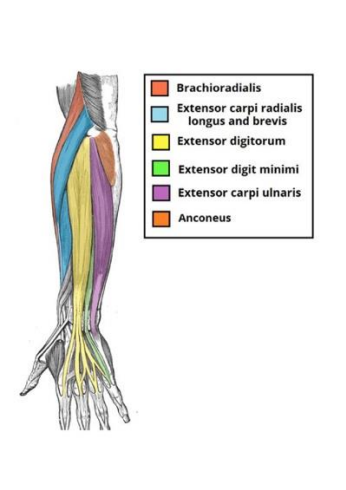

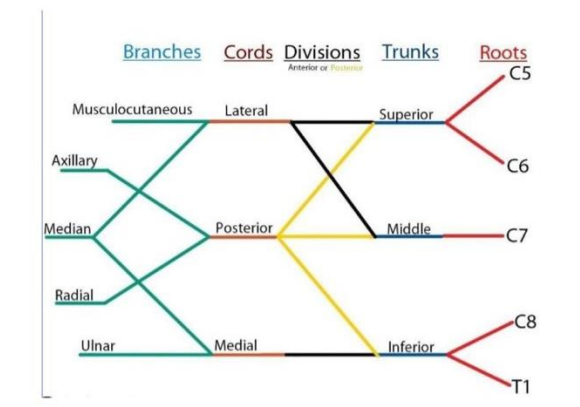

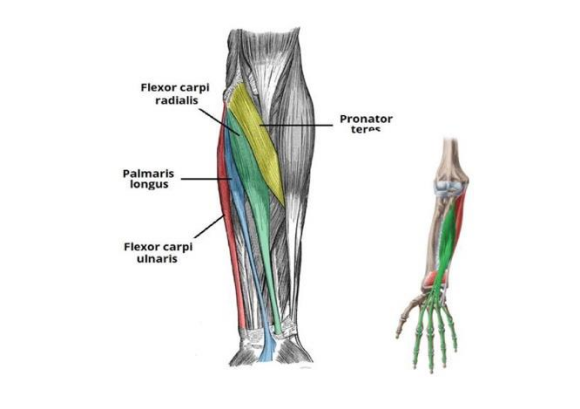

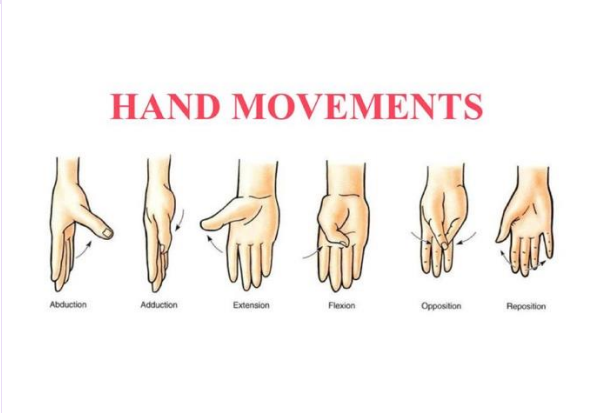

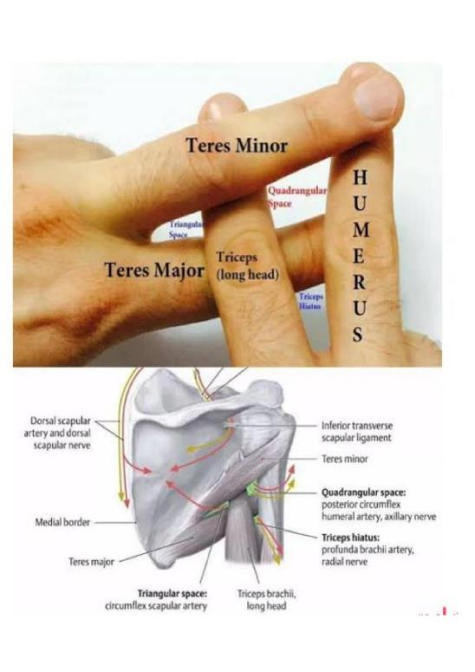

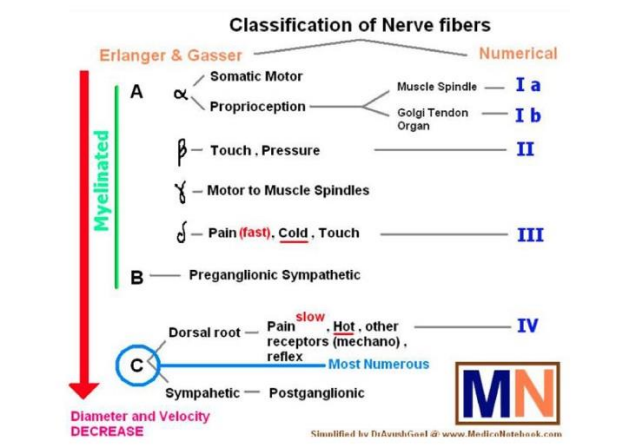

- If the ulnar artery arises high from the brachial artery and runs invariably superfi cial to the fl exor muscles, then when injecting, the artery may be mistaken for a vein for certain drugs, resulting in disastrous gangrene with subsequent partial or total loss of the hand. The ulnar artery may be compressed or felt for the pulse on the anterior aspect of the fl exor retinaculum on the lateral side of the pisiform bone.
- Median nerve controls coarse movement of hand i.e, supplies most of long muscles of forearm.It is called labourer's nerve or eye of hand as it is sensory to most of the hand.It is injured

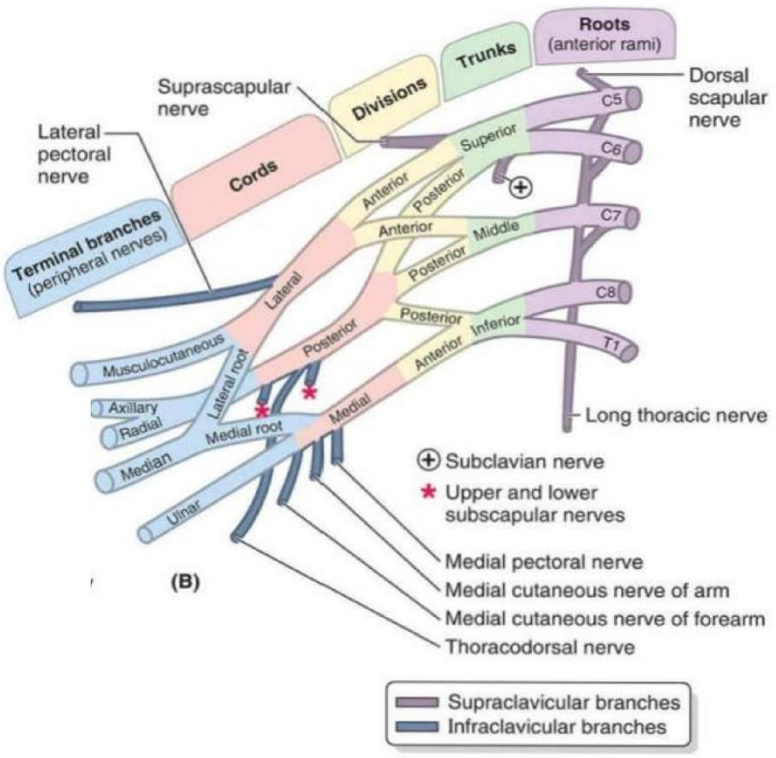

Oxygen dissociation curve

Shifted to right	Shifted to left
○ Decreased oxygen affinity to hemoglobin	○ Increased oxygen affinity to hemoglobin (AI 03)
○ Increased P50	○ Decreased P50
○ Increased oxygen delivery (PGI 08, TN 99) to tissues	○ Decrease oxygen delivery (PGI 03) to tissues
○ Causes :	○ Causes :
▫ Decreased pH (Acidosis) (AIIMS 99, 98, AI 00, PGI 98, SGPGI 05, UPSC 08)	▫ Increased pH (alkalosis) (PGI 07, 03, AIIMS 95, AP 08, UP 08, AI 94)
▫ Increased temperature (AIIMS 06, 99, 98, AI 03, 95, SGPGI 05, UP 08)	▫ Decreased temperature (PGI 08, AIIMS 99, AI 99, 95)
▫ Increased PCO_2 (PGI 08, 01, 98, AIIMS 06, 99, AI 03, SGPGI 05)	▫ Decreased PCO_2 (PGI 03)
▫ Increased 2,3 DPG (BPG) (AIIMS 06, 98, AI 03, 97, 94, UP 08, PGI 98)	▫ Decreased 2,3 DPG (BPG) :- Stored blood (AI 00, Jipmer 95) — acidosis
i) Growth hormone, Androgen, thyroid hormone	▫ Fetal hemoglobin (HbF) (PGI 08, AIIMS 99, SGPGI 05, AI 99, 95)
ii) Exercise (AI 00)	
iii) Tissue hypoxia (PGI 98, UP 08, AI 95)	
iv) High altitude (AI 00)	
v) Anemia (AI 09, 00, DNB 09, UP 08)	
vi) Alkalosis	
vii) Cyanotic CHD	
viii) Pregnancy	
ix) Chemicals : Inosine (AI 09), Pyruvate, PEP, phosphate	
▫ Sickle hemoglobin (HbS) (PGI 01).	

Classification of Mammalian Nerve fibres

Group: Erlanger and Gasser	Group: Lloyd & Hunt*	Myelination	Diameter (microns)	Conduction velocity (m/s)	Function	Agent to which conduction is most susceptible
A alpha	I	Heavily myelinated	13-20	70-120 **Maximum** (DPG 03, Bihar 01, UP 99)	**Proprioception** (AI 13, PGI 04) Motor supply to Skeletal muscle (extrafusal to muscle spindle)	**Pressure** (AIIMS 05)
A beta	II	Myelinated	4-13 (NEET)	25-70	Touch, kinesthetic sense, pressure	Pressure
A gamma	-	Slightly myelinated	3-6	15-30	Motor supply to intrafusal muscle fibres (muscle spindle)	Pressure
A delta	III	Some myelination	1-5 (NEET)	5-30	**Pain** (Comed 08, 07) temperature, pressure, touch	Pressure
B	-	Some myelination	1-3	3-14	**Preganglionic autonomic fibres** (AIIMS 97)	Hypoxia
C	IV	**Unmyelinated** (BHU 03, UP 02, AP 01, TN 98)	0·2-1·0	0·2-2 **Minimum** (NEET)	**Pain, temperature** (BHU 03, UP 02, AP 01, TN 98), *pressure, post-ganglionic autonomic fibres* (NEET, BHU 03, UP 02, AP 01, TN 98)	**Local anaesthetics** (AIIMS 06, AI 93)

Susceptibility of nerve fibers

Pressure :- A (NEET, AIIMS 05) > B > C

Hypoxia :- B > A > C

Local anesthesia :- C (AI 13, 95, AIIMS 04) > B > A (AIIMS 08)

Woven vs. Lamellar Bone

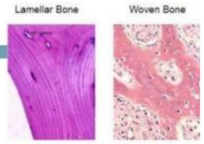

- **Woven bone – weak**
  - Haphazard organization of fibers
  - Osteoblasts produce osteoid rapidly
  - In all fetal bones – replaced later by lamellar bone
  - Also present after fractures – initially woven bone as healing occurs.
- **Lamellar bone - strong**
  - Secondary bone created by remodeling of woven bone.
  - Highly organized alignment of collagen in sheets
  - Fibers run in opposite directions in cross-section
    - tensile strength
  - Less osteocytes

Anastomosis Around Scapula Body :-

Subclavian Artery → 1st Part → Thyrocervical Trunk → Suprascapular / Deep Branch of Trans Cervical

Axillary Artery → 3rd Part → Subscapular → Circumflex Scapular

Anastomose

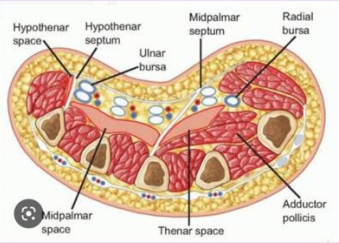

Curvatures of the spine are established during the vertebrae formation. The thoracic and sacral curvatures are called primary curves of the spine, while the **cervical and lumbar curvatures** are called **secondary** curves of the spine.

The cervical curvature is established when a child is learning to hold up his/her head and the lumbar curvature is established when a child learns to walk.

This specialization of undifferentiated cells proceeds in this **order**: stylopod (humerus and femur) → zeugopod (radius/ulna + tibia/fibula) → autopod (carpals, metacarpals, digits, tarsals, metatarsals).

Hence, an absence of the **scaphoid** bone (a carpal bone) indicates a defect in the development of **autopod**.

The epimeres or epaxial muscles (muscles of the back) are innervated by dorsal primary rami.
The hypomeres or hypaxial muscles (muscles of the limbs and body wall) are innervated by ventral primary rami.

Myofilaments are the filaments of myofibrils, constructed from proteins, principally myosin or actin.
A myofibril (muscle fibril) is a basic rod-like unit of a muscle cell, it is composed of actin, myosin, and titin.
The myocardium is another name for the cardiac muscle or the heart muscle.
Actin and myosin are two different proteins that form myofilaments. Actin forms thin filaments while myosin forms thick filaments.

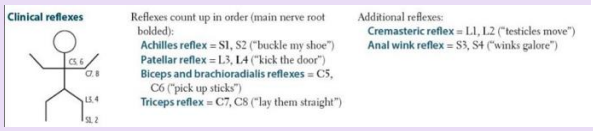

Waiter's tip position is a presenting sign of Erb's palsy. This occurs as a result of injury or lesions of the upper brachial plexus involving C5-C6 roots.

Wrist drop occurs due to radial nerve injury. This condition is known as Saturday night palsy.

Hand of benediction is an indicator of medial nerve injury.

Shoulder drop occurs when the clavicle gets fractured and the trapezius is unable to keep the lateral fragment up, making the shoulder droop down.

Excitatory	Inhibitory	Both
Glutamate	Glycine	ACh
Aspartate	GABA	Norepinephrine
Nitric Oxide	Serotonin	Dopamine

The growth plate (also known as epiphyseal plate or epiphyseal cartilage) has a very specific morphology in having a zonal arrangement as follows:
Zone of reserve - quiescent/dormant chondrocytes are found in the hyaline cartilage at the epiphyseal end.
Zone of proliferation - chondrocytes divide rapidly via mitosis.
Zone of maturation and hypertrophy - chondrocytes begin to hypertrophy by accumulating glycogen, lipids, and alkaline phosphatase.
Zone of calcification - chondrocytes undergo apoptosis and the cartilaginous matrix begins to calcify by the formation of hydroxyapatite crystals.
Zone of ossification - Osteoclasts and osteoblasts replace the cartilage with mineralized bone tissue.

Klumpke palsy is a lower **C8-T1** brachial plexus lesion that usually occurs when the upper limb is forcefully abducted above the head (such as while grabbing an object to break fall or upward stretch of the arm during delivery). It primarily affects the ulnar nerve and the intrinsic muscles of the hand with a loss of sensation on the medial forearm and digits. The presenting sign is a combination of **claw hand** (ulnar nerve) and **ape hand** (median nerve), also known as **total claw hand**. Another possible cause of this hand presentation is thoracic outlet syndrome.

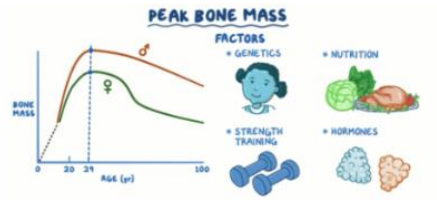

- Africans have higher PBM
- Higher Vit D intake
- More strength training
- Estrogen & androgens inhibit resorption

Osteoporosis vs Osteomalacia:

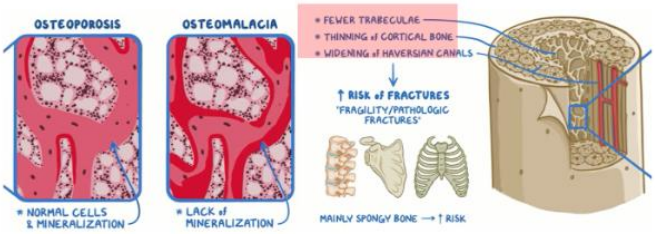

Osteoporosis: high breakdown + brittle but normal composition
Osteomalacia: improper mineralization + abnormal composition so soft

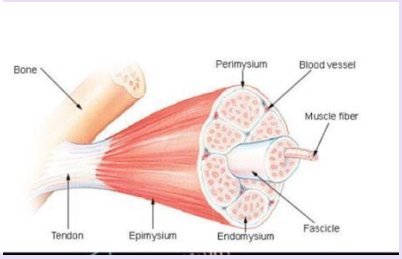

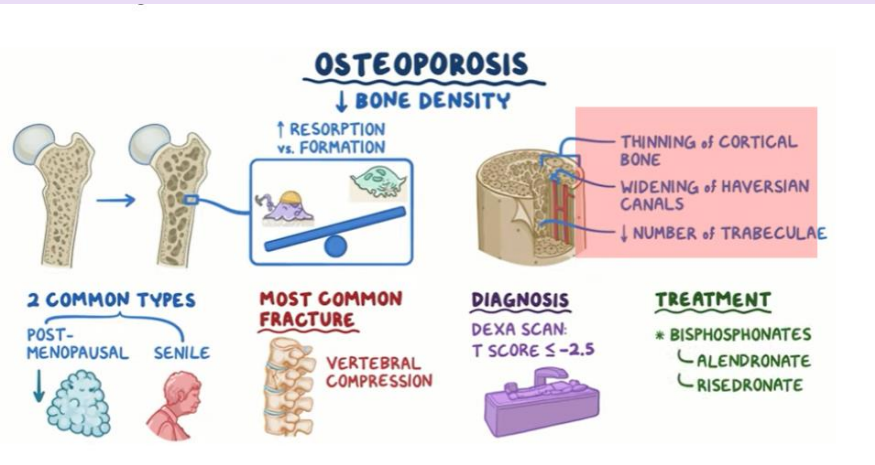

Paget's Disease of Bone: Diagnosis & Treatment

Diagnosis:

- *Increased alkaline phosphatase*
- ***Radiographic imaging (X-Ray)*** demonstrating characteristic findings
  - Deformity, thickened cortex, tunneling
  - Enlarged and dense bones

Treatment:

- Treat symptoms
  - Pain control
- Exercising (not too much physical activity)
  - Weight-bearing
- Calcium and vitamin D supplementation
  - Prevents secondary hyperparathyroidism
- Bisphosphonates
  - Ex. Alendronate
- Calcitonin

Bisphosphonates (-dronates) first line of treatment

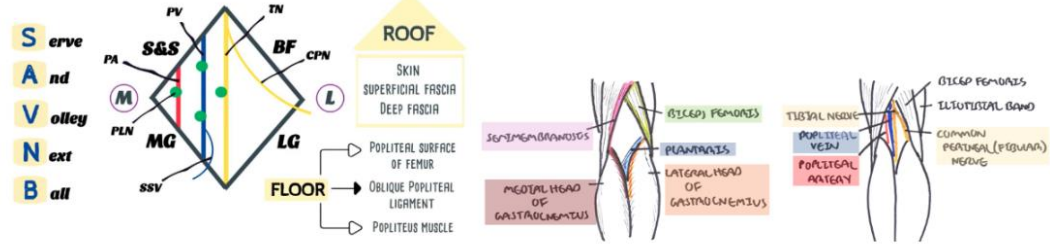

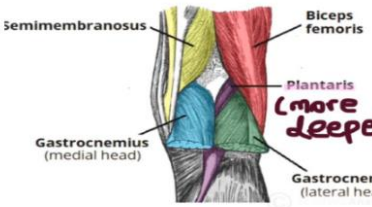

- **Boundaries**
  - [1] **Superior/lateral**: biceps femoris
  - [2] **Superior/medial**: semitendinosus and semimembranosus
  - [3] **Inferior/lateral**: lateral head of the gastrocnemius and plantaris muscle
  - [4] **Inferior/medial**: medial head of the gastrocnemius
  - [5] **Roof**: Fascia lata
    - Branches of the posterior femoral cutaneous nerve
    - Branches of the lesser saphenous vein
  - [6] **Floor**: Popliteal surface of the femur
    - Capsule of the knee joint
    - Oblique popliteal ligament

Etiology and classification

- Osteopetrosis is characterized by dysfunctional osteoclasts. That is, there is some sort of issue that prevents them from properly breaking down bone. This is usually due to a mutation in a gene that encodes for a protein involved in bone resorption.

ⓐ Autosomal recessive (AR)

- There are two forms AR osteopetrosis, the malignant and the intermediate forms. The former is so called because of its severity and it usually causes death early on. The latter form usually presents in the first decade of life and is due to a mutation in the gene that codes for carbonic anhydrase II (CAII). Without this enzyme, osteoclasts cannot generate protons (H^+), which diminishes the ability to resorb bone.

ⓑ Autosomal dominant (AD)

- There are two forms of AD osteopetrosis - type I and type II. They are more common, less severe and generally don't present until adulthood. This is usually due to a mutation in the gene that encodes for chloride channel 7. This channel exchanges two Cl^- ions for one H^+, which helps maintain the acidity required to resorb bone.

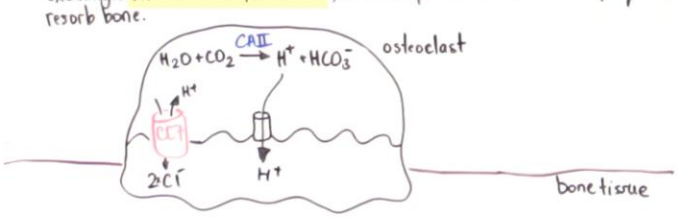

Paget's Disease of Bone (PDB):

- Also known as ***osteitis deformans***
- *Metabolic* disease of increased bone destruction and remodeling
  - Can cause a variety of *skeletal deformities*
- Onset in *older* adults
- **Common** condition
  - 2-9% of older patients
  - Prevalence increases with increasing age
  - Increased prevalence in people of *European descent*

Etiology

- Etiology is not entirely clear
- *Genetic predisposition*
  - Mutations in *SQSTM1*
  - >20 mutations in SQSTM1 identified
  - *Familial PDB (autosomal dominant)*
- ?Due to an indolent viral infection of osteoclasts
  - Paramyxoviruses (ex. Measles virus)

Increased Formation of Osteoclasts

This theory is also supported by some evidence that measles vaccinations have led to a decrease in prevalence of PDB

- **Sporadic**: caused by **random mutation** – not genetics

Pathophysiology

Occurs in the skeleton of elderly

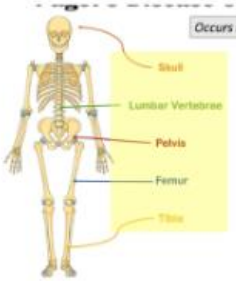

- Increased osteoclastic activity
- Accelerated rate of bone remodeling
- Osteoblast activity increases to compensate

4 Phases of PDB

Phase 1:
Primarily Osteoclastic Activity (Osteolytic)
Phase 2:
Both Osteoclastic & Osteoblastic Activity (Mixed)
Phase 3:
Primarily Osteoblastic Activity (Osteosclerotic)
Phase 4:
Malignant Degeneration

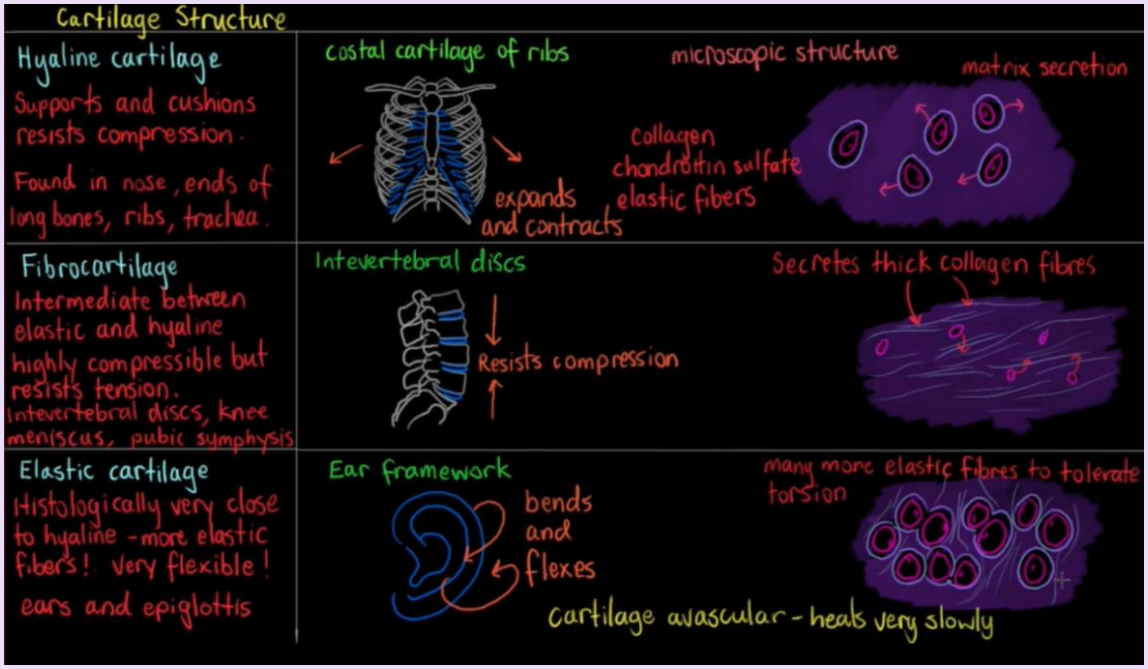

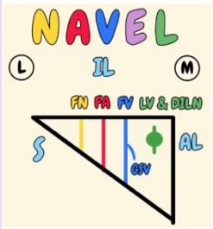

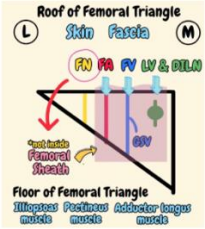

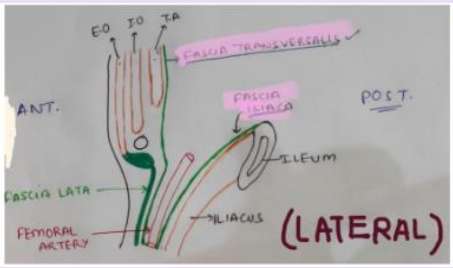

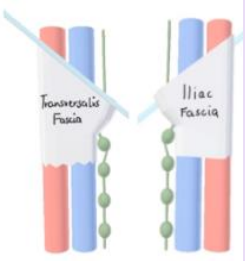

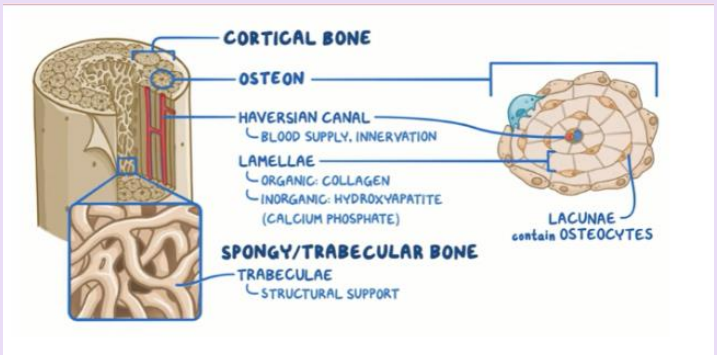

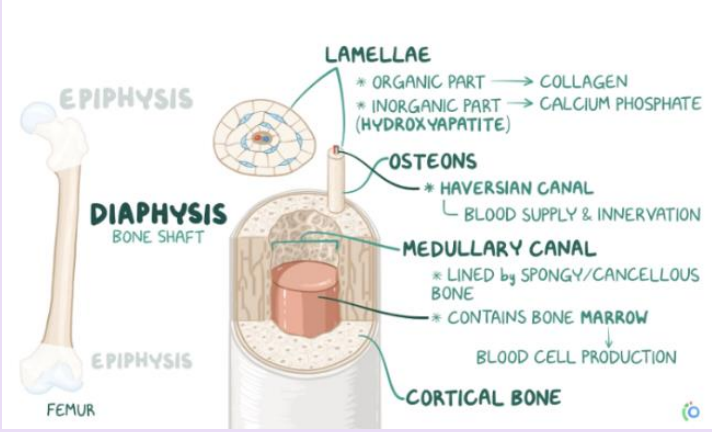

- **Achilles tendon reflex** is tested by **tapping** the **calcaneal tendon** to elicit plantar flexion at the ankle joint.
- Both afferent and efferent limbs of the reflex arc are carried in the **tibial nerve** (S1, S2).
- **Ankle jerk reflex**: tests spinal nerves **S1-S2**.

Skin: 7-dehydrocholesterol
Vit D3: cholecalciferol (animals)
Liver: calcidiol/25-hydroxycholecalciferol
Active: calcitriol/1,25-dihydroxycholecalciferol
Vit D2: ergocalciferol (plants)

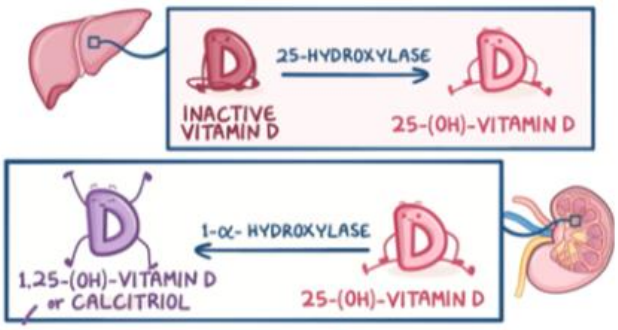

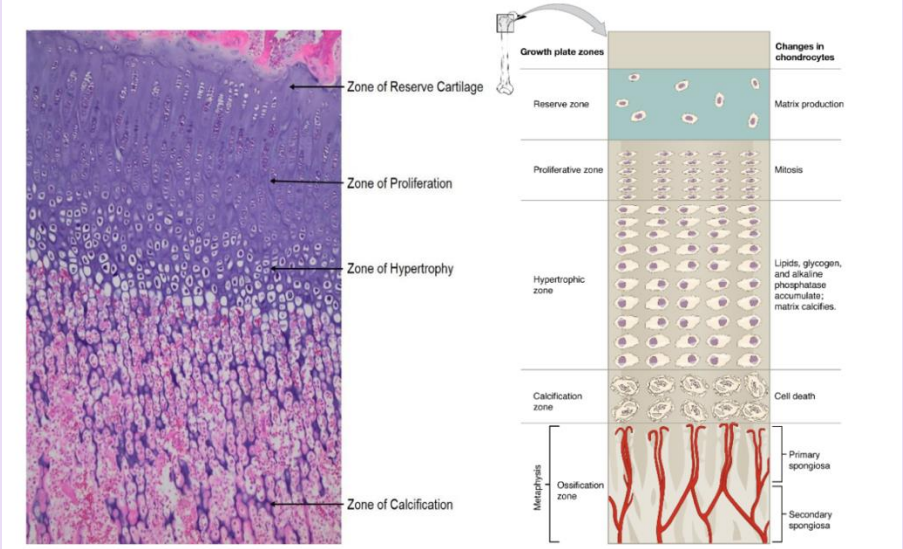

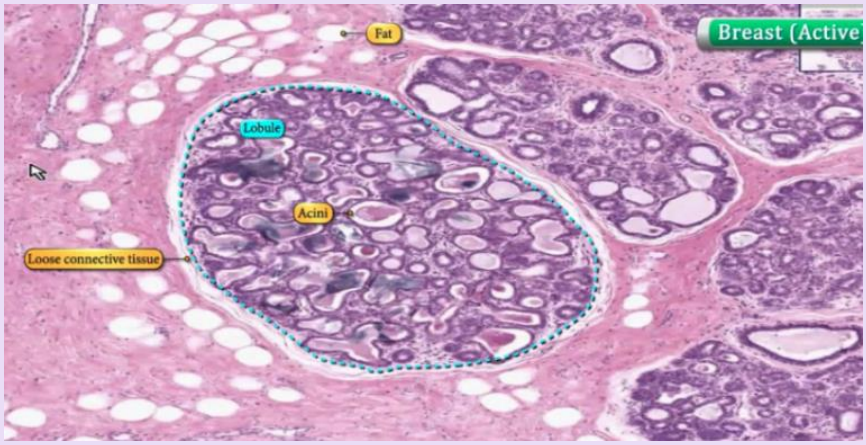

Knee jerk reflex

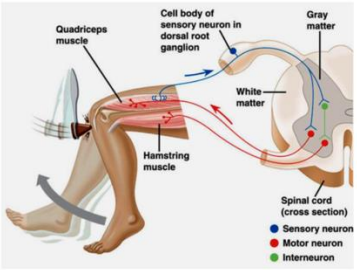

- The **patellar reflex** is tested by tapping the patellar ligament with a reflex hammer to elicit extension at the knee joint. Both afferent and efferent limbs of the reflex arch **are** in the **femoral nerve (L2-L4).**
- **Knee jerk reflex:** tests spinal nerves **L2-L4.**

Dr. Mavrych, MD, PhD, DSc prof.mavrych@gmail.com

Rotator Cuff

Supraspinatus	Infraspinatus	Teres Minor	Subscapularis
Supraspinous Fossa of Scapula	Infraspinous Fossa of Scapula	Lateral Border of Scapula	Subscapular Fossa
Greater Tubercle Of Humerus	Greater Tubercle Of Humerus	Greater Tubercle Of Humerus	Lesser Tubercle Of Humerus
Abduction	Lateral Rotation	Lateral Rotation	Medial Rotation
Suprascapular Nerve	Suprascapular Nerve	Axillary Nerve	Subscapular Nerve

Rotator Cuff muscles and their actions - Mnemonic

MNEMONIC- *Rotator cuff muscles* - **SITS**, *Action* - **AEEI**

Muscles	Action
Supraspinatus	**a**Bduction
Infraspinatus	**E**xternal Rotation
Teres Minor	**E**xternal Rotation and aDduction
Subscapularis	**I**nternal Rotation and aDduction

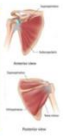

	Water soluble vitamins	Fat soluble Vitamins
Excretion in urine	Excess is Excreted in urine.	Not excreted in urine.
Storage	Not stored, except: • Vitamin B9 (folate): 3-4 months. • Vitamin B12 (cobalamin): 3-4 years	Stored in fat & liver
Deficiency	More likely	Less likely
Toxicity (hypervitaminosis)	Less likely	More likely (especially Vit. A, and D)
Absorption	Easy, Does NOT depend on GIT or pancreas	Depend on GIT and pancreas
Malabsorption syndrome	No effect	Decrease absorption --> deficiency
Examples	Vitamin: • B • C	Vitamin: • K • E • D • A

- **PTH** is produced by the *parathyroid glands* in response to low serum calcium, and it increases bone resorption to release calcium into the bloodstream
- **Calcitonin** is produced by the *thyroid gland* in response to high serum calcium, so it opposes the action of PTH, promoting bone formation and decreasing bone resorption
- **Vit D** promotes calcium absorption in the *gut*, so it increases serum calcium, promoting bone formation and decreasing bone resorption.

Greater sciatic foramen is formed by:

- Sacrotuberous and sacroiliac ligament
- Iliofemoral and ischiofemoral ligament
- Sacrotuberous and ischiotuberous ligament
- Iliofemoral and pubofemoral ligament
- Sacrotuberous and sacrospinous ligament

Scurvy affects the structure of collagen. However, it is due to a **deficiency of ascorbic acid** (Chapter 44), and is not a genetic disease. Its major signs are bleeding gums, subcutaneous hemorrhages, and poor wound healing. These signs reflect impaired synthesis of collagen due to **deficiencies of prolyl and lysyl hydroxylases**, both of which require ascorbic acid as a cofactor.

In **Menkes disease** deficiency of copper results in defective cross-linking of collagen and elastin by the copper-dependent enzyme lysyl oxidase. (Menkes disease is discussed in Chapter 50.)

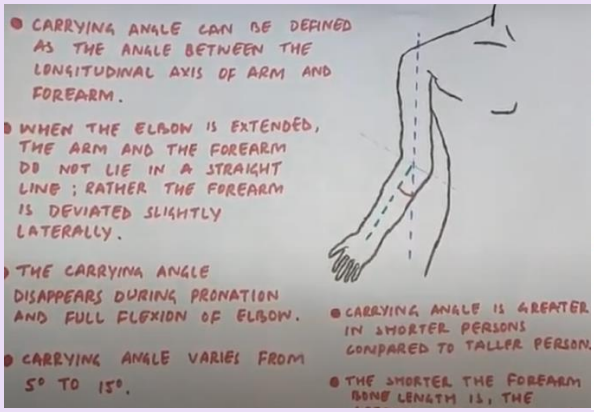

Movements

As a **ball and socket** synovial joint, there is a wide range of movement permitted:

- **Extension (upper limb backwards in sagittal plane)** – posterior deltoid, latissimus dorsi and teres major.
- **Flexion (upper limb forwards in sagittal plane)** – pectoralis major, anterior deltoid and coracobrachialis. Biceps brachii weakly assists in forward flexion.
- **Abduction (upper limb away from midline in coronal plane):**
  - The first 0-15 degrees of abduction is produced by the supraspinatus.
  - The middle fibres of the deltoid are responsible for the next 15-90 degrees.
  - Past 90 degrees, the scapula needs to be rotated to achieve abduction – that is carried out by the trapezius and serratus anterior.
- **Adduction (upper limb towards midline in coronal plane)** – pectoralis major, latissimus dorsi and teres major.
- **Internal rotation (rotation towards the midline, so that the thumb is pointing medially)** – subscapularis, pectoralis major, latissimus dorsi, teres major and anterior deltoid.
- **External rotation (rotation away from the midline, so that the thumb is pointing laterally)** – infraspinatus and teres minor.
- **Circumduction (moving the upper limb in a circle)** – produced by a combination of the movements described above.

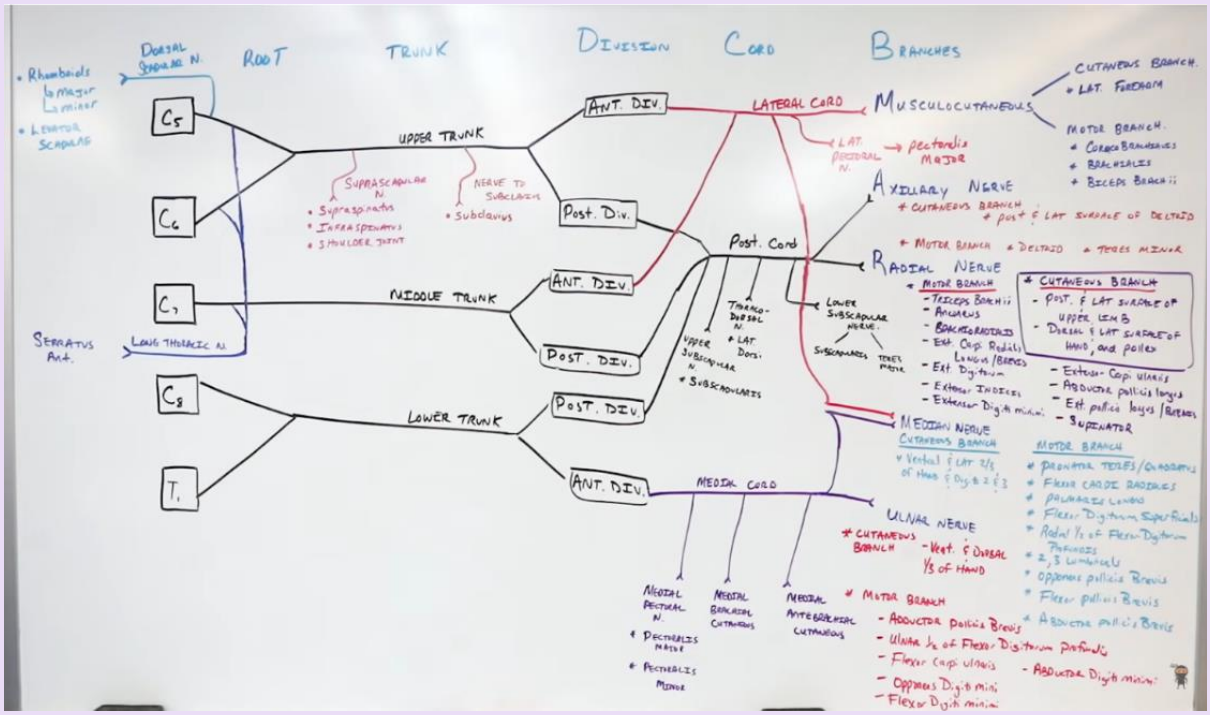

- Characteristic lamellae of bone matrix
- Haversian and Volkmann's canals are present
- Osteocytes in lacunae
- Haversian system present

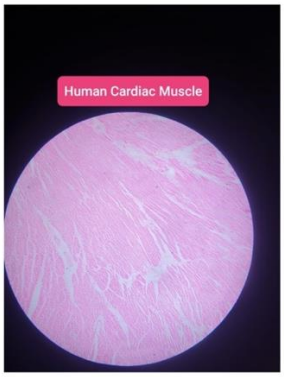

- Cross striations present
- Branching fibres
- Intercalated disc present
- 1-2 oval central nuclei

Pott's fracture/potts syndrome/Dupuytren fracture: refers to an injury in which the medial malleolus is often torn off, the fibula is broken and the medial/deltoid ligament is strained and broken. It occurs while playing volleyball, jumping or rolling of the ankle.

Collagen

- Collagen is the most abundant protein in the body. Depending on the type and organization of collagen, it can take on a variety of functions. In some tissues it may act to provide support while in others it may act to give tensile and even shear strength.

Structure

- A single collagen monomer consists of three polypeptide α-chains that intertwine to give rise to an α-helix. Each α-chain is rich in proline and glycine amino acids; in fact glycine is found in every third position. The proline acts to create "kinks" in the polypeptide chain and helps form the helical structure while the small size of the glycine allows the three α-chains to fit together (gives space) to give rise to the triple stranded helix.

- The triple helix creates a fibrous elongated structure that places many of the amino acid side chains on the surface. This enables adjacent collagen monomers to interact with each other thereby forming longer, stronger fibers.
- In addition, many of the amino acid side chains are modified post-translationally. The hydroxyproline helps stabilize the triple helix by maximizing hydrogen bonding while the hydroxylysine residues may be glycosylated to allow individual collagen monomers to bind to one another via cross-links.

Types

- There are over twenty different types of collagen and each are suited for a specific purpose. Variations in the amino acid sequence confers specific properties onto the α-chains and then the different chains can combine to form the different types of collagen. For example, type I collagen consists of two α_1-chains and one α_2-chain while type II collagen consists of three α_1-chains. There are four major types of collagens:

① Type I (90%): Bone, tendons, skin, cornea
② Type II: Cartilage, intervertebral disk
③ Type III: Blood vessels, granulation tissue

These generally form fibrils that confer tensile or shear strength to the tissue

④ Type IV: Basement membrane, lens

These form sheet-like structures rather than fibrils seen in types I–III and act to provide support

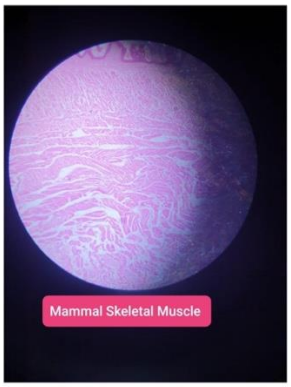

- Well marked/prominent cross striations
- Non branching cylindrical fibres
- Multiple nuclei located peripherally
- Endomysium and perimysium present

- Trabeculae of the bone matrix
- Haemopoietic (bone marrow) tissue
- Few Haversian system

Roots (**Ant Rami**) travel BETWEEN ANT & MIDDLE SCALENE MUSCLES; BEHIND SUBCLAVIAN ARTERY to enter BASE OF NECK
Trunk splits into Divisions in POSTERIOR TRIANGLE OF NECK
Division enter AXILLA and form Cords (named RELATIVE TO AXILLARY ARTERY; Lateral, Post, Medial)

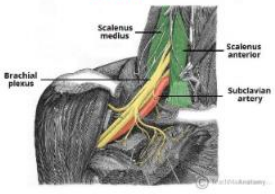

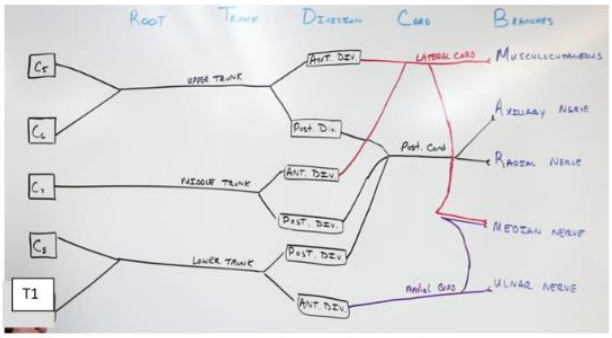

Remember To Drink Cheap Beer

MARMU

- Type 1 = bONE
- Type 2 = carTWOledge
- Type 4 = four = floor = basement

Ehlers-Danlos syndrome comprises a group of inherited disorders whose principal clinical features are hyperextensibility of the skin, abnormal tissue fragility, and increased joint mobility. The clinical picture is

Osteogenesis imperfecta (brittle bones) is characterized by abnormal fragility of bones. The scleras are often abnormally thin and translucent and may appear blue owing to a deficiency of connective tissue. Four types of this condition (mild, extensive, severe, and variable) have been recognized, of which the extensive type occurring in the newborn is the most ominous. Affected infants may be born with multiple fractures and not survive. Over 90% of patients with osteogenesis imperfecta have mutations in the *COL1A1* and *COL1A2* genes, encoding proα1(I) and proα2(I) chains, respectively. Over 100 mutations in these two genes have been documented and include partial gene deletions and duplications. Other mutations affect RNA splicing, and the most frequent type results in the replacement of glycine by another bulkier amino acid, affecting formation of the triple helix. In general, these mutations result in decreased expression of collagen or in structurally abnormal proα chains that assemble into abnormal fibrils, weakening the overall structure of bone. When one abnormal chain is present, it may interact with two normal chains, but folding may be prevented, resulting in enzymatic degradation of all of the chains. This is called "procollagen suicide" and is an example of a dominant negative mutation, a result often seen when a protein consists of multiple different subunits.

- Fusiform/spindle shaped cells
- Single, rod shaped, central nucleus in each cell
- Cross striations absent.

- Perichondrium present
- Branching elastic fibres present.
- Scattered chondrocytes are present singly or as pairs

Locomotor Histology Spotting

Points of Identification

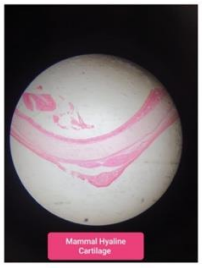

- Perichondrium Present.
- Glassy (homogenous) ground substance.
- Chondrocytes making isogenous groups.
- Territorial matrix
- Interterritorial matrix

\