Annals of Biomedical Engineering, Vol. 49, No. 1, January 2021 *(© 2020)* pp. 502–514
https://doi.org/10.1007/s10439-020-02581-2

Original Article

A Novel High-Density Electromyography Probe for Evaluating Anorectal Neurophysiology: Design, Human Feasibility Study, and Validation with Trans-Sacral Magnetic Stimulation

Niranchan Paskaranandavadivel,[1,2] Chris Varghese,[2] Jaime Lara,[1] Shasti Ramachandran,[1] Leo Cheng,[1,3] Ales Holobar,[4] Armen Gharibans,[2] Ian Bissett,[2,5] Rowan Collinson,[5] Cathy Stinear,[6] and Gregory O'Grady[1,2,5]

[1]Auckland Bioengineering Institute, University of Auckland, Auckland, New Zealand; [2]Department of Surgery, University of Auckland, Auckland, New Zealand; [3]Vanderbilt University, Nashville, TN, USA; [4]Faculty of Electrical Engineering and Computer Science, University of Maribor, Maribor, Slovenia; [5]Auckland City Hospital, Auckland, New Zealand; and [6]Department of Medicine, University of Auckland, Auckland, New Zealand

(Received 9 January 2020; accepted 22 July 2020; published online 31 July 2020)

Associate Editor Nathalie Virag oversaw the review of this article.

Abstract—Fecal incontinence (FI) substantially impairs quality of life and imparts a major socioeconomic burden. Anal sphincter injury and possibly pudendal nerve damage are considered common causes, however, current clinical methods for evaluating their function remain suboptimal. Electromyography (EMG) and pudendal nerve terminal latencies have been applied with some success, but are not considered standard practice due to uncertain accuracy and clinical value. In this study we developed and applied a novel anorectal high-density (HD) EMG probe in humans and pigs to acquire quantitative electrophysiological metrics of the anorectum. In the human trial we assessed somatic pathways and showed that EMG amplitude was greater for tight voluntary squeezes than light voluntary squeezes (0.03 ± 0.02 mV vs. 0.05 ± 0.03 mV). In a porcine model we applied trans-sacral magnetic stimulation to evoke extrinsically activated involuntary pathways and the resulting motor evoked potentials (MEP) were captured using the HD-EMG probe. The mean MEP amplitude at 50% magnetic stimulation intensity output (MSO) was significantly lower that the MEP amplitude at 85, 95 and 100% MSO (1.52 ± 0.50 mV vs. 3.10 ± 0.60 mV). In conclusion, the use of HD-EMG probe in conjunction with trans-sacral magnetic stimulation, for spatiotemporal mapping of anorectal EMG and MEP activity is anticipated to achieve new insights into FI and could offer improved diagnostic and prognostic biomarkers for anorectal dysfunction.

Keywords—Anorectal electrophysiology, High-resolution, Electromyography.

INTRODUCTION

Anorectal dysfunction is a common manifestation in functional disorders. A population-based study based on the Rome IV classification found the prevalence of anorectal dysfunction to be 7.4% in the general population.[2] Fecal incontinence (FI), as defined by at least one episode of liquid or solid leakage per month, has a prevalence of around 12% in the general population and is commonly associated with anorectal sensorimotor dysfunction.[36,43] In women, the most common cause of anorectal dysfunction is obstetric trauma, owing to damage of the pelvic floor muscles, anal sphincter, and/or pudendal nerves; while for men it is most commonly related to iatrogenic injury to sphincters and perianal disease.[5] Accurate evaluation of the muscular and neurophysiological functions of the anorectum in all patients should ideally involve an objective assessment to guide appropriate targeted therapy.

In practice, anorectal neurophysiological evaluation has commonly been performed using a pudendal nerve terminal motor latency (PNTML) test to assess pudendal neuropathy and motor innervation of the external anal sphincter.[3,9] Needle electromyography

Address correspondence to Niranchan Paskaranandavadivel, Auckland Bioengineering Institute, University of Auckland, Auckland, New Zealand. Electronic mail: nira.pask@auckland.ac.nz

0090-6964/21/0100-0502/0 © 2020 Biomedical Engineering Society

(EMG) of the anal sphincter has also been applied in limited research studies and is considered too invasive for routine use. With the PNTML test, an electrical stimulus is delivered to the pudendal nerve *via* the assessor's index finger deeply intubated into the rectum. The resulting compound action potential response from the innervation of the deep nerve bundles to the anal sphincter is recorded around 4 cm proximal to the end of the anal canal.[17,39]

A disposable electrode for this test was developed in the 1980s, termed the St Marks electrode, with proposed clinical utility *via* a prolonged temporal compound action potential response, particularly in FI patients.[18,33] However, uptake of this method has been limited by operator dependency,[44] poor sensitivity and specificity,[34,40] and limited utility for modifying or predicting clinical outcomes after intervention.[19] The assessment is highly dependent on the site of recording and level of nerve damage, with studies showing that normal latencies could be recorded from some damaged nerve fibers due to the presence of residual fast acting fibers, which are the least susceptible to damage.[9,19] Substantial nerve damage is required for the PNTML test to detect a prolonged response. Another crucial limitation of using EMG needle electrode and PNTML has been the sparse recording of the complex anal sphincter structure. Anal sphincter dysfunction and neuropathy may occur heterogeneously, and valuable physiological and diagnostic data could therefore be missed by a single summative measure.

Recently, trans-sacral magnetic stimulation has been proposed as a method of non-invasively and reliably generating motor-evoked potentials (MEPs) of the external anal sphincter. A brief current (~ 100 μs) is passed through a magnetic coil generating a magnetic field of up to 2 T; this induces an orthogonal electric field to stimulate deep neuronal structures.[13] The function of the external anal sphincter can be evaluated by characterizing the MEP onset latency, amplitude and morphology. It has been suggested that magnetically-evoked MEPs of the external anal sphincter are more reproducible, patient tolerable, less operator-dependent and more sensitive for neuropathic FI than MEPs evoked by the PNTML.[30,45] However, recording of magnetically evoked MEPs has been limited to low resolution methods.[30,32,35,41,45]

High-density (HD) EMG electrode arrays have been introduced in limited studies to date to allow comprehensively spatiotemporal evaluations of anorectal function. The first probe introduced by Merletti *et al.*,[22] has undergone several design iterations and been used in multi-center trials to investigate HD-EMG response before and after vaginal delivery.[7] Computational HD-EMG decomposition methods based on Convolution Kernel Compensation (CKC) have been used to identify individual motor unit (MU) action potentials (MUAP) and their locations.[15] These methods have been applied to anorectal recordings and enhanced the understanding of the anatomy and circular geometric arrangement of muscle fibres of the external anal sphincter (EAS) muscles.[6] A recent consensus paper has denoted EMG to have findings of clinical importance for investigating anorectal physiological function, paving a path for HD–EMG systems to be adopted into clinical use.[5]

The aim of this study was to develop HD-EMG techniques and analysis methods to define electrophysiological function of the anorectum. We hypothesized that HD-EMG using flexible printed circuit board electrodes, when performed alone or in combination with magnetic stimulation, could provide detailed quantitative metrics of anorectal function and innervation. To investigate this hypothesis, we developed and applied a novel HD-EMG anorectal probe in human studies to assess somatic or voluntary intrinsic function, and also applied it in a porcine model to assess involuntary function, *via* extrinsic trans-sacral magnetic stimulation.

MATERIAL AND METHODS

Design and Fabrication of Anorectal Probe

Custom anorectal probes with diameter (14 and 16 mm) were constructed from polyetherimide thermoplastic with flexible HD electrode arrays with up to 64 electrodes bonded to it (FlexiMap, Auckland, New Zealand), as shown in Fig. 1. For human trials, the flexible HD electrodes had an inter-electrode distance of 4 mm and covered a depth of 16 mm (arranged in 12 $\times$ 4 configuration for 14 mm diameter probe and 13 $\times$ 4 configuration for the 16 mm diameter probe). For porcine trials, the flexible HD electrodes had an inter-electrode distance of 5.5 mm and covered a depth of 38.5 mm (arranged in a 8 $\times$ 8 configuration for both 14 and 16 mm probes). All electrode tip sizes were 0.5 mm in diameter with gold-plated contacts. The thermoplastic and flexible HD electrode arrays were designed to be sterilizable and reusable, following enzymatic cleaning.

Human Experimental Protocol to Assess Voluntary Function

Ethical approval for the feasibility study was obtained from the New Zealand Health and Disability Ethics Committee and studies were undertaken at the

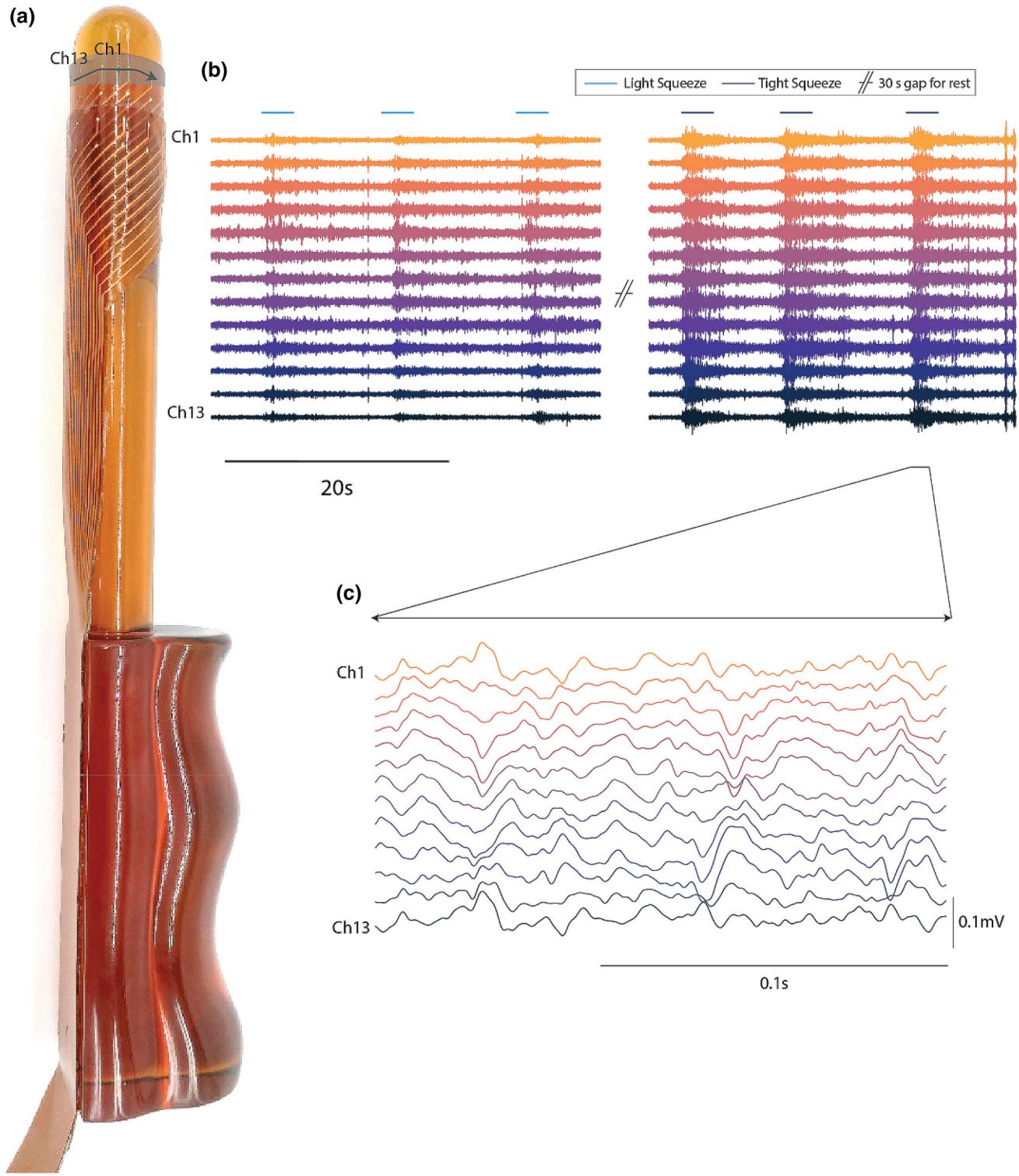

FIGURE 1. High-resolution probe design (a), with thirteen anorectal EMG tracings during light and tight squeeze for a participant (b). The electrode channels displayed are the first row of electrodes on the probe as illustrated in (a). In (c) a close-up view of the EMG signals during a tight squeeze is shown.

Greenlane Clinical Centre, Auckland, New Zealand. All participants provided written informed consent.

The HD-EMG anorectal probe was lubricated using gel (A-Gel, Fresenius Kabi Australia Pty Limited, Australia) and inserted into the anorectal canal whilst the participant was lying in a left lateral position. This device was of comparable size to that of a standard anorectal ultrasound probe. Once the HD-EMG probe was inserted, the participant would rest for 30 s to acquire a baseline recording, before being asked to perform voluntary light anorectal squeezes for 5 s, three times. This was followed by another 30 s rest, before they started on three further voluntary tight anorectal squeezes.

The HD-EMG anorectal probe was connected to an ActiveTwo multi-channel data acquisition system (Biosemi, Amsterdam, The Netherlands) modified for passive use. The HD-EMG recordings were digitized and then sent to the laptop through an optical fiber connection. The reference electrodes were ConMed Cleartrace pre-gelled disposable Ag/AgCl electrodes (Conmed Corp. Utica, NY, USA) and were placed on the right iliac crest. The data were sampled at 4 kHz.

Porcine Experimental Protocol to Assess Involuntary Function

Ethical approval for porcine studies was obtained from the Animal Ethics Committee at the University of Auckland. Induction of anesthesia was achieved *via* Zoletil (Tiletamine HCl 50 mg mL^{-1} and Zolazepam HCl 50 mg mL^{-1}), followed by intubation and maintenance anesthesia with isoflurane (2.5–5%, with oxygen flow of 400 mL within a closed-circuit aesthetic system). Arterial blood pressure, temperature and oxygen saturations were continuously monitored to ensure they were maintained within normal physiological ranges. A porcine model was used in this study to evaluate the efficacy of magnetic stimulation to evoke a MEP. This allowed us to trial different intensity protocols as described below. Pigs were employed as they are a common large-animal model used in technical gastrointestinal electrophysiological studies, due to their sufficiently comparable anatomy to humans.[26]

The anorectal probes were lubricated with gel (Aquasonic 100 Ultrasound Transmission Gel, Parker Laboratories, Orange, NJ) and inserted into the porcine anorectal canal whilst the animal was in a prone position. The S3 nerve root, a contributor to the pudendal nerve, which subsequently provides the somatic innervation of the external anal sphincter, was stimulated as it arises through its sacral foramen. The surface projection of the S3 nerve root was found by palpating approximately 12 cm cephalad of the anal margin and 1 cm lateral to the midline.[23] Trans-sacral magnetic stimulation was delivered to this area *via* the Magstim Rapid2, with a 70 mm figure-of-eight coil (The MagStim Company, Whitland, UK). Stimulations were applied five times to both left and right S3 nerve roots with current travelling in a cephalocaudal direction in the body at stimulation intensities of 50, 65, 85, 95 and 100% maximum stimulator output (MSO) with a pulse duration of 342 μs. Data from the anorectal probes were recorded at 8 kHz. The times at which magnetic stimuli were delivered were recorded using a trigger signal from the MagStim Rapid2 to the multi–channel data acquisition system.

The pigs were reused for other research projects, before euthanasia by bolus intravenous injection of 50 mL magnesium sulphate, whilst under anesthesia.

Data Analysis

The human HD-EMGs from the anorectal probe were bandpass filtered (10–500 Hz) using a 20th order Butterworth filter. The average of all signals was then subtracted from each signal to eliminate common noise across all signals, after which a 50 Hz notch filter was applied to eliminate powerline interference.

To calculate the amplitude of the HD-EMG signals, a moving root mean square envelope of 0.2 s was computed for all filtered signals across time. To compare the EMG of voluntary light squeeze vs. tight squeeze, the maximum amplitude during the squeeze was identified across all signals. Results are reported as mean and standard deviation. A Wilcoxon rank sum was computed to evaluate for statistical significance for HD-EMG amplitude across voluntary light and tight squeeze, within participants and across participants.

To identify somatic MUs, HD-EMG signals were decomposed using the Convolution Kernel Compensation (CKC) algorithm.[15] The estimated MUAP shape, firing spike trains and discharge rate plots were obtained for each MU. The discharge rate plots were derived from the firing spike trains by differentiating temporally and low-pass filtering by zero-lag 5th order Butterworth filter with cut-off frequency of 3 Hz.

The plots of firing spike trains indicate overall temporal activity of each MU by illustrating the moments a MU triggers. The discharge rate plots show the frequency of activation (measured in pulses per second). MUAP shapes are estimated by spike-triggered windowing and averaging of each EMG channel. Afterwards they are spatially arranged into grids that reflect their relative position in the electrode arrays.

For the porcine data, no filtering was performed as it would distort the extrinsically induced MEP *via* magnetic stimulation. MEPs were visualized and quantified in a 15 ms post–stimulus time window for

all channels. The activity recorded in each channel was averaged for the 5 stimuli delivered at each stimulus intensity. The onset latency was defined as the first negative deflection of the MEP.[16] This was defined using the gradient of the signal, where the negative trough relates to the negative deflection and the zero crossings relate the peak and trough of the signal.[29] The MEP amplitude was then computed using the closest peak and trough positions to the onset latency. Mean amplitude and onset latencies were plotted as a spatiotemporal map, and mean values were reported. A non-parametric Kruskal–Wallis test was used to calculate significance of MEP amplitude and latency vs. stimulation intensities between 50 and 100% MSO trials.

RESULTS

Human Studies with the HD-EMG probe to Assess Voluntary Function

Six participants were recruited for the feasibility study (3 males, 3 females; median age: 56, age range 38–68; median weight: 76 kg, range 47–102 kg). All except one participant had some form of lower anorectal dysfunction, including FI ($n = 2$), anal fissures ($n = 2$), previous hysterectomy ($n = 1$) and obstructive defecation with a hypertonic pelvic floor ($n = 1$).

Average EMG amplitude was greater for tight voluntary squeezes than light voluntary squeezes (see Fig. 2, 0.03 ± 0.02 mV vs. 0.05 ± 0.03 mV, $p < 0.05$). However, for two participants there was no statistical difference between light and tight squeeze, which may be pathophysiological (Participant 1 and 3, see Fig. 2 for relevant clinical notes). Figure 3 shows the representative traces from two participants where one produced a higher EMG amplitude with tight squeeze compared to light squeeze, while the other participant produced similar EMG amplitude. On assessment of clinical notes for the participant that illustrated similar EMG amplitude response with light and tight squeeze (Participant 1), it was found they have FI and had a previous anterior sphincter repair surgery, and had reported to have hypotonic pressure response when evaluated using anorectal manometry (resting pressure: 39 mmHg and maximum pressure: 51 mmHg). The insignificant change in maximum pressure correlates with the EMG response with voluntary tight squeeze. The similar EMG amplitude response to light and tight squeeze may be due to pathology in the muscles or the participant was nervous under the experimental setting.

Somatic/Voluntary Intrinsic Motor Unit Decomposition

Figure 4 shows the results of the decomposition of EMG from a participant performing a series of three tight squeezes. In total, 14 individual somatic MU were identified in this example, where the first six MU produced a mean peak amplitude of 0.15 ± 0.05 mV, and the last 8 MU produced a mean peak amplitude of 0.05 ± 0.01 mV. The spatial arrangement of the first four largest MU suggest that circular muscle fibres are the most dominant, as their contributions to EMG show clear propagation patterns. The other MUs (such as MU 5 and 6 in Fig. 4) illustrate non-propagating components contributed by muscle fibres that may be less superficially located.[6,14]

All 14 MUs were recruited quasi-simultaneously and their firing rate increased progressively to 12–25 pulses per second (pps) during the voluntary tight squeeze (for ~ 1 s) and then decreased to around 5 pps to maintain the pressure applied (~ 3 s). The first three MUs were also active during the relaxation phase as shown in Fig. 5, which could reflect the participant's response to the experimental setting or due to an activation dysfunction.

Porcine Studies to Assess Involuntary MEP via Magnetic Stimulation

Recordings were obtained from two pigs (38 ± 0.9 kg) with a mean recording time of 20 s for each stimulation intensity. Figures 6a and 6b shows two stacks of motor evoked potentials, where magnetic stimulation was applied at 50 and 100% intensities. There was a positive correlation between MEP amplitude and stimulation intensity, with significant differences across stimulus intensity ($p < 0.05$, Fig. 7a). In particular, the mean MEP amplitude at 50% MSO was significantly lower than the mean MEP amplitude at 85, 95 and 100% MSO (1.52 ± 0.50 mV vs. 3.10 ± 0.60 mV). However, the spatiotemporal localization of high and low amplitude MEPs was similar when elicited with 50% and 100% MSO stimuli as shown in Figs. 6c and 6d. There were no significant changes in onset latency measurements with increase in stimulation intensity ($p > 0.05$, Fig. 7b). There were heterogenous spatiotemporal latency patterns as shown in Figs. 6e and 6f. Mean onset latency was 4.0 ± 0.3 ms across all stimulus intensities.

DISCUSSION

A novel HD multi-electrode anorectal EMG probe was developed, validated in a clinical feasibility study, then applied in conjunction with trans-sacral magnetic

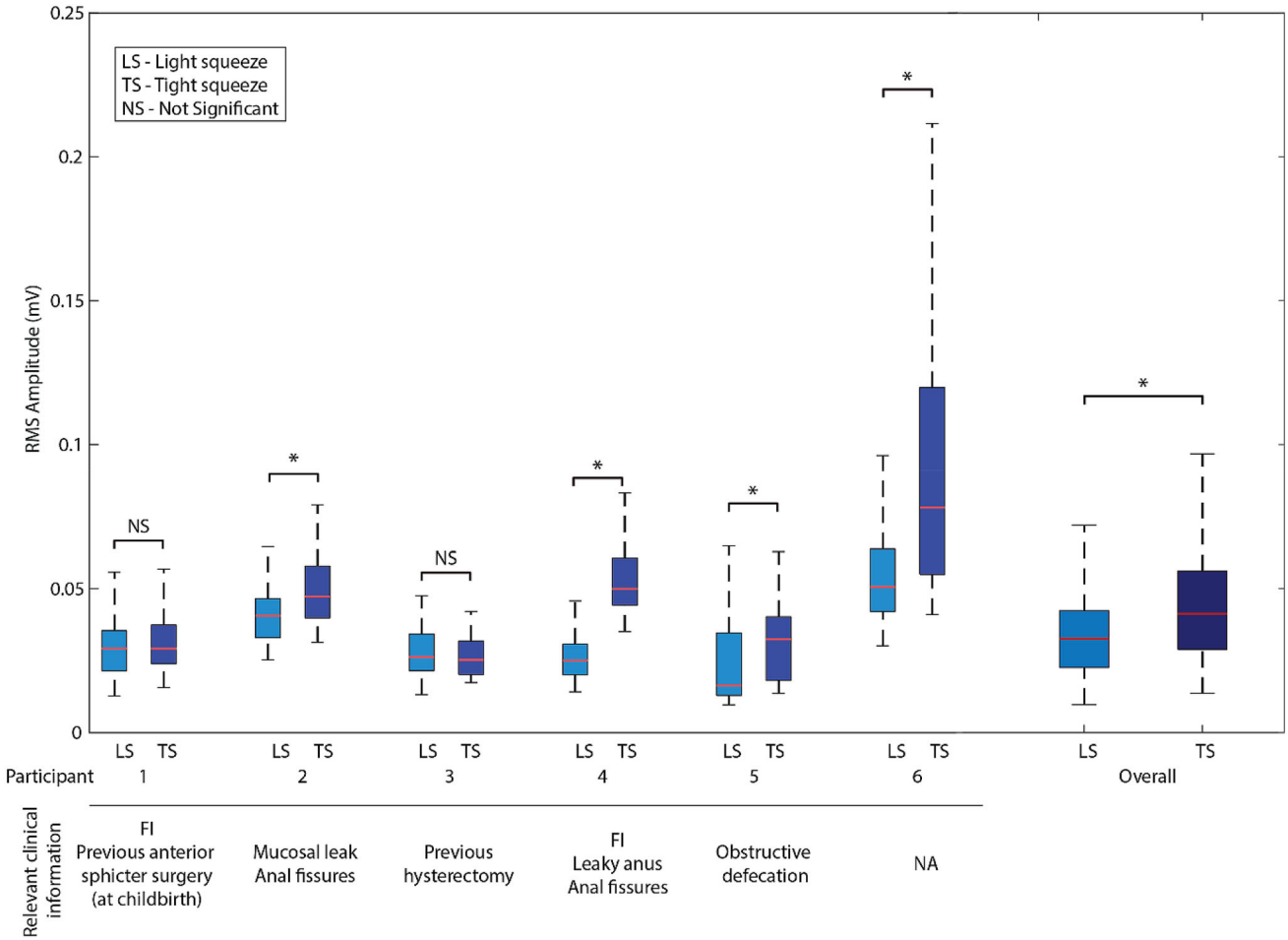

FIGURE 2. Box plot illustrating the RMS of EMG amplitude for individual participants and overall RMS amplitude across participants. The relevant clinical information for each of the participants are listed below in the *x*-axis.

stimulation in a porcine model. Preliminary clinical data indicated that the HD EMG probe could detect functional differences in squeeze pressure responses, and could potentially indicate the presence of pathophysiology in disease states. These analysis methods can now be applied to quantify spatiotemporal characteristics of sphincter function and innervation in a larger series of participants with FI in order to determine clinical utility.

The ability to profile anorectal function at high spatiotemporal resolution is now being widely applied in manometry, where pressure measurements are sampled circumferentially and longitudinally in the sphincter. Previously, only single point pressure measurements were taken using pull-through techniques.[34] HR manometry is being actively explored for clinical utility compared to traditional methods, including as a predictor of treatment outcomes.[1,4]

Currently, clinical EMG-based anorectal tests such as the PNTML, bipolar sponge electrodes and needle EMG electrodes are less commonly used than manometry. Needle approaches are invasive and therefore are not routinely used in clinical practice. Bipolar sponge electrodes are generally limited to the evaluation of paradoxical puborectalis contraction, while PNTML is falling from use due to questionable reliability and clinical utility.[34] The use of a HD-EMG probe could provide an alternative option to acquire higher-quality intrinsic and extrinsically activated muscular and neurophysiologic data on anorectal function. In particular, HD-EMG could provide a direct and precise measure of whether specific elements of the circumferential sphincter complex are intact, innervated and contracting normally; whereas pressure provides a more summative measure of function that might not be so reliable at detecting specific areas or types of inactivity.[6]

Magnetic stimulation is used clinically for diagnosis and prognosis in disorders affecting the motor system, including stroke, multiple sclerosis, and spinal cord injury.[24,37,38] Magnetic stimulation has also been used in other exploratory studies to evaluate cauda equina

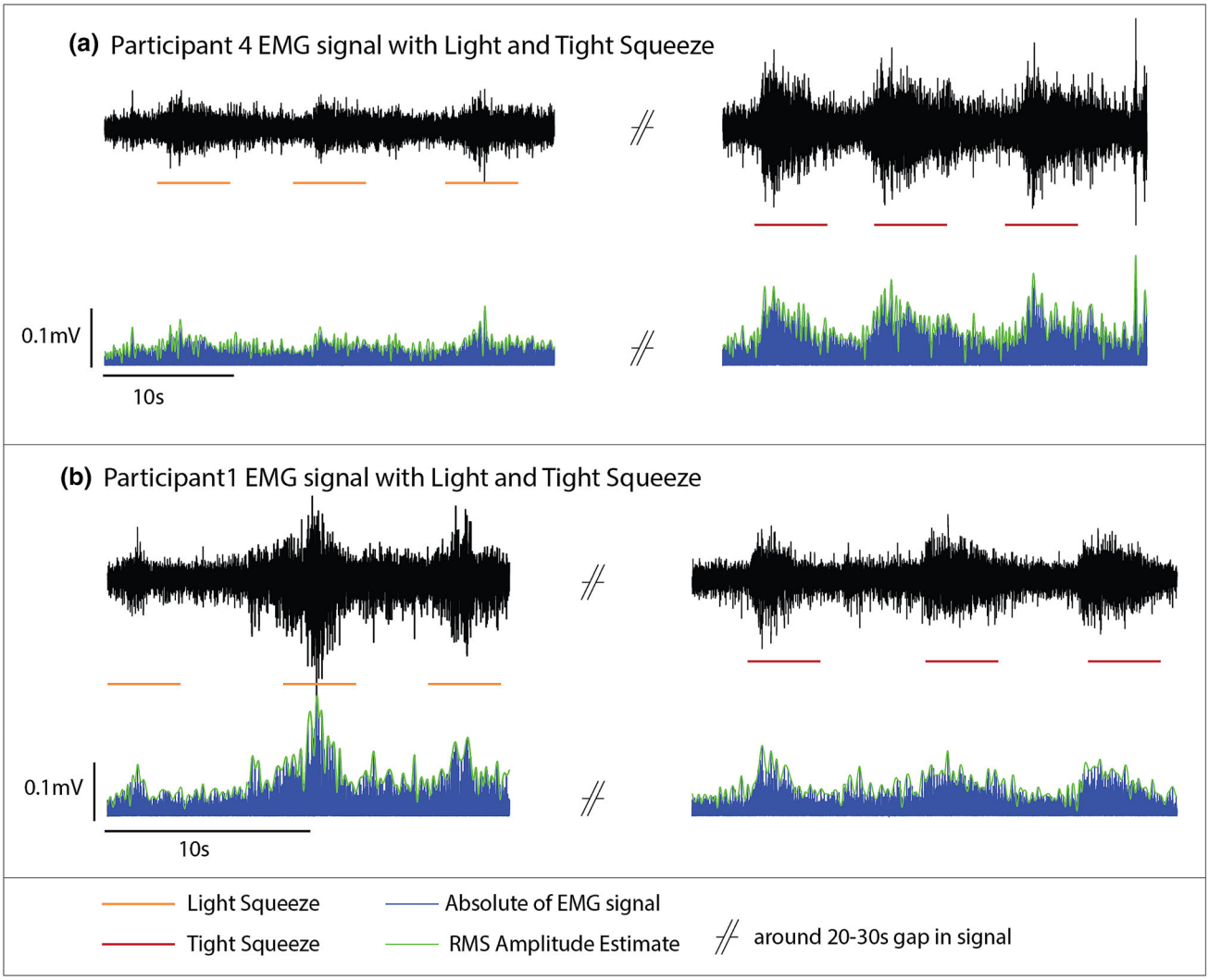

FIGURE 3. Representative anorectal EMG recordings from two participants. (a) Shows Participant 4 anorectal EMG where the amplitude during tight squeeze is higher than light squeeze. (b) Shows the EMG of Participant 3 where the EMG amplitude was comparable between light squeeze and tight squeeze.

or pudendal nerve function in patients with anorectal dysfunction. Xiang *et al.* and Rao *et al.* have shown patients with FI have longer magnetically-evoked MEP latencies.[32,45] Previous methods of measuring magnetically-evoked MEPs have been limited to low resolution EMG (needle-electrodes,[30] bipolar ring-electrodes,[32,45] three radial plate electrodes,[41] skin-surface electrode[35]) and low–resolution balloon catheter anorectal manometry.[28] Functional evaluation of the anal sphincter using these methods is limited as a single locus of EMG and is unlikely to be representative of overall sphincter function. To our knowledge, this study is the first attempt to characterize magnetically evoked MEPs using HD–EMG. Our results are concordant with the observation that the MEP amplitude increases with stimulus intensity.[42] Similar to other fields, detailed latency measurement studies are required in healthy adults and those with anorectal dysfunction to assess diagnostic or prognostic value of magnetic stimulation for clinical adoption.

There is a growing acceptance and need for computer based or algorithmic decision making for clinical diagnosis.[8,12] A study utilized 16 EMG anorectal signals to classify FI using a rule-based computerized method and showed good sensitivity and specificity measures ranging from 80 to 90%.[25] Popular machine learning techniques such as neural networks are also being applied to assess prognostic utility of therapies such as anal sphincter repair for FI.[11] With increased data collection and sampling of EMG and integration of qualitative metrics, machine learning techniques could be applied in order to further characterize the data and assist in evaluating underlying pathophysiology.


(a)
Row 1
Row 2
Row 3
Row 4
(b)
MU 1
Row 1
Row 2
Row 3
Row 4
0.18 mV
MU 2
Row 1
Row 2
Row 3
Row 4
0.2 mV
MU 3
Row 1
Row 2
Row 3
Row 4
0.17 mV
MU 4
Row 1
Row 2
Row 3
Row 4
0.14 mV
MU 5
Row 1
Row 2
Row 3
Row 4
0.11 mV
MU 6
Row 1
Row 2
Row 3
Row 4
0.07 mV

◀**FIGURE 4. Somatic HD-EMG motor unit (MU) decomposition where the MU shapes are estimated and spatially arranged according to the electrode locations in the probe as shown in (a). In (b), each MU is shown, with the first four MU occurring in one row, suggesting a circumferential muscle fibre source.**

Anorectal HD-EMG is being adopted to understand the electrophysiological nature of anorectal muscle fibers in diseased and normal states.[7,31] A multi-center trial, involving over 500 patients using HD-EMG to investigate changes in innervation zones before and after vaginal delivery provides evidence that

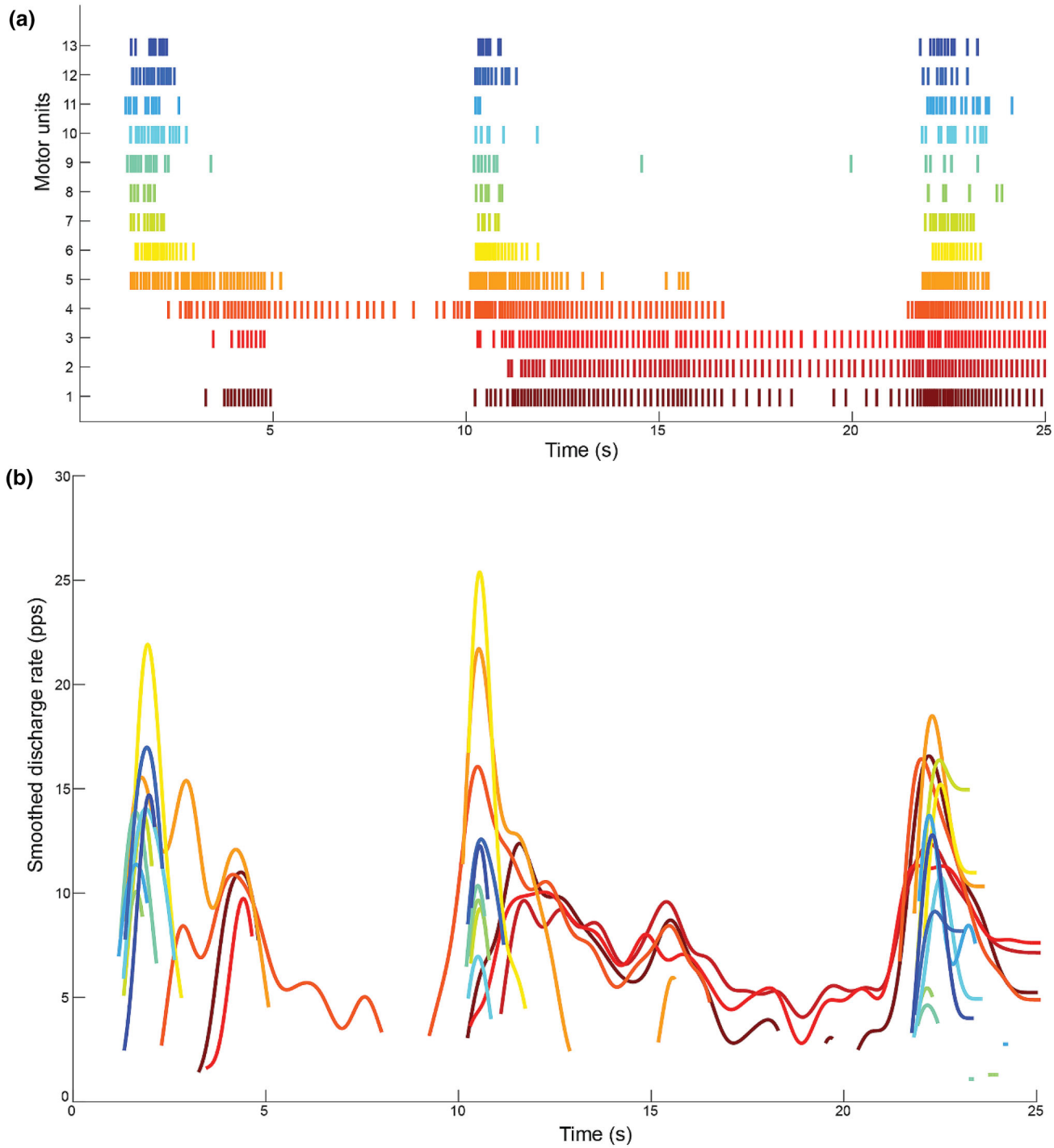

FIGURE 5. Somatic HD-EMG motor unit decomposition. (a) Shows the timing of the motor units over time for three tight squeezes for a participant. (b) Shows the discharge rate (derived from differentiating the temporal motor units). There is a rapid recruitment of motor units during the initial squeeze.

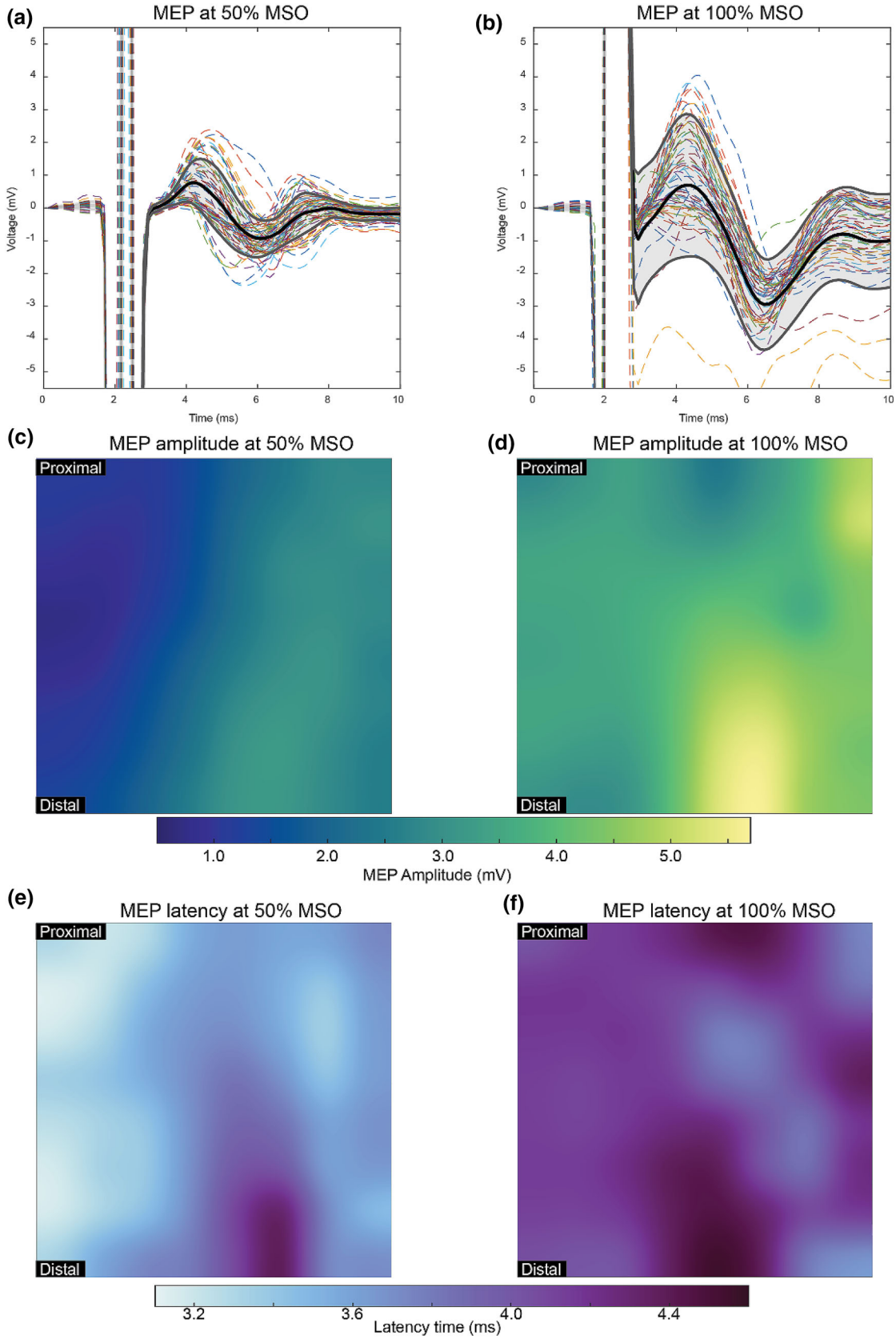
(a)
MEP at 50% MSO
Voltage (mV)
Time (ms)
(b)
MEP at 100% MSO
Voltage (mV)
Time (ms)
(c)
MEP amplitude at 50% MSO
Proximal
Distal
(d)
MEP amplitude at 100% MSO
Proximal
Distal
1.0
2.0
3.0
4.0
5.0
MEP Amplitude (mV)
(e)
MEP latency at 50% MSO
Proximal
Distal
(f)
MEP latency at 100% MSO
Proximal
Distal
3.2
3.6
4.0
4.4
Latency time (ms)

◀**FIGURE 6. Magnetically evoked anorectal motor potentials using two stimulus intensities, 50% and 100% MSO as shown in (a) and (b). The corresponding MEP amplitude and latency maps are shown in (c)–(f). In (a) and (b) all signals recorded using HD-EMG are shown as dashed lines and the averaged signal is shown as a black line with standard deviation of the signal shaded across time. MEP amplitude was 2.2 times higher with a stimulus intensity of 100% MSO than 50% MSO.**

a large amount of data can be collected for detailed data analysis and population-based understanding, along with clinical uptake.[7] Furthermore, use of MU decomposition from HD-EMG has allowed investigation of the complex external anal sphincter, which is hypothesized to have three loops of musculature.[6] In our studies we have shown that rates of MU recruitment/firing increased during the voluntary squeeze and then decreased as the participant relaxed. Larger cohorts of healthy adults and patients are required to allow detailed investigation between MU recruitment in these cohorts. In future, our design of the HD-EMG anorectal probe will be optimized, primarily with the choice of electrode material, electrode size and inter-electrode distance.[27] Optimal reference electrodes should also be of the same material as the measurement electrodes and at a similar location, yet not in contact with the desired signal.[21] While other studies have used external references,[20] or bipolar electrode systems,[10] a reference electrode on the probe may optimize noise mitigation.

In conclusion, anorectal HD-EMG probes were designed and applied in human and animal trials to assess intrinsic and extrinsically activated pathways in the anorectum. Analysis methods were also developed to quantify and visualize the EMG, MU and MEP activation in the anorectum. There were three key findings in this study. First, a low EMG amplitude during a tight squeeze may indicate a potential weakness in a subject's anorectum, and this could be used clinically to grade severity. Second, we have shown that voluntary MU potentials can be decomposed from HD-EMG recordings. Third, we have shown that the innervation of the anorectal sphincter can be tested using magnetic stimulation in combination with HD-EMG, whereby the amplitude and latency of the resulting magnetically-evoked MEPs can be quantified and visualized in spatio-temporal detail. The techniques presented in this paper therefore provide a novel approach to gain increased information about the electro-physiological mechanisms (*via* somatic and extrinsically activated pathways) involved in anorectal dysfunction and paves a path for improved diagnostics of anorectal dysfunction. Biomarkers such as propagation pathway, magnetically-evoked MEP latency, and signal morphology could be tested and validated, along with reporting normative values, for diagnostic and prognostic clinical utility. To achieve this clinical translation studies utilizing HD–EMG anorectal probe along with trans-sacral magnetic stimulation in a large

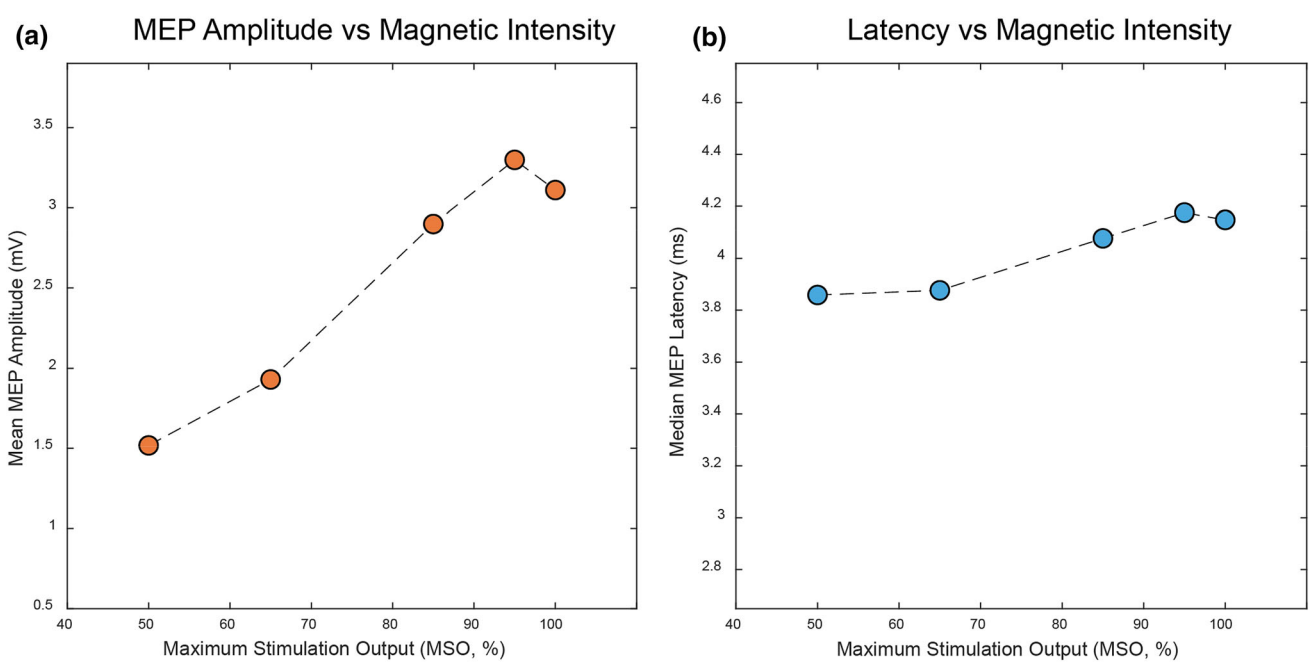

FIGURE 7. MEP amplitude (a) and latency (b) across magnetic intensities. MEP amplitude increased with increasing stimulus intensity ($p < 0.05$). However, MEP latency was consistent across stimulus intensities. ($p > 0.05$).

cohort of control and FI participants will need to be performed.

ACKNOWLEDGMENTS

The authors would like to acknowledge the assistance of the clinical staff at Greenlane Hospital and Ms Linley Nisbet from University of Auckland.

FUNDING

This project was funded in part by the Medical Technologies Centre of Research Excellence (MedTech CoRE), the Health Research Council of New Zealand, the International Research Training Programme (IRTG) on Soft Tissue Robotics and by the Slovenian Research Agency (projects J2-1731 and L7-9421 and Programme funding P2-0041).

DISCLOSURES

NP, LC and GOG hold intellectual property in the field of gastric electrophysiology and are shareholders in FlexiMap Ltd. No commercial financial support was received for this study.

REFERENCES

[1]Andrianjafy, C., L. Luciano, A. Loundou, M. Bouvier, and V. Vitton. Three-dimensional high-resolution anorectal manometry can predict response to biofeedback therapy in defecation disorders. *Int. J. Colorectal Dis.* 34:1131–1140, 2019.

[2]Aziz, I., O. S. Palsson, H. Törnblom, and A. D. Sperber. The prevalence and impact of overlapping Rome IV-diagnosed functional gastrointestinal disorders on somatization, quality of life, and healthcare utilization : a cross-sectional general population study in three countries. *Am. J. Gastroenterol.* 113:86–96, 2018.

[3]Bartolo, D. C., J. A. Jarratt, and N. W. Read. The use of conventional electromyography to assess external sphincter neuropathy in man. *J. Neurol. Neurosurg. Psychiatry* 46:1115–1118, 1983.

[4]Carrington, E. V., C. H. Knowles, U. Grossi, and S. M. Scott. High-resolution anorectal manometry measures are more accurate than conventional measures in detecting anal hypocontractility in women with fecal incontinence. *Clin. Gastroenterol. Hepatol.* 17:477–485, 2019.

[5]Carrington, E. V., S. M. Scott, A. Bharucha, F. Mion, J. M. Remes, A. Malcolm, H. Heinrich, M. Fox, and S. S. Rao. Advances in the evaluation of anorectal function. *Nat. Rev. Gastroenterol. Hepatol.* 15:309–323, 2018.

[6]Cescon, C., L. Mesin, M. Nowakowski, and R. Merletti. Geometry assessment of anal sphincter muscle based on monopolar multichannel surface EMG signals. *J. Electromyogr. Kinesiol.* 21:394–401, 2011.

[7]Cescon, C., D. Riva, V. Za, K. Drusany-stari, K. Martsidis, O. Protsepko, K. Baessler, and R. Merletti. Effect of vaginal delivery on the external anal sphincter muscle innervation pattern evaluated by multichannel surface EMG: results of the multicentre study TASI-2. *Int. Urogynecol. J.* 25:1491–1499, 2014.

[8]Chen, P.-J., M.-C. Lin, M.-J. Lai, J.-C. Lin, H. H.-S. Lu, and V. S. Tseng. Accurate classification of diminutive colorectal polyps using computer-aided analysis. *Gastroenterology* 154:568–575, 2018.

[9]Cheong, D. M. O., C. A. Vaccaro, S. D. Waxner, V. D. Salanga, R. C. Phillips, and M. R. Hanson. Electrodiagnostic evaluation of fecal incontinence. *Muscle Nerve* 18:612–619, 1995.

[10]Enck, P., H. Franz, F. Azpiroz, X. Fernandez-Fraga, H. Hinninghofen, K. Kaske-Bretag, A. Bottin, S. Martina, and R. Merletti. Innervation zones of the external anal sphincter in healthy male and female subjects. *Digestion* 69:123–130, 2004.

[11]Gardiner, A., G. Kaur, J. Cundall, and G. S. Duthie. Neural network analysis of anal sphincter repair. *Dis. Colon Rectum* 47:192–197, 2004.

[12]Hagiwara, Y., H. Fujita, S. L. Oh, J. H. Tan, R. San Tan, E. J. Ciaccio, and U. R. Acharya. Computer-aided diagnosis of atrial fibrillation based on ECG signals: a review. *Inf. Sci.* 467:99–114, 2018.

[13]Hallett, M. Transcranial magnetic stimulation: a primer. *Neuron* 55:187–199, 2007.

[14]Holobar, A., D. Farina, M. Gazzoni, R. Merletti, and D. Zazula. Estimating motor unit discharge patterns from high-density surface electromyogram. *Clin. Neurophysiol.* 120:551–562, 2009.

[15]Holobar, A., and D. Zazula. Multichannel blind source separation using convolution kernel compensation. *IEEE Trans. Signal Process.* 55:4487–4496, 2007.

[16]Kasius, K. M., F. Claes, J. Meulstee, H. C. Weinstein, and W. I. M. Verhagen. Comparison of peak versus onset latency measurements in electrodiagnostic tests for carpal tunnel syndrome. *J. Clin. Neurophysiol.* 31:382–386, 2014.

[17]Kiff, E. S., F. S. Mark, and T. L. Hospital. Normal proximal and delayed distal conduction in the pudendal nerves of patients with idiopathic (neurogenic) faecal incontinence. *J. Neurol. Neurosurg. Psychiatry* 47:820–823, 1984.

[18]Kiff, E. S., and M. Swash. Slowed conduction in the pudendal nerves in idiopathic (neurogenic) faecal incontinence. *Br. J. Surg.* 71:614–616, 1984.

[19]Lacima, G., M. Pera, X. González-Argenté, A. Torrents, J. Valls-Solé, and M. Espuña-Pons. Is electromyography a predictive test of patient response to biofeedback in the treatment of fecal incontinence? *Neurourol. Urodyn.* 35:390–394, 2016.

[20]Lefaucheur, J. P. Intrarectal ground electrode improves the reliability of motor evoked potentials recorded in the anal sphincter. *Muscle Nerve* 32:110–112, 2005.

[21]Ludwig, K. A., R. M. Miriani, N. B. Langhals, M. D. Joseph, D. J. Anderson, and D. R. Kipke. Using a Common Average Reference To Improve Cortical Neuron Recordings From Microelectrode Arrays. *J. Neurophysiol.* 101:1679–1689, 2009.

[22]Merletti, R., A. Bottin, C. Cescon, D. Farina, M. Gazzoni, S. Martina, L. Mesin, M. Pozzo, A. Rainoldi, and P. Enck. Multichannel surface EMG for the non-invasive assessment of the anal sphincter muscle. *Digestion* 69:112–122, 2004.

[23]Meurette, G., C. Blanchard, E. Duchalais-Dassonneville, S. Coquenlorge, P. Aubert, M. Wong, P. A. Lehur, and M. Neunlist. Sacral nerve stimulation enhances epithelial barrier of the rectum: Results from a porcine model. *Neurogastroenterol. Motil.* 24:267-e110, 2012.

[24]Nardone, R., Y. Höller, F. Brigo, A. Orioli, F. Tezzon, K. Schwenker, M. Christova, S. Golaszewski, and E. Trinka. Descending motor pathways and cortical physiology after spinal cord injury assessed by transcranial magnetic stimulation: a systematic review. *Brain Res.* 1619:139–154, 2015.

[25]Nowakowski, M., K. A. Tomaszewski, R. M. Herman, J. Sałówka, M. Romaniszyn, M. Rubinkiewicz, and J. A. Walocha. Developing a new electromyography-based algorithm to diagnose the etiology of fecal incontinence. *Int. J. Colorectal Dis.* 29:747–754, 2014.

[26]O'Grady, G., T. R. Angeli, N. Paskaranandavadivel, J. C. Erickson, C. I. Wells, A. A. Gharibans, L. K. Cheng, and P. Du. Methods for high-resolution electrical mapping in the gastrointestinal tract. *IEEE Rev. Biomed. Eng.* 12:287–302, 2018.

[27]O'Grady, G., N. Paskaranandavadivel, T. R. Angeli, P. Du, J. A. Windsor, L. K. Cheng, and A. J. Pullan. A comparison of gold versus silver electrode contacts for high-resolution gastric electrical mapping using flexible printed circuit board arrays. *Physiol. Meas.* 32:N13–N22, 2011.

[28]Paris, G., N. Chastan, G. Gourcerol, E. Verin, J. F. Menard, F. Michot, J. Weber, and A. M. Leroi. Evoked pressure curves from the external anal sphincter following transcranial magnetic stimulation in healthy volunteers and patients with faecal incontinence. *Colorectal Dis.* 15:e732–e740, 2013.

[29]Paskaranandavadivel, N., L. K. Cheng, P. Du, G. O'Grady, and A. J. Pullan. Improved signal processing techniques for the analysis of high resolution serosal slow wave activity in the stomach. *Proceedings of the Annual International Conference of the IEEE Engineering in Medicine and Biology Society*, 2011, pp. 1737–1740.

[30]Pelliccioni, G., O. Scarpino, and V. Piloni. Motor evoked potentials recorded from external anal sphincter by cortical and lumbo-sacral magnetic stimulation: normative data. *J. Neurol. Sci.* 149:69–72, 1997.

[31]Peng, Y., J. He, R. Khavari, T. B. Boone, and Y. Zhang. Functional mapping of the pelvic floor and sphincter muscles from high-density surface EMG recordings. *Int. Urogynecol. J.* 27:1689–1696, 2016.

[32]Rao, S. S. C., E. Coss-Adame, K. Tantiphlachiva, A. Attaluri, and J. Remes-Troche. Translumbar and transsacral magnetic neurostimulation for the assessment of neuropathy in fecal incontinence. *Dis. Colon Rectum* 57:645–652, 2014.

[33]Rogers, J., M. M. Henry, and J. J. Misiewicz. Disposable pudendal nerve stimulator: evaluation of the standard instrument and new device. *Gut* 29:1131–1133, 1988.

[34]Scott, S. M., and M. A. Gladman. Manometric, sensorimotor, and neurophysiologic evaluation of anorectal function. *Gastroenterol. Clin. North Am.* 37:511–538, 2008.

[35]Shafik, A. Magnetic pudendal neurostimulation: a novel method for measuring pudendal nerve terminal motor latency. *Clin. Neurophysiol.* 112:1049–1052, 2001.

[36]Sharma, A., L. Yuan, R. J. Marshall, A. E. H. Merrie, and I. P. Bissett. Systematic review of the prevalence of faecal incontinence. *Br. J. Surg.* 103:1589–1597, 2016.

[37]Simpson, M., and R. Macdonell. The use of transcranial magnetic stimulation in diagnosis, prognostication and treatment evaluation in multiple sclerosis. *Multiple Scler. Relat. Disord.* 4:430–436, 2015.

[38]Stinear, C. Prediction of recovery of motor function after stroke. *Lancet Neurol.* 9:1228–1232, 2010.

[39]Tetzschner, T., M. Sørensen, O. Ø. Rasmussen, G. Lose, and J. Christiansen. Reliability of pudendal nerve terminal motor latency. *Int. J. Colorectal Dis.* 12:280–284, 1997.

[40]Thomas, C., J.-P. Lefaucheur, G. Galula, V. de Parades, J. Bourguignon, and P. Atienza. Respective value of pudendal nerve terminal motor latency and anal sphincter electromyography in neurogenic fecal incontinence. *Clin. Neurophysiol.* 32:85–90, 2002.

[41]Turnbull, G. K., S. Hamdy, Q. Aziz, K. D. Singh, and D. G. Thompson. The cortical topography of human anorectal musculature. *Gastroenterology* 117:32–39, 1999.

[42]Weber, M., and A. A. Eisen. Magnetic stimulation of the central and peripheral nervous systems. *Muscle Nerve* 25:160–175, 2002.

[43]Whitehead, W. E., L. Borrud, P. S. Goode, S. Meikle, E. R. Mueller, A. Tuteja, A. Weidner, M. Weinstein, and W. Ye. Fecal incontinence in US adults: epidemiology and risk factors. *Gastroenterology* 137:512–517.e2, 2009.

[44]Whitehead, W. E., A. Wald, N. E. Diamant, P. Enck, J. H. Pemberton, and S. S. C. Rao. Functional disorders of the anus and rectum. *Gut* II45:II55–59, 1999.

[45]Xiang, X., T. Patcharatrakul, A. Sharma, R. Parr, S. Hamdy, and S. S. C. Rao. Cortico-anorectal, spino-anorectal, and cortico-spinal nerve conduction and locus of neuronal injury in patients with fecal incontinence. *Clin. Gastroenterol. Hepatol.* 17:1130–1137.e2, 2019.

Publisher's Note Springer Nature remains neutral with regard to jurisdictional claims in published maps and institutional affiliations.