Rheumatology International (2021) 41:595–603
https://doi.org/10.1007/s00296-020-04781-4

Rheumatology
INTERNATIONAL

OBSERVATIONAL RESEARCH

The structural, functional and electrophysiological assessment of paraspinal musculature of patients with ankylosing spondylitis and non-radiographic axial spondyloarthropathy

Ekim Can Ozturk[1] · **Ilker Yagci**[1]

Received: 27 November 2020 / Accepted: 29 December 2020 / Published online: 27 January 2021
© The Author(s), under exclusive licence to Springer-Verlag GmbH, DE part of Springer Nature 2021

Abstract

Paravertebral muscles are affected in spondyloarthritis. Decreased mobility of spine may lead to atrophy and fatty degeneration of these muscles. The objective of this study was to compare the sonographic, electrophysiological and magnetic resonance imaging (MRI) features of paraspinal muscles between patients with ankylosing spondylitis (AS) and non-radiographic axial spondyloarthritis (nr-axSpA). The patients who were diagnosed as AS with modified New York criteria and those as nr-axSpA with ASAS 2009 criteria were enrolled. Clinical evaluation, electrophysiological examination including nerve conduction studies and needle electromyography (EMG) for lower extremities and paraspinal mapping (PSM) were performed by the first examiner. The second examiner measured lumbar multifidus areas, graded the fatty degeneration of the muscle at different levels in T2 weighted axial MRI and also performed the ultrasonographic evaluation. A total of 19 patients with AS and 14 patients with nr-axSpA were evaluated. MRI of 2 patients with AS could not be obtained. Right lumbar multifidus area/vertebra area (MV ratio) was smaller in AS patients at L3 level (p 0,029); there were no significant differences in other levels. Fatty degeneration was also higher in AS patients in left multifidus at L5–S1 disc level (p 0,015). PSM scores that demonstrate the extent of denervation in paraspinal muscles were significantly higher in AS patients than in nr-axSpA patients ($p < 0{,}001$). Patients with AS have more fatty degeneration and denervation in paraspinal muscles. These processes may also contribute the severity of pain and disability. The relationship between paraspinal muscle denervation and progression of fatty degeneration should further be revealed.

Keywords Paraspinal mapping · Multifidus · Electromyography · Ankylosing spondylitis · Non-radiographic axial spondyloarthritis · Ultrasonography

Introduction

Spondyloarthropathy (SpA) defines a heterogeneous group of rheumatic diseases and is classified as axial and peripheral SpA in accordance with the predominant symptoms and findings. Axial SpA is also subdivided into two groups as radiographic and non-radiographic, consistent with the features of the sacroiliac joints, and radiographic SpA includes ankylosing spondylitis (AS) [1]. It is still unclear whether non-radiographic axial spondyloarthropathy (nr-axSpA) is an early phase of ankylosing spondylitis or a separate clinical entity [2, 3].

Paravertebral muscles are affected in ankylosing spondylitis. The restriction of spinal mobility is a well-known process in the disease; immobility-related atrophy of the paravertebral muscles is common and could be a potential cause of worsened quality of life [4, 5]. There have been a few studies in which the lumbar multifidus muscles of patients with AS and non-radiographic SpA were examined by magnetic resonance imaging (MRI), and the electrophysiological findings of paraspinal muscles of patients with AS and mechanical low back pain were compared. The data obtained from aforementioned surveys demonstrate that more fatty degeneration occurs in the multifidus muscle in patients with AS than those with non-radiographic SpA [4, 6]. Ultrasound

✉ Ekim Can Ozturk
ekimtrilogy@gmail.com

Ilker Yagci
drilkery@yahoo.com

[1] Department of Physical Medicine and Rehabilitation, School of Medicine, Marmara University, Fevzi Çakmak Mh., Muhsin Yazıcıoğlu Cd., No:10, Pendik, 34899 Istanbul, Turkey

(US) imaging on the other hand was found to be reliable for thickness measurement and dynamic examination of lumbar multifidus muscle [7].

In this study, our hypothesis is that multifidus muscle undergoes more fatty degeneration in patients with AS compared to patients with non-radiographic SpA, which impairs the function of the muscle. In keeping with the former one, our second and novel hypothesis is that paraspinal muscle electrophysiology is also expected to be deteriorated in AS group.

Materials and methods

Design

Observational cross-sectional study

Participants Approval was taken from the Ethics Committee of XXXX prior to the initiation of the study, and all steps were approached with respect to Declaration of Helsinki. Among the patients admitted to the physical medicine and rehabilitation outpatient clinic, those ageing between 18 and 65 years, diagnosed with AS according to the modified New York criteria and non-radiographic SpA according to the ASAS 2009 criteria, were included into two groups. A written informed consent was obtained from each participant before enrolment. Patients who have another inflammatory rheumatic disease except SpA or endocrine disease (diabetes mellitus, thyroid function abnormalities, etc.) deemed to affect electrophysiological findings or contradiction to electrophysiological examination (cardiac pacemaker, bleeding diathesis etc.), history of back surgery, hesitation to participate the survey were excluded.

Assessment tools

Clinical evaluation of patients, interpretation of plain radiographs and MRI scans of sacroiliac joints were carried out by first physician. Demographic data, laboratory tests including C-reactive protein (CRP), erythrocyte sedimentation rate (ESR), HLA-B27, physical examination findings such as range of motion of spine and hips, Schober's test, chest expansion, response to provocative manoeuvres for sacroiliac joints were noted. The Bath Ankylosing Spondylitis Metrology Index (BASMI), Disease Activity Index (BASDAI), Functional Index (BASFI), Radiology Index for the spine (BASRI-s) were calculated for mobility, disease activity, functional status and radiologic assessment, respectively. Spine radiographs were rated with the modified Stoke Ankylosing Spondylitis Spinal Score (m-SASSS) between C2–T1 and T12–S1 levels additionally.

A second physician with 4 years of experience in lumbar MRI and US, who was blinded to the diagnosis of patients, graded the fat content of right and left lumbar multifidus muscles at L4–L5 and L5–S1 disc levels semi-quantitatively (grade 0, normal = < 10% fat; grade 1, slight = > 10% but < 25% fat; grade 2, moderate = > 25% but < 50% fat; 3, severe = > 50% fat within the muscle) in T2 weighted axial magnetic resonance images (Fig. 1). Cross-sectional area (CSA) of the muscle was also measured bilaterally at L2, L3, L4 and L5 levels (Fig. 2). To decrease the margin of error, CSA of multifidus muscle was divided by the CSA of the vertebral corpus at the same level (muscle:vertebra ratio, MVr) [6]. Functional assessment of multifidus muscle with ultrasonographic thickness measurement at rest and during a submaximal contraction was performed with the technique described by Koppenhaver et al. [7]. Images were acquired in B mode with a GE Logic P5 device and a 2–5-MHz curvilinear array with constant gain, frequency, depth settings. To depict briefly, measurements were performed in prone and made between the posterior-most portion of the relevant zygapophyseal joint and the plane between the muscle and subcutaneous tissue at L4–L5 and L5–S1 levels (Fig. 3, Fig. 4). For the submaximal contraction, patients were asked for a contralateral arm lift about 5 cm off the table with the elbows flexed 90°, shoulders abducted 120° while holding a hand mass appropriate with their body weight [7]. An electrophysiological examination was also carried out by first physician who has twenty years of experience in electroneuromyography. Medtronic Keypoint Portable device was used to carry out peroneal, tibial and sural nerve conduction studies (NCS), lower extremity needle electromyography (EMG) of tibial, peroneus longus and gastrocnemius muscles and paraspinal mapping (PM). Paraspinal mapping is a well-described technique to detect denervation of single-level innervated 'specific' multifidus muscle and multi-level innervated 'mixed' superficial muscles; longissimus and iliocostalis. It provides a quantitative data of paraspinal muscle denervation and is shown to be useful in lumbar spinal stenosis [8]. In prone, the middle point of the line passing through the posterior superior iliac spines of the patient was taken as reference and L5 spinous process was found. Then, 2.5 cm lateral and 1 cm cranial of spinous processes of L2, L3, L4, L5 vertebrae were marked. 50–75-mm monopolar EMG needle was directed at a 45° angle towards the midline and advanced with 5-mm needle movements till it touches spinous process. Acute denervation potentials (positive sharp wave, fibrillation), which are indicators of membrane instability in muscle, were scored as 0 and 4 + . Scores were recorded under the M column due to mixed innervation of superficial muscles at the first 4 cm depth and to the specific column S, where the multifidus muscle was evaluated at the last 1 cm depth. The procedure was repeated with the needle directed 45° cranial and caudal

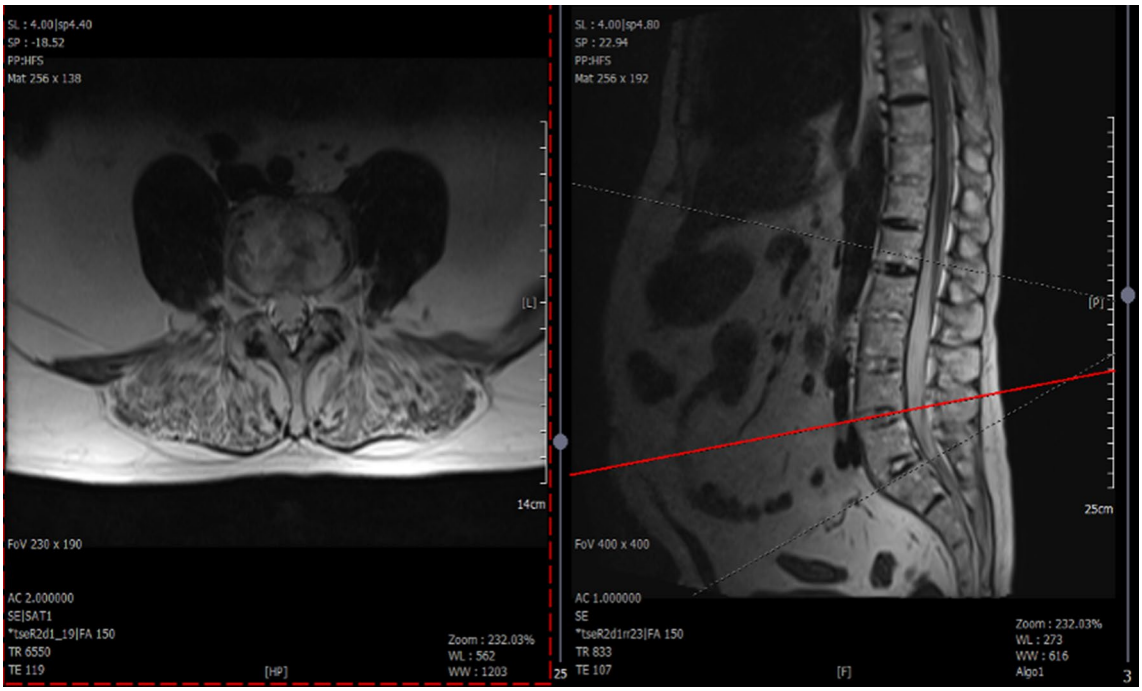

Fig. 1 Grade 3 fatty degeneration at L4–L5 disc level

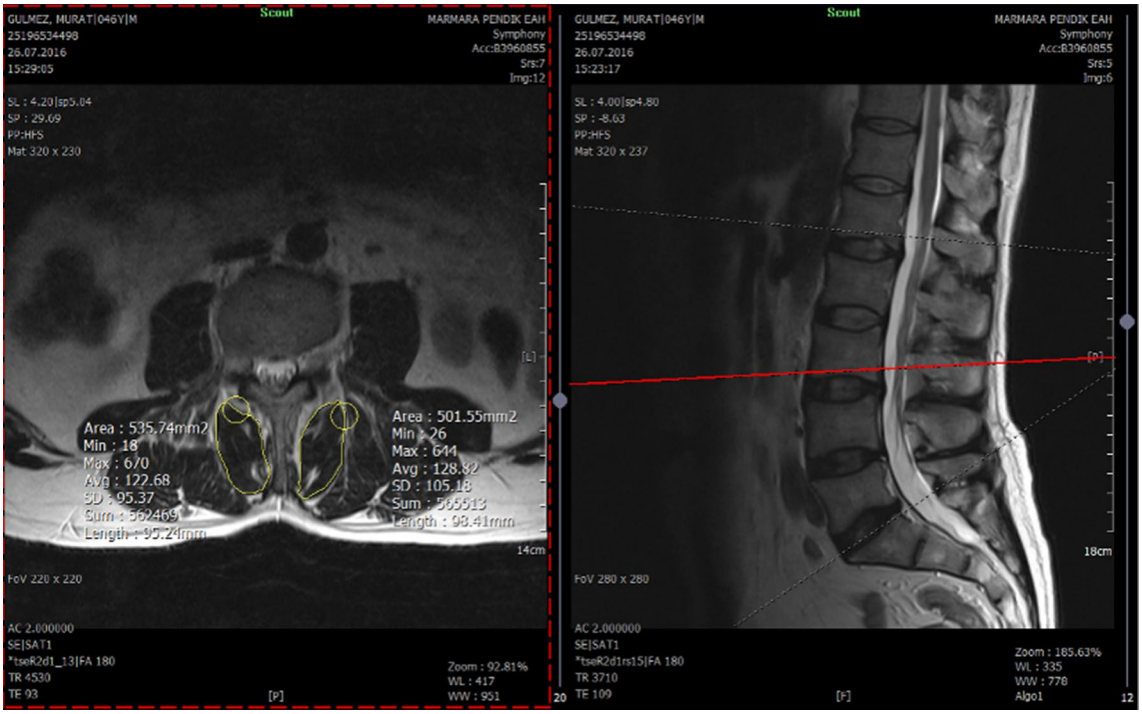

Fig. 2 Cross-sectional area measurement of multifidus muscle at L3 level

for the same level. The sum of the "+'s" range between 0 and 96, where high score means more profound denervation. The method lasted an average of 10 min in each patient. The normal value was found to be 2 and below in a healthy population under 50 years of age [9]. Abnormal spontaneous activities such as complex repetitive discharges (CRD), fasciculations which are not included in scoring, were also noted.

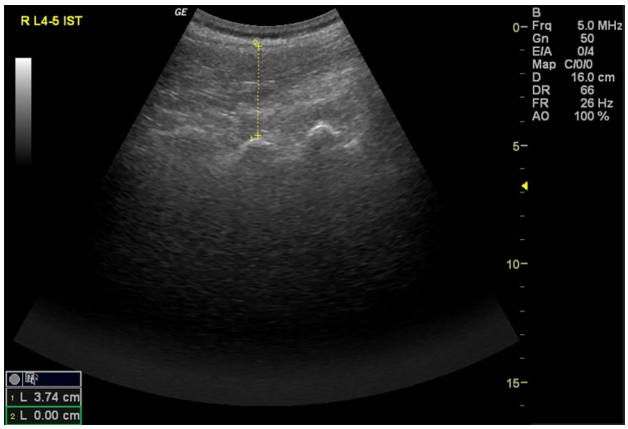

Fig. 3 Thickness measurement of multifidus muscle at rest at L4–L5 zygapophyseal joint level

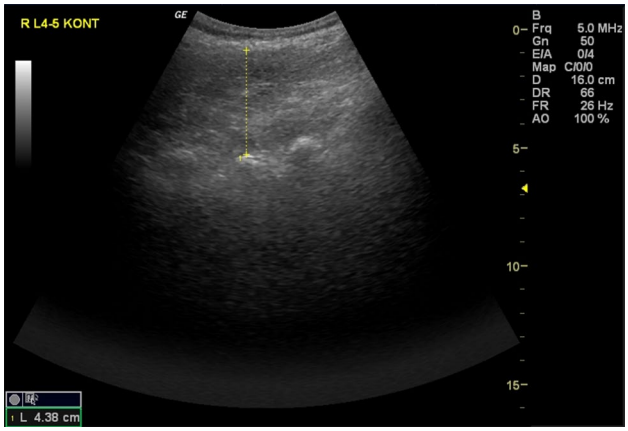

Fig. 4 Thickness measurement of multifidus muscle during contraction at L4–L5 zygapophyseal joint level

Study outcomes

Our primary outcomes are the evaluation of lumbar multifidus in two different patient population with MRI and US which show the degree of fatty degeneration and functional status of the relevant muscle, respectively. Our second outcome, which may be more worthy of note, is to delineate electrophysiological properties of paraspinal musculature in the same study groups with respect to abnormal spontaneous activities during PM.

Statistical analysis

Statistical analysis was performed with SPSS Statistics 22.0 (IBM corp., Armonk, NY, USA). Descriptive analyses were compared with Pearson Chi-square and Fisher's exact tests. As the number of samples was 33, the normal distribution of variables was examined with histogram graphics and Kolmogorov–Smirnov test. All values were considered nonparametric, and Mann–Whitney *U* test was used to the make comparisons of age, body mass index (BMI) and duration of symptoms between the groups. Data are presented as median, minimum and maximum values. Correlations between m-SASSS, BASRI-s, BASFI, BASDAI, BASMI, chest expansion, Schober's test and PM score were determined with Spearman correlation test. Results with a *p* value less than 0.05 were accepted statistically significant.

Results

Twenty patients with AS and 20 patients with nr-axSpA were planned to be included in the study, considering the exclusion criteria and patients willingness to participate in the study, 19 patients were included in the AS group, and 14 patients were included in the nr-axSpA group. Since 2 patients (6.1%) with AS could not take appropriate positioning, MRI scans could not be obtained and PM scores of 2 different patients (6.1%) in the same group could not be evaluated, because of inadequate muscle relaxation during the examination. There was no data loss in nerve conduction studies, lower extremity needle EMG and US measurements.

There was no statistically significant difference between the groups in terms of age and BMI ($p > 0.05$). Compatible with previous reports, male predominancy was observed in both groups without significant difference between each other (AS: 84,21%, nr-axSpA: 64,29%). The median symptom duration (10 years) of the AS group was significantly higher than the nr-axSpA group (3 years) (*p* 0,001) (Table 1). Current TNF inhibitor therapy among patients with AS (84.21%) was significantly more common than patients with nr-axSpA (14.29%) ($p < 0.001$). Although HLA-B27 positivity was more frequent in the AS group, no significant difference was found between the groups (AS: 57,89%, nr-axSpA: 28,57) (*p* 0,095). Laboratory markers such as CRP and ESR were also similar ($p > 0.05$) (Table 2). Physical examination findings derived from Schober's test and chest expansion measurements, BASMI scores showing mobility of hip and spine, indicated significant limitation

Table 1 Age, BMI and symptom duration of patients

	AS Median (Min–Max)	nr-axSpA Median (Min–Max)	*p*
Age	39.00 (20.00–60.00)	34.50 (20.00–49.00)	0.053*
BMI	28.38 (21.22–30.48)	28.41 (21.46–35.29)	0.689*
Symptom duration (year)	10.00 (1.00–30.00)	3.00 (1.00–7.00)	**0.001***

AS ankylosing spondylitis, *BMI* body mass index, *nr-axSpA* non-radiographic axial spondyloarthropathy

*Mann–Whitney *U* test, bold value indicates statistical significance

Table 2 Comparison of ESR, CRP, Schober's test (cm), chest expansion (cm) and BASMI values

	AS Median (Min–Max)	nr-axSpA Median (Min–Max)	*P*
ESR	16.00 (3.00–62.00)	13.50 (4.00–30.00)	0.304*
CRP	3.00 (3.00–35.00)	3.50 (3.00–20.00)	0.957*
Schober's test (cm)	4.00 (0.50–6.00)	5.00 (2.5–8.00)	**0.012***
Chest expansion (cm)	2.50 (1.00–6.50)	3.50 (2.00–6.00)	**0.021***
BASMI	6.00 (5.00–13.00)	5.00 (5.00–6.00)	**0.026***

AS ankylosing spondylitis, *BASMI* bath ankylosing spondylitis metrology index, *CRP* C-reactive protein, *ESR* erythrocyte sedimentation rate, *nr-axSpA* non-radiographic axial spondyloarthropathy

*Mann–Whitney *U* test, bold values indicate statistical significance

Table 4 Comparison of MVr at L2, L3, L4 and L5 levels

Level of MVr	AS Median (Min–Max)	nr-axSpA Median (Min–Max)	*p*
Right L2	0.14 (0.08–0.22)	0.14 (0.08–0.28)	0.937*
Left L2	0.13 (0.05–0.21)	0.14 (0.09–0.28)	0.361*
Right L3	0.18 (0.10–0.39)	0.24 (0.17–0.41)	**0.029***
Left L3	0.20 (0.10–0.39)	0.24 (0.17–0.41)	0.177*
Right L4	0.36 (0.03–0.84)	0.37 (0.30–0.56)	0.475*
Left L4	0.35 (0.02–0.85)	0.39 (0.29–0.51)	0.177*
Right L5	0.46 (0.23–0.94)	0.52 (0.42–0.76)	0.165*
Left L5	0.49 (0.22–0.91)	0.55(0.46–0.74)	0.095*

AS ankylosing spondylitis, *MVr* multifidus vertebra ratio, *nr-axSpA* non-radiographic axial spondyloarthropathy

*Mann–Whitney *U* test, bold value indicates statistical significance

in patients with AS as opposed to patients with nr-axSpA (Table 2).

When radiologic scores were analysed, m-SASSS and BASRI-s scores were significantly higher in the AS group, which was compatible with physical examination ($p < 0{,}001$). However, functional status and disease activity were comparable between the groups as a result of different treatment regimens ($p > 0.05$) (Table 3). On MRI evaluation, MVr (multifidus muscle cross-sectional area divided by the cross-sectional area of the vertebra at the same level) was lower in all levels between L2 and L5 in the AS group, but the difference was significant only at right L3 level (*p* 0,029) (Table 4). The fatty degeneration in the same muscle in patients with AS was more intense in comparison to patients with nr-axSpA; nonetheless, the difference was significant at left L5–S1 disc level but not in other three levels (Table 5).

While the percent thickness change in right and left multifidus at rest and during contraction detected with US at L4–L5 and L5–S1 disc levels was higher in the nr-axSpA group than the AS group, only the left multifidus thickness change at L5–S1 disc level was statistically significant in favour of nr-axSpA group (with a median value of 8.98 in the AS group, 15.32 in the nr-axSpA group) (*p* 0.022) (Table 6).

Nerve conduction studies and lower extremity needle EMG evaluation were comparable between the groups. Right tibialis anterior was the only muscle in lower extremity with statistically significant difference with respect to abnormal spontaneous activities (*p* 0.037). Paraspinal mapping scores of AS patients (13,82 ± 24,01) were significantly higher than nr-axSpA patients (1,07 ± 3,25) ($p < 0{,}001$). In addition, the presence of complex repetitive discharges and fasciculations during PM was compared between the groups; while no CRD or fasciculation was observed in any patient in the nr-axSpA group, 47.6% of the patients in the AS group showed one of these abnormal spontaneous activities which had not been counted in PM scoring (*p* 0,003). PM scores were found to be negatively correlated with Schober's test measurement (*p* 0.009) and chest expansion (*p* 0.021), positively correlated with m-SASSS (*p* 0.001), BASRI-s (*p* 0.002) and BASFI (*p* 0.02) scores.

Table 3 Comparison of BASMI, m-SASSS, BASRI-s, BASFI and BASDAI values

	AS Median (Min–Max)	nr-axSpA Median (Min–Max)	*p*
m-SASSS	24.00 (11.00–70.00)	5.50 (4.00–11.00)	**< 0.001***
BASRI-s	7.50 (4.50–12.00)	4.50 (1.50–5.00)	**< 0.001***
BASFI	1.20 (0.00–7.20)	0.80 (0.00–2.50)	0.114*
BASDAI	1.40 (0.00–7.20)	2.50 (0,90–5.20)	0.199*

AS ankylosing spondylitis, *BASDAI* the Bath ankylosing spondylitis disease activity index, *BASFI* the Bath ankylosing spondylitis functional index, *BASRI-s* the Bath ankylosing spondylitis radiology index for the spine, *m-SASSS* modified stoke ankylosing spondylitis spinal score, *nr-axSpA* non-radiographic axial spondyloarthropathy

*Mann–Whitney *U* test, bold values indicate statistical significance

Discussion

To date, there are few studies comparing paraspinal muscle morphology and histology of AS patients with healthy controls. It was suggested that atrophy in type 2 fibres and fibrosis were linked with decreased motor activity [4]. Zhang et al. found more collagen fibril accumulation and atrophy in AS patients' paraspinal muscle samples than healthy controls. They explained this by the increased TGF-beta 1 expression in these muscles in the patient group; nonetheless, there was no difference between the groups in TNF-alpha expression [10]. In another study, lumbar paraspinal muscles of AS patients and healthy

Table 5 Comparison of fatty degeneration degrees

Level of fatty degeneration		AS		nr-axSpA		*p*
		n	%	*n*	%	
Right L4-L5	Grade 1	9	(52.94)	10	(71.43)	0.235*
	Grade 2	5	(29.41)	4	(28.57)	
	Grade 3	3	(17.65)	0	(0.00)	
Left L4-L5	Grade 0	0	(0.00)	1	(7.14)	0.144*
	Grade 1	7	(41.18)	9	(64.29)	
	Grade 2	6	(35.29)	4	(28.57)	
	Grade 3	4	(23.53)	0	(0.00)	
Right L5-S1	Grade 1	2	(11.76)	5	(35.71)	0.192*
	Grade 2	11	(64.71)	8	(57.14)	
	Grade 3	4	(23.53)	1	(7.14)	
Left L5-S1	Grade 1	1	(5.88)	7	(50.00)	**0.015***
	Grade 2	11	(64.71)	6	(42.86)	
	Grade 3	5	(29.41)	1	(7.14)	

AS ankylosing spondylitis, *n* number, *nr-axSpA* non-radiographic axial spondyloarthropathy

*Chi Square and Fisher's exact tests, bold value indicates statistical significance

Table 6 Percent thickness change of multifidus at L4-5 and L5-S1 disc levels

	AS Median (Min–Max)	nr-axSpA Median (Min–Max)	*p*
L4-5 right multifidus thickness change (%)	12.62 (2.69–32.08)	13.90 (5.13–25.17)	0.274*
L4-5 left multifidus thickness change (%)	11.00 (1.88–30.89)	15.59 (5.47–27.47)	0.229*
L5-S1 right multifidus thickness change (%)	8.33 (1.53–22.13)	8.29 (3.70–19.51)	0.799*
L5-S1 left multifidus thickness change (%)	8.98 (2.07–28.53)	15.32 (7.44–30.00)	**0.022***

AS: Ankylosing spondylitis; nr-axSpA: Non-radiographic axial spondyloarthropathy;

* Mann–Whitney U test, bold value indicates statistical significance

controls were evaluated by MRI and fatty degeneration and atrophy were observed more in the AS group at almost all levels [11]. Akgul et al. evaluated cross-sectional areas and semi-quantitative fatty degeneration levels of paraspinal muscles of patients with AS and nr-axSpA. While cross-sectional areas were similar, the fatty degeneration degrees were higher in the AS group; on the basis of this, it can be concluded that the structural changes in paraspinal musculature in AS patients are in the foreground [6]. In our study, multifidus/vertebra area ratios at L2, L3, L4 and L5 levels of 17 patients in the AS group and of 14 patients in the nr-axSpA group were also comparable except right L3 level. The fatty degeneration levels of the groups in the same muscle were analysed with the semi-quantitative manner at L4–L5 and L5–S1 disc levels, although there had been more fatty degeneration in AS patients at all levels, statistical significance was detected only at left L5–S1 level. Likewise, in functional evaluation of lumbar multifidus muscles with ultrasonography, percent thickness change during resting and submaximal contraction of the muscle in L4–L5 and L5–S1 disc levels was lower at all levels in the AS group compared to the nr-axSpA group, but the statistical significance was reached only at left L5–S1disc level, probably related to the low sample size.

It has been claimed in various researchers that multifidus muscle atrophy can be a predictor of low back pain, and in patients with chronic low back pain, fat infiltration is more common in this muscle [12–14]. In patients with AS, atrophy and fat infiltration in paraspinal muscles, which are thought to be resulted due to various cytokines and limitation in spinal mobility, may have an effect on pain. In our study population, there was no difference between the groups in terms of pain scores which can be explained with common use of biologics in the AS group as opposed to the nr-axSpA group (AS:80%, nr-axSpA:14%). Therefore, a relationship between pain and electrophysiological or morphological features of the paraspinal musculature could not be clearly revealed.

There were no abnormalities in nerve conduction studies which were similar between the groups. In needle EMG evaluation tibialis anterior, gastrocnemius and peroneus longus muscles were examined bilaterally. Prolonged duration and, polyphasic motor unit potentials (MUP) were determined in MUP analyses for both groups; however, reduced

recruitment was significantly more frequent in the AS group as well as abnormal spontaneous activities for right tibialis anterior muscle. Although nerve conduction studies were normal, findings in needle EMG might be associated with concomitant radicular involvement in both groups, especially in the AS group. In a study in which neurological complications were investigated in patients with AS, the rate of radiculopathy was 8.3% in needle EMG examination of trapezius and supraspinatus muscles, while cervical radiculopathy was 29.2% and lumbosacral radiculopathy was 16.7% in somatosensory evoked potential studies, and the potential mechanisms were thought to be inflammation and compression. It has been stated that neurological involvement could be in a range that can lead to cauda equina syndrome due to spinal stenosis, dural inflammation and arachnoiditis [15]. In our study group, signs of chronic denervation in lower extremity needle EMG study were seen in both groups, but it was more severe in the AS group. The pathophysiological background of this process should be elucidated. In a study of 9 patients in which Simmons et al. examined the histopathology of paraspinal muscles in AS patients, the atrophy observed in type 1 and type 2 fibres supports the denervation of these muscles [16].

In patients with SpA, electrophysiological evaluation of paraspinal muscles was performed for the first time in the literature with a standard method. Abnormal spontaneous activities, which may be mostly associated with denervation and various myopathies, were systematically evaluated using the paraspinal mapping method. In the standard PM method, positive sharp waves and fibrillation potentials are scored, while other observed abnormal spontaneous activities such as complex repetitive discharge and fasciculations are ignored. In our study, all abnormal spontaneous activities were noted, but only positive sharp wave and fibrillation potentials were counted for scoring. As a result, the mean PM score in the AS group was 13.82 ± 24.01, and 1.07 ± 3.25 in the nr-axSpA group, indicating a significant difference between the groups. With regard to the data obtained from a study performed in our clinic with the same evaluator and method, the PM score ranges between 2.8 ± 3.5 in normal and patients with radiculopathy, while it does 33.64 ± 21.17 in patients with lumbar spinal stenosis [17]. In another survey, the normal value was found to be 2 and below in a healthy population under 50 years old while the scores increase with age [9]. Nevertheless, in our study population ages vary between 20 and 60, and the number of patients over the age of 50 was only four. Therefore, these electrophysiological abnormalities did not seem to be age dependent. In addition, it is known that there was no channel stenosis or radiculopathy due to the detailed clinical and radiological evaluation performed in all patients. Still, the PM scores were found to be quite high in the AS group. The incidence of CRD and/or fasciculation which was not included in the PM scoring was also significantly higher in the AS group (47.6%), contrary to the nr-axSpA (0%) group. These findings have not been shown before to the best of our knowledge. The high determination of these potentials in the AS group causes suspicion of chronic neurogenic involvement in these patients.

The abnormal spontaneous activities observed in the needle EMG examination of the lower extremity muscles of the patients were not as intense as those in the paraspinal muscles; thus, mechanical stress, entrapment or local inflammatory process involving predominantly the posterior primary ramus may be an explication. It is known that denervation findings can be seen in needle EMG examination in muscular disorders [18]. Our results revealed more fatty degeneration with statistical significance in the AS group at single level. Even so, at all other levels, fatty degeneration grades were higher in the same group, if not statistically significant. Whether fatty degeneration is a cause or a consequence should be enlightened. Denervation observed in the paraspinal muscles, may lead to fat accumulation. Yet, the mechanism of this denervation is not clear. Excessive inflammation in the area may affect the nerves and elicit denervation process, but this theory needs to be confirmed.

The fact that PM scores were positively correlated with BASFI, BASRI-s, m-SASSS scores and negatively correlated with Schober's test and chest expansion measurement suggests the degree of paraspinal muscle involvement increases as spinal mobility and radiological progression deteriorate. The important effects of lumbar paraspinal muscles on spine biomechanics, such as stabilization and contributing to correct movement by generating sensory feedback, explain the development of problems such as spinal deformities and balance disorders in case of denervation of these muscles [19, 20]. Although chronic low back pain also induces atrophy and deconditioning of paraspinal muscles, the relationship here seems to be bidirectional rather than a cause and effect. Paraspinal fat infiltration and muscle denervation have also been reported to accelerate the degenerative cascade of the spine [18, 21]. It is possible that denervation and atrophy contribute to the development of pain and disability, balance impairment and spinal deformity in the population we investigated. Our results may be a hint for that rehabilitation of paraspinal muscles and prescribing a specific exercise programme in early stages may bring benefit to further estimated balance problems, disability, pain and degenerative process of spine in patients with SpA. Further study is necessary to investigate the potential gains of such an exercise programme.

To summarize, there has not been any study in the literature in which paraspinal muscles of patients with AS or nr-axSpA were evaluated electrophysiologically using the PM method. Our study is valuable in terms of showing paraspinal muscle denervation for the first time with a wide

scoring system in patients with AS; nonetheless, lack of a control group and an insufficient sample size are the main limitations. Another drawback is that we did not determine the intraobserver and interobserver reliability of our measurements in MRI and US.

Conclusion

The intensity of abnormal spontaneous activities observed in paraspinal muscles of the AS group was higher with respect to the nr-axSpA group, and this involvement may be due to local inflammation, mechanical compression or stretching, especially affecting the posterior primary ramus. Denervation findings may also be associated with the degenerative process in paraspinal muscles that develops secondary to inflammatory cytokines and restriction in spinal mobility. Paraspinal muscle denervation in AS patients may contribute to the course of the disease in terms of imbalance, acceleration of the degenerative cascade and pain, which should be considered in future treatment strategies. Prospective, long-term researches with healthy controls are warranted to investigate whether our findings will appear over time in nr-axSpA patients.

Acknowledgements None.

Author contributions The authors ECO and IY conceived the study and design, carried out the assessments of participants. ECO performed the statistical analyses and wrote the draft of this paper. IY reviewed and revised the content prior to submission. They both approved the final manuscript.

Funding There is no additional funding except social health insurance expenditures of participants.

Compliance with ethical standards

Conflicts of interest The authors have no conflict of interest to declare.

Ethics approval All procedures were performed in accordance with ethical standards of the institutional/national committee and with the 1964 Helsinki declaration and its later amendments or comparable ethical standards. Ethics approval was provided from institutional ethics committee. Protocol Number: 09.2016.012.

Informed consent Written and verbal consent was obtained from all participants before the initiation of survey, and all data were kept confidential.

Consent for publication The authors give consent for publication of this paper in Rheumatology International if it is accepted.

References

1. Andreasen RA, Kristensen LE, Ellingsen T, Christensen R, Baraliakos X, Wied J et al (2017) Clinical characteristics of importance to outcome in patients with axial spondyloarthritis: protocol for a prospective descriptive and exploratory cohort study. BMJ Open 7:1–10. https://doi.org/10.1136/bmjopen-2016-015536
2. Dougados M, Baeten D (2011) Spondyloarthritis Lancet 377:2127–2137. https://doi.org/10.1016/S0140-6736(11)60071-8
3. Sieper J, Poddubnyy D (2017) Axial spondyloarthritis. Lancet 390:73–84. https://doi.org/10.1016/S0140-6736(16)31591-4
4. Cooper RG, Freemont AJ, Fitzmaurice R, Alani SM, Jayson MIV (1991) Paraspinal muscle fibrosis: a specific pathological component in ankylosing spondylitis. Ann Rheum Dis 50:755–759. https://doi.org/10.1136/ard.50.11.755
5. Hopkins GO, Mcdougall J, Mills KR, Isenberg DA, Ebringer A (1983) Muscle changes in ankylosing spondylitis. Rheumatology 22:151–157. https://doi.org/10.1093/rheumatology/22.3.151
6. Akgul O, Gulkesen A, Akgol G, Ozgocmen S (2013) MR-defined fat infiltration of the lumbar paravertebral muscles differs between non-radiographic axial spondyloarthritis and established ankylosing spondylitis. Mod Rheumatol 23:811–816. https://doi.org/10.1007/s10165-012-0750-6
7. Koppenhaver SL, Hebert JJ, Fritz JM, Parent EC, Teyhen DS, Magel JS (2009) Reliability of rehabilitative ultrasound imaging of the transversus abdominis and lumbar multifidus muscles. Arch Phys Med Rehabil 90:87–94. https://doi.org/10.1016/j.apmr.2008.06.022
8. Haig AJ (1997) Clinical experience with paraspinal mapping. II: a simplified technique that eliminates three-fourths of needle insertions. Arch Phys Med Rehabil 78:1185–1190. https://doi.org/10.1016/S0003-9993(97)90329-4
9. Tong HC, Haig AJ, Yamakawa KSJ, Miner JA (2005) Paraspinal electromyography: age-correlated normative values in asymptomatic subjects. Spine. https://doi.org/10.1097/01.brs.0000176318.95523.12
10. Zhang Y, Xu H, Hu X, Zhang C, Chu T, Zhou Y (2016) Histopathological changes in supraspinous ligaments, ligamentum flava and paraspinal muscle tissues of patients with ankylosing spondylitis. Int J Rheum Dis 19:420–429. https://doi.org/10.1111/1756-185X.12305
11. Resorlu H, Savas Y, Aylanc N, Gokmen F (2017) Evaluation of paravertebral muscle atrophy and fatty degeneration in ankylosing spondylitis. Mod Rheumatol 27:683–687. https://doi.org/10.1080/14397595.2016.1245176
12. Prasetyo M, Nindita N, Murdana IN, Prihartono J, Setiawan SI (2020) Computed tomography evaluation of fat infiltration ratio of the multifidus muscle in chronic low back pain patients. Eur J Radiol Open 7:100293. https://doi.org/10.1016/j.ejro.2020.100293
13. Ranger TA, Cicuttini FM, Jensen TS, Peiris WL, Hussain SM, Fairley J et al (2017) Are the size and composition of the paraspinal muscles associated with low back pain? A systematic review. Spine J 17:1729–1748. https://doi.org/10.1016/j.spinee.2017.07.002
14. Goubert D, De Pauw R, Meeus M, Willems T, Cagnie B, Schouppe S et al (2017) Lumbar muscle structure and function in chronic versus recurrent low back pain: a cross-sectional study. Spine J 17:1285–1296. https://doi.org/10.1016/j.spinee.2017.04.025
15. Khedr EM, Rashad SM, Hamed SA, El-Zharaa F, Abdalla AKH (2009) Neurological complications of ankylosing spondylitis: neurophysiological assessment. Rheumatol Int 29:1031–1040. https://doi.org/10.1007/s00296-009-0841-7

16. Simmons EH, Graziano GP HRJ (1991) Muscle disease as a cause of kyphotic deformity in ankylosing spondylitis. Spine (Phila Pa 1976) 16:361
17. Yagci I, Gunduz OH, Ekinci G, Diracoglu D, Us O, Akyuz G (2009) The utility of lumbar paraspinal mapping in the diagnosis of lumbar spinal stenosis. Am J Phys Med Rehabil 88:843–851. https://doi.org/10.1097/PHM.0b013e3181b333a9
18. Haig AJ (2002) Paraspinal denervation and the spinal degenerative cascade. Spine J 2:372–380. https://doi.org/10.1016/S1529-9430(02)00201-2
19. Kim DH, Lee SY, Park SJ, Lee YS (2019) Relationships between spinal sarcopenia and spinal sagittal balance in older women. Ann Geriatr Med Res 23:141–148. https://doi.org/10.4235/agmr.19.0030
20. Ozcan-Eksi EE, Yagci I, Erkal H, Demir-Deviren S (2016) Paraspinal muscle denervation and balance impairment in lumbar spinal stenosis. Muscle Nerve 53:422–430. https://doi.org/10.1002/mus.24759
21. James G, Chen X, Diwan A, Hodges PW (2020) Fat infiltration in the multifidus muscle is related to inflammatory cytokine expression in the muscle and epidural adipose tissue in individuals undergoing surgery for intervertebral disc herniation. Eur Spine J. https://doi.org/10.1007/s00586-020-06514-4

Publisher's Note Springer Nature remains neutral with regard to jurisdictional claims in published maps and institutional affiliations.