Gait & Posture 124 (2026) 110063

Contents lists available at ScienceDirect

Gait & Posture

journal homepage: www.elsevier.com/locate/gaitpost

Does transferred medial gastrocnemius flap help with knee extension during gait following proximal tibial endoprosthesis?

Dyuti Deepta Rano [a,1], Love Kapoor [a,b,1], Venkatesan Sampath Kumar [a,*,2], Shamim Ahmed Shamim [c,2], Shah Alam Khan [a,2]

[a] Department of Orthopaedics, All India Institute of Medical Sciences, New Delhi 110029, India
[b] Department of Orthopaedics, National Cancer Institute, Jhajjar, All India Institute of Medical Sciences, New Delhi, India
[c] Department of Nuclear Medicine, All India Institute of Medical Sciences, New Delhi 110029, India

ARTICLE INFO

Keywords:
Gait analysis
Proximal Tibial Endoprosthesis
Medial Gastrocnemius flap

ABSTRACT

Introduction: Patients undergoing proximal tibial endoprosthesis for bone tumors usually have a medial gastrocnemius flap for wound coverage, supposed to help in knee extension instead of normal flexor of the knee.
Objectives: 1. Does medial gastrocnemius flap participates in knee extension during normal gait? 2. What are the gait changes following proximal tibial endoprosthesis?
Materials & methods: This cross-sectional observational study included 52 patients who had proximal tibial endoprosthesis between January 2008 to January 2020 for bone tumours and regained maximum function with independent ambulatory capacity. Instrumented gait analysis was done according to Helen-Hayes protocol with a special surface EMG probe placed over the flap. Tc 99 m three-phase bone scan was used to evaluate flap viability.
Results: Mean age was 27.92 ± 12.88 years and mean follow-up duration was 23.1 ± 4.2 months. Patients walked slower with mean velocity of 0.74 ± 0.23 m/s and mean cadence of 87.9 ± 10.3 steps/min. Mean knee flexion on the operated side was significantly decreased(89.42 ± 14.87° vs 125.38 ± 6.01°, $p < 0.001$). Mean swing time was significantly increased on the operated limb(0.56 ± 0.08 sec vs 0.46 ± 0.07 sec, $p < 0.001$) with consequent increase in mean single support phase on the normal limb(operated vs normal limb, 33.71 ± 5.05 % vs 40.81 ± 4.03 %, $p < 0.001$). Peak knee flexion in swing, total sagittal plane excursion, peak flexion loading response, peak knee extensor moment at early stance and peak ankle plantarflexion moment at stance decreased significantly on operated side. Electrical activity in the knee extensors decreased over the operated side. Bone scan confirmed flap viability in all.
Conclusion: The medial gastrocnemius flap primarily provides successful soft tissue coverage but does not consistently adopt a functional role in knee extension during gait. Patients' walking patterns remain slower and asymmetrical but well compensated post-reconstruction, adopting a stiff-knee gait pattern with features of quadriceps avoidance.

Endoprosthetic reconstruction for proximal tibial tumors presents two unique challenges to the orthopaedic oncologists. Firstly, the surgical resection involves disruption of the extensor mechanism of the knee as the patellar tendon is detached away from its insertion on the tibial tuberosity [1,2]. Secondly, lack of adequate soft tissue for providing coverage to the endoprosthesis can potentially lead to wound necrosis and dehiscence. Various techniques have been described in literature for the reconstruction of the extensor mechanism including direct reattachment of the patellar tendon, pedicled muscle flaps reinforced with autologous bone graft, Dacron tape, circlage wire, mesh technology [3–6], LARS (Ligament Advancement Reinforcement System) [7] and Leeds-Keio artificial ligament [7]. We routinely use a mesh for reattaching the patellar tendon to prosthesis augmented with medial gastrocnemius rotational flap [8].

* Corresponding author.
E-mail addresses: dyutideeptarano@gmail.com (D.D. Rano), lovekapoor871988@rediffmail.com (L. Kapoor), venkatortho4@gmail.com (V.S. Kumar), sashamim2002@gmail.com (S.A. Shamim), shahalamkhan70@gmail.com (S.A. Khan).
[1] The first two authors contributed equally to this manuscript
[2] The last three authors contributed equally to this manuscript

https://doi.org/10.1016/j.gaitpost.2025.110063
Received 24 September 2025; Received in revised form 18 November 2025; Accepted 20 November 2025
Available online 29 November 2025
0966-6362/© 2025 Elsevier B.V. All rights are reserved, including those for text and data mining, AI training, and similar technologies.

The transposed muscle is believed to support the vascularity of the overlying skin flap, obliterate the dead space after tumor resection and serves as a cover for the underlying prosthesis. In addition, it also serves as an attachment for the remnant patellar tendon to re-establish the continuity of the extensor apparatus. The medial head of gastrocnemius is preferred over the lateral counterpart as it is easy to harvest from the anteromedial surgical approach used for wide resection of the tumor, has a more bulky and longer muscular part and also shorter rotational arc, compared to lateral gastrocnemius which has to be rotated over the fibula [9].

The role of gastrocnemius flap in active knee extension has been debatable with some authors advocating that it assists knee extension [10],although this has never been validated. Also, there has been no previous research on the viability of the flap after reconstruction.

The present study was designed for objective assessment of the viability of the medial gastrocnemius and its role in active knee extension in patients with tumors of the proximal tibia endoprosthesis reconstruction. The study was carried out to answer the following research questions:

- Does medial gastrocnemius flap participates in knee extension during normal gait?
- What are the gait changes following proximal tibial endoprosthesis?

1. Materials and methods

The study was conducted after obtaining Institutional Review Board approval. A total of 82 patients who had undergone proximal tibial endoprosthesis reconstruction and medial gastrocnemius muscle flap following resection of malignant/benign locally aggressive bone tumor of the proximal tibia between January 2008 to January 2020 were identified from previous records, among which 10 had lost to follow-up, 8 patients had metastatic disease and 12 had been died during the course. Remaining 52 patients were enrolled in the study and were analysed prospectively for functional outcome, gait analysis and viability of the muscle flap after obtaining written informed consent. Patients not giving informed consent for the study, having recurrent or metastatic disease and patients with known allergy to contrast agents including Tc99 methylene diphosphonate and gadolinium were excluded.

1.1. Surgical technique

The surgical margin with regards to the extent of involvement tibia and surrounding soft tissues, involvement of proximal fibula and tibiofibular joint, and involvement of major nerves and vessels were determined. We performed the surgery under tourniquet, using an anteromedial incision extending from distal 1/3rd of the thigh to the distal 1/3rd of the leg, with the distal extent of the incision varying according to the tumor extent as determined by the imaging, incorporating the biopsy tract in the incision. Medial para-patellar arthrotomy was done followed by intra-articular resection. The cruciate ligaments were released near the femoral insertion and patellar tendon was resected close to the tibial insertion while respecting oncological margins. Careful dissection of the popliteal vessels was performed posteromedially by releasing the pes anserinus and semimembranosus tendon, mobilizing the medial gastrocnemius muscle and detaching the soleus muscle from the tibia, The anterior tibial artery was ligated wherever necessary to mobilise the neurovascular bundle. Wide excision of tumor was performed as usual respecting the oncological margin. The entire Medial gastrocnemius flap was harvested from its origin to the musculotendinous junction. The size of the flap varied depending upon the height and nutritional status of the patient. However, the graft size measurement was not included in the study variable. The medial gastrocnemius was separated from the soleus muscle and freed superficially and deep with minimal blunt dissection. The medial sural cutaneous nerve, a branch of the tibial nerve, that exits the popliteal fossa between these two heads was used as an anatomic reference point to identify the midline superficially. The median raphe was identified by carefully inspecting the different orientation of the fascia fibers and was released longitudinally with electrocautery, beginning at the proximal muscle belly and carried down to the level of the insertion distally. Keeping the origin intact, the flap was then released distally from the underlying soleus fascia where the gastrocnemius and soleus become confluent at the proximal edge of the Achilles tendon. Flap was wrapped in saline-soaked sponge to prevent desiccation.

Proximal tibial defect was reconstructed using single axis hinged cemented proximal tibial endoprosthesis (Restor Smith & Nephew) with non-rotatory platform after preparation of femur and tibia. In the prosthetic design which was employed in this study, the medial part of medial femoral condyle and lateral part of lateral femoral condyle were preserved as femoral component inserts into a box-cut around the intercondylar notch. Hence, these landmarks were utilized for the placement of markers. Reconstruction of the extensor mechanism was performed using Prolene mesh (Ethicon, Johnson & Johnson). Finally, the medial gastrocnemius flap was rotated anteriorly to cover the prosthesis and the mesh, and the implant was covered with the preserved muscles and soft tissues (Fig. 1). Care was to taken to ensure that the mesh is completely covered by biological tissue (flap and muscle).

This repair was protected using an above knee POP slab for 6 weeks, followed by gradual passive and active ROM exercises, quadriceps strengthening and partial weight bearing walking using walker and sticks, progressing to gradual full weight bearing unassisted walking under physiotherapist guidance.

All patients underwent Gait analysis in the high configuration, 3D Gait analysis lab equipped with BTS, Italy motion analysis system equipped with high resolution and high frequency (500 Hz) Infrared (IR) cameras (12 no.) for recording kinematic gait variables, force plates (8 no.) for kinetic analysis, wireless surface electromyograph (EMG) probes (16 no.) for recording muscle activity and video cameras (4 no.) for real time video analysis. Helen Hayes protocol was used for reflective markers and surface EMGs placement with a separate EMG electrode placed on the transferred Gastrocnemius medialis on the operated side at its expected location (Fig. 2). 18 reflective markers including 3 on trunk (Cervical 7, Rt and Lt acromion), 3 on pelvis (sacrum 2, Rt and Lt ASIS), 4 on thigh (Rt and Lt thigh in line with great trochanter, Rt and Lt lateral femoral condyle), 4 on shank (Rt and Lt malleolus, Rt and Lt shank), and 4 on foot (one on Rt and one on Lt in between 2nd and 3rd metatarsal, Rt and Lt heel) were placed according to the protocol in their expected anatomical locations as landmarks for markers placement were not altered by the surgery.

Viability of medial gastrocnemius flap was assessed by blood flow and blood pool imaging as a part of 3 phase bone scan. Blood flow images were obtained in 64×64 or greater matrix. Blood pool images were obtained in a 128×128 or greater matrix and with a count density of approximately 300000 counts per image. Functional outcome was assessed using Musculoskeletal Tumor Society 93 (MSTS 93) scoring system. Oncological outcomes with respect to local recurrences and distant metastases were recorded.

1.2. Statistical analysis

Data was managed on an excel spreadsheet and analysed. Categorical variables were analysed using Chi-square test. For continuous variables, normality of data distribution was assessed using Shapiro-Wilk test. The Student's *t*-test and the sign test was used to assess significance for normal and non-normal variables respectively. All the observations were considered to be significant when p-value was < 0.05. All analysis was performed using SPSS Version 20.0 (SPSS, Armonk, NY) and STATA version 15 (Texas, College Station).

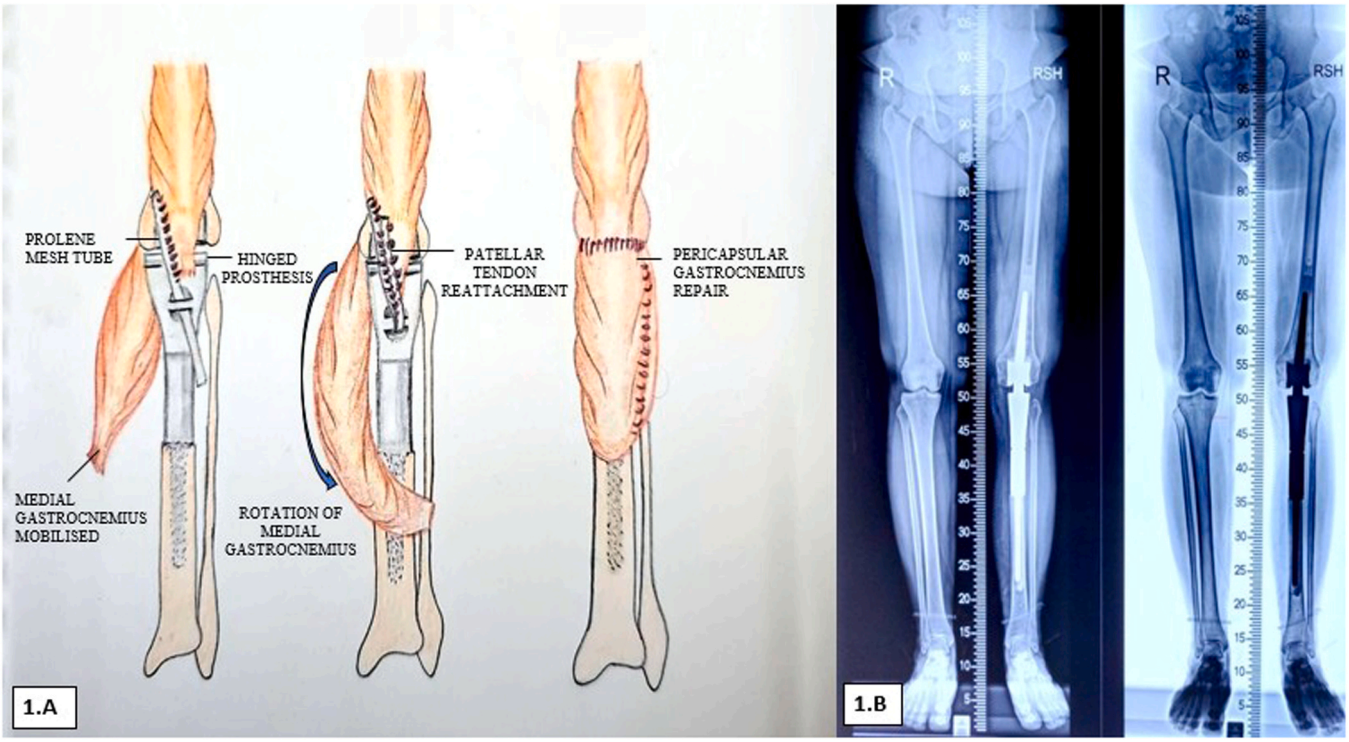

Fig. 1. A-B: Figures showing steps of Medial Gastrocnemius flap creation and transposition over hinged proximal tibial endoprosthesis. **1.A**: Harvesting medial gastrocnemius flap and attachment of prolene mesh loop to the remaining patellar tendon followed by looping of mesh tube through the slot proximally. After suturing of the loop with medial parapatellar tissue proximally, Medial gastrocnemius flap rotated anteriorly to cover the prosthesis and sutured to the remaining soft tissue. **1.B:** Scannogram of an operated case of left proximal tibial osteosarcoma reconstructed with proximal tibial endoprosthesis and medial gastrocnemius flap.

Fig. 2. Reflective markers and EMG probes placement on patient for Gait assessment according to Helen Hayes protocol with an EMG probe placed over left Medial Gastrocnemius flap in an operated case of left proximal tibial endoprosthesis.

2. Results

2.1. Participants demographics

52 participants were enrolled which included 31 males and 21 females, with a mean age of 27.92 ± 12.88 years. The mean follow-up in the study was 23.1 ± 4.2 months (range 13–144 months). Osteosarcoma was the most common tumor seen in 44 % (n = 23) of the patients, followed by Giant cell tumor in 42 % (n = 22), Ewing's sarcoma in 8 % (n = 4), Chondrosarcoma in 4 % (n = 2) of the cases and 1 case (2 %) of malignant mesenchymal tumor. The mean resection length was found to be 14.33 ± 2.07 cm (range 9–20 cm). Weight, height and BMI of our study population are 56.06 ± 9.4 kgs, 1.61 ± 0.08 m and 21.59 ± 3.62 kg/m^2 respectively.

2.2. Gait parameters

2.2.1. Spatial-temporal parameters

All participants walked independently without any assistive devices. Mean velocity(0.74 ± 0.23 m/s, range 0.3–1.3 m/s) and cadence(87.9 ± 10.3 steps/min. range 53.4–108 steps/min) have been decreased in the cohort [11,12]. Mean step width has been increased(0.09 ± 0.04 m). Non-dimensional normalized velocity and cadence are 0.277 ± 0.087 and 23.9 ± 2.72, respectively as suggested by At L. Hof [13]

Comparison of spatial-temporal parameters between operated and non-operated limb is shown in Table1. On applying Student's *t*-test, swing phase was noted to be significantly longer in the operated limb with a significantly shortened stance phase. Single support phase was significantly shorter on the operated side while no significant difference was noted in the double support phase. Also, Gait Deviation Index was significantly better on the non-operated side.

2.2.2. Kinematic and kinetic parameters

Peak hip flexion at stance, peak knee flexion in swing phase, total sagittal plane excursion, knee initial contact angle and maximum flexion loading response angle knee on the operated side were significantly lower than non-operated side, whether maximum plantarflexion at initial stance was significantly higher on the operated side. Peak knee extensor moment at early stance and peak ankle plantarflexion moment at stance both were significantly decreased on the operated limb. These kinematic and kinetic parameters were tabulated in Table 2 and depicted in Fig. 3. For normal and non-normal parameters, Student's *t*-test and the Sign test were applied respectively.

2.2.3. Electromyographic study

Electromyographic study could be performed on 47 patients only. The transferred flap fired with decreased amplitude throughout the gait cycle. Electrical activity of the key muscles involved in knee flexion-extension has been tabulated below in Table 3. Rectus femoris activity on the operated side had been significantly lower during stance phase compared to normal limb. Muscle activity in rest of the muscles were similar during stance and swing phase between the limbs.

Table 1
Comparison of spatial-temporal parameters between operated and non-operated limb.

Variables	Operated limb	Non- operated limb	p value
Step length (m)	0.52 ± 0.11	0.47 ± 0.13	0.0326
Normalized step length	0.72 ± 0.16	0.65 ± 0.18	0.033
Stride length (m)	1.0 ± 0.24	1.0 ± 0.23	0.99
Swing phase (s)	0.56 ± 0.08	0.46 ± 0.07	< 0.001
Swing phase percentage (%)	40.74 ± 3.94	33.17 ± 5.57	< 0.001
Stance phase (s)	0.83 ± 0.15	0.94 ± 0.21	0.0027
Stance phase percentage (%)	59.11 ± 4.63	66.19 ± 6.42	< 0.001
Single support phase (%)	33.71 ± 5.05	40.81 ± 4.03	< 0.001
Double support phase (%)	13.22 ± 5.99	12.76 ± 3.25	0.6291
Gait Deviation Index (normal >100)	86.58 ± 8.06	89.8 ± 8.42	0.0485

Table 2
Comparison of kinematic and kinetic parameters between operated and non-operated limb.

Variable	Operated limb	Non-operated limb	P value	
Kinematic parameters				**Normal values***
Peak hip flexion in stance	29.2 ± 10.6°	32.4 ± 12.9°	< 0.001	39.11 ± 7.62°
Peak hip extension in stance	Median −2.5° (range −29.8° to 16.9°)	Median −5.4° (range −24.2° to 11.9°)	0.3151	8.78 ± 7.88°
Pelvic tilt in midstance	Median 11.4° (range −9.7° to 23.8°)	Median 14° (range −5.4° to 28.4°)	0.6212	11.62 ± 6.52°
Peak knee extension in stance	Median 0.5° (range −13.2° to 20.3°)	Median 3.1° (range −7° to 14.1°)	0.0809	3.26 ± 4.59°
Peak knee flexion in swing phase	49.2 ± 11.6°	58.77 ± 8.12°	< 0.001	62.76 ± 3.94°
Total sagittal plane excursion knee	48.5 ± 13.94°	56.03 ± 8.84°	0.0014	
Knee initial contact angle	Median 1.1° (range −12.6° to 20.3°)	Median 7.4° (range −3.9° to 18.1°)	< 0.001	6.99 ± 3.96°
Maximum plantarflexion at initial stance	-8.5 ± 4.2°	-3.1 ± 1.3°	< 0.001	-3.74 ± 3.12°
Maximus dorsiflexion at stance	15.2 ± 4.9°	15.3 ± 3.4°	0.972	21.08 ± 3.38°
Maximum flexion loading response knee	Median 6.6° (range −11.4° to 30.1°)	Median 16.9° (range −0.1° to 29.1°)	< 0.001	20.05 ± 6.61°
Kinetic parameters				
Peak Knee extension moment at early stance(N.m/kg)	0.307 ± 0.149	0.497 ± 0.165	0.0148	
Peak ankle plantarflexion moment at stance (N.m/kg)	0.906 ± 0.361	1.222 ± 0.353	0.0435	

(*Normal values suggested by DSF de Campos depending upon age in healthy individuals [14])

2.2.4. Viability of Medial Gastrocnemius flap

In three-phase bone scan, the medial gastrocnemius flap showed preserved tracer uptake in all the patients.

2.2.5. Functional outcomes

The mean flexion range of motion was 89.42 ± 14.87 ° (Range 80 – 110^0) on the operated side while it was 125.38 ± 6.01 ° (Range 70 – 140^0). Mean extension lag was 6.33 ± 1.87 °. 32 patients had full active extension whereas 9 patients had extension lag more than 10^0 (maximum extension lag being 20^0). Good to excellent functional outcome was observed in our patients with mean MSTS93 score of 27.5 ± 2.51 (range 22–30) at the latest follow-up.

3. Discussion

Adequate soft tissue coverage provided by interposition of medial gastrocnemius following proximal tibial endoprosthetic reconstruction is an absolute necessity to prevent deep-seated infections [15,16]. While there is wide variation in literature with regards to the preferred choice of extensor mechanism reattachment, most surgeons now agree that a medial gastrocnemius flap is an absolute necessity to cover the prosthesis and reinforce the extensor mechanism. In 1983, at the second International Symposium on Limb Salvage (ISOLS) meeting in Vienna,

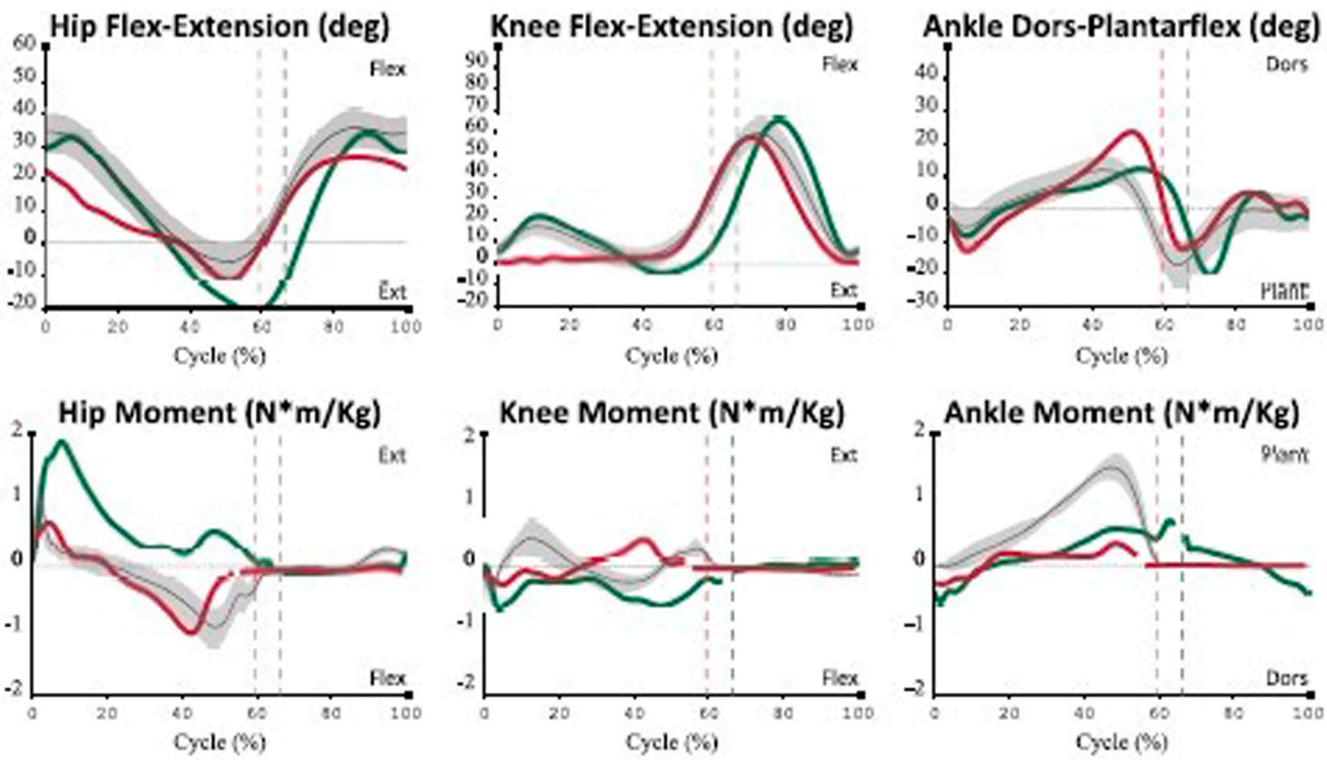

Fig. 3. Figure showing kinematic and kinetic changes for hip, knee and pelvis in operated case of left proximal tibial endoprosthesis. Graphs depicted in red for the left which is the operated limb and green lines denoted the right or the non-operated limb.

Table 3
Comparison of peak electrical activity in key muscle groups during stance and swing phase.

Muscle(Group)	Operated limb	Non-operated limb	p-value
Stance phase(Peak electrical activity)			
Rectus Femoris(mV)	0.028 ± 0.015	0.078 ± 0.034	0.032
Vastus Lateralis(mV)	0.112 ± 0.1	0.113 ± 0.076	0.992
Medial Hamstrings(mV)	0.217 ± 0.084	0.144 ± 0.079	0.427
Lateral Hamstrings(mV)	0.156 ± 0.165	0.136 ± 0.121	0.815
Swing phase(Peak electrical activity)			
Rectus Femoris(mV)	0.03 ± 0.019	0.063 ± 0.085	0.255
Vastus Lateralis(mV)	0.078 ± 0.042	0.095 ± 0.035	0.652
Medial Hamstrings(mV)	0.104 ± 0.099	0.058 ± 0.019	0.641
Lateral Hamstrings(mV)	0.137 ± 0.055	0.121 ± 0.047	0.809

Austria, Jean Dubousset first reported his results using a medial gastrocnemius rotational flap as a means of obtaining soft tissue coverage over proximal tibial endoprosthesis [17]. Later, Buchner et al. reported the midterm results of 25 patients who underwent proximal tibial resections with endoprosthetic reconstruction combined with a medial gastrocnemius flap where 24 out of 25 flaps survived without any complication and provided protection against infection [9]. Some authors believe that this transferred muscle participates in active knee extension [18]. However, there is no study available in the literature which has studied the contribution of medial gastrocnemius flap in knee extension.

Gait abnormalities or better to be called as gait compensation, after major soft and bone resection in case of lower limb salvage surgery were first described by Simon et al. [19]. In our study, patients with proximal tibial endoprosthesis walked slower as compared to the normal gait parameters [20,21]. The slower velocity of the affected limb is likely due to muscle weakness after wide resection, or it might be compensatory measure to reduce energy expenditure [19,22]. Mean step width had been increased, probably in order to avoid imbalance while walking or subsequent to decreased proprioception resulting from loss of intra-articular structures [21,23]. Both swing time and swing phase percentage significantly increased on the salvaged limb with contralateral increase in the stance phase, stance time and single limb support phase [21]. In line with the available literature, these findings suggested attempts to increase stability and shift the weight off the affected lower limb as quickly as possible [21,24]. Gait Deviation Index, a subjective measurement of overall gait characteristics, was worse on the affected side. In acceptance of previous studies, our study population had shown less flexion at initial contact, significantly decreased knee flexion angle during loading response and significant plantar flexion at ankle during heel strike on the operated side in comparison to the non-operated one. This pattern of reduced flexion has been termed 'stiff-legged gait' [2,3] and has been attributed to a number of factors including proprioceptive impairment, avoidance of shear forces, disruption of the mechanical advantage mechanism (i.e. patella and patellar tendon), instability, pain and/or habit [25–27]. Also, peak knee extensor moment at stance and peak ankle plantarflexion at stance had been decreased on the operated side owing to quadriceps and ankle plantarflexion weakness, which prevented the movement of the ground reaction force vector posterior to knee joint [28]. All these gait abnormalities reflect weakness and compensatory, but somehow protective mechanisms. Full knee extension could provide the mechanical advantage in the form of stability during loading response, as this position was associated with a greater amount of passive stability due to the anterior position of the Ground Reaction Force (GRF) vector to the knee. However, the loss of knee flexion during stance phase has detrimental effect on the survival of the endoprosthesis. Knee flexion during stance phase is important for shock absorption as it reduces the direct force transmission from the femur to tibia during walking [29]. There were no significant differences between the two limbs in terms of peak hip extension in stance, peak knee extension in stance and pelvic tilt in midstance. So, from the above-mentioned findings we could conclude that the unaffected limb had decompensated to compensate the affected limb to provide a

symmetrical and more physiological gait with minimum energy expenditure during walking.

After analyzing the kinematic abnormalities at the level of hip, knee and ankle, the most common kinematic abnormalities found were reduced peak knee flexion in swing and peak knee extension at stance. Both of these abnormalities are likely related to the stiffness of the knee joint after surgery. At ankle, there is concomitant reduction in peak dorsiflexion at stance and increase in peak plantarflexion during initial stance which may be due to slow speed. There is either decreased or absent 3rd rocker in most of our patients. Almost every parameter of gait we have studied could be affected by walking speed as suggested by Schwartz et al. [30]. However, our study findings suggested that the changes noted are primarily due to the surgical procedure and prosthetic reconstruction because these changes were not noticeable in the contralateral non-surgical limb.

There was no study conducted till date which had evaluated the role of transferred medial gastrocnemius flap in knee extension after proximal tibial endoprosthetic reconstruction. The transferred flap fired with decreased amplitude throughout the gait cycle in all participants, suggesting that it was unable to generate same power as it was generating before. In all our patients, the medial gastrocnemius flap had shown preserved tracer uptake in three-phase bone scan, confirming that it provides a viable soft tissue cover for the prosthesis. Furthermore, on EMG analysis, we found that the quadriceps, especially rectus femoris showed less muscle activity on the affected limb, but hamstrings showed greater activity in both phases of gait cycle on the operated side. Decreased knee extension moment along with greater hamstring muscle activity is consistent with the so-called Quadriceps avoidance gait [31, 32]. Along with this, the other findings of the present study suggest that the transferred medial gastrocnemius flap does not participate in active knee extension.

With regards to the functional outcomes, our results are comparable with the previous reports. Dominkus et al. [7] reported the use of LARS (Ligament Advancement Reinforcement System), a nonresorbable polyester band, for reconstruction of extensor mechanism after proximal tibia tumor resection, and the mean of extension lag reported was 25° (range; 0–90°. A reattachment tube (Implantcast) around the prosthesis was used for extensor mechanism reconstruction with non-absorbable sutures and gastrocnemius flap by Hardes et al. [13]. They found that extension deficit in 25 % of their patients. Ichikawa et al. [4] used a complex surgical technique for extensor mechanism reconstruction which included the attachment of mesh to the tibial component using a plate and screws, with a band of meshes passed through bone tunnels in the patella and looped over it, along with a gastrocnemius flap for coverage in a small series of 9 patients undergoing proximal tibia ER and reported a mean extension lag of 50 and active flexion of 96.250, with infection occurring in only 1 patient.

We reported a good functional outcome (mean MSTS93 27.5) with a mean flexion of 89.42 ° on the operated side and a mean extension lag of 6.33 ± 1.87 ° with majority of patients having full active extension. The mean range of flexion was significantly lower on the operated side, which is consistent with the results of previous studies [9,15]. Since there are no mechanical constraints related to the prosthesis hindering range of motion of the operated knee, extent of soft tissue resection including hamstrings, which are the chief knee flexors around the knee, and intraoperative pre-tensioning of the prolene mesh tube might have affected post operative range of flexion. Like many previous studies, our study proved that endoprosthetic reconstruction with medial gastrocnemius flap in proximal tibial bone tumors is an effective mode of limb salvage.

The present study is unique as this is the first study in South-East Asian population evaluating functional outcomes in patients undergone proximal tibial endoprosthesis for bone tumors with gait deviations and compensations evaluated by means of instrumented Gait analysis. Also, we had evaluated a new way of reconstructing extensor mechanism by Prolene mesh tube and its implications and outcomes. Lastly, our study proved, the transferred medial gastrocnemius flap doesn't assist in knee extension during gait cycle.

However, we acknowledge that our study results are limited by the small patient population and measurement of variables at follow-up only with no measurement of gait parameters pre-operatively. Also, the results of the study were obtained from short to intermediate follow-ups only. Multi-site studies with larger sample sizes are needed to validate these results strongly.

4. Conclusion

In summary, the medial gastrocnemius flap used in proximal tibial endoprosthetic reconstructions primarily provides soft tissue coverage with very little participation in knee extension during gait. Compared to normal limb, our study subjects had prolonged swing phase in the operated limb with consequent increased single limb support in the contralateral limb which were not abnormalities of the operated limb but might be compensatory and protective changes adapted during gait to reduce stress on the salvaged limb and extensor mechanism and to conserve energy during walking. There was significant decrease in maximum flexion loading response, total sagittal plane excursion and extension moment in operated limb to keep GRF vector in front of knee and to use quadriceps mechanism efficiently.

CRediT authorship contribution statement

Shah Alam Khan: Writing – review & editing, Validation, Formal analysis, Conceptualization. **Love Kapoor:** Methodology, Investigation, Conceptualization. **Shamim Ahmed Shamim:** Writing – review & editing, Visualization, Conceptualization. **Venkatesan Sampath Kumar:** Writing – review & editing, Supervision, Data curation, Conceptualization. **Dyuti Deepta Rano:** Writing – original draft, Investigation, Data curation.

Declaration of Competing Interest

The authors declare that they have no known competing financial interests or personal relationships that could have appeared to influence the work reported in this paper.

Appendix A. Supporting information

Supplementary data associated with this article can be found in the online version at doi:10.1016/j.gaitpost.2025.110063.

References

[1] M.M. Malawer, K.A. McHale, Limb-sparing surgery for high-grade malignant tumors of the proximal tibia. Surgical technique and a method of extensor mechanism reconstruction, Clin. Orthop. Relat. Res. 239 (1989 Feb 1) 231–248.
[2] S.M. Horowitz, J.M. Lane, J.C. Otis, J.H. Healey, Prosthetic arthroplasty of the knee after resection of a sarcoma in the proximal end of the tibia. A report of sixteen cases, J. Bone Jt. Surg. Am. 73 (2) (1991 Feb 1) 286–293.
[3] B.M. Holzapfel, H. Rechl, S. Lehner, H. Pilge, H. Gollwitzer, E. Steinhauser, Alloplastic reconstruction of the extensor mechanism after resection of Tibial Sarcoma, Sarcoma (2011 Apr 11). ⟨https://www.hindawi.com/journals/sarcoma/2011/545104/⟩ [cited 2022 May 21];2011:e545104. Available from.
[4] J. Bickels, J.C. Wittig, Y. Kollender, R.S. Neff, K. Kellar-Graney, I. Meller, et al., Reconstruction of the extensor mechanism after proximal tibia endoprosthetic replacement, J. Arthroplast. 16 (7) (2001 Oct 1) 856–862. ⟨https://www.sciencedirect.com/science/article/pii/S0883540301527503⟩ (Available from).
[5] B. Liu, J.C. Tan, H.L. Wang, Z. Wu, Z.C. Yuan, C.Y. Wei, The role of mesh technology with tumor prosthesis reconstruction to reconstruct the extensor mechanism of knee joint after resection of proximal tibial tumors, J. Orthop. Surg. Res. 14 (1) (2019 Feb 26) 64, https://doi.org/10.1186/s13018-019-1105-1.
[6] J.J. Eckardt, J.G. Matthews, F.R. Eilber, Endoprosthetic reconstruction after bone tumor resections of the proximal tibia, Orthop. Clin. North Am. 22 (1) (1991 Jan 1) 149–160.
[7] K. Fujikawa, T. Ohtani, H. Matsumoto, B. Seedhom, Reconstruction of the extensor apparatus of the knee with the Leeds-Keio ligament, J. Bone Jt. Surg. Br. Vol. 76-B (2) (1994 Mar) 200–203. Available from: ⟨https://online.boneandjoint.org.uk/doi/abs/10.1302/0301-620X.76B2.8113276⟩.

[8] L. Kapoor, R. Banjara, S.A. Khan, A. Majeed, Extensor apparatus reconstruction using prolene mesh tube and medial gastrocnemius flap following proximal tibial endoprosthetic reconstruction, Tech. Orthop. 37 (1) (2022 Mar) 65–69. Available from: ⟨https://journals.lww.com/techortho/Fulltext/2022/03000/Extensor_Apparatus_Reconstruction_Using_Prolene.13.aspx?context=FeaturedArticles&collectionId=3⟩.
[9] Medial Gastrocnemius Muscle Flap in Limb-Sparing Surgery of…: Annals of Plastic Surgery [Internet]. [cited 2022 May 21]. Available from: ⟨https://journals.lww.com/annalsplasticsurgery/Abstract/2003/09000/Medial_Gastrocnemius_Muscle_Flap_in_Limb_Sparing.7.aspx⟩.
[10] C.A. Cipriano, J. Dalton, D.J. McDonald, Does Patellar tendon repair with gastrocnemius flap augmentation effectively restore active extension after proximal tibial sarcoma resection? Clin. Orthop. Relat. Res. 477 (3) (2019 Mar) 584–593. Available from: ⟨https://journals.lww.com/00003086-201903000-00021⟩.
[11] L. Mobbs, V. Fernando, R.D. Fonseka, P. Natarajan, M. Maharaj, R.J. Mobbs, Normative database of spatiotemporal gait metrics across age groups: an observational case–control study, Sensors 25 (2) (2025 Jan 20) 581. Available from: ⟨https://pmc.ncbi.nlm.nih.gov/articles/PMC11768510/⟩.
[12] M.W. Whittle, Gait Analysis: An Introduction, Butterworth-Heinemann, 2014, p. 241.
[13] Hof A.L. Scaling gait data to body size. Gait & Posture [Internet]. 1996 May 1 [cited 2025 Oct 23];4(3):222–223. Available from: ⟨https://www.sciencedirect.com/science/article/pii/0966636295010572⟩.
[14] S.F. de Campos D da, S. Shokur, A.C. de Lima-Pardini, M. Runfeng, M. Bouri, D. B. Coelho, Kinematics predictors of spatiotemporal parameters during gait differ by age in healthy individuals, Gait Posture 96 (2022 July) 216–220.
[15] Endoprosthetic replacement of the proximal tibia | The Bone & Joint Journal [Internet]. [cited 2022 May 21]. Available from: ⟨https://online.boneandjoint.org.uk/doi/abs/10.1302/0301-620x.81b3.0810488⟩.
[16] S.E. Puchner, P. Kutscha-Lissberg, A. Kaider, J. Panotopoulos, R. Puchner, C. Böhler, et al., Outcome after reconstruction of the Proximal Tibia – complications and competing risk analysis, PLoS One 10 (8) (2015 Aug 13) e0135736. Available from: ⟨https://www.ncbi.nlm.nih.gov/pmc/articles/PMC4535855/⟩.
[17] Dubousset J., Missenard G., Kalifa C. Management of Osteogenic Sarcoma in Children and Adolescents. Clinical Orthopaedics and Related Research® [Internet]. 1991 Sept [cited 2022 May 25];270:52–9. Available from: ⟨https://journals.lww.com/clinorthop/Abstract/1991/09000/Management_of_Osteogenic_Sarcoma_in_Children_and.9.aspx⟩.
[18] J. Dalton, C. Cipriano, D. Mcdonald, Patellar tendon repair with gastrocnemius flap augmentation effectively restores active extension following proximal tibial sarcoma resection, Clin. Orthop. Relat. Res. 477 (2018 Oct 7).
[19] M.A. Simon, Limb Salvage for Osteosarcoma, in: J.R. Ryan, L.O. Baker (Eds.), Recent Concepts in Sarcoma Treatment: Proceedings of the International Symposium on Sarcomas, Tarpon Springs, Florida, October 8–10, 1987 [Internet, Springer Netherlands, Dordrecht, 1988, pp. 239–240, https://doi.org/10.1007/978-94-009-2691-2_37.
[20] M.W. Whittle, Gait Analysis: An Introduction, Butterworth-Heinemann, 2014, p. 241.
[21] J.C. Rompen, S.J. Ham, J.P.K. Halbertsma, J.R.V. Horn, Gait and function in patients with a femoral endoprosthesis after tumor resection, Acta Orthop. Scand. 73 (4) (2002 Jan 1) 439–446, https://doi.org/10.1080/00016470216319.
[22] J.C. Otis, J.M. Lane, M.A. Kroll, Energy cost during gait in osteosarcoma patients after resection and knee replacement and after above-the-knee amputation, J. Bone Jt. Surg. Am. 67 (4) (1985 Apr) 606–611.
[23] De Visser E., Mulder T., Schreuder H.W.B., Veth R.P.H., Duysens J. Gait and electromyographic analysis of patients recovering after limb-saving surgery. Clinical Biomechanics [Internet]. 2000 Oct 1 [cited 2022 June 19];15(8):592–599. Available from: ⟨https://www.sciencedirect.com/science/article/pii/S0268003300000218⟩.
[24] M.G. Benedetti, F. Catani, D. Donati, L. Simoncini, S. Giannini, Muscle performance about the knee joint in patients who had distal femoral replacement after resection of a bone tumor: an objective study with use of gait analysis*, JBJS 82 (11) (2000 Nov) 1619. Available from: ⟨https://journals.lww.com/jbjsjournal/Abstract/2000/11000/Muscle_Performance_About_the_Knee_Joint_in.16.aspx⟩.
[25] Benedetti M.G., Catani F., Bilotta T.W., Marcacci M., Mariani E., Giannini S. Muscle Activation Pattern and Gait Biomechanics after Total Knee Replacement. Clinical Biomechanics [Internet]. 2003 Nov 1 [cited 2022 June 19];18(9):871–876. Available from: ⟨https://www.sciencedirect.com/science/article/pii/S0268003303001463⟩.
[26] T.P. Andriacchi, Functional analysis of pre and post-knee surgery: total knee arthroplasty and ACL reconstruction, J. Biomech. Eng. 115 (4B) (1993 Nov 1) 575–581, https://doi.org/10.1115/1.2895543.
[27] L.D. Dorr, J.L. Ochsner, J. Gronley, J. Perry, Functional comparison of posterior cruciate-retained versus cruciate-sacrificed total knee arthroplasty, Clin. Orthop. Relat. Res. 236 (1988 Nov 1) 36–43.
[28] E.G. Fowler, J.J. Eckardt, A. Vuong, M.B. Greenberg, K. Yamaguchi, S.V. Bukata, et al., Gait outcomes following proximal tibial tumor resection and endoprosthetic reconstruction, Gait Posture 88 (2021 July) 167–173.
[29] E. de Visser, J. Pauwels, J.E. Duysens, T. Mulder, R.P. Veth, Gait adaptations during walking under visual and cognitive constraints: a study of patients recovering from limb-saving surgery of the lower limb, Am. J. Phys. Med. Rehabil. 77 (6) (1998 Dec) 503–509.
[30] M.H. Schwartz, A. Rozumalski, J.P. Trost, The effect of walking speed on the gait of typically developing children, J. Biomech. 41 (8) (2008) 1639–1650.
[31] P. Bulgheroni, M.V. Bulgheroni, L. Andrini, P. Guffanti, A. Giughello, Gait patterns after anterior cruciate ligament reconstruction, Knee Surg. Sports Traumatol. Arthrosc. 5 (1) (1997) 14–21.
[32] C.S. Roberts, G.S. Rash, J.T. Honaker, M.P. Wachowiak, J.C. Shaw, A deficient anterior cruciate ligament does not lead to quadriceps avoidance gait, Gait Posture 10 (3) (1999 Dec) 189–199.