Facial F wave recording: A novel and effective technique for extra- and intraoperative diagnosis of facial nerve function in acoustic tumor disease

CHRISTOPH WEDEKIND, MD, and NORFRID KLUG, MD, Cologne, Germany

OBJECTIVE: **To investigate the diagnostic yield of facial F wave recording in patients with acoustic neurinomas intraoperatively and extraoperatively.**
STUDY DESIGN AND SETTING: **Prospective study, comparative evaluation of facial F waves, transcranial magnetic stimulation of the facial motor cortex, blink reflex, and intraoperative online electromyographic activity. The study was performed in the neurosurgical department of a university hospital.**
RESULTS: **Extraoperatively, only F wave latencies were closely correlated to tumor diameter as an independent variable. Intraoperatively, loss of F waves was specific for the development of a severe to total facial paresis postoperatively. A transient loss of F waves heralds an imminent danger of severe facial dysfunction.**
CONCLUSION: **Facial F wave recording provides valuable information on the functional status of the nerve intra- and extraoperatively.**
SIGNIFICANCE: **Facial F wave recording should be used as a standard electrodiagnostic technique in addition to transcranial magnetic stimulation and blink reflex recording. It seems particularly useful for intraoperative facial nerve monitoring.** (Otolaryngol Head Neck Surg 2003;129:114-20.)

Two methods are currently used for intraoperative monitoring of facial nerve function: First, online electromyographic (EMG) recording obtained from the facial muscles (usually orbicularis oculi and oris muscles) has been introduced in the mid-eighties by Prass and Lueders.[1] This technique has been credited by some authors[1-3] to provide information on the nerves current strain as tumor dissection proceeds as well as on the functional status of the nerve to be expected after surgery has been completed. Others,[4,5] however, deny any valid prognostic bearing of online EMG changes intraoperatively. Second, intraoperative electrical stimulation of the facial nerve by the surgeon has been performed for years.[5-7] This method has unequivocally turned out to provide significant prognostic information on the postoperative facial nerve outcome, especially the ratios of compound muscle action potential amplitudes obtained consequent to stimulation at the root exit zone and at the internal acoustic meatus are well correlated with the functional status after surgery. Unfortunately, electrostimulation can only be performed when dissection is interrupted. There is no information available as long as surgery is continued. Damage to the nerve, however, occurs during tumor dissection and, thus, may develop unrecognized to an irreversible extent.

Facial F wave monitoring was established to overcome the obstacles inherited by both methods. It provides continuous and valid real-time information concerning the functional status of the nerve under the strain of dissection. In addition, it allows a reliable prognosis on facial nerve function postoperatively. As a further advantage, F wave recording can be used extraoperatively for facial nerve testing. This report is dedicated to illustrating the perioperative and intraoperative application of facial F wave recording in acoustic tumor disease.

MATERIALS AND METHODS

Patients

A total of 35 patients (mean age, 55.9 years) harboring acoustic neurinomas (diameter, 5 to 50 mm; mean, 29.1 mm) were studied extraoperatively. This investigation as well as the intraoperative measurements were carried out after obtaining informed consent and according to the guidelines of the local ethic's committee. Facial nerve function was assessed clinically by means of

From the Department of Neurosurgery, University of Cologne, Cologne, Germany.
Reprint requests: PD Dr Chr Wedekind, Department of Neurosurgery, University of Cologne, 50924 Cologne, Germany; e-mail, DrChrWedekind@web.de.
Copyright © 2003 by the American Academy of Otolaryngology–Head and Neck Surgery Foundation, Inc.
0194-5998/2003/$30.00 + 0
doi:10.1016/S1094-5998(03)00475-3

the House-Brackmann (HB) scale.[8] Facial function was normal (HB °I) in all cases.

A total of 32 patients (mean age, 54.5 years) underwent surgery. Mean tumor diameter was 27.6 mm (range, 5 to 50 mm). For tumor surgery, anesthesia was induced and maintained by application of midazolam and fentanyl and a single dose of a short-acting muscle relaxant (norcuronium). No additional muscle relaxants were given during the operation. Surgery was carried out in the semi-sitting position via a suboccipital retrosigmoid approach in 30 patients. Two patients with small intrameatal tumors were operated on via a subtemporal approach. For outcome analysis, we refer to the House-Brackmann index obtained on the first day after surgery. In 22 patients, a second assessment of facial nerve function took place 3 months after surgery. With respect to the outcome, patients were gathered into 3 groups: good (HB °I and °II), moderate (HB °III and °IV) and poor (HB °V and °VI) outcome.

Nasal Muscle F Wave Recordings

The technique of nasal muscle F-wave recording is described in detail elsewhere.[9-11] For recording of muscle activity, silver chloride cup electrodes filled with conducting gel were placed on both alae nasi to record the compound action potential of the pars alaris of the nasal muscle. These active electrodes were referenced to an electrode on the nose tip or the glabella. The facial nerve was stimulated with constant current rectangular monophasic pulses (duration, 0.2 ms) transmitted transcutaneously (for extraoperative studies) or by subdermal needle electrodes (for intraoperative measurements). The cathode was placed in proximal position over the zygomatic branch of the facial nerve. Its position was adjusted until direct supramaximal activation could be achieved with minimum stimulus intensity (usually 3 to 5 mA). Stimulation frequency was 1 Hz. F waves were obtained directly without the need for signal averaging. Recordings were passed through a preamplifier and amplifier (100 μ/div) and then filtered (bandpass 20 to 3000 Hz). All recordings were stored on a floppy disk for off-line analysis. The minimum F-wave latency out of a total of 16 recordings was used for further statistical analysis. Amplitudes were not assessed since they show a wide variance interindividually.[9] Intraoperatively, F-wave recordings were obtained every 2 to 3 minutes for a period of 1 minute, corresponding to 60 electrical stimuli. The interval was dedicated to online EMG recording. Intraoperative F-wave findings were grouped into 3 categories[11]: (1) stable F waves (best case); (2) latency increase (> 2 ms) and/or amplitude decrease (> 50%), transient loss of the F wave; (3) permanent loss of the F wave (worst case).

Transcranial Magnetic Stimulation of the Facial Cortex (FATMEP) and Blink Reflex Recording

In addition to F wave recording, FATMEP and blink reflex recordings were performed extraoperatively. These methods are referred to as a diagnostic standard for electrophysiologic assessment of facial nerve function in diseases involving the brainstem, the cerebello-pontine angle, and the petrous bone.[12-15] Transcranial magnetic stimulation of the facial motocortex was carried out as described by Rösler et al.[14,15] For blink reflex recording, the technique described by Kimura[12] was used. Latencies of blink reflex R1 (shortest of 4 recordings) and of the compound muscle action potential evoked by FATMEP (shortest of 6 recordings) was taken for further statistical analysis.

Intraoperative EMG Recordings

EMG recordings were performed with subdermal needle electrodes (impedance < 5 kOhm) placed over the orbicularis oculi and oris muscles. Muscle activity was amplified (100 μV/div) and filtered (bandpass 20 to 3000 Hz). A standard 4-channel electrophysiologic device (NeuroPack 4, Nihon Kohden Inc, Tokyo, Japan) was used for all stimulation and recording purposes. Recordings were documented with a thermoprinter for off-line analysis. EMG findings were classified into 3 categories: (1) transient, manipulation-evoked activity that ceases immediately when manipulation stops (best case); (2) ongoing, lasting activity that outlasts obvious manipulation with amplitudes below 200 μV; (3) Ongoing, lasting activity that outlasts obvious manipulation with amplitudes above 200 μV (worst case).

Table 1. Mean (standard deviation) latencies of F wave, FATMEP, and Blink reflex R1 for unaffected vs tumor side

	F Wave latency (ms)	Cortical FATMEP latency (ms)	Blink-R1 latency (ms)
Normal	10.87 (±0.94)	10.23 (±1.52)	11.34 (±1.05)
Diseased	12.34 (±1.56)	11.45 (±1.66)	12.84 (±1.46)
P	<0.001	<0.001	<0.001

Statistical Analysis

For extraoperative recordings, Student's *t* test was applied for assessment of interside differences of latencies. Spearman's correlation analysis was performed for latencies and tumor diameter as well as for the House-Brackmann-grading early after surgery and the tumor diameter. Diagnostic sensitivity, specificity, positive predictive value, and negative predictive value of both methods were calculated and compared.[16]

RESULTS

Preoperative Diagnosis of Facial Nerve Function

The results of preoperative facial nerve testing with recording of F waves, FATMEP, and blink reflex are gathered in Table 1. Each of the parameters assessed was significantly increased on the side of tumor growth. Correlation analysis of these parameters with tumor diameter, however, resulted in a significant correlation only for F wave latencies (Table 2). Fig 1 gives an example of F wave latency increase paralleling tumor growth in a patient who had been followed over a period of 6 years and finally underwent surgery.

Intraoperative Monitoring of Facial Nerve Function

An example of intraoperative F wave recording is displayed in Fig 2. The intraoperative EMG and F wave findings related to postoperative outcome are displayed in Tables 3 and 4. In terms of diagnostic sensitivity and specificity, results were comparable for good (HB °I-II) facial function postoperatively for EMG (transient, manipulation-evoked activity; sensitivity 69%, specificity 89%) and for F wave monitoring (stable F waves; sensitivity 61%, specificity 89%). Positive as well as negative predictive values were similar for both techniques (EMG: positive predictive value 81%, negative predictive value 81%; F wave, 79% and 77%, respectively).

For a poor facial outcome, however, marked differences were observed between the 2 techniques: the diagnostic sensitivity of worst case EMG was only 36%, the specificity equalling 86%. Loss of F waves, in contrast, bore a 91% sensitivity and a specificity of 100% for a poor outcome. As a consequence, the positive predictive value of worst case EMG was only 57%, the negative predictive value being 72%. This means that only 57 of 100 cases presenting with major EMG changes intraoperatively will develop a severe to total paresis of the facial nerve; however, 28% of those without major EMG changes will nevertheless experience a poor facial nerve outcome. Loss of the F wave is associated with a positive predictive value of 100% and a negative predictive value of 96% that means that all cases exhibiting this finding intraoperatively will actually have a severe facial dysfunction whereas only 4% of those with preserved F waves will present with a poor facial outcome.

A transient loss of F waves that was observed in 9/32 (28%) cases was always associated with facial dysfunction (HB °II-IV). Transient loss was more frequent in cases with moderate facial dysfunction (6/8; 75%) than in those with good outcome (3/13; 23%). There was no correlation between the length of the time period of F wave loss, or of the number of periods of F wave loss, and the degree of facial dysfunction postoperatively. The correlation of EMG and F wave findings intraoperatively is given in Table 5. Stable F waves were never observed together with major EMG changes.

DISCUSSION

The data presented above reveal that F wave latency increase reflects the impact of a growing

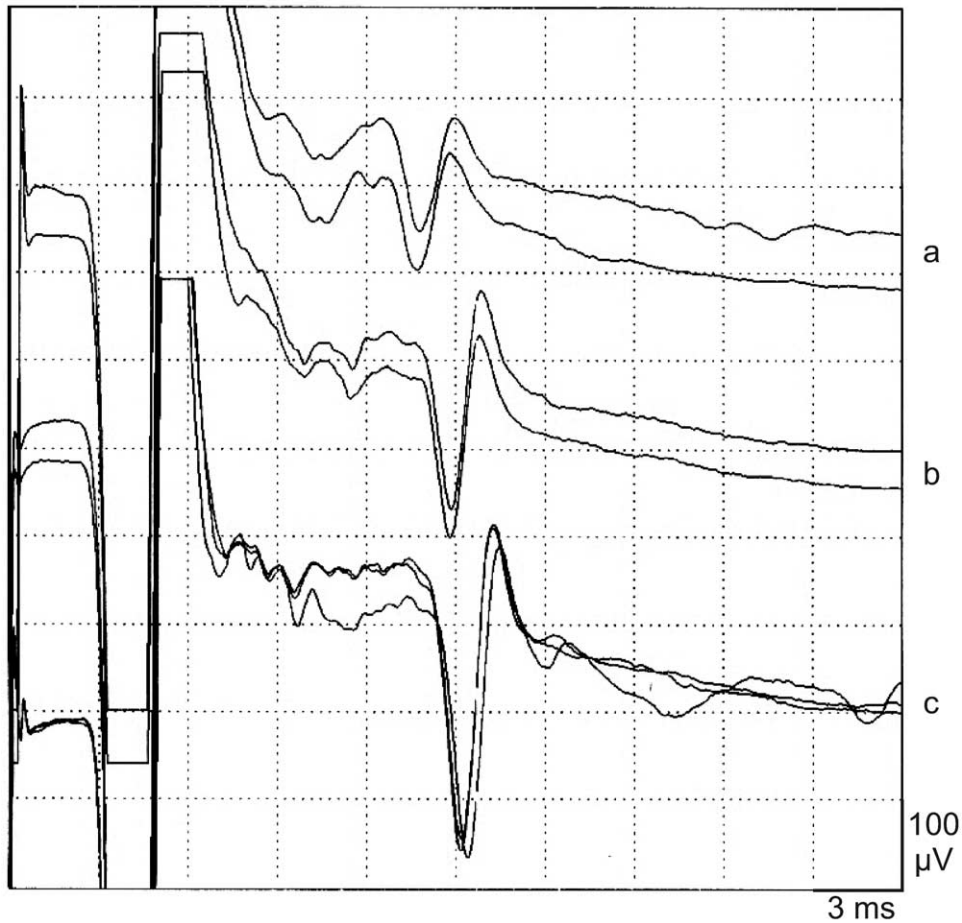

Fig 1. Increase of facial F wave latency in a patient with a growing acoustic tumor followed for 6 years (1995-2001) who finally underwent surgery. **A**, 1995: tumor diameter 10 mm. **B**, 1999: tumor diameter not assessed. **C**, 2001: tumor diameter 35 mm.

Table 2. Correlation coefficients (R) and *P* values for correlation of facial function (HB) and latencies of F wave, FATMEP, and Blink reflex R1 with tumor diameter

	HB 1d postop.	F-wave latency	Cortical FATMEP latency	Blink-R1 latency
R	0.38	0.56	0.21	0.21
P	0.025	0.001	0.23	0.23

acoustic tumor on facial nerve function and that intraoperative F wave changes closely parallel the actual strain exerted on the nerve. Intraoperative monitoring of F waves further provides a feature (transient loss of the F wave) which heralds an imminent danger of severe facial dysfunction to occur.

Several electrodiagnostic methods have been used to assess facial nerve function in acoustic tumor disease, as are electroneurography,[3,14] electromyography,[13] blink reflex recording,[10,13] and TMEP recording.[10,14,17] If clinical facial function was normal, however, a correlation with tumor diameter was detected only for blink reflex[13] and for facial transcranial motor evoked potentials (FATMEP).[10,17] In our previous comparative study of F wave and FATMEP in patients with acoustic tumors, the closest correlation with tumor diameter was calculated for F wave latencies, followed by the response latency to cortical magnetic stimulation.[10] This can be interpreted as a consequence of an increasing focal demyelination at the site of the growing tumor.[10,13]

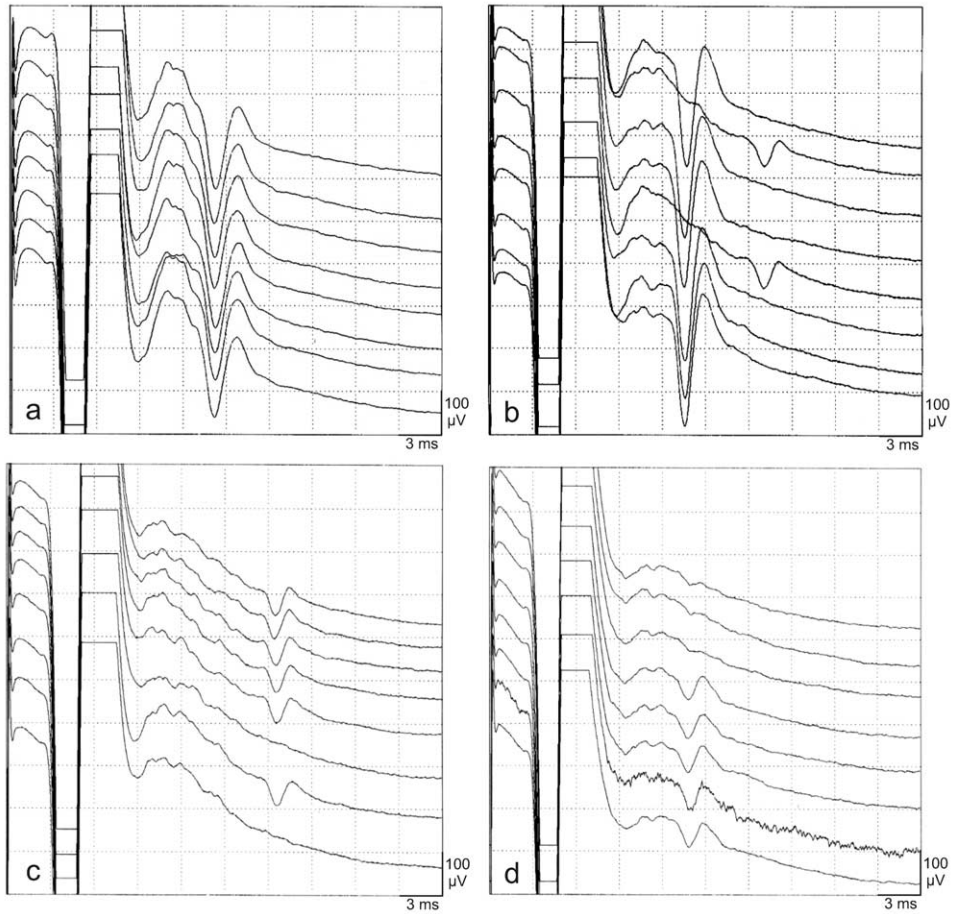

Fig 2. Intraoperative F wave recordings with transient loss of the signal. Tumor diameter was 45 mm, facial nerve function 1 day after surgery was HB °IV. **A**, Stable F waves after positioning of the patient. **B**, Initial stage of tumor dissection: intermittent F wave latency increase. **C**, Late stage of tumor removal: constant latency increase and transient loss of the signal. **D**, Final stage of surgery (dura closure): recovery of the F wave, latencies are still increased.

Table 3. Intraoperative EMG findings related to facial nerve outcome 1 day after surgery and of 22 cases re-examined 3 months after surgery (in parentheses)

Outcome	Transient, manipulation evoked	Ongoing, lasting, amplitude < 200 µV	Ongoing, lasting, amplitude > 200 µV	Total
Good	9 (9)	2 (3)	2 (1)	13 (13)
Moderate	1 (1)	6 (2)	1 (0)	8 (3)
Poor	1 (0)	6 (4)	4 (2)	11 (6)

Intraoperative monitoring of facial nerve function has to comply with 2 basic requirements: first, reliable and valid information concerning the present and future postoperative functional status is needed that, second, is available continuously in real-time fashion without a break in tumor dissection. Facial nerve stimulation done by the surgeon to compare the amplitudes and the thresholds to electrical stimulation proximal and distal to the tumor site bears information pertinent to the functional status of the nerve but does not fulfill the need for continuous online information, because electrical stimulation can only be carried out if dissection is interrupted. A continuous information on facial nerve function can be obtained from online EMG recording. The value of intraopera-

Table 4. Intraoperative F wave findings related to facial nerve outcome 1 day after surgery and of 22 cases re-examined 3 months after surgery (in parentheses)

Outcome	Stable	Latency/amplitude changes, transient loss	Permanent loss	Total
Good	8 (8)	5 (5)	0 (0)	13 (13)
Moderate	1 (1)	7 (0)	0 (2)	8 (3)
Poor	1* (1*)	0 (0)	10 (5)	11 (6)

*Postoperative hemorrhage into the cerebellopontine angle.

Table 5. Correlation of intraoperative EMG and F wave findings

	EMG		
F Wave	Transient, manipulation evoked	Ongoing, lasting, amplitude <200 μV	Ongoing, lasting, amplitude > 200 μV
Stable	7	3	0
Latency/amplitude changes, transient loss	3	6	3
Permanent loss	1	5	4

tive online EMG recordings to detect impairment of facial nerve function has been put into doubt by several authors including ourselves[4,5,11] (HP Schlake, personal communication). Especially the diagnostic sensitivity for a major degree of facial paresis to develop postoperatively appears to be low and thus fails to predict a considerable proportion of unfavorable courses. Permanent loss of the F wave, in contrast, bore a 100% positive predictive value for an unfavorable facial outcome (ie, a paresis °V-°VI according to the House-Brackmann classification). Electrical stimulation of the nerve as the second method currently used has been credited with reliability and effectiveness.[6,7] Because this method gives only discontinuous information, it is well supplemented by F wave monitoring that provides reliable and continual information. Because F waves are obtained in real time without signal averaging, this method is superior to monitoring techniques like recording of auditory evoked potentials that requires time-consuming signal averaging. Furthermore, F-wave monitoring bears a feature that heralds severe dysfunction of the facial nerve. Because the loss of the F wave can well be transient—we hypothesize that in most cases it is transient if dissection is interrupted immediately—a break in tumor preparation until the signal recovers may be the strategy of choice to prevent a lasting and severe paresis of the facial nerve.

We are indebted to Hartmut Stützer, PhD, for his help concerning the statistical analysis of the data. We thank Mrs Karin El-Tamer, Katja Kreuer, and Dina Wiegand for their skillfull technical support during the intraoperative measurements.

REFERENCES

1. Prass RL, Lueders H. Acoustic (loudspeaker) facial electromyographic monitoring: part I. Evoked electromyographic activity during acoustic neuroma resection. Neurosurgery 1986;19:392-400.
2. Beck DL, Atkins JS, Benecke JS, et al. Intraoperative facial nerve monitoring: prognostic aspects during acoustic tumor removal. Otolaryngol Head Neck Surg 1991; 104:780-2.
3. Harner SG, Daube JR, Ebersold MJ, et al. Improved preservation of facial nerve function with use of electrical monitoring during removal of acoustic neuromas. Mayo Clin Proc 1987;62:92-102.
4. Hone SW, Commins DJ, Rames P, et al. Prognostic factors in intraoperative facial nerve monitoring for acoustic neuroma. J Otolaryngol 1997;26:374-8.
5. Magliulo G, Zardo F. Facial nerve function after cerebellopontine angle surgery and prognostic value of intraoperative facial nerve monitoring: a critical evaluation. Am J Otolaryngol 1998;19:102-6.
6. Silverstein H, Willcox TO, Rosenberg SI, et al. Prediction of facial nerve function following acoustic neuroma resection using intraoperative facial nerve stimulation. Laryngoscope 1994;104:539-44.

7. Sobottka SB, Schackert G, May SA, et al. Intraoperative facial nerve monitoring (IFNM) predicts facial nerve outcome after resection of vestibular schwannoma. Acta Neurochir (Wien) 1998;140:235-43.
8. House W, Brackmann DE. Facial nerve grading system. Otolaryngol Head Neck Surg 1986;93:146-7.
9. Wedekind C, Klug N. Nasal muscle F-wave for peri- and intraoperative diagnosis of facial nerve function. Electromyogr clin Neurophysiol 1998;38:481-90.
10. Wedekind C, Klug N. Assessment of facial nerve function in acoustic tumor disease by nasal muscle F waves and transcranial magnetic stimulation. Muscle Nerve 2000;23:58-62.
11. Wedekind C, Klug N. Recording nasal muscle F waves and electromyographic activity of the facial muscles: a comparison of two methods used for intraoperative monitoring of facial nerve function. J Neurosurg 2001;95: 974-8.
12. Kimura J. Electrodiagnosis in diseases of nerve and muscle, 2nd ed. Philadelphia: FA Davis; 1989.
13. Normand MM, Daube JR. Cranial nerve conduction and needle electromyography in patients with acoustic neuromas: a model of compression neuropathy. Muscle Nerve 1994;17:1401-6.
14. Rösler KM, Jenni WK, Schmid U, et al. Electrophysiological characterization of pre- and postoperative facial nerve function in patients with acoustic neuroma using electrical and magnetic stimulation techniques. Muscle Nerve 1994;17:183-91.
15. Rösler KM, Magistris MR, Glocker FX, et al. Electrophysiological characterstics of lesions in facial palsies of different etiologies: a study using electrical and magnetic stimulation techniques. Electroencephalogr Clin Neurophysiol 1995;97:355-68.
16. Sachs L. Angewandte Statistik, 8th ed. Berlin: Springer; 1997.
17. Wolf SR, Schneider W, Berg M, et al. Facial nerve involvement in patients with acoustic neurinomas. Acta Otolaryngol (Stockh) 1995(Suppl520):29-32.

BOUND VOLUMES AVAILABLE TO SUBSCRIBERS

Bound volumes of *Otolaryngology–Head and Neck Surgery* are available to subscribers (only) for the 2003 issues from the Publisher, at an individual cost of $118.00 ($146.59 for Canadian, $137.00 for international subscribers) for Vols. 128 (January-June) and 129 (July-December). Shipping charges are included. Each bound volume contains subject and author indexes, and all advertising is removed. Copies are shipped within 60 days after publication of the last issue in the volume. The binding is durable blue buckram with the Journal name, volume number, and year stamped in gold on the spine. *Payment must accompany all orders.*

Contact Mosby, Inc, Subscription Customer Service, 6277 Sea Harbor Dr, Orlando, FL 32887; phone 800-654-2452 or 407-345-4000.

Subscriptions must be in force to qualify. Bound volumes are not available in place of a regular Journal subscription.