ELSEVIER

Clinical Neurophysiology 118 (2007) 1010–1018

www.elsevier.com/locate/clinph

Kinematic analysis of motor dysfunction in Niemann-Pick type C

A.G. Floyd [a], Q.P. Yu [a], P. Piboolnurak [a], E. Wraith [c], M.C. Patterson [b], S.L. Pullman [a,*]

[a] *Clinical Motor Physiology Laboratory, Department of Neurology, Columbia University Medical Center, New York, NY, USA*
[b] *Division of Pediatric Neurology, Columbia University Medical Center, New York, NY, USA*
[c] *Willink Biochemical Genetics Unit, Royal Manchester Children's Hospital, Manchester, UK*

Accepted 11 January 2007
Available online 27 February 2007

Abstract

Objective: To provide the first descriptive analysis of upper limb motor physiology in Niemann-Pick Type C disease (NP-C).
Methods: Fifteen patients with confirmed NP-C underwent motor physiology testing using accelerometry and surface EMG (sEMG). Tremor amplitude and frequency were quantified using accelerometry, and sEMG was examined for abnormal patterns consistent with various movement disorders.
Results: Forty-seven percent of patients had postural tremor in the upper limbs, generally bilateral, with frequencies ranging from 0.3 to 3 Hz, and an average amplitude of 1.20 ± 0.98 mm. Eighty-seven percent of patients had bilateral action tremor with frequencies ranging from 2.0 to 3.7 Hz, and an average amplitude of 5.25 ± 3.76 mm. sEMG revealed long but variable duration, variable amplitude muscle burst discharges during action in some patients, as well as short high frequency irregularly timed bursts in others.
Conclusions: Accelerometric findings correlated with the clinical findings were most consistent with cerebellar outflow tremors. sEMG revealed a mix of dystonic, myoclonic and choreiform movements.
Significance: These quantitative methods may serve as ancillary measures of disease pathophysiology, markers of change over time, and methods to evaluate efficacy, and side effects, of new treatments as they are developed.
© 2007 International Federation of Clinical Neurophysiology. Published by Elsevier Ireland Ltd. All rights reserved.

Keywords: Niemann-Pick disease; Clinical manifestation; Neurophysiology; Motor control; Tremor analysis; Spiral analysis

1. Introduction

Niemann-Pick Type C disease (NP-C) is an autosomal recessive storage disease characterized by sequestration of unesterified LDL cholesterol and sphingolipids in fibroblast lysosomes (Pentchev et al., 1985), as well as premature enrichment of cholesterol in trans Golgi cisternae (Coxey et al., 1993) associated with changes in intracellular sterol trafficking (Sturley et al., 2004). Excess glycosphingolipid accumulation accounts for characteristic neuropathology, including ectopic dendritogenesis (Walkley and Suzuki, 2004). The incidence of NPC is estimated at 1:130,000 live births and diagnosis is confirmed through biochemical testing demonstrating impaired cholesterol esterification in cultured fibroblasts.

NP-C can present at any age from infancy to adulthood with variable clinical manifestations. The classic presentation occurs in mid to late childhood with progressive ataxia, vertical supranuclear gaze palsy, and dementia, generally resulting in death in the second decade. Neonates may present with liver disease with or without secondary pulmonary failure that proves fatal in one-half of cases; some infants manifest initially with hypotonia and delayed motor development. Hepatosplenomegaly is common in infants and children. Adults are more likely to present with dementia or psychiatric symptoms (Pentchev et al., 1995). Later age of onset typically correlates with slower disease progression. No specific treatment exists to modify the progressive neurologic deterioration characteristic of NP-C in humans, but substrate reduction therapy (SRT) (Zervas et al., 2001), neurosteriod replacement (Griffin et al.,

* Corresponding author. Tel.: +1 212 305 1331; fax: +1 212 305 0743.
E-mail address: sp31@columbia.edu (S.L. Pullman).

1388-2457/$32.00 © 2007 International Federation of Clinical Neurophysiology. Published by Elsevier Ireland Ltd. All rights reserved.
doi:10.1016/j.clinph.2007.01.011

2004) and CDK inhibition (Zhang et al., 2004) have produced clinical and pathological benefit in animal models. SRT with miglustat has reversed the lipid trafficking abnormalities in peripheral lymphocytes in one patient (Lachmann et al., 2004).

The primary motor manifestation of NP-C is cerebellar ataxia; but intention tremor, dystonia, dysmetria, dysdiadochokinesia, and choreoathetosis are frequent. In a study of 22 NP-C patients, ataxia was present in all, and was the presenting clinical abnormality in five patients (Fink et al., 1989). Ataxic symptoms consistently worsened over time, generalizing from mild upper limb to moderate to severe full body involvement within 5–7 years of onset. Dysmetria and intention tremor are associated with both the infantile and juvenile onset forms of NP-C.

Cerebellar degeneration is among the earlier and more prominent features of NP-C neuropathology. Considerable loss of Purkinje cells has been established in both BALB/c and C57BL/KsJ mouse models of NP-C (Sarna et al., 2003; Tanaka et al., 1988; Yadid et al., 1998), as well as in humans albeit with greater variability (Patterson, 2003). Clinical manifestations of cerebellar loss include tremor and ataxia (Higashi et al., 1993).

The literature on motor dysfunction in NP-C, to our knowledge, has been limited to studies of saccadic eye movements as a potential surrogate marker (Rottach et al., 1997). Quantification and tracking of non-ocular motor symptoms, either over the natural course of disease progression or in the context of therapeutic efficacy, could provide a valuable supplement to clinical outcome measures.

As there are no established methods for characterizing and following pathological limb movements in NP-C, this report provides some basic upper limb motor physiology of NP-C using accelerometry and surface EMG (sEMG), a technique for simultaneously recording muscle activity and limb motion (Pullman et al., 2000). The combination of accelerometry and sEMG is a non-invasive method suited for testing periods of sufficient length to capture the erratic, variably superimposed motor symptoms of NP-C, particularly in young people. While not an exhaustive description of NP-C motor physiology, to our knowledge this is one of the largest quantitative studies of this rare disorder.

2. Methods

2.1. Patients

Data for this study were collected as part of a multi-centered study investigating the safety and efficacy of oral miglustat (Zavesca, Actelion Pharmaceuticals, Ltd, Switzerland), a reversible inhibitor of glucosylceramide synthase, the enzyme catalyzing the initial step in the synthesis of glycosphingolipids, in patients with NP-C. The clinical and physiologic evaluations were taken from baseline assessment before initiation of study medication. This study was approved by the Columbia University Medical Center Institutional Review Board.

All patients were clinically evaluated in the Pediatric Neurology division of the Columbia University Medical Center and informed consent was obtained. Standardized clinical assessments were performed. Patients were also rated using the Extended Disability Status Scale (Kurtzke, 1983). The EDSS, designed for multiple sclerosis patients and not validated for NP-C, reflects well the variability and severity of disability in NP-C. The EDSS ranges from 0 (normal) to 10 (death) and encompasses the following functional systems: pyramidal, cerebellar, brain stem, sensory, and bowel and bladder.

Fifteen patients completed baseline motor physiologic testing. Patients enrolled in the study were at least 12 years of age and had the diagnosis of NP-C confirmed by abnormal cholesterol esterification and abnormal filipin staining. Patients were excluded if they were concurrently under enrollment in other clinical trials, taking drugs or diet supplements that could interfere with digestive absorption of study medication, had a significant history of gastrointestinal disorders, HIV or hepatitis, or could not comply with study procedures.

2.2. Accelerometry and surface EMG

Lightweight (0.5 g) piezoresistive uniaxial accelerometers with linear sensitivities of approximately 4.5 mV/g in the biologic tremor range (0–25 Hz) were attached over the dorsum of both hands to assess wrist movements. Silver/silver chloride surface EMG electrodes simultaneously recorded muscle activity from bilateral wrist flexors (*flexor carpi radialis*, FCR) and extensors (*extensor carpi radialis*, ECR). sEMG signals were rectified and integrated prior to analyses. Accelerometric and sEMG signals were digitized at 300 Hz and multiple recordings were taken across four standard conditions: at rest, with arms extended (with and without 500 g inertial loading), flexing and extending the hands at the wrists, and during finger-to-nose (FTN) movements. Additional sEMG and accelerometry recordings were also taken from the leg or head in a subset of patients to quantify clinically observable tremor occurring at these locations.

The tremor acquisition setup allowed for relatively unrestrained activity of the head, arms and legs throughout testing to approximate the clinical state. The at rest condition was taken with the patient seated, the arms flexed at 90° and forearms supported by the chair to prevent transmitted upper arm movement. To measure postural tremors, the arms were flexed at the shoulders and extended at the elbows with the forearms, hands, and fingers held straight in a horizontal plane level with the shoulders. Inertial loading consisted of 500-g weights placed over the dorsum of each hand separately. With FTN trials, care was taken to ensure that the patients' hands, wrists and arms were level so that FTN movements were maintained in a level plane.

Pathologic tremor was defined as those oscillations exhibiting frequency spectra containing a maximum peak power at least double baseline power and exceeding 2×10^{-5} g^2 displayed at a gain of 1×10^{-5} g^2 per increment. Normal physiologic tremors are of markedly lower power and are thus not observable as a distinct peak under these criteria. Coherence with rectified integrated sEMG signals was evaluated, but not required for classification.

Data obtained included tremor amplitude, frequency spectra and power, side-to-side relationships, and relative timing of sEMG activation patterns. Tremor amplitude was obtained via double integration and averaging of accelerometric data. Peak tremor frequencies were calculated using a fast Fourier transform and resulting spectra were evaluated for clinically significant frequency bands and corresponding powers. In the FTN trials only, frequencies below 2 Hz were excluded as they generally were associated with voluntary motion.

Wrist flexor and extensor sEMG activity was classified as co-contracting, alternating contracting, as a mix of co- and alternating activity, or as lacking sEMG burst discharges. Asymmetric findings in sEMG, tremor frequency or amplitude were noted during resting and arms extended conditions, as were contralateral findings during FTN conditions. sEMG–accelerometry coherence was determined using cross-correlation techniques and evaluation of the superimposed spectra. Significant coherence was defined as peaks in the coherence spectra at least twice the power of background noise. Two to three trials were recorded in 4-s epochs for rest and postural conditions, and 10 s for kinetic conditions, resulting in a collection of 10–15 trials per patient. The trials with the highest amplitude tremors and highest power frequency peaks were submitted for analysis. Data from the more affected sides were used in the calculations of group averages. Total recording time lasted 1–2 h.

3. Results

3.1. Clinical findings

Fifteen patients (seven males) completed the study. Their mean age was 25 ± 10 years, ranging from 12 to 42 years. Five patients (33%) exhibited their first motor symptom in mid to late childhood (ages 6–10), three (20%) in adolescence (ages 12–17), and four (27%) did not experience their first motor symptom until adulthood, though non-motor abnormalities may have been present earlier. Gait disturbance was specifically mentioned as the initial motor symptom in 7/15 (47%) of cases. 14/15 patients (93%) were right hand dominant.

Patients were typically moderately impaired, with a median EDSS rating of 3.5 (mean: 4.6 ± 1.9), reflecting ability to fully ambulate without aid but with mild to moderate disability in one or more functional systems. Scores reflected a wide range of abilities, ranging from 2.5 (minimal disability in two functional systems) to 9 (restricted to bed most of the day). Patients had a variety of movement dysfunction with gait ataxia and dystonia the most prevalent. Specifically, all fifteen (100%) patients had gait ataxia to varying degrees; additionally, two (13%) patients had ataxia associated with finger-to-nose or heel-to-shin movements. Ten (67%) patients had dystonia, ranging from mild (seven cases) to severe (two cases), most commonly manifested as posturing of the feet or upper limbs while walking. Eight patients (53%) had difficulty with rapid alternating movements. Five patients (33%) exhibited dysmetria during standard testing (finger-to-nose and heel-to-shin). Three patients (20%) each exhibited intention tremor or myoclonic jerks. In addition, one patient (7%) had sEMG findings consistent with a peripheral neuropathy, another (7%) had repeated episodes of cataplexy, and a third single patient (7%) had rest tremor. Demographic, clinical, and physiologic summaries of each case are given in Table 1.

3.2. Motor physiology

Accelerometric findings showed no activity at rest, but there were low frequency, erratic oscillatory movements that were variably present with sustained postures, and most consistent and severe during action (Table 1).

Amplitudes had significant between-trial correlations in both the arms extended and FTN conditions on both right and left sides ($r = 0.78$–0.98, $p < 0.05$). Previous research on PD patients using these methods found consistent within-subjects peak tremor frequencies across a 3-month span (Pullman et al., 1994). However, given the broader range of the spectra in NP-C patients, correlations within subjects in trial-to-trial peak frequencies were not always evident. Nevertheless, frequency ranges across additional trials remained within 1 Hz of their original upper and lower bounds in all cases.

Seven patients (47%) had pathological postural tremor in the upper limbs; five of these seven had bilateral, generally symmetric, tremors. Side-to-side frequency differences ranged only from 0.1 to 1.4 Hz. Postural tremors averaged 1.6 ± 0.80 Hz and ranged from 0.3 to 3.0 Hz. All but one patient (case 8) showed a broad based frequency band, extending over an average interval of 1 Hz in the dominant hand, and 3 Hz in the non-dominant hand (Fig. 1). Three out of seven (43%) had significant coherence between the forearm sEMG and accelerometry spectra suggesting that although multiple joints are being measured from the shoulder to the hand, at least a component of the limb oscillations related to forearm muscle activity.

Postural tremor amplitudes ranged from 0.60 to 3.45 mm, with a mean of 1.20 ± 0.98 mm. Dominant versus non-dominant amplitudes significantly correlated within subjects (Pearson $r = 0.938$; $p < 0.05$). Amplitude variability for each case was based on the coefficient of variance within a given trial (SD/mean). The standard deviation within a trial was calculated by averaging across all peak-to-peak amplitudes. Patients showed $44\% \pm 7\%$ vari-

Table 1
Clinical and physiologic summary

Case	Age	Gender	Age of onset of motor symptoms	First motor symptom(s)	EDSS score	Clinical: ataxia	Clinical: dystonia	Clinical: myoclonic jerks	Physiology: postural tremor	Physiology: action tremor	Physiology: dystonia	Physiology: myoclonus
1	17	F	10	Gait ataxia	5.5	++	+	0	0	+	0	0
2	18	F	14	Gait difficulty	3.5	n/a	0	0	0	+++	0	0
3	42	M	28	Balance, coordination, speech	3	++	0	0	0	++	0	0
4	12	F	8	Balance coordination	3.5	++	+	√	+	++	√	√
5	20	F	12	Gait disturbance	6.5	++	+++	0	+	+++	√	0
6	18	F	15	Gait disturbance, Axial tremor	8	+++	+	0	+	+++	√	0
7	39	M	33	Subtle change in balance	3.5	++	0	0	0	+	0	0
8	32	F	26	Tremor, gait disturbance, handwriting	3.5	+	+	√	+	++	0	√
9	18	M	Unknown	Unclear, no motor mentioned in history	3.5	+	+	0	0	+	0	0
10	17	M	Unknown	Unclear	2.5	+	0	0	0	0	0	0
11	35	M	6	Dysarthria	4.5	+	+	0	+	+	√	0
12	25	M	8	Fine motor coordination, gait unsteadiness	9	+++	+++	0	+	+	√	0
13	17	F	9	Coordination	5	++	+	0	0	+	0	0
14	42	M	Unknown	Coordination	3	+	0	√	0	0	0	0
15	25	F	19	Gait disturbance	4.5	++	++	0	+	+	0	0

The clinical rating scales are scored as follows: dystonia: 0, not present; +, apparent only with action; ++, affecting one limb with action and at rest; +++, affecting two or more limbs including generalized dystonia. Ataxia: +, apparent only on tandem walking; ++, ataxic gait but able to walk without assistance; +++, unable to walk without assistance. Myclonus: 0, absent; √, present. The physiologic rating scales are as follows: postural tremor: 0, <0.5 mm; +, 0.5–5 mm; ++, 5–10 mm; +++, >10 mm. Action tremor: 0, <1 mm; +, 1–5 mm; ++, 5–10 mm; +++, >10 mm.

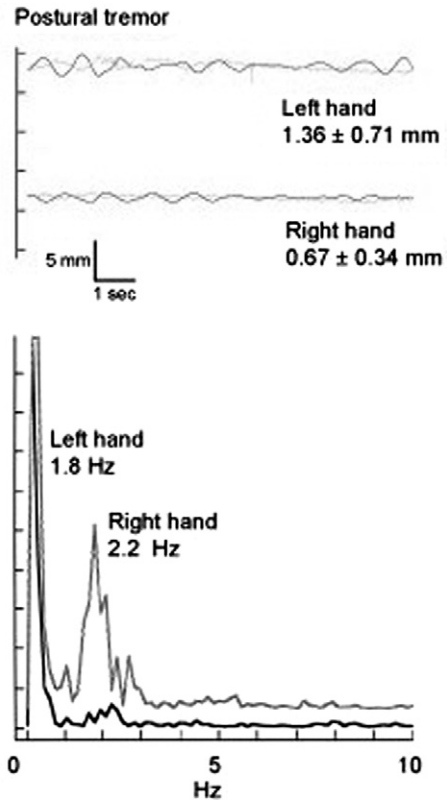

Fig. 1. Top: bilateral postural tremors in a NP-C patient. Note the highly variable, low amplitude tremors. Bottom: corresponding frequency spectra of right and left hand tremor in the same patient. Note the broad frequency base (2–3 Hz bilaterally), and low peak frequencies (1.8 and 2.2 Hz).

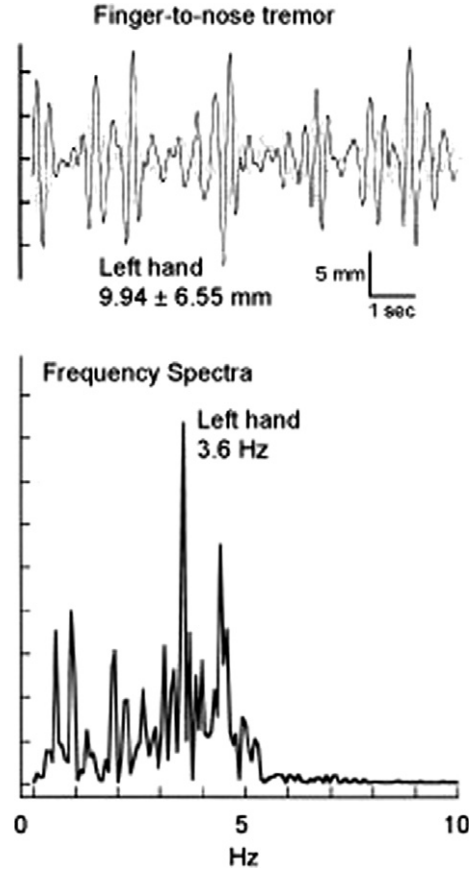

Fig. 2. Top: left hand action tremor during left finger-to-nose action that is of higher amplitude, and more variable than the postural tremors. Bottom: corresponding frequency spectra of the above. Note the broad frequency base (0–5.5 Hz) and slightly higher peak frequency (3.6 Hz), as well as the variably increasing amplitudes at regular intervals through movement, reflecting the intention component.

ability in the dominant hand and 64% ± 19% in the non-dominant hand. Inertial loading produced mixed results on tremor amplitudes, but generally had little effect on tremor frequencies, which remained within 1 Hz of their original value.

sEMG of wrist flexors and extensors during the arms extended condition showed typical baseline activity in 11 cases (73%). Four cases (4, 5, 8, 12) had abnormal postural activity. Cases 5 and 12 showed a similar pattern of discrete, irregularly timed mix of co- and alternating contractions, more prominent in the ECR than FCR. Case 4 had lower amplitude co- and alternating contractions in both left and right ECR/FCR pairs. Case 8 had semi-rhythmic short duration (50–80 ms) bursts, slightly more prominent in the ECR.

Thirteen patients (87%) had action tremor induced by FTN movements; all findings were bilateral. Frequency bands induced by normal, voluntary FTN motion peak between 0 and 1 Hz and significant activity does not extend beyond an upper bound of 2 Hz. Therefore only peak frequencies above 2 Hz are reported. The peak frequency of the primary (highest power) band ranged from 2.0 to 3.7 Hz, averaging 2.6 ± 0.2 Hz. Upper bounds ranged from 3.0 to 6.0 Hz (Fig. 2). Dominant and non-dominant tremor frequencies did not correlate within subjects. Seven of the 13 patients (54%) had coherent sEMG peaks in the 2–3.7 Hz range. Five patients (33%) had a second, higher frequency more sharply peaked oscillation band with maximum power found between 5.5 and 8.6 Hz. There was no significant coherence between accelerometry and forearm flexor or extensor sEMG at these higher frequency ranges.

Mean tremor amplitudes during action were 5.25 ± 3.76 mm (range: 0.79–14.7 mm). Bilateral dominant and non-dominant hand tremor amplitudes were significantly correlated within subjects (Pearson $r = 0.876$; $p < 0.0001$). The within-subject amplitude variability across time was 58% ± 12% for the dominant hand and 59% ± 22% for the non-dominant hand. Among the seven patients with both action and postural tremor, action tremor revealed significantly higher frequencies ($p = 0.008$) and a trend towards larger amplitudes ($p = 0.07$). FTN tremors revealed variable but consistently higher amplitudes toward the end-points of movement (Fig. 2).

Typical sEMG profiles in a normal control performing FTN action showed rhythmic ECR bursts of consistent duration and amplitude, accompanied by lower level co-

contraction in the FCR antagonist. Burst durations rarely varied by more than 100 ms, and the ratio of largest to smallest burst amplitude within a trial is below 2. sEMG activity during FTN action was abnormal in six cases (40%). Abnormalities among NP-C patients included, variable burst duration and inter-burst intervals, variable burst amplitude, the presence of alternating contractions, and sEMG activity in the contralateral arm.

Among NP-C patients, burst duration often varied by 500–1000 ms within a 10 s trial, and burst amplitudes varied up to fourfold from the smallest to largest burst amplitude in a single muscle and trial (cases 6 and 11). Case 11 had burst durations ranging from 1000 to 3000 ms in the ECR, and amplitudes that varied most noticeably during right FTN, with an amplitude ratio of four (Fig. 3). Case 6 had burst durations ranging from 500 to 1000 ms and burst amplitudes varied by a ratio of two to one. Cases 5 and 12 had variable duration bursts without variable amplitude.

In addition to abnormal sEMG in the moving hand, four cases (2, 4, 5, 11) had involuntary sEMG activity in the contralateral arm during FTN. Case 11 had low amplitude, long duration (up to 3000 ms) alternating ECR/FCR activity in the left arm during right FTN motion. There was no corresponding motion signal given by accelerometry. Cases 2, 4, and 5 each had muscle activity in the contralateral ECR or FCR during FTN, coherent with 1.8, 4–6, and 3.3 Hz tremor, respectively.

Two cases (4, 11) presented a mix of irregularly timed alternating contractions interspersed among co-contractions during action. Case 4 had alternating ECR/FCR burst activity during left FTN trials. Case 11 had alternating contractions in bilateral FTN conditions. Two cases (4, 8) had short duration (<100 ms) high frequency sEMG bursts during action. Case 4 exhibited this pattern on right FTN motion in the right ECR and FCR muscles (Fig. 3), as well as in the contralateral arm as described above. Case 8 had persistent 20–100 ms high frequency bursts at rest, with arms extended, and during FTN trials.

Five NP-C patients (cases 6, 5, 1, 4, 9; data collected in 8/15 cases) had abnormal sEMG patterns during wrist flexion and extension, often in the form of partially overlapping, poorly defined, agonist–antagonist bursts (Fig. 4).

Case 8 uniquely revealed a moderate amount of sEMG activity at rest, and a specific pattern of short, high frequency sEMG bursts with arms extended, variably superimposed on longer co-contracting bursts. The resting sEMG was accompanied by low amplitude 6.3 Hz rest tremor in the left (non-dominant) hand. sEMG during the postural condition was coherent with two distinct tremor bands, one peaking at 0.3 Hz, and the other at 6.5 Hz. This patient had additional sEMG leads placed on the left and right zygomaticus major muscles based on clinical report of facial twitching. FTN movement induced 9–10 Hz sEMG activity bilaterally in these facial muscles.

4. Discussion

We found that the motor physiologic findings of NP-C are characterized predominantly by variable, low frequency irregular movements that are absent at rest, intermittently present while sustaining postures, and most severe with action. The accelerometric and sEMG measurements reliably quantified movements and muscle activity most consistent with cerebellar tremor, dystonia, myoclonus, and choreiform movements (Table 1).

NP-C action tremor had significantly larger amplitudes, as well as slightly higher frequencies, than postural tremor. Because larger amplitude tremors are generally associated with lower frequency movements, this combination of physiologic results indicates increased severity with action, as would be expected with a predominantly cerebellar disorder.

The frequencies and waveform properties of the analyzed tremors were suggestive, though not diagnostic, of cerebellar outflow tremor. This tremor was characterized by its low frequency range (<5 Hz), high amplitude variability, and consistent activation patterns (action > postural, absent rest tremor). FTN tremors revealed their characteristic intention components with markedly increasing amplitudes at end-points of movement. Cerebellar outflow tremor has been attributed to force and timing disturbances in the activity of antagonistic muscles (Deuschl et al., 2001). sEMG profiles in the present study during both voluntary FTN motion and flexion extension maneuvers showed variable amplitude, variable duration bursts

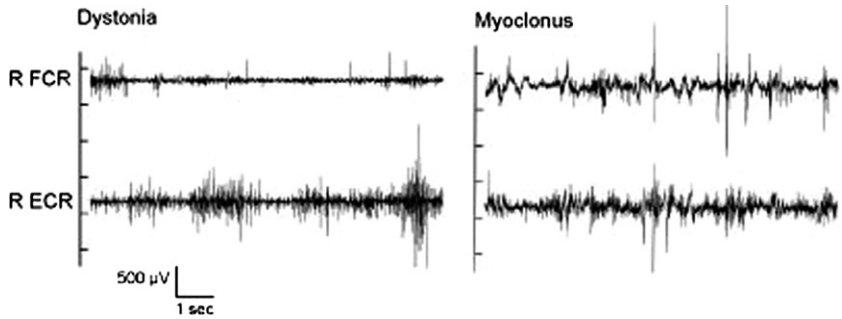

Fig. 3. Left: sEMG from right arm flexor extensor pair in a NP-C patient during right finger-to-nose action. Note the variable duration, variable amplitude muscle burst discharges with mixed co- and alternating contractions. Right: sEMG from right arm flexor extensor pair in a different NP-C patient during right finger-to-nose motion. Note the short duration EMG burst discharges with variable inter-burst durations.

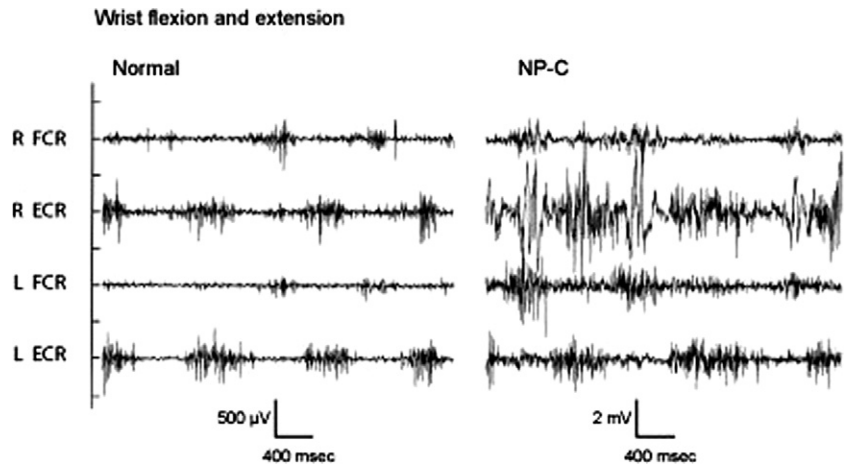

Fig. 4. Left: normal sEMG burst duration patterns from both right and left arm flexor and extensor pairs during wrist flexion extension maneuvers. There are clear alternating ECR and FCR contractions of similar duration and consistent timing. Right: corresponding sEMG from another NP-C patient with abnormal muscle activity. Note the poorly defined, overlapping muscle burst discharges, the continuous contraction in the right ECR, and the variable amplitude EMG burst discharges.

with irregular timing and poorly defined boundaries between antagonists. Overall agonist–antagonist sEMG bursts during action were temporally uncoordinated compared to the normal control pattern, and their amplitude variability was consistent with force disturbances.

In addition to low frequency tremor, the present study found higher frequency, 5.5–8.6 Hz range, irregular tremors in a subset of cases. These tremor frequencies are common to a number of disorders such as essential tremor, dystonic tremor, psychogenic tremor, neurogenic tremor, and lower frequency physiologic tremor (Deuschl et al., 2001). However, given broad frequency spectra and irregular amplitudes, dystonic tremor seems most likely. All but one physiologically recorded case in this subset had clinically documented action-induced dystonia.

The lack of significant coherence between arm movements and distal arm muscles is problematic due to the measurement over multiple joints making the accelerometry difficult to interpret. The long duration, partially overlapping antagonist sEMG burst activity suggests that these abnormal movements may have been generated and modulated by more proximal sEMG activity that was not measured.

Tremor amplitudes were relatively symmetric between the dominant and non-dominant hands. All patients with action tremor (87%) exhibited the tremor bilaterally with a large and highly significant side-to-side amplitude correlation ($r = 0.9$, $p < 0.0001$). Although postural tremor was not as symmetric bilaterally (three of eight patients were unilateral), amplitudes of bilateral cases correlated within subjects ($r = 0.9$, $p < 0.05$). This is in contrast to previous asymmetries found in the sEMG topography of tremor in patients with cerebellar disorders (Milanov, 2001).

Forty percent of NP-C patients (six cases) had sEMG findings consistent with dystonia during FTN. sEMG correlates of dystonia included burst duration variability (overall duration was often longer than normal), variable burst amplitude, and an erratic pattern of co- and alternating contractions (Fig. 3). Dystonic sEMG features were most prominent with action, agreeing with the most common clinical conclusion of dystonia induced by action only. Dystonic sEMG was also bilateral in all cases, suggesting that action-induced dystonia in NP-C is more generalized.

There was reasonable agreement between clinical and electrophysiologic measures of dystonia. None of the five patients without clinically detected dystonia had any of the physiologic correlates of dystonia. Among the 10 patients with mild to severe clinical dystonia, consistent sEMG abnormalities were found in five cases. However, when dystonia was clinically assessed, upper versus lower extremity involvement was not always documented. sEMG was done only on the upper wrist flexors and extensors, so a full comparison is not possible.

There was an association between abnormal sEMG in the arms extended condition and unique or severe clinical findings. Of the four such patients, cases 5 and 12 were the only two with clinically documented dystonia of Grade 4 (generalized dystonia). In contrast, the majority of cases (73%) had Grade 1 dystonia, defined as present only during action. Case 4 was the only case of clinically documented choreiform movements, described as subtle and occurring when the upper extremities were held extended. The ECR/FCR burst amplitudes were correspondingly low, and bursts were also shorter and less defined than the two generalized dystonia cases.

Thirteen percent of NP-C patients (cases 4 and 8) had electrophysiologic correlates of cortical myoclonus (Fig. 3). Correlates were short duration (<100 ms) high frequency clusters of bursting activity with no consistent inter-cluster interval, present during posture or action, with both agonist and antagonist involvement (Shibasaki and Hallett, 2005).

Case 8 had persistent myoclonic sEMG features, apparent in all testing conditions (rest, postural, FTN). The 20–80 ms burst durations in the rest and postural conditions suggest cortical myoclonus, though the bursts were not uniformly co-contracting as is typical. During action, sEMG findings were consistent with previous descriptions of myoclonic dystonia (Obeso et al., 1983); namely, short, high frequency antagonist bursts superimposed upon continuous contraction and periodic long duration bursts.

In cases revealing myoclonus, there were high levels of agreement between physiologic and the clinical assessments; the clinical and physiologic findings correlated in two out of three myoclonus positive cases and all myoclonus negative cases.

Dystonic and myoclonic muscle activity in homologous muscles in both hands during FTN motion was notable in almost a third (4/15) of the cases. One patient revealed homologous myoclonic sEMG bursts in wrist flexors and extensors in both the moving and non-moving limb during right FTN trials. sEMG activity in both hands was coherent with a 4–6 Hz tremor; however, homologous muscle activity was not time-locked. Three cases had long and variable duration, low amplitude sEMG activity in the contralateral hand during FTN consistent with dystonia. The pattern of activation (burst duration, inter-burst interval) was similar to the moving hand in all three cases, though significant coherence between right and left ECR/FCR pairs was found only in one case.

Activation of muscle activity on the contralateral side during unilateral motion is associated with focal dystonia (Merello et al., 2006; Jedynak et al., 2001), and was found in a subset of NP-C cases. These types of mirror movements have been attributed to lack of transcallosal inhibition combined with over activation of the ipsilateral motor cortex (Aranyi and Rosler, 2002), and abnormal bilateral activation of primary motor areas (Mayer et al., 1999). Of note, one patient with contralateral activation had no other physiologic correlates of dystonia, suggesting that the mechanisms controlling mirror movements may be independent of the basal ganglia circuitry associated with dystonia (Vitek, 2002), such as those underlying variable force and duration of muscle activation.

Motor physiologic assessment of neurodegenerative disorders such as NP-C provides a degree of objective quantification to a complex clinical picture. In this study, accelerometry and sEMG helped delineate the breadth and scope of NP-C motor abnormalities, delineating physiologic correlates suggestive of cerebellar outflow tremor, dystonia, chorea, and myoclonus. These quantitative methods also serve as ancillary measures of disease pathophysiology, markers of change over time, and methods to evaluate efficacy as novel treatments are developed.

Acknowledgement

This study was supported by a research grant from Actelion Pharmaceuticals [OGT 918-007].

References

Aranyi Z, Rosler KM. Effort-induced mirror movements. A study of transcallosal inhibition in humans. Exp Brain Res 2002;145:76–82.

Coxey RA, Pentchev PG, Campbell G, Blanchette-Mackie EJ. Differential accumulation of cholesterol in Golgi compartments of normal and Niemann-Pick type C fibroblasts incubated with LDL: a cytochemical freeze-fracture study. J Lipid Res 1993;34:1165–76.

Deuschl G, Raethjen J, Lindemann M, Krack P. The pathophysiology of tremor. Muscle Nerve 2001;24:716–35.

Fink JK, Filling-Katz MR, Sokol J, Cogan DG, Pikus A, Sonies B, et al. Clinical spectrum of Niemann-Pick disease type C. Neurology 1989;39:1040–9.

Griffin LD, Gong W, Verot L, Mellon SH. Niemann-Pick type C disease involves disrupted neurosteroidogenesis and responds to allopregnanolone. Nat Med 2004;10:704–11.

Higashi Y, Murayama S, Pentchev PG, Suzuki K. Cerebellar degeneration in the Niemann-Pick type C mouse. Acta Neuropathol (Berl) 1993;85:175–84.

Jedynak PC, Tranchant C, Zegers de Beyl D. Prospective clinical study of writer's cramp. Mov Disord 2001;16:494–9.

Kurtzke JF. Rating neurologic impairment in multiple sclerosis: an expanded disability status scale (EDSS). Neurology 1983;33:1444–52.

Lachmann RH, te Vruchte D, Lloyd-Evans E, Reinkensmeier G, Sillence DJ, Fernandez-Guillen L, et al. Treatment with miglustat reverses the lipid-trafficking defect in Niemann-Pick disease type C. Neurobiol Dis 2004;16:654–8.

Mayer M, Schulze S, Danek A, Botzel K. Dipole source analysis in persistent mirror movements. Brain Topogr 1999;12:49–60.

Merello M, Carpintiero S, Cammarota A, Meli F, Leiguarda R. Bilateral mirror writing movements (mirror dystonia) in a patient with writer's cramp: functional correlates. Mov Disord 2006;21:683–9.

Milanov I. Electromyographic differentiation of tremors. Clin Neurophysiol 2001;112:1626–32.

Obeso JA, Rothwell JC, Lang AE, Marsden CD. Myoclonic dystonia. Neurology 1983;33:825–30.

Patterson MC. A riddle wrapped in a mystery: understanding Niemann-Pick disease, type C. Neurologist 2003;9:301–10.

Pentchev PG, Comly ME, Kruth HS, Vanier MT, Wenger DA, Patel S, et al. A defect in cholesterol esterification in Niemann-Pick disease (type C) patients. Proc Natl Acad Sci USA 1985;82:8247–51.

Pentchev PV, Vanier MT, Suzuki K, Patterson MC. Niemann-Pick disease type C: A cellular cholesterol lipidosis. New York: McGraw-Hill; 1995.

Pullman SL, Elibol B, Fahn S. Modulation of parkinsonian tremor by radial nerve palsy. Neurology 1994;44:1861–4.

Pullman SL, Goodin DS, Marquinez AI, Tabbal S, Rubin M. Clinical utility of surface EMG: report of the therapeutics and technology assessment subcommittee of the American Academy of Neurology. Neurology 2000;55:171–7.

Rottach KG, von Maydell RD, Das VE, Zivotofsky AZ, Discenna AO, Gordon JL, et al. Evidence for independent feedback control of horizontal and vertical saccades from Niemann-Pick type C disease. Vision Res 1997;37:3627–38.

Sarna JR, Larouche M, Marzban H, Sillitoe RV, Rancourt DE, Hawkes R. Patterned Purkinje cell degeneration in mouse models of Niemann-Pick type C disease. J Comp Neurol 2003;456:279–91.

Shibasaki H, Hallett M. Electrophysiological studies of myoclonus. Muscle Nerve 2005;31:157–74.

Sturley SL, Patterson MC, Balch W, Liscum L. The pathophysiology and mechanisms of NP-C disease. Biochim Biophys Acta 2004;1685:83–7.

Tanaka J, Nakamura H, Miyawaki S. Cerebellar involvement in murine sphingomyelinosis: a new model of Niemann-Pick disease. J Neuropathol Exp Neurol 1988;47:291–300.

Vitek JL. Pathophysiology of dystonia: a neuronal model. Mov Disord 2002;17(Suppl. 3):S49–62.

Walkley SU, Suzuki K. Consequences of NPC1 and NPC2 loss of function in mammalian neurons. Biochim Biophys Acta 2004;1685:48–62.

Yadid G, Sotnik-Barkai I, Tornatore C, Baker-Cairns B, Harvey-White J, Pentchev PG, et al. Neurochemical alterations in the cerebellum of a murine model of Niemann-Pick type C disease. Brain Res 1998;799:250–6.

Zervas M, Dobrenis K, Walkley SU. Neurons in Niemann-Pick disease type C accumulate gangliosides as well as unesterified cholesterol and undergo dendritic and axonal alterations. J Neuropathol Exp Neurol 2001;60:49–64.

Zhang M, Li J, Chakrabarty P, Bu B, Vincent I. Cyclin-dependent kinase inhibitors attenuate protein hyperphosphorylation, cytoskeletal lesion formation, and motor defects in Niemann-Pick Type C mice. Am J Pathol 2004;165:843–53.