Real-time monitoring of the recurrent laryngeal nerve: An observational clinical trial

Christoph Ulmer, MD,[a] Klaus Peter Koch, PhD,[c] Andreas Seimer, MD,[b] Viktor Molnar, MD,[a] Uta Meyding-Lamadé, MD, PhD,[d] Klaus-Peter Thon, MD, PhD,[a] *and* **Wolfram Lamadé, MD, PhD,[a]** *Stuttgart, St. Ingbert, and West Frankfurt, Germany*

Background. *A variety of tools has been developed to identify nerve structures and to lower the risk of nerval injury during thyroid surgery. These tools are usually based on intermittent electrophysiological tracing of the nerves, but its use is still associated with permanent recurrent laryngeal nerve (RLN) injury. We are now presenting the results of the implementation of a novel real-time nerve monitoring system, based on a new vagal nerve cuff electrode.*

Methods. *Nineteen consecutive patients scheduled for thyroid surgery (17 with benign, 2 with malignant disease), were enrolled in this observational trial. The flexible cuff electrode was implanted during each operation and atraumatically surrounded the vagal nerve. The evoked potentials were sensed by standard thyroid electrodes. Electrical stimulation and recording were achieved through a multichannel electromyography (EMG) system. The signal analysis was performed in real-time by specially designed software.*

Results. *The cuff electrode did not cause any complications during or after the surgery. In all patients, stable and reproducible signals were easily evoked. The mean time required to place the electrode was 6.5 min. The mean overall vagal nerve stimulation time was 65 min. No permanent RLN lesions were detected in any patient. One patient with a postoperative bleeding from a strap muscle vein required a wound revision, which was performed without nerve monitoring. This patient experienced a temporary partial impairment of the left vocal cord. No hypoparathyroidism was observed in any patient postoperatively.*

Conclusions. *The presented technique of real-time continuous RLN monitoring by stimulation of the vagal nerve is feasible, safe, reproducible, and easy to perform. In addition, this new system is compatible with existing equipment and can be used as an add-on with conventional nerve monitoring devices during thyroid surgery. (Surgery 2008;143:359-65.)*

From the [a]Department of General, Visceral, and Trauma Surgery, Robert-Bosch-Hospital, Stuttgart; [b]Department of Phoniatry and Pedaudiology, Marienhospital, Stuttgart; [c]Fraunhofer Institute for Biomedical Technique, St. Ingbert; [d]Department of Neurology, Hospital Nord, West Frankfurt, Germany

Injury to the recurrent laryngeal nerve (RLN), resulting in permanent voice changes, is one of the most serious complications of thyroid surgery. Nerves may visually resemble connective tissue and small vessels and can be damaged during dissection. Moreover, unusual anatomic variants of the RLN exist in up to 20% of patients, which further increase the risk of its intraoperative injury.[1]

Several systems for electrophysiologic identification of the nerves have been initially developed in the early 60's, and are routinely used in many countries.[2] There are multiple published evidences of improved RLN identification and preservation of its function with the use of intraoperative neurophysiologic testing (INT).[2-6] But despite the use of INT, temporary and permanent paralysis of the vocal cord is still observed in about 1-6% of patients undergoing primary thyroid surgery.[7-10]

All devices for INT are based on electrical stimulation of the RLN-fibers and the registration of the laryngeal muscular response.[11-14] Conventional INT, with the use of a handheld stimulation

This work was supported by the "Bundesministerium für Medizinische Forschung" (BMBF Grand number 01EZ0722).

Accepted for publication October 11, 2007.

Reprint requests: Christoph Ulmer, MD, Robert-Bosch-Krankenhaus Stuttgart, Abteilung fur Allgemein-, Viszeral- und Unfallchirurgie, Auerbachstrasse 110, 70376 Stuttgart. E-mail: christoph.ulmer@rbk.de.

0039-6060/$ - see front matter

© 2008 Mosby, Inc. All rights reserved.

doi:10.1016/j.surg.2007.10.007

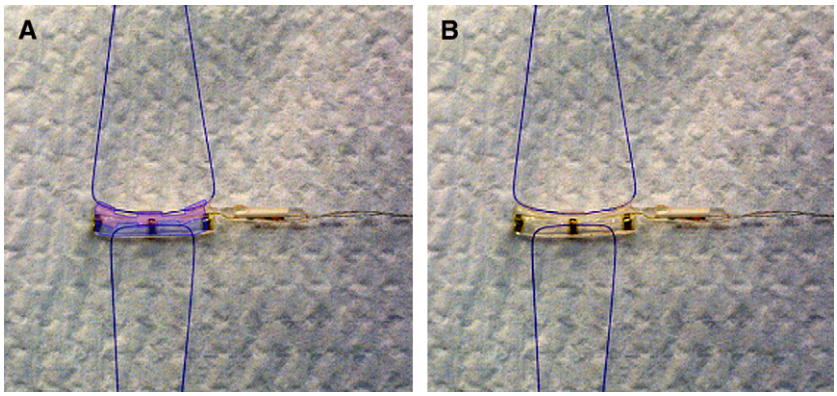

Fig 1. The vagal cuff electrode ready for implantation. The cuff electrode opened up with 4-0 monocryl sutures pulled through to cuff handles. For better visualization the electrode has been colored in blue (**A**). The original colors are seen in (**B**).

electrode, leads to nerve localization within the surgery field, but control of nerve function is limited to the short time interval of direct nerval stimulation. Therefore, the nerve is still at risk for damage between two RLN stimulations. Because of this limitation, some authors question the value of conventional intermitted INT, at least for broad use in routine clinical procedures.[10,15,16] In order to overcome this limitation, one of the authors (W.L.) has described the first real-time monitoring system to improve RLN monitoring.[17] This system was based on a double balloon electromyography (EMG) tube with atraumatic surface electrodes.[17] However, due to technical and economic reasons, this system has not been introduced into broad clinical practice yet.

The aim of the present study was to test a new vagal nerve electrode for the real-time continuous monitoring of the RLN. In accordance to the demands of the local ethical committee, the presented study was performed as a nonrandomized observational trial.

MATERIALS AND METHODS

The vagal cuff electrode. The presented real-time monitoring system has been developed in cooperation with the Fraunhofer Institute (St. Ingbert, Germany) and Inomed GmbH (Teningen, Germany). A tripolar hybrid cuff-shaped electrode to stimulate the vagal nerve was developed. This electrode is fully implantable during surgery and is very flexible to prevent nerval damage, even in case of incidental dislocation (Fig 1). Technical details of the electrode are presented elsewhere.[18]

Handheld stimulation electrode. In addition to the vagal cuff electrode for the real-time nerval stimulation, a conventional handheld bipolar stimulation electrode (Bipolar Microfork Probe, Inomed GmbH, Germany) was used for intermittent RLN localization and to identify any structure suspicious for nerves prior to dissection. The applied electrical pulses had amplitude of 5 mA, a pulse width of 200 μs, and a frequency of 3 Hz. The real-time monitoring was interrupted automatically when the handheld stimulation probe got into contact with the tissue.

Sensing electrodes. We used a bipolar needle electrode (Neurosign 100®, Inomed GmbH, Germany) as a basic sensing electrode to monitor compound muscle action potentials of the internal laryngeal muscles. This electrode was placed into the ipsilateral vocal muscle via the cricrothyroid ligament. The neutral electrode was placed into the subcutaneous tissue. In addition, we used a sticky surface electrode (Laryngeal Electrode™, The Magstim Company, UK) that was attached to a standard Woodbridge™ intubation tube (Mallinckrodt, UK).

EMG computer system. A commercial EMG system (NEMO®, Inomed GmbH, Germany) generated stimulation pulses with amplitude of 1–5 mA and pulse width of 200 μs. A special signal analysis software was developed, based on the software for the double balloon EMG tube. The induced compound action potentials from the tube electrode and the needle electrode were recorded and displayed separately. An acoustic feedback system alerted the surgeon about any changes in signal amplitude.

Anesthesia. All procedures were performed under standard general anesthesia. Only short acting muscle relaxants (ie, Cisatracurium) were given to the patients for induction of the anesthesia. The correct localization of the surface electrode was tested before and after positioning of the patient's

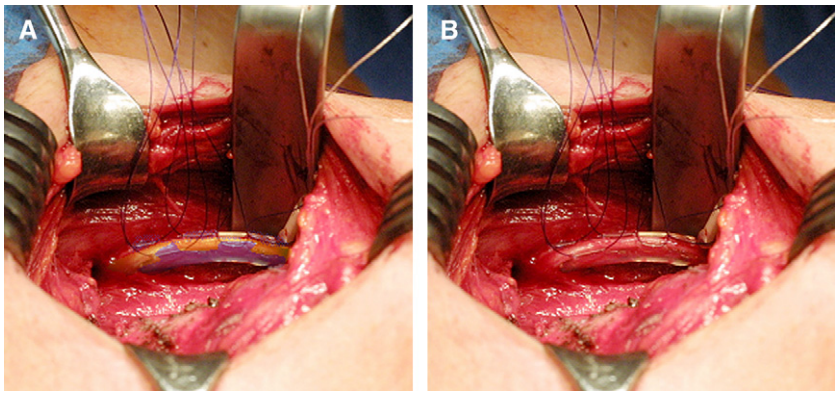

Fig 2. Placement of the vagal cuff electrode tension free around the vagal nerve. For better visualization the electrode has been colored in blue, the vagal nerve in yellow (**A**). The original colors are seen in (**B**).

head on the operating table. No further muscle relaxants were given during surgery.

Placement of the vagal cuff electrode. After a 3 cm long dissection of the ispilateral vagal nerve, the cuff electrode (Fig 1) was placed around the vagal nerve without any tension (Fig 2). To open the cuff 4-0 monocryl sutures were pulled through the cuff handles for smoother nerve introduction (Figs 1 and 2). Supramaximal stimulation current was applied to ensure complete stimulation of the entire nerve fibers. The applied current amplitude was between 0.5–1.5 mA.

Details of the operation course. Differences to standard thyroid operations are presented:

1. After preparation of the thyroid capsule, the vein of Kocher was dissected and medial force to the thyroid gland was applied to expose the vaso-vagal sheath. In case of a large goiter, transection of the thyroid isthmus was performed first in order to facilitate this maneuver;
2. Isolation of the vagal nerve;
3. Tension free placement of the vagal cuff electrode;
4. Calibration of the system to set the supramaximal stimulation current between 0.5–1.5 mA (all nerve fibers of the laryngeal nerve should be stimulated);
5. Recording of 10-30 recording impulses as reference signals;
6. The placement of the handheld stimulating probe to trace the course of the RLN was identical to standard nerve stimulation techniques;
7. Before dissection of the upper pole, the superior laryngeal nerve was stimulated with the handheld electrode.

Patients. The study was approved by the ethical committee of the medical faculty of the University of Tübingen, Germany. A written informed consent was obtained from each patient. Nineteen patients were enrolled into a nonrandomized observational clinical trial according to inclusion and exclusion criteria (Table I).

Table I. Inclusion and exclusion criteria

Inclusion criteria	*Exclusion criteria*
Elective thyroid operation	Preexisting RLN-paralysis
Age ≥ 18 years	Pacemaker
	Severe heart disease
	Missing informed consent

Pre- and postoperative laryngeal examination. All patients received a laryngeal examination of the vocal cord within 21 days prior to and after the surgery. In case of a vocal cord injury, the repeat examinations were scheduled until preoperative status was achieved or for a maximum of 2 years.

Statistical analysis and obtained data. All data were obtained prospectively, coded and saved in a Microsoft Access database (Microsoft, Redmond, Wash). Statistical analysis was done with SPSS software (SPSS Inc, Chicago, Ill).

RESULTS

Patients' characteristics. Patients' characteristics and types of resection are listed in Table II. Further details about the operations are summarized in Table III.

Results of electrophysiological studies. In all 19 patients, we were able to record stable evoked potentials from the vocal muscle (mean 197 μV; range, 45–401 μV) by the transligamentary placed needle electrodes. The mean supramaximal current was 1 mA. The maximal current used for supramaximal stimulation was 1.5 mA, and the minimal current was .5 mA.

The optional surface electrodes on the endotracheal tubes were not dependable. In 3 patients,

Table II. Patients characteristics

Patient No.	*Age*	*Sex*	*Diagnosis*	*Operation*	*Stable laryngeal electrode signals*	*Postoperative Complications*	*Postoperative RLN paralysis*
1	64	f	Hashimoto thyroiditis	Dunhill-OP	Yes	No	No
2	46	m	Bilateral, multiple follicular adenomas	Dunhill-OP	Yes	No	No
3	30	f	Unilateral, unifocal follicular adenoma	Unilateral resection	Yes	No	No
4	48	f	Unilateral multiple follicular adenomas	Hemithyroidectomy	Yes	No	No
5	42	f	Bilateral multiple follicular adenomas	Dunhill-OP	Yes	No	No
6	34	f	Unifocal papillary cancer T1N0, 2,5 cm	Total thyroidectomy, central lymph node dissection	Yes	No	No
7	72	f	Unilateral, multiple follicular adenomas	Dunhill-OP	Yes	No	No.
8	72	m	Unilateral multiple follicular adenomas	Hemithyroidectomy	Yes	No	No
9	44	m	Unilateral multiple follicular adenomas	Hemithyroidectomy	Yes	Reoperation due to hemorrhage	Yes (partially and temporarily)
10	73	m	Unilateral, unifocal follicular adenoma	Dunhill-OP	Yes	No	No
11	59	f	Bilateral, multiple follicular adenomas	Bilateral subtotal resection	Yes	No	No
12	37	f	Unilateral, unifocal follicular adenomas	Hemithyroidectomy	Yes	No	No
13	47	f	Unilateral, unifocal, pT1N0 papillary cancer	Dunhill-OP (Hemithyroidectomy on the carcinoma side)	Yes	No	No
14	55	f	Bilateral, follicular adenomas	Dunhill-OP	Yes	No	No
15	53	f	Regressive cyst	Hemithyroidectomy	Yes	No	No
16	50	f	Bilateral, follicular adenomas	Dunhill-Op	Yes	No	No
17	65	f	Unilateral, unifocal follicular adenoma	Dunhill-Op	Yes	No	No
18	39	f	Bilateral, follicular adenomas	Dunhill-Op	Yes	No	No
19	41	f	Hashimoto thyroiditis	Dunhill-Op	Yes	No	No

the misplacement of the recording surface electrodes on the endotracheal tube lead to a signal recording exclusively via the transligamentary needle electrode. In another 2 patients, unexpected difficulties during intubation resulted in detachment of the surface tube electrodes from the endotracheal tube. The signal recording in these patients was also made exclusively via the transligamentary needle electrodes. At the same time, transligamentary needle electrodes provided stable, reliable, and reproducible signal recording in all patients.

In 2 patients, we observed a reduction of the signal amplitude by more than 60% when the thyroid gland was retracted to expose the lateral part of the gland (see Fig 3). Because of the acoustic feedback system, the impaired nerve function was immediately detected by the surgeon, who reacted without delay by relieving the strain on the nerve. This led to instantaneous reconstitution of normal signal amplitude.

Neither false negative nor false positive signals were recorded through the transligamentary needle electrodes in any case.

Surgical complications. No permanent RLN-paralysis occurred in this study. One patient with a postoperative hemorrhage from a strap muscle vein required operating wound revision without nerve monitoring. This patient experienced temporarily a partial impairment of the left vocal cord without complete loss of mobility. None of the patients enrolled in the study has suffered from prolonged hypoparathyroidism.

Systemic interaction. We found no cardiac or pulmonary interaction during continuous vagal nerve stimulation. No patient had any motility disorders of the stomach or the intestine postoperatively.

Problems and pitfalls. Even though the application of the electrode to the vagal nerve is considered safe, it is still time consuming. In order to facilitate the placement of the vagal cuff electrode, we used monofile sutures for the opening of the cuff. The preparation of the vagal cuff electrode required a medium time of 3 min. In addition, the placement of the electrode required another 3 min. Altogether, the total preparation time for installation of the real time monitoring system took 6–10 min.

Two incidental dislocations of the vagal cuff electrode occurred due to the force of the electrode wires. As a result of geometry and flexibility of the cuff electrode, these dislocations did not cause any harm to the nerves. In 1 of these patients, a plump vagal nerve with a slight size mismatch to the cuff electrode contributed to the dislocation of the cuff electrode. In both of these patients, the only 3 and 7 min of additional procedure time were required to replace the electrodes.

Table III. Operations time and time to prepare the vagal cuff electrode

Characteristics	*Mean time (min)*	*Range (min)*
Total operation time	140	(93–240)
Time to place the cuff electrode	6,5	(1–35)
Time period of true continuous RLN monitoring	65	(20–100)
Time for electrical RLN depiction	40	(15–82)
Time for optical RLN depiction	50	(30–82)

DISCUSSION

Preservation of the recurrent laryngeal nerve is one of the key elements in thyroid surgery. Despite the broad use of INT, temporary and permanent paralysis of the vocal cord still occurs.[7-10] For this reason, several authors strongly questioned the value of the conventional INT systems during routine thyroid operations.[7-10,19,20] In order to overcome the limitations of intermittent electrophysiological nerve testing systems, Beldi et al recently stated the need of a "real time monitoring system."[21]

To implement the real time nerve monitoring, we collaborated with the Fraunhofer Institute St. Ingbert and Inomed (Teningen, Germany) to develop a new system based on a novel tripolar hybrid cuff electrode and special analysis software. In the present study, this electrode was placed at the vagal nerve below the superior laryngeal nerve off-branching for continuous RLN stimulation. The electrode can also be positioned above that branch, but it will require anatomical tissue dissection higher in the neck, which would be more traumatic. As an alternative, we routinely stimulated the external branch of the superior laryngeal nerve with the handheld electrode, in order to localize and preserve this part of the nerve before dissecting the upper pole of the thyroid gland.

Considerable experience with prolonged vagal stimulation over several months already exists in the therapy of drug-resistant epilepsy and depression.[22,23] Although voice alterations and coughing were detected after long-term stimulation over weeks and months, no complications were seen in these patients after a short-term stimulation.[24] In our study, vagal stimulation did not cause any cardiac, pulmonary, or gastrointestinal interactions (no bronchospasm, arrhythmia, postoperative gastrointestinal motility disorders, etc.).

Because of the highly flexible material, the cuff electrode could be easily implanted around the vagal nerve, as well as effortlessly extracted after the procedure. We had no complications during placement or removal of the vagal cuff electrode, even in rare cases of incidental electrode dislocation. In all patients, stable, homogenous, and reliable induced EMG signals from the larynx were recorded via the transligamentary needle electrodes. The computer based real time signal analysis was acoustically reported to the surgeon.

Two incidental dislocations of the vagal cuff electrode were observed during our study. These dislocations were caused by the force of the electrode wires and a slight mismatch between the size of the cuff electrode and the vagal nerve. These dislocations did not result in any nerve damage, but to correct this problem, different sizes of cuff electrodes will be needed in future. Furthermore,

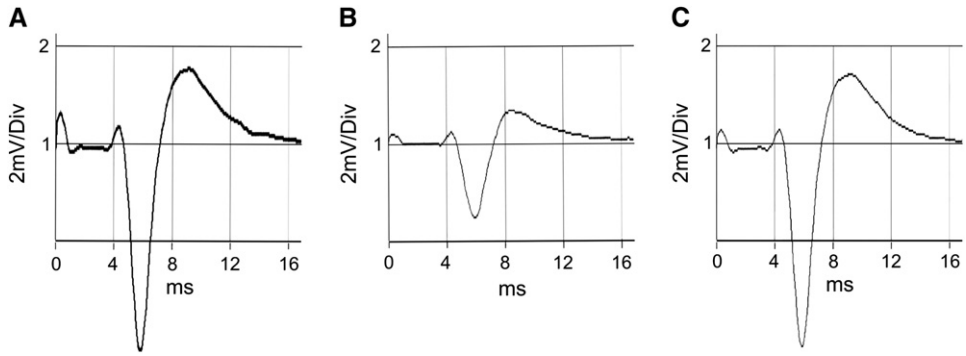

Fig 3. A, Reference signal at the beginning of the operation. **B**, Reduced signal due to pressure to RLN. **C**, Reconstitution of the signal after reducing pressure to RLN.

the current adapters of the electrodes are small and fragile and will be redesigned in future to improve their handling.

In addition to the transligamentary needle electrodes, we tested surface sensing electrodes mounted on the endotracheal tube. Our study demonstrated that surface sensing electrodes mounted on the endotracheal tube are not reliable because of their frequent dislocation and, therefore, should not be used for real time nerve monitoring.

Mechanical trauma caused by stretching or compression of the RLN is the main reason for postoperative vocal cord paralysis. Our study demonstrated that even slight pressure or stretching on the RLN was immediately detected by our real-time continuous monitoring system, and alerted the surgeon who was able to correct the problem right away. This instant feedback warning the surgeon about possible nerve injury is a very useful feature of our system, which is not present in other currently available nerve detection systems.

In conclusion, the presented technique of continuous real-time laryngeal nerves monitoring by stimulation of the vagal nerve is feasible, safe, and easy to perform. Evoked potentials of the Parynx are highly reproducible throughout surgery and can be used for real-time signal analysis with audio feedback. In addition, this new system is compatible with existing equipment and can be used as add-on with conventional nerve monitoring devices during ongoing thyroid surgery.

REFERENCES

1. Myssiorek D. Recurrent laryngeal nerve paralysis: anatomy and etiology. Otolaryngol Clin North Am 2004;37:25-44.
2. Shedd DP, Burget GC. Identification of the recurrent laryngeal nerve. Arch Surg 1966;92:861-4.
3. Snyder SK, Hendricks JC. Intraoperative neurophysiology testing of the recurrent laryngeal nerve: Plauditis and pitfalls. Surgery 2005;138:1183-92.
4. Flisberg K, Lindholm T. Electrical stimulation of the human recurrent laryngeal nerve during thyroid operation. Acta Otolaryngol 1970;63:63-7.
5. Horn D, Rötzscher VM. Intraoperative electromyogram monitoring of the recurrent laryngeal nerve: experience with an intralaryngeal surface electrode. Langenbecks Arch Surg 1999;84:392-5.
6. Kunath M, Hussock J, Marusch F, Horschig P, Gastinger I. Identification of the recurrent laryngeal nerve by intraoperative neuromonitoring. Zentralbl Chir 1999;24:641-5.
7. Thomusch O, Sekulla C, Ukkat J, Gastinger L, Lippert H, Dralle H. Quality assurance study of benign and malignant goiter. Prospective multicenter data collection regarding 7,617 patients. Zentralbl Chir 2001;126:664-71.
8. Petro ML, Schweinfurth JM, Petro AB. Transcricothyroid, intraoperative monitoring of the vagus nerve. Arch Otolaryngol Head Neck Surg 2006;132:624-8.
9. Thomusch O, Machens A, Sekulla C, et al. Multivariate analysis of risk factors for postoperative complications in benign goiter surgery: prospective multicenter study in Germany. World J Surg 2000;24:1335-41.
10. Dralle H, Sekulla C, Haerting J, et al. Risk factors of paralysis and functional outcome after recurrent laryngeal nerve monitoring in thyroid surgery. Surgery 2004;136:1310-22.
11. Zambudio AR, Rodriguez J, Riguelme J, Soria T, Canteras M, Parrilla P. Prospective study of postoperative complications after total thyroidectomy for multinodular goiters by surgeons with experience in endocrine surgery. Ann Surg 2004;240:18-25.
12. Hillermann CL, Tarpey J, Phillips DE. Laryngeal nerve identification during thyroid surgery—feasibility of a novel approach. Can J Anaesth 2003;50:189-92.
13. Scheuller MC, Ellison D. Laryngeal mask anesthesia with intraoperative laryngoscopy for identification of the recurrent laryngeal nerve during thyroidectomy. Laryngoscope 2002; 112:1594-7.
14. Khan A, Pearlman RC, Bianchi DA, Hauck KW. Experience with two types of electromyography monitoring electrodes during thyroid surgery. Am J Otolaryngol 1997;18: 99-102.
15. Chan WF, Lo CY. Pitfalls of intraoperative neuromonitoring for predicting postoperative recurrent laryngeal nerve function during thyroidectomy. World J Surg 2006;30: 806-12.

16. Robertson ML, Steward DL, Gluckman JL, Welge J. Continuous laryngeal nerve integrity monitoring during thyroidectomy: does it reduce risk of injury? Otolaryngol Head Neck Surg 2004;131:596-600.
17. Lamadé W, Meyding-Lamadé U, Buchhold C, Brauer M, Brandner R, Uttenweiler V, Motsch J, Klar E, Herfarth C. First continuous nerve monitoring in thyroid gland surgery. Chirurg 2000;71:551-7.
18. Lamadé W, Ulmer Ch, Seimer A, et al. A new system for continuous recurrent laryngeal nerve monitoring. Minim Invasive Ther Allied Technol 2007;16:149-54.
19. Hermann M, Hellebart C, Freissmuth M. Neuromonitoring in thyroid surgery: prospective evaluation of intraoperative electrophysiological responses for the prediction of recurrent laryngeal nerve injury. Ann Surg 2004;240: 9-17.
20. Otto RA, Cochran CS. Sensitivity and specificity of intraoperative recurrent laryngeal nerves stimulation in predicting postoperative nerve paralysis. Ann Otol Rhinol Laryngol 2002;111:1005-7.
21. Beldi G, Kinsbergen T, Schlumpf R. Evaluation of intraoperative recurrent nerve monitoring in thyroid surgery. World J Surg 2004;28:589-91.
22. Wheless JW, Baumgartner J. Vagus nerve stimulation therapy. Drugs Today (Barc) 2004;40:501-15.
23. Annegers JF, Coan SP, Hauser WA, Leestma J. Epilepsy, vagal nerve stimulation by the NCP system, all-cause mortality, and sudden, unexpected, unexplained death. Epilepsia 2000;4:549-53.
24. Rychlicki F, Zamponi N, Trignani R, Ricciuti RA, Iacoangeli M, Scerrati M. Vagus nerve stimulation: clinical experience in drug-resistant pediatric epileptic patients. Seizure 2006;15:483-90.