Effects of Comprehensive Swallowing Intervention on Obstructive Sleep Apnea and Dysphagia After Stroke: A Randomized Controlled Trial

Surong Qian, MD student,[a,b,1] Xiaomin Zhang, MM,[a,1] Tong Wang, PhD,[c] Lixia Zhang, MD,[d] Cuiqin Hu, MB,[c] Ruidong Jia, MM,[c] Ling Zhang, MB,[e] Xiangrong Li, MB,[e] Lixiang Yan, MB,[e] Yan Zhang, MB,[e] Jinrong Zhang, MB,[e] and Ping Yuan, MB[e]

Objective: This study aims to explore the effects of comprehensive swallowing intervention on obstructive sleep apnea (OSA) and dysphagia in stroke patients. *Methods:* We performed a randomized controlled trial in stroke patients with obstructive sleep apnea (OSA) complicated by dysphagia, divided into treatment group and control group. The treatment group underwent comprehensive swallowing intervention and received swallowing care for 4 weeks, while the control group received only swallowing care. Outcome measurements were obtained at baseline and after the 4-week intervention, evaluated by polysomnography (PSG), videoendoscopic swallowing study (VFSS) synchronized surface electromyography (sEMG), oropharyngeal magnetic resonance imaging (MRI) and swallowing assessment scales. *Results:* Sixty patients with stroke (30 treatment and 30 control) were eligible to participate in this study. There were no significant differences in any assessment between two groups at baseline. After a 4-week intervention, compared with to control group, there was a significant decrease in the apnea-hypopnea index (AHI) and oxygen desaturation index (ODI), and increased mean and minimal oxygen saturation (SaO_2), amplitudes of suprahyoid muscle group (ASUPMG) and subhyoid muscle group (ASUBMG). Moreover, the posterior palatal distance (PPD), posterior lingual distance (PLD) and minimal cross-sectional area (MCSA) were obviously elevated in the treatment group. Additionally, the scores of Gugging swallowing screen (GUSS) and VFSS were significantly increased in the treatment group, compared to control group. *Conclusions:* The comprehensive swallowing intervention had therapeutic effects on OSA and dysphagia after stroke, and the mechanism was related to enhancing oropharyngeal muscle strength and changing upper airway structure.

Keywords: Stroke—Comprehensive swallowing intervention—Obstructive sleep apnea—Dysphagia

© 2022 Elsevier Inc. All rights reserved.

From the [a]Department of Rehabilitation Medicine, The Affiliated Suzhou Hospital of Nanjing Medical University, China; [b]Suzhou Municipal Hospital, Gusu School, Nanjing Medical University, Suzhou, Jiangsu, China; [c]Department of Rehabilitation Medicine, First Affiliated Hospital of Nanjing Medical University, No.300, Guangzhou Road, Nanjing, Jiangsu 210029, China; [d]Rehabilitation Department, Jiangsu Geriatric Hospital, No.269, Jiqingmen Street, Nanjing, Jiangsu 210024, China; and [e]Department of Rehabilitation Medicine, Changzhou DE 'an Hospital, Changzhou, Jiangsu, China.

Received February 10, 2022; revision received April 12, 2022; accepted April 17, 2022.

Correspondence authors. E-mails: wangtong60621@163.com, lxzhang16@sina.com.

[1]These authors contributed equally to this work.

1052-3057/$ - see front matter

© 2022 Elsevier Inc. All rights reserved.

https://doi.org/10.1016/j.jstrokecerebrovasdis.2022.106521

Introduction

Sleep-disordered breathing (SDB) is a global disorder and obstructive sleep apnea (OSA) is its most common form.[1] The well-known complications of untreated OSA are increased risks of stroke, and 57% of stroke patients with OSA often experience fatigue and sleepiness during the day, which may influence cognitive function, social relationship, and quality of life.[2,3] In addition, stroke patients with OSA had an increased risk of death.[4,5] Therefore, it is important to identify therapies for post-stroke OSA. Presently, the gold standard for the clinical treatment of OSA is using continuous positive airway pressure (CPAP),[6] but the rate of patient compliance to this therapy was low.[7] Moreover, after stroke, sensory impairment of the face leads to more problems with mask installation, and hemiplegia may also limit the ability to adjust or remove the mask. Additionally, aphasia may have a greater impact on communication for CPAP therapy. So CPAP compliance appears to be worse in stroke patients.[6] Therefore, physical therapy for non-invasive, alternative management of OSA has been developed.[6,8] Some studies have demonstrated that physical therapy for OSA was designed to restore oropharyngeal function,[9−11] but other studies assert that physical therapy was ineffective for OSA.[12] These have led to inconsistencies in clinical practice. However, the therapeutic effect of physical therapy on poststroke OSA has not been widely studied.[13]

Due to the common pathogenesis of OSA and dysphagia, poststroke OSA was highly correlated with dysphagia.[14,15] Various imaging methods have been used to study the airways and these imaging techniques have confirmed the existence of differences in pharyngeal anatomy between patients with and without OSA.[16,17] In a previous study, surface electromyography (sEMG) showed decreased movement of the oropharyngeal muscle in stroke patients.[18] Previous studies showed that oropharyngeal muscle training could alleviate OSA severity and related symptoms.[13,19] Therefore, oropharyngeal muscle trainings may be a promising treatment strategy for stroke patients with OSA. Recently, most studies reported that Neuromuscular electrical stimulation (NMES) was effective on swallowing function in post-stroke dysphagic patients, and NMES of laryngeal muscles could induce an increase in anterior hyoid excursion, and NMES of infrahyoid muscle elevated the larynx in the superior direction.[20−22] Additionally, the external lingual muscle group, soft palate muscle group and pharyngeal muscle group are respiratory related muscles.[17] Masako training is often used for swallowing rehabilitation, and it could promote compensatory forward movement of the posterior pharyngeal wall and improve the contractibility of the pharyngeal cavity.[23,24] Therefore, comprehensive swallowing intervention of oropharyngeal muscle training and NMSE combined with Masako training, may be beneficial for stroke patients' airway obstruction and swallowing function. However, to date, there is no report on the therapeutic effects of comprehensive swallowing intervention on OSA and dysphagia in patients with stroke.

To determine the effects of comprehensive swallowing intervention on obstructive sleep apnea (OSA) and dysphagia in stroke patients. The present study focused on OSA complicated by dysphagia in stroke rehabilitation units, and used VFSS synchronized sEMG and oropharyngeal MRI to evaluate the oropharyngeal morphology, swallowing motor electrophysiology and biomechanics. We hypothesized that comprehensive swallowing intervention would have therapeutic effects on OSA and dysphagia after stroke and confirmed by oropharyngeal morphology, swallowing motor electrophysiology and biomechanics.

Methods

This study is a double-blind, randomized controlled study. It was conducted at Changzhou city rehabilitation center of the De'an branch court of the First Affiliated Hospital of Nanjing Medical University from May 2018 to March 2019. This study was approved by the ethics committee of the First Affiliated Hospital of Nanjing Medical University (Project no: 2019-SR-316) and carried out according to the institutional principles of randomized Clinical Trials (No: ChiCTR1900024309). The study was supported by the Social Development Project of Jiangsu Science and Technology Department (No: BE2017752). All participants understood the purpose of this study and provided their written informed consent prior to their participation in the study.

Subjects

Hemorrhagic or ischemic stroke patient were included with the following selection criteria:(1) 18−80 years old, (2) diagnosis via head computed tomography (CT) or magnetic resonance imaging (MRI), (3) first onset of stroke <3 months, (4) ability to participate in all evaluations, and (5) apnea-hypopnea index (AHI) >5 times/h, Gugging Swallowing Screen (GUSS) score <20 points, and detection of swallowing disorders (in the pharyngeal stage) on videoendoscopic swallowing study (VFSS).

The exclusion criteria were as follows: (1) severe stroke (NIH Stroke Scale,NIHSS) score ≥16 points), (2) severe speech disorder, (3) severe cognitive impairment (Mini-Mental State Examination, MMSE) score <9), (4) central sleep apnea (if the features of apnea are present and there is no inspiratory effort during the entire loss of airflow, central sleep apnea was considered to be present), (5) previous history of nocturnal apnea, (6) previous history of severe daytime sleepiness (Epworth Score >16), (7) previous histories of maxillofacial deformities, pharyngeal

stenosis, or nasal abnormalities; (8) previous history of CPAP treatment, and (9) severe cardiopulmonary dysfunction or acute disease (decompensated heart failure, cardiac or respiratory arrest or myocardial infarction within the previous 3 months, severe pneumonia, refractory hypertension, pneumothorax, or emphysema bulbar).

Procedures

After the baseline evaluations were performed, all patients were randomly divided into two groups using random numbers created by the computer. The random number program was managed by a physician who was blinded to the study protocol and did not participate in this study. The patients and the physiotherapist who supervised game playing were not blinded due to the nature of the study. Before and after the intervention, the patients were measured for polysomnography (PSG), surface electromyography (sEMG), oropharyngeal magnetic resonance imaging (MRI) and swallowing assessment scales.

Interventions

Both the treatment group and the control group underwent a traditional swallowing care program for a total of 4 weeks. The swallowing care included oral ice stimulation and a free water plan. An ice cotton swab was used to stimulate the bilateral isthmus, soft palate, root of the tongue, and oropharyngeal junction. A free water plan was affected to keep the patients' mouths clean; there was no restriction on the drinking of clean water. The swallowing care was performed for approximately 20 min, twice daily, 6 days a week.

The treatment group underwent comprehensive swallowing intervention, which included oropharyngeal muscle training, NMES and Masako training. The intervention lasted for 4 weeks. The comprehensive oropharyngeal muscle training was illustrated in Fig. 1. Patients were instructed to stick out their tongue, hold it for 6 s, and retract it. This procedure was repeated 15 times (1 set), and this set of training was conducted 2-3 times (Fig. 1A). Then, without ingesting water, patients puffed and relaxed their cheeks successively. This routine was repeated 15 times (1 set), and this set of training was conducted 2-3 times (Fig. 1B). Subsequently, patients brushed the superior and lateral surfaces of the teeth with the tongue, 15 repetitions per set, 2-3 sets (Fig. 1C-H). Finally, patients forced their tongue against the hard palate, pressing the entire tongue against it. This was repeated 15 times and each set of 15 repetitions was repeated 2-3 times (Fig. 1I). For Masako training, patients stretched out their tongue and gently bit it or a speech pathologist used a gloved hand to hold the tongue in place. Patients were asked to swallow while maintaining the tongue in that position. As the patient adapted to and mastered the training, the tongue was gradually extended as far as possible, to produce greater forward contraction of the pharyngeal wall, which could improve the ability of the pharyngeal muscles. Oropharyngeal muscle training and Masako training were conducted by a speech pathologist. Patients who were unable to complete the training or who did not perform the training adequately were assisted by a speech pathologist. For NMES, the 2nd generation Vital-Slim electric stimulator developed by Chanttanooga was used. Treatment parameters of NMES included waveform, bidirectional wave, 700ms wave width, and output intensity, 0-15 mV. The first electrode was placed immediately above the hyoid bone. The second electrode was placed immediately below the first electrode on the thyroid cartilage. The third and fourth electrodes were placed at an equal distance between the first two electrodes. Comprehensive swallowing intervention (oropharyngeal muscle training, 30 min; Masako training, 10 min; and neuromuscular electrical stimulation, 20 min) was performed for approximately 1 h, twice daily, 6 days a week.

Evaluation

Assessments were performed at baseline and after a 4-week intervention. These measurements were carried out by two researchers who were blinded to the patients' randomization and not involved in the administration of the study interventions.

Primary outcome measures

In this study, PSG included electroencephalography, respiratory inductance plethysmography, electrocardiography, and oxygen saturation assessment. Measurements were made using a portable PSG device (Embla, MPR PGST7X, USA). Apnea was defined as a reduction in peak signal excursion by ≥90% of the pre-event baseline that lasted for ≥10 s. Hypopnea was defined as a reduction in peak signal excursion by ≥30% for ≥10 s, with a corresponding oxygen desaturation event of ≥4%. AHI was calculated using total apnea and hypopnea events detected in hourly nightly data. Sleep apnea was diagnosed when AHI was ≥5 times/h. Respiratory events with chest and abdominal activity were obstructed, while respiratory events without chest and abdominal activity were central. If there was no inspiratory effort in the latter part of the event, it was a mixture. To distinguish OSA from central sleep apnea, mixed apnea was classified as an obstructive respiratory event.[25] In this study, we recorded AHI, oxygen desaturation index (ODI), mean oxygen saturation (mean SaO_2), and minimal oxygen saturation (minimal SaO_2) as primary outcome indicators.

Secondary outcome measures

Secondary outcome measures included surface electromyography (sEMG), Oropharyngeal MRI, VFSS and

Fig. 1. ***Oropharyngeal muscle training. A****. The patient was to stick their tongue out, hold for 6 seconds, and retract the tongue. This was repeated 15 times. This set of 15 repetitions was conducted 2-3 times.* ***B****. Without the use of water, the patients puffed out their cheeks then relaxed. This set of 15 repetitions was conducted 2-3 times.* ***C-H****.The patients brushed the superior and lateral surfaces of the teeth with the tongue: 15 repetitions per set for 2-3 sets.* ***I.*** *The patients forced their tongues upward against the palate, and pressed the entire tongue against the palate. There were 15 repetitions per set for 2-3 sets.*

GUSS scores. Electrodes were placed on the patient in the front neck position. The methods and detailed steps of sEMG were mainly based on previous studies,[26,27] including steps for standardization of sEMG assessment of normal and abnormal deglutition. In this study, when we did VFSS, we did a surface sEMG assessment. In this study, the mean and maximum amplitudes of the suprahyoid and subhyoid muscles were recorded as secondary outcome indicators.

Oropharyngeal MRI was performed using syngo.via image software (Siemens) at baseline and after intervention. Experienced neuroradiologists who were blinded to the interventions performed all the measurements. We recorded the posterior palatal distance (PPD), posterior lingual distance (PLD), and minimal cross-sectional area (MSCA) in the pharyngeal area as secondary outcome indicators, which were shown in Fig. 2A and B.

Barium sulfate powder, water, and a thickener were mixed to form a diluted liquid, thick liquid, paste, and solid food, as required. Patients successively swallowed 3, 5, and 10 mL of the mixtures. Video recording of the swallowing process was completed through the digital collection and analysis system of a swallowing angiography (LGT-4000) and gastrointestinal tract x-ray fluoroscopy machine. The swallowing condition and the degree of pharyngeal dysfunction were observed and scored, based

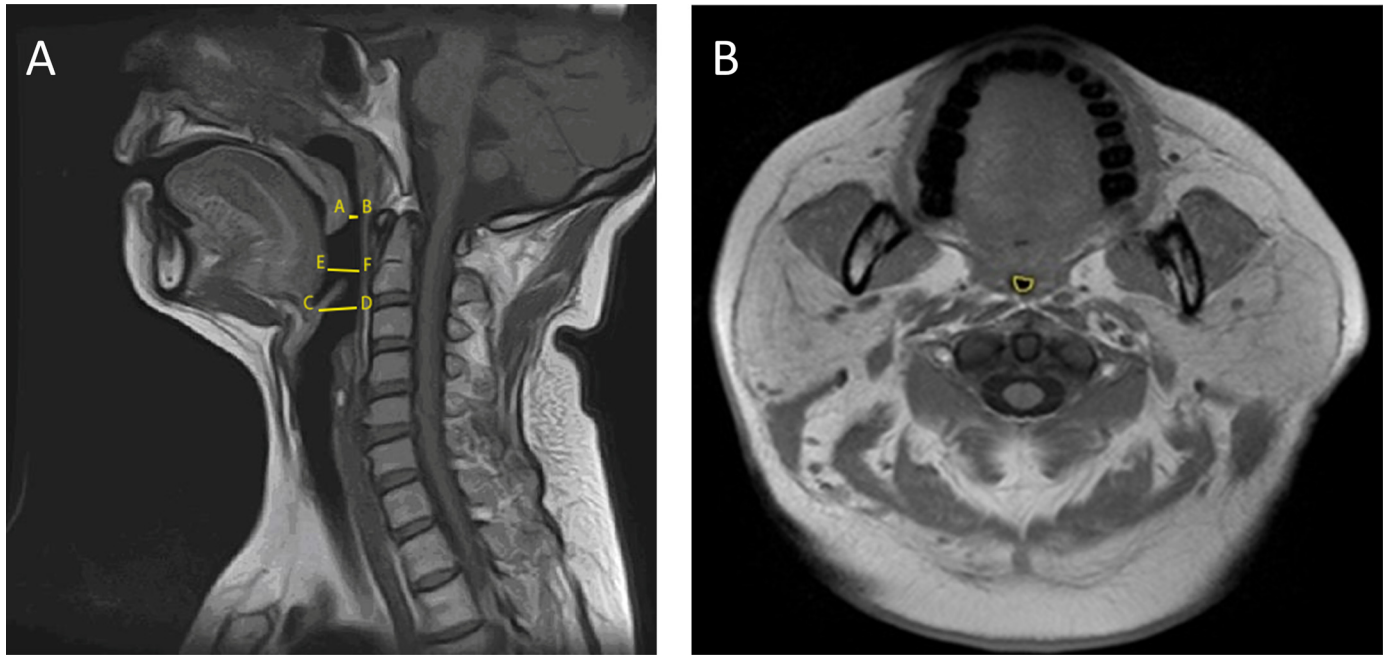

Fig. 2. ***Oropharyngeal magnetic resonance imaging of sagittal plane. A.*** *Posterior palatal distance (PPD) (**A-B**): minimum vertical distance from the soft palate to the posterior oropharyngeal wall. Posterior lingual distance (PLD) (**C-D**): vertical distance from the anterior epiglottic valley to the posterior wall of the lower pharynx.* ***B.*** *Minimal cross-sectional area.*

on the video recording. We recorded VFSS score as a secondary outcome indicator. Additionally, GUSS score was served as another outcome indicator. In this study, all patients' scores of VFSS and GUSS were compared between two groups after a 4-week intervention.

Statistical analysis

SPSS (version 24.0, IBM, NY, USA) was used for statistical analysis. Quantitative data were expressed as mean (standard deviation, SD), while Categorical data were presented as numbers (frequency). For continuous data, independent sample t-tests were used for between-group comparisons, and paired sample t-tests were used for within-group comparisons. Chi-square test was used for categorical data. $P < 0.05$ was considered statistically significant.

Results

One hundred and eighteen stroke patients with snoring complaints were screened for eligibility for this study. Of these patients, 69 patients who underwent PSG were selected. Of the 69 patients, 6 patients who were unable to complete the PSG and 3 patients who had an AHI of <5 were excluded from the study. Finally, 60 patients who met the inclusion criteria were divided into 2 groups: the treatment group (n = 30) and control group (n = 30). The background characteristics of the treatment and control groups are summarized in Table 1. At baseline, no statistically significant difference was found between the groups in terms of age, gender, BMI, neck circumference, waist circumference, days between onset to rehab unit, polysomnographic indicators, sEMG, Oropharyngeal MRI, GUSS, VFSS data and swallowing assessment scales between the two groups (all $P > 0.05$).

After a 4-week intervention, PSG, sEMG, oropharyngeal MRI and swallowing assessment scales were repeated and these results were presented in Tables 2 and 3. The PSG indicators were significantly improved in the treatment group, which included AHI, ODI, mean SaO_2, and minimal SaO_2 (all $P < 0.01$), but not in the control group (all $P > 0.05$). After the intervention, compared to control group, there was a significant decrease in the apnea-hypopnea index (AHI) ($P < 0.001$) and oxygen desaturation index (ODI) ($P = 0.002$), and increase in the mean and minimal oxygen saturation (SaO_2) ($P < 0.001$) in the treatment group.

The results of sEMG showed significant improvement in sEMG indicators, including the increased mean and maximum amplitudes of the suprahyoid and subrahyoid muscle groups, in the treatment group (all $P < 0.01$). When compared to control group, there was a significant increase in the amplitudes of mean and max suprahyoid muscle group (ASUPMG) (P=0.003,0.034), and the amplitudes of mean and max subhyoid muscle group (ASUBMG) (P=0.041, 0.014). Moreover, the results of MRI revealed significant improvement in the oropharyngeal MRI indicators in the treatment group (all $P < 0.001$). Moreover, the posterior palatal distance (PPD) ($P < 0.001$), posterior lingual distance (PLD) ($P < 0.001$) and minimal cross-sectional area (MCSA) (P=0.039) were obviously elevated in the treatment group. In addition, after the intervention, the scores of (GUSS) ($P < 0.001$) and VFSS ($P < 0.001$) were significantly increased in the treatment group after the intervention, compared to control group.

Discussion

This study mainly explored the effects of comprehensive swallowing intervention on OSA symptoms and dysphagia in stroke patients. Furthermore, oropharyngeal muscle and morphological changes in the upper airway were also investigated. In this study, comprehensive swallowing intervention mainly included oropharyngeal muscle training, Masako training and NMES After 4 weeks interventions, the improvement in OSA symptoms and dysphagia in stroke patients was observed, such as PSG indicators, VFSS and GUSS scores. Moreover, the indicators of sEMG, and oropharyngeal MRI were also improved. Therefore, these results revealed that comprehensive swallowing intervention could significantly alleviate OSA and dysphagia after stroke and confirmed by oropharyngeal morphology, swallowing motor electrophysiology and biomechanics. Therefore, these results suggest that comprehensive swallowing intervention may be a new method to treat OSA and dysphagia after stroke, and the main mechanism was related to enhancing oropharyngeal muscle strength and changing upper airway structure.

As described in previous studies,[1,28] the prevalence of OSA in stroke patients was approximately 70%, which is higher than that in the general population. Consistent with these previous studies,[1,29] we also found that there was a high proportion of patients with stroke complicated with sleep apnea. Moreover, OSA is an independent risk factor for the development of incident stroke and may also be a consequence of stroke. Therefore, it is particularly important to identify suitable treatment methods for OSA after stroke. According to previous studies,[30,31] OSA and dysphagia may share a common pathogenesis. In this study, the high prevalence of OSA and dysphagia after stroke further confirmed this theory. The main function of upper airway dilator muscles (including the mental tongue muscle, palatine velar muscle, and so on) is to maintain the position of the tongue, hyoid bone, and soft palate; resist negative pressure from the pharynx, and keep the upper airway open.[17] However, after stroke, upper airway dilator muscles lose control from higher centers, which is often manifested as insufficient tension in upper airway dilator muscles.[32] In this setting, it is difficult to maintain an open airway, causing collapse and

Table 1. *Demographic characteristics of the stroke patients.*

Variables	Control group (n = 30)	Treatment group (n = 30)	P-value
Age	61.20(10.68)	59.13(9.41)	.430[a]
Male, n (%)	25(83.33%)	22(73.33%)	.347[b]
BMI, kg/m^2	26.65(4.89)	26.77(4.98)	.927[a]
Neck circumference, cm	35.53(3.65)	37.17(3.37)	.077[a]
Waist circumference, cm	86.80(6.38)	83.83(8.14)	.122[a]
Days between onset to rehab unit, day	38.07(12.80)	41.33(11.75)	.307[a]
Medical history			
Ischemia, n (%)	26(86.67%)	27(90.00%)	.688[b]
Hypertension, n (%)	18(60.00%)	17(56.67%)	.793[b]
Diabetes, n (%)	13(43.33%)	14(46.67%)	.795[b]
Neck plate, n (%)	10(33.33%)	9(30.00%)	.781[b]
PSG			
AHI	26.07(6.01)	27.36(7.23)	.456[a]
ODI	20.68(5.72)	23.71(9.85)	.153[a]
Mean SaO_2 (%)	92.07(1.42)	92.48(1.37)	.260[a]
Minimal SaO_2 (%)	73.23(5.17)	72.42(5.05)	.542[a]
sEMG			
Mean ASUPMG	15.35(9.13)	13.21(6.21)	.443[a]
Mean ASUBMG	10.90(4.33)	10.96(4.67)	.967[a]
Max ASUPMG	38.68(13.49)	38.76(26.54)	.992[a]
Max ASUBMG	35.21(16.55)	37.68(20.90)	.724[a]
Oropharyngeal MRI			
PPD	5.36(1.81)	5.33(2.52)	.974[a]
PLD	22.96(4.76)	24.15(4.24)	.477[a]
MCSA	85.34(21.85)	84.10(15.69)	.860[a]
GUSS and VFSS			
GUSS score	10.86(1.94)	11.70(3.10)	.217[a]
VFSS score	6.27(1.14)	6.20(1.13)	.821[a]

Data are mean (SD) and frequency (%). BMI, body mass index; AHI, apnea-hypopnea index; ODI, oxygen desaturation index; mean SaO2, mean oxygen saturation; minimal SaO_2, minimal oxygen saturation; mean ASUPMG, mean amplitude of suprahyoid muscle group; mean ASUBMG, mean amplitude of subhyoid muscle group; max ASUPMG, maximum amplitude of suprahyoid muscle group; max ASUBMG, maximum amplitude of subhyoid muscle group; PPD, posterior palatal distance; PLD, posterior lingual distance; MCSA, minimal cross-sectional area. VFSS, videoendoscopic swallowing study; GUSS, Gugging swallowing screen. Values are presented as mean (standard deviation). Values are presented as mean (standard deviation); n=numbers; a=Student's t-test; b=chi-square test.

Table 2. *Measures of obstructive sleep apnea and dysphagia before and after treatment.*

	Control group			Treatment group		
	Baseline	4 weeks	P-value	Baseline	4 weeks	P-value
AHI	26.07(6.01)	25.31(4.94)	0.223	27.36(7.23)	19.08(6.88)*	<.001
ODI	20.68(5.72)	19.88(4.48)	0.433	23.71(9.85)	15.35(6.15)*	<.001
Mean SaO_2 (%)	92.07(1.42)	92.31(1.32)	0.543	92.48(1.37)	96.09(1.24)*	<.001
Minimal SaO_2(%)	73.23(5.17)	73.08(4.38)	0.893	72.42(5.05)	77.61(4.52)*	<.001
Mean ASUPMG	15.35(9.13)	15.16(8.87)	0.568	13.21(6.21)	18.40(7.40)*	<.001
Mean ASUBMG	10.90(4.33)	11.28(4.74)	0.575	10.96(4.67)	15.67(7.09)*	<.001
Max ASUPMG	38.68(13.49)	34.69(16.03)	0.063	38.76(26.54)	54.12(32.97)*	<.001
Max ASUBMG	35.21(16.55)	33.52(10.24)	0.679	37.68(20.90)	44.42(31.63)*	.004
PPD	5.36(1.81)	5.45(1.67)	0.409	5.33(2.52)	9.07(0.92)*	<.001
PLD	22.96(4.76)	22.57(3.58)	0.736	24.15(4.24)	29.17(3.32)*	<.001
MCSA	85.34(21.85)	84.30(21.82)	0.641	84.10(15.69)	98.21(11.87)*	<.001
GUSS score	10.86(1.94)	11.30(1.89)	0.641	11.70(3.10)	15.93(1.33)*	<.001
VFSS score	6.27(1.14)	6.47(1.01)	0.051	6.20(1.13)	8.20(1.03)*	<.001

Data are mean (SD), *$P < 0.05$ Baseline vs. 4 weeks in treatment group.

Table 3. *Differences in obstructive sleep apnea and dysphagia before and after treatment between the groups after treatment.*

	Control group	Treatment group	*P*-value
AHI	25.31(4.94)	19.08(6.88)	<.001
ODI	19.88(4.48)	19.26(5.06)	.002
Mean SaO_2 (%)	92.31(1.32)	96.09(1.24)	<.001
Minimal SaO_2 (%)	73.08(4.38)	77.61(4.52)	<.001
Mean ASUPMG	15.16(8.87)	18.40(7.40)	.003
Mean ASUBMG	11.28(4.74)	15.67(7.09)	.041
Max ASUPMG	34.69(16.03)	54.12(32.97)	.034
Max ASUBMG	33.52(10.24)	44.42(31.63)	.014
PPD	5.45(1.67)	9.07(0.92)	<.001
PLD	22.57(3.58)	29.17(3.32)	<.001
MCSA	84.30(21.82)	98.21(11.87)	.039
GUSS score	11.30(1.89)	15.93(1.33)	<.001
VFSS score	6.47(1.01)	8.20(1.03)	<.001

Data are mean (SD).

obstruction of the upper airway after stroke.[33] Moreover, upper airway dilator muscles comprise a muscle group that is closely related to the swallowing function.[34] Furthermore, stroke patients complicated with OSA and dysphagia existed abnormal changes in oropharyngeal morphology.[35] Therefore, changes in upper airway structure will simultaneously affect breathing and swallowing functions. In this study, we aimed to determine the effects of comprehensive swallowing intervention on OSA and dysphagia after stroke by using VFSS synchronized sEMG and oropharyngeal MRI.

In this study, compared to other upper airway muscle training interventions for OSA in the literature,[12,13,36] the four movements we selected in the oropharyngeal muscle training routine in this study train the tongue and soft palate. Among them, the first (Fig. 1A) and third (Fig. 1C–H) movements train the genioglossus (extends the tongue), styloglossus (raises and retracts the tongue), and other extralingual muscle groups. In Masako training, patients were required to stretch their tongue and gently bite it. Therefore, the first training in this study was also to prepare the patients for Masako training. The second (Fig. 1B) and fourth (Fig. 1I) movements strengthen the soft palate, that is, the soft palate muscle group, such as the palatal sail levator and palatal sail tension. In addition, Neuromuscular electrical stimulation (NMES) was effective on swallowing function in post-stroke dysphagic patients,[20–22] and Masako training could promote compensatory forward movement of the posterior pharyngeal wall and improve the contractibility of the pharyngeal cavity.[23,24] Above all, comprehensive swallowing intervention could produce positive structural changes in the upper respiratory tract, which further improve dysphagia and OSA in stroke patients.

At present, subjective scales and PSG are widely used to evaluate OSA.[37] PSG is the gold standard for diagnosing and evaluating OSA and the result of PSG is more relatively accurate than that of scales.[25] Therefore, in this study, PSG monitoring was mainly used to evaluate the OSA symptoms of patients, and AHI, ODI and oxygen saturation of PSG indicators were served as the main observation indicators. We found that the combined swallowing intervention significantly reduced the values of AHI and ODI, as well as improved oxygen saturation and alleviated symptoms of nocturnal sleep apnea. Simultaneously, the scores of GUSS and VFSS scale were significantly improved, and the swallowing function of patients was significantly improved. Therefore, comprehensive swallowing intervention has a good therapeutic effect on OSA and dysphagia in stroke patients. In addition, comprehensive swallowing intervention has a good compliance in stroke patients.

In order to further explore the mechanism of comprehensive swallowing intervention on OSA and dysphagia in stroke patients, we used oropharyngeal MRI and VFSS synchronized sEMG to evaluate oropharyngeal morphology, swallowing motor electrophysiology and biomechanics. The oropharyngeal MRI could accurately assess the oropharyngeal morphology in stroke patients with OSA and dysphagia.[35] The VFSS is the gold standard for the diagnosis of dysphagia and could dynamically evaluate the whole swallowing process.[38] The method of sEMG can be used for quantitative analysis of motor electrophysiological indicators in terms of time, amplitude and timing of local muscle group activity mode during swallowing movement, but it cannot evaluate overall swallowing function.[39] Therefore, we used oropharyngeal MRI and VFSS synchronized sEMG technologies to accurately evaluate oropharyngeal morphology, swallowing motor electrophysiology and biomechanics in stroke patients with OSA and dysphagia. The results of our study showed that the comprehensive swallowing intervention could significantly improve the strength of the swallowing muscles, widen the distance between the back of the palate and the back of the tongue, increase the minimum area of the pharynx, and improve the upper airway

structure. This study further confirmed that the mechanism of comprehensive swallowing intervention may be related to enhancing oropharyngeal muscle strength and changing upper airway structure.

The present study had some limitations. First, for a single-center study, the sample size of the study was small; thus, it was difficult to conduct a subgroup analysis to examine the effects of different age groups, stroke types, and severities of OSA. A larger sample size is required to verify the clinical curative effects of the intervention. Second, most of the enrolled patients had moderate OSA (AHI 15-30); thus, the therapeutic efficacy of this intervention in mild and severe OSA should be further investigated. Finally, CPAP is the clinically recommended treatment for OSA and we could not compare the therapeutic efficacy of our intervention with that of CPAP owing to limited resources. We suggest that this important comparison be conducted in future studies.

In conclusion, the comprehensive swallowing intervention had therapeutic effects on OSA and dysphagia after stroke, and the mechanism was related to enhancing oropharyngeal muscle strength and changing upper airway structure. The results suggest that the administration of comprehensive swallowing intervention may be an alternative therapeutic strategy for OSA complicated by dysphagia in stroke patients.

Declaration of Competing Interest

The authors declare that the research was conducted in the absence of any commercial or financial relationships that could be construed as a potential conflict of interest.

Acknowledgements: The study was supported by the Social Development Project of Jiangsu Science and Technology Department (No: BE2017752), and this study was conducted in the rehabilitation medicine department of the De'an branch court of the First Affiliated Hospital of Nanjing Medical University.

References

1. Heinzer R, Vat S, Marques-Vidal P, et al. Prevalence of sleep-disordered breathing in the general population: the HypnoLaus study. Lancet Respir Med 2015;3:310-318.
2. Aaronson J, van Bennekom C, Hofman W, et al. Obstructive sleep apnea is related to impaired cognitive and functional status after stroke. Sleep 2015;38:1431-1437.
3. Das AM, Khan M. Obstructive sleep apnea and stroke. Expert Rev Cardiovasc Ther 2012;10:525-535.
4. Bassetti CL, Milanova M, Gugger M. Sleep-disordered breathing and acute ischemic stroke: diagnosis, risk factors, treatment, evolution, and long-term clinical outcome. Stroke 2006;37:967-972.
5. Cherkassky T, Oksenberg A, Froom P, et al. Sleep-related breathing disorders and rehabilitation outcome of stroke patients: a prospective study. Am J Phys Med Rehabil 2003;82:452-455.
6. Ramar K, Dort L, Katz S, et al. Clinical practice guideline for the treatment of obstructive sleep apnea and snoring with oral appliance therapy: an update for 2015. J Clin Sleep Med 2015;11:773-827. JCSM: official publication of the American Academy of Sleep Medicine.
7. Rotenberg B, Murariu D, Pang K. Trends in CPAP adherence over twenty years of data collection: a flattened curve. J otolaryngol Head Neck Surg 2016;45:43.. = Le Journal d'oto-rhino-laryngologie et de chirurgie cervico-faciale.
8. Zaidi F, Meadows P, Jacobowitz O, et al. Tongue anatomy and physiology, the scientific basis for a novel targeted neurostimulation system designed for the treatment of obstructive sleep apnea. Neuromodul J Int Neuromodul Soc 2013;16:376-386. discussion 386.
9. Guimarães K, Drager L, Genta P, et al. Effects of oropharyngeal exercises on patients with moderate obstructive sleep apnea syndrome. Am J Respir Crit Care Med 2009;179:962-966.
10. Ieto V, Kayamori F, Montes M, et al. Effects of oropharyngeal exercises on snoring: a randomized trial. Chest 2015;148:683-691.
11. Diaféria G, Santos-Silva R, Truksinas E, et al. Myofunctional therapy improves adherence to continuous positive airway pressure treatment. Sleep Breathing Schlaf Atm 2017;21:387-395.
12. Nemati S, Gerami H, Soltanipour S, et al. The effects of oropharyngeal-lingual exercises in patients with primary snoring. Eur Arch Oto-Rhino-Laryngol 2015;272:1027-1031. official journal of the European Federation of Oto-Rhino-Laryngological Societies (EUFOS): affiliated with the German Society for Oto-Rhino-Laryngology - Head and Neck Surgery.
13. Ye D, Chen C, Song D, et al. Oropharyngeal muscle exercise therapy improves signs and symptoms of post-stroke moderate obstructive sleep apnea syndrome. Front Neurol 2018;9:912.
14. Bhutada AM, Broughton WA, Focht Garand KL. Obstructive sleep apnea syndrome (OSAS) and swallowing function-a systematic review. Sleep Breath 2020;24:791-799.
15. Wallace ES, Bhutada MA, Broughton WA, Eckert DJ, Garand K. Knowledge, attitudes, and practice patterns of obstructive sleep apnea among speech-language pathologists. Sleep Breath 2021. https://doi.org/10.1007/s11325-021-02481-2. [published online ahead of print, 2021 Sep 29].
16. Fusco G, Macina F, Macarini L, et al. Magnetic resonance imaging in simple snoring and obstructive sleep apnea-hypopnea syndrome. La Radiol Med 2004;108:238-254.
17. Schwab R, Gupta K, Gefter W, et al. Upper airway and soft tissue anatomy in normal subjects and patients with sleep-disordered breathing. Significance of the lateral pharyngeal walls. Am J Respir Crit Care Med 1995;152:1673-1689.
18. Giannantoni N, Minisci M, Brunetti V, et al. Evaluation of pharyngeal muscle activity through nasopharyngeal surface electromyography in a cohort of dysphagic patients with acute ischaemic stroke. Acta Otorhinolaryngol Italica 2016;36:295-299. *organo ufficiale della Societa italiana di otorinolaringologia e chirurgia cervico-facciale*.
19. Verma R, Johnson JJ, Goyal M, et al. Oropharyngeal exercises in the treatment of obstructive sleep apnoea: our experience. Sleep Breathing Schlaf Atm 2016;20:1193-1201.

20. Beom J, Kim SJ, Han TR. Electrical stimulation of the suprahyoid muscles in brain-injured patients with dysphagia: a pilot study. Ann Rehabil Med 2011;35:322-327.
21. Nam HS, Beom J, Oh BM, et al. Kinematic effects of hyolaryngeal electrical stimulation therapy on hyoid excursion and laryngeal elevation. Dysphagia 2013;28:548-556.
22. Ludlow CL, Humbert I, Saxon K, et al. Effects of surface electrical stimulation both at rest and during swallowing in chronic pharyngeal Dysphagia. Dysphagia 2007;22:1-10.
23. Logemann JA. Treatment of oral and pharyngeal dysphagia. Phys Med Rehabil Clin N Am 2008;19:803-816. ix.
24. Karsten RT, Ter Beek LC, Jasperse B, et al. MRI assessment of swallow muscle activation with the swallow exercise aid and with conventional exercises in healthy volunteers: an explorative biomechanical study. Dysphagia 2021;36:41-53.
25. Kapur VK, Auckley DH, Chowdhuri S, et al. Clinical practice guideline for diagnostic testing for adult obstructive sleep apnea: an American academy of sleep medicine clinical practice guideline. J Clin Sleep Med 2017;13:479-504.
26. Vaiman M. Standardization of surface electromyography utilized to evaluate patients with dysphagia. Head Face Med 2007;3:26.
27. Vaiman M, Eviatar E. Surface electromyography as a screening method for evaluation of dysphagia and odynophagia. Head Face Med 2009;5:9.
28. Arnardottir E, Bjornsdottir E, Olafsdottir K, et al. Obstructive sleep apnoea in the general population: highly prevalent but minimal symptoms. Eur Respir J 2016;47:194-202.
29. Camilo M, Fernandes R, Sander H, et al. Supine sleep and positional sleep apnea after acute ischemic stroke and intracerebral hemorrhage. Clinics 2012;67:1357-1360. (Sao Paulo, Brazil).
30. Friberg D, Ansved T, Borg K, et al. Histological indications of a progressive snorers disease in an upper airway muscle. Am J Respir Crit Care Med 1998;157:586-593.
31. Paulsen FP, Steven P, Tsokos M, et al. Upper airway epithelial structural changes in obstructive sleep-disordered breathing. Am J Respir Crit Care Med 2002;166:501-509.
32. North JB, Jennett S. Abnormal breathing patterns associated with acute brain damage. Arch Neurol 1974;31:338-344.
33. Harbison J, Ford GA, James OF, et al. Sleep-disordered breathing following acute stroke. QJM 2002;95:741-747.
34. Jobin V, Champagne V, Beauregard J, et al. Swallowing function and upper airway sensation in obstructive sleep apnea. J Appl Physiol (1985) 2007;102:1587-1594.
35. Zhang L, Wu Q, Zhang Q, et al. The correlation of pharyngeal morphology and obstructive sleep apnea in patients with recent stroke. Panminerva Med 2019;61:495-498.
36. Verma RK, Johnson JJ, Goyal M, et al. Oropharyngeal exercises in the treatment of obstructive sleep apnoea: our experience. Sleep Breath 2016;20:1193-1201.
37. Lee JJ, Sundar KM. Evaluation and management of adults with obstructive sleep apnea syndrome. Lung 2021;199:87-101.
38. Martin-Harris B, Jones B. The videofluorographic swallowing study. Phys Med Rehabil Clin N Am 2008;19:769-785. viii.
39. Zhu M, Yu B, Yang W, et al. Evaluation of normal swallowing functions by using dynamic high-density surface electromyography maps. Biomed Eng Online 2017;16:133.