# Mapping the Compound Muscle Action Potentials of Cricothyroid Muscle Using Electromyography in Thyroid Operations

## *A Novel Method to Clinically Type the External Branch of the Superior Laryngeal Nerve*

*Ben Selvan, MS,* Srinivasa Babu, PhD,† M. J. Paul, MS,‡§ Deepak Abraham, MS,‡§ Prasanna Samuel, MSc,¶ and Aravindan Nair, MS‡*

**Objective:** Variations of the external branch of the superior laryngeal nerve (EBSLN) are well represented in literature but with conflicting reports about the types and variations. Using EMG, the cricothyroid compound muscle action potential (CMAP) was recorded, to identify the EBSLN and classified them according to clinical variation during routine thyroid operations.

**Summary Background Data:** There is increasing awareness among patients and physicians of the consequences of injury to the external laryngeal nerve in thyroid surgeries. There are at least 4 types, which are described in the literature.[1] The gold standard of nerve identification is EMG, which we used during operations in this study to identify all the EBSLN by demonstrating CMAP and reclassify them. Based on this principle, to avoid injury during thyroidectomy, we propose a new classification.

**Methods:** This study was a prospective, descriptive study of the EBSLN done during elective thyroidectomy operations. CMAP was demonstrated and EMG was plotted to identify and type them according to clinical variations. The distance between the entry of superior thyroid vessels (STVs) to the lobe and the EBSLN, relationship with the cricothyroid muscle and inferior constrictor muscle were taken into consideration. Based on the possible risk to this during thyroidectomy, we divided them into 4 types.

**Results:** A total of 70 external laryngeal nerves were dissected and confirmed by the CMAPs in 35 total thyroidectomy patients. Using CMAPs, all the nerves were identified.

Ia. The nerve can be found within 1 cm from the entry of the vessels into the gland either anterior or intertwined to the STVs or within 3 cm from the cricoid cartilage.

Ib. The nerve can be found posterior to the vessels but within 1 cm from the entry of the STV into the gland. This entry point was close to the anterior insertion line of the CT muscle onto cricoid cartilage.

II. Nerve can be found within 1 to 3 cm from the entry of the vessels into the gland or within 3 to 5 cm from the cricoid cartilage.

III. Nerve can be found between 3 and 5 cm from the entry of the vessels into the gland or more than 5 cm from the cricoid cartilage.

**Conclusion:** New clinical typing of the EBSLN will give a better understanding of the EBSLN in the intraoperative period. EBSLN need not be identified in routine thyroidectomy operations. Even in large goiters, the incidence of nerve at risk does not increase significantly. Injury to EBSLN can be avoided if the principle of ligating the STVs individually away from the CT muscle and close to the capsule of the gland is followed.

From the Departments of *Surgery, †NeuroPhysics, ‡General, §Endocrine Surgery, and ¶Biostatistics, Christian Medical College, Vellore, Tamilnadu.

Reprints: Ben Selvan, MS, Department Surgery, Christian Medical College, Vellore, North Arcot Dt, Vellore, Tamilnadu 632004, India. E-mail: drckben@gmail.com.

Copyright © 2009 by Lippincott Williams & Wilkins

ISSN: 0003-4932/09/25002-0293

DOI: 10.1097/SLA.0b013e3181b17342

**Key Words:** external laryngeal nerve, compound muscle action potentials, cricothyroid muscle, electromyography external laryngeal nerve clinical classification, Selvan's clinical types

(*Ann Surg* 2009;250: 293–300)

This was a prospective study of the external branch of the superior laryngeal nerve (EBSLN) done during routine thyroidectomy operations. Electromyography (EMG) was used to identify and map the nerve according to clinical variations by recording the compound muscle action potential (CMAP).

This clinical research was done to type the EBSLN that will facilitate intraoperative identification and aimed to answer the following questions:

What is the anatomic relation of the external laryngeal nerve to the superior thyroid pole and what percentage of the nerves are at risk? Are the visually identified fibers always the nerve?

Is a neurostimulator required in routine thyroid operations to identify the EBSLN? Can CMAP be used to identify the EBSLN more accurately and arrive at a new clinical typing?

## BACKGROUND

There is an increasing awareness among patients and physicians of the consequences of injury to the EBSLN. There are at least 4 anatomic types that are described in the literature.[1] For the identification of any nerve, the gold standard is EMG. There is no consensus of opinion regarding the variation in the course of this nerve. There is a significant percentage of failure to identify this nerve in various studies. The external laryngeal nerve is the motor nerve of the cricothyroid, which is a tensor of the vocal fold. Injury induces different voice problems, often transitory. The injury to EBSLN caused by thyroid operations was recognized as early as 1987.[2]

Published literature from studies on patients and cadavers are conflicting anatomic types and injuries. Less than 5% of patients had a reduced quality of life scores caused by the injury to this nerve. However, for patients where voice is important in their profession, it is critical to avoid injury to the EBSLN.

## MATERIALS AND METHODS

This prospective, descriptive clinical research study of the EBSLN was carried out during elective thyroidectomy operations. CMAP was demonstrated and EMG was plotted to identify and type the nerve according to clinical variations.

### Institutional Review Board Clearance Was Obtained and All Patients Were Consented for the Study

Mapping of 70 EBSLN using EMG and recording the CMAP in 35 consecutive patients undergoing total thyroidectomy was carried out.



Copyright © Lippincott Williams & Wilkins. Unauthorized reproduction of this article is prohibited.

## Inclusion Criteria

All patients with benign and malignant thyroid disease requiring total thyroidectomy.

## Exclusion Criteria

1. Previous thyroid or other major operations of the neck.
2. Large and clinically infiltrating thyroid cancer.
3. Previous history of radiation to the neck.

To demonstrate the absence of skeletal muscle paralysis before recording CMAP, anesthetist was asked to maintain 2 to 3 twitches to a train of 4 twitches (TOF) in response to peripheral nerve stimulation at the time of identification of the EBSLN.

Skin incision was made, flaps were raised, fascia opened, and strap muscles were retracted. The middle thyroid vein was ligated, the recurrent laryngeal nerve was identified, and the inferior thyroid vessels were ligated. The avascular cricothyroid space (space between the superior thyroid vessel [STV] and medially the larynx, which is relatively avascular) was dissected and an attempt was made to find the EBSLN. Part of the cricothyroid muscle was delineated through this space. The thyroid lobe was dissected off the cricothyroid muscle and the EBSLN was identified visually. If the nerve was not found, then the posteromedial or superomedial part of the muscle was dissected. The first assistant, who was either senior resident or a consultant surgeon, was asked to identify the nerve. An intraoperative monitoring machine (Nicolet Endeavor, Fig. 1) was used for stimulation and recording of the CMAP. The recording sub dermal needle electrodes were placed in the cricothyroid muscle, 1 cm apart. The ground electrode was placed close to the operating field such as the skin flap. Another set of recording electrodes are placed in the sternocleidomastoid muscle on the same side (control). Stimulus was delivered using concentric bipolar probe. The rate of stimulation was 4.7 Hz, 200 microseconds pulse width. The stimulus strength was set at 0.5 mA and this was not escalated. The first assistant (a qualified surgeon or a trainee) was asked to identify the first dissected nerve, which seemed to be the one going into the cricothyroid muscle. If this structure was not confirmed to be the EBSLN, further dissection was carried out until the visualized structure was confirmed to be EBSLN by global contraction of the cricothyroid muscle. CMAP was demonstrated and EMG was plotted to identify and type the nerve according to clinical variations. When the visually identified nerve did not evoke any CMAP and the corresponding EMG mapping in the Nicolet Endeavor machine, then the dissection was continued to get the nerve so that the stimulation of it mapped the typical EMG in the machine as depicted in Figures 1 and 2.

**FIGURE 1.** Nicolet endeavor machine recording the cricothyroid muscle CMAP and plotting the EMG during intraoperative recording.

The stimulation was done with 0.5 mA in all the patients. Once the nerve was confirmed with the CMAP, the entry point of the STVs to the upper pole was defined and the distance between this point and the EBSLN entering the CT muscle were measured by Vernier calipers. Measurement also was taken from the cricoid cartilage (fixed point at the anterior insertion line of the cricothyroid muscle on the cricoid cartilage) to the point of nerve entry into the CT muscle. Thyroid lobe was placed in the anatomic location before taking the measurement. All the nerves were photographed and the details were recorded. Following the identification of the nerve, the thyroidectomy proceeded as planned. The procedure was repeated on the other side.

## Statistical Analysis

Categorical variables were summarized using frequencies and percentages. The association between categorical variables and clinical types of EBSLN were examined using $\chi^2$ test after adjusting for the paired nature of the data 26. A $P$ value of 0.05 was considered statistically significant. All analysis was done using STATA 8.0.

# RESULTS

A total of 70 external laryngeal nerves were dissected and confirmed by the CMAP in 35 total thyroidectomy patients. Using CMAP, all the nerves were identified. Gland weight >100 g were present in 29% of the patients and the rest were <100 g (Table 1). Muscle relaxants did not interfere in identification of the nerve by this method. The electrical stimulus was focal and did not spread to other regions as confirmed by the control and stimulus contraction seen in only one muscle and not in others. The nerve was thin and less than 0.55 mm in more than 50 nerves (80%). Based on the distance between the entry of the STVs to EBSLN and cricoid cartilage, we divided EBSLN into 4 clinical types. The average additional time required to plot the EMG was 20 minutes (range: 15–30 minutes) together for both the sides.

## Current Classification Scheme (Selvan's EBSLN Types)

1a. Nerve that was located within 1 cm of the entry of the vessels into the gland either anterior or between the branches of the STVs and within 3 cm from the cricoid cartilage (9%) (Fig. 3).

1b. Nerve that was located posterior to the vessels but within 1 cm of the entry of the STV into the gland. This entry point is close to the anterior insertion line of the CT muscle onto cricoid cartilage (3%) (Fig. 4).

2. Nerve that was located within 1 to 3 cm of the entry of the vessels into the gland or within 3 to 5 cm from the cricoid cartilage (68%) (Fig. 5).

3. Nerve that was located between 3 and 5 cm of the entry of the vessels into the gland or more than 5 cm from the cricoid cartilage (20%) (Fig. 6).

In our series, the nerve was not found in the avascular space of cricothyroid in 17% of type 1a nerves, 100% of type 1b, 19% of type 2, 50% of type 3 (Table 2). To avoid inter observer bias, the first assistant who was a trainee or a consultant surgeon was asked to identify the structure, which was identified to be the EBSLN without the EMG confirmation (Table 3) Identification characteristics include:

1. The fiber should have the oblique course along the CT and/or inferior constrictor muscle.


© 2009 Lippincott Williams & Wilkins
Copyright © Lippincott Williams & Wilkins. Unauthorized reproduction of this article is prohibited.

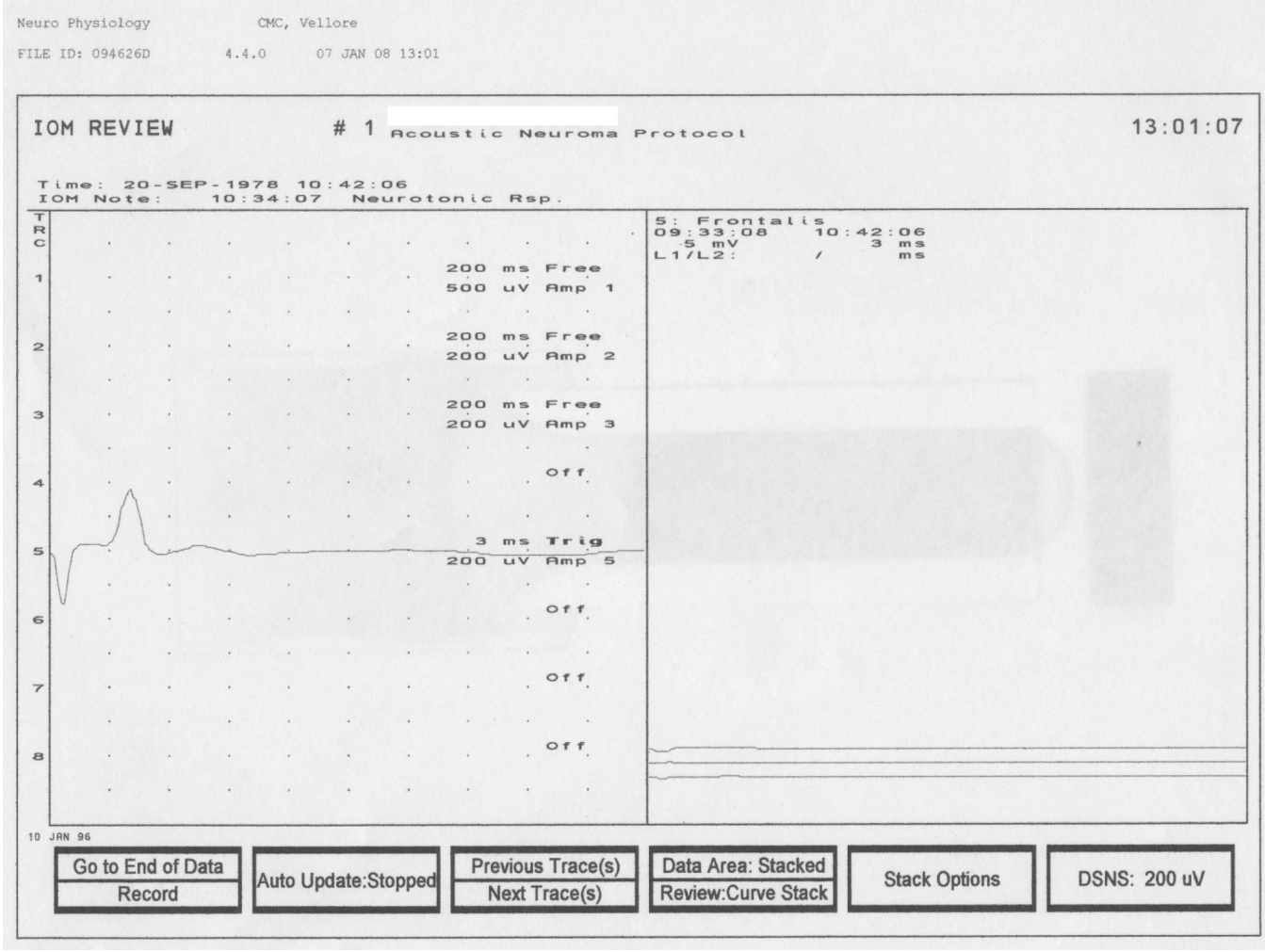


**FIGURE 2.** Graphic representation of the CMAP on the monitor with smooth bell-shaped EMG with 0.5 mA.

**TABLE 1.** Relationship of Different Nerves to the Weight of the Gland

| | Type | | | | |
|---|---|---|---|---|---|
| **Weight (g)** | **1a** | **1b** | **2** | **3** | ***P*** |
| <100 | 5 (10%) | 1 (2%) | 35 (70%) | 9 (18%) | |
| ≥100 | 1 (5%) | 1 (5%) | 13 (65%) | 5 (25%) | |
| Total | 6 (8.6%) | 2 (2.9%) | 48 (68.5%) | 14 (20%) | 0.78 |

The table showing percentage of different types of EBSLN according to the mean weight of the gland range 100 to 300 g.

2. The fiber should be ending in the CT muscle.

Not surprisingly, majority of the nerves were not visualized in the avascular cricothyroid space, especially type 3. From our experience, this variety can be missed in thyroid operations as they are quite high up but not at increased risk. The nerve in type 2 and 3 were either superficial to or within the fascia over the CT muscle. In 21% of type 2 and in 57% of type 3, the fascia had to be teased open to find the nerve (Table 4). In 10% of type 2 and 50% of type 3, the nerve was found either within the CT or inferior constrictor muscle.

In majority of the patients, type 2 nerve was on the CT muscle or in the junction between the CT muscle and the inferior constrictor (Table 5). When the nerve was not found in avascular cricothyroid space, they were seen in the posteromedial or superomedial aspect of the CT muscle.

In type 1a, the entire nerve lies within the STV, either between or superficial to the STV. In 1b, the nerve comes posterior to the STV and entered the CT at its insertion on the cricoid cartilage anteriorly, which can be easily missed and injured in thyroid operations (Table 6).

## DISCUSSION

The external laryngeal nerve is an important structure to be preserved in any thyroid surgery. The search for identifying a consensus for the different types started as early as 1872, by Sappey in cadavers[1] and the extent of injury secondary to thyroid operations was recognized as early as 1987.[2]

### Identification of the EBSLN

However, conflicting types and percentage of the injury pattern varies between articles depending on the study subjects (live patients or cadavers).[3] This is probably because the identification rates of these nerves in thyroidectomy itself vary from 20% to 90%.[4,5]



Copyright © Lippincott Williams & Wilkins. Unauthorized reproduction of this article is prohibited.

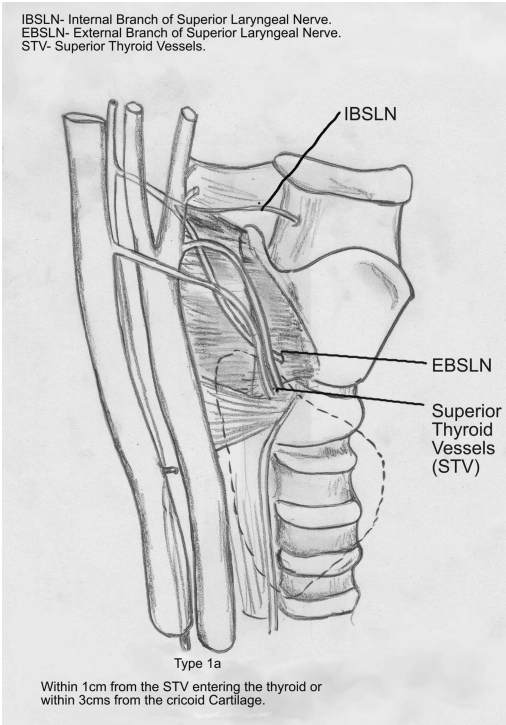


**FIGURE 3.** This type 1a EBSLN was anatomically placed within 1 cm of the entry of the vessels into the gland either anterior or between the branches of the superior thyroid vessels (STV) and within 3 cm from the cricoid cartilage (9%).

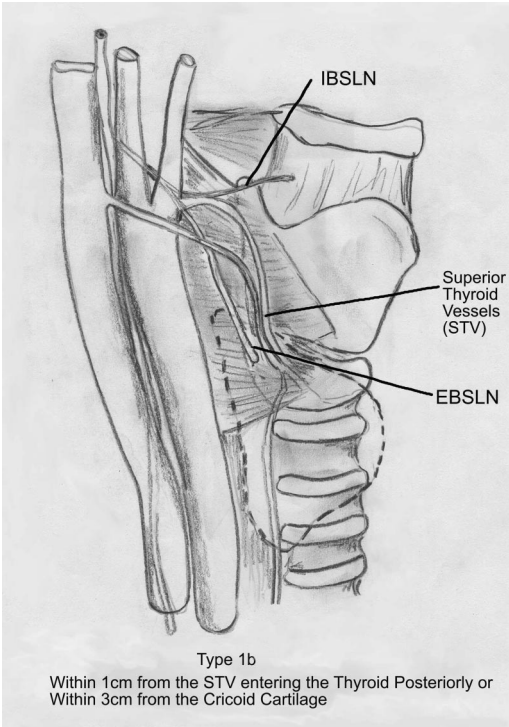


**FIGURE 4.** This type 1b EBSLN was anatomically located posterior to the vessels but within 1 cm of the entry of the STV into the gland. This entry point is close to the anterior insertion line of the CT muscle onto cricoid cartilage (3%).

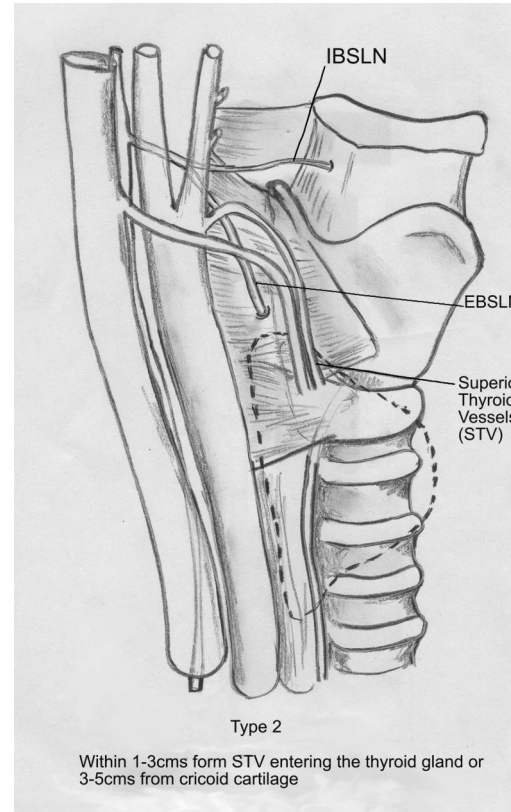


**FIGURE 5.** This type 2 EBSLN was anatomically located within 1 to 3 cm of the entry of the vessels into the gland or within 3 to 5 cm from the cricoid cartilage (68%).

With the advent of nerve stimulator, the rate of identification is still not appreciable in most studies, which ranges from 20% to 90%.[4,6] In a study done by Friedman et al, no specific method or criteria was used to differentiate the findings of direct muscle stimulation and that of EBSLN stimulation. The stimulus strength used was 2 mA current, which can lead to a high rate of false identification due to global stimulation of the CT.[6] Even in cadaveric studies, classifications and the identification rates are also different. Mu's study[7] on cadavers described variations that are very different from other studies. In another cadaveric study,[8,9] type 2 was 36% but according to the Cernea et al classification it was 60%[10] and in Kierner's study, 30%.[11] In our series, the nerve identification was 100% and we have attempted to redefine the variations and retype them according to the EMG findings, which is the gold standard (Table 7).

One of the limitations to identify this nerve intraoperatively is due to the advent of mini incision thyroidectomy, which is being practiced these days. In this approach, the extent of exposure during thyroidectomy is limited. Hence, due to size of this thin nerve or when it is within the muscles, there is high possibility of wrongly identifying a muscle fiber as nerve or it may not be visualized at all.

Studies on the anatomy of the EBSLN have quoted the identification rate from 58% to 95%. From this table, it is evident that the identification rates are highly operator dependant and varies widely even with the use of neurostimulator. Interestingly in our study, 79% of the time the first identified fiber did not correspond to the nerve in type 3. It was one of the structures as described below:

(1) A thin non neural fiber. (2) The tendinous fibers of CT or inferior constrictor muscles. (3) Rarely a communication between

 © 2009 Lippincott Williams & Wilkins

Copyright © Lippincott Williams & Wilkins. Unauthorized reproduction of this article is prohibited.

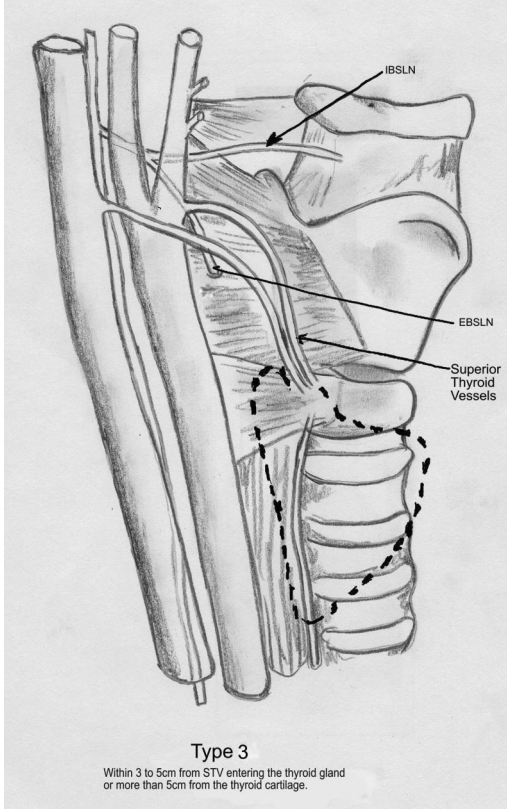


**FIGURE 6.** This type 3 EBSLN was anatomically located between 3 to 5cm of the entry of the vessels into the gland or more than 5 cm from the cricoid cartilage (20%).

**TABLE 2.** Percentage of Different Types of Nerves in the Avascular Space

| Avascular space | Type 1a | 1b | 2 | 3 | *P* |
|---|---|---|---|---|---|
| Yes | 5 (83.4%) | 0 (0%) | 39 (81.3%) | 7 (50%) | |
| No | 1 (16.6%) | 2 (100%) | 9 (18.8%) | 7 (50%) | |
| Total | 6 (8.6%) | 2 (2.9%) | 48 (68.5%) | 14 (20%) | 0.01 |

The percentage of EBSLN in the Reeve space varies according to types. Interestingly, the percentage of the nerve seen within the avascular space is limited as the EBSLN types move away from type 1.

**TABLE 3.** Relationship Between the Visual Identification of Nerve by the First Assistant and the Chance of it Being False Positive With EMG Recording of CMAP as Gold Standard

| | Type 1a | 1b | 2 | 3 | *P* |
|---|---|---|---|---|---|
| 1 | 5 (83.3%) | 1 (50.0%) | 41 (85.4%) | 3 (21.4%) | |
| 2 | 1 (16.7%) | 1 (50.0%) | 7 (14.6%) | 11 (78.6%) | |
| Total | 6 (8.6%) | 2 (2.9%) | 48 (68.5%) | 14 (20.0%) | 0.001 |

The visually identified nerve by the first assistant was verified by the EMG. The table depicts various EBSLN types and the chance of it being a fiber rather than the actual nerve which was confirmed by the EMG. The assistant was either a surgeon or senior resident. The table 1 depicts first assistant identification rates and 2 indicates the EMG confirmation.

**TABLE 4.** Relationship of the Nerve to the Cricothyroid Fascia

| Fascia | Type 1a | 1b | 2 | 3 | *P* |
|---|---|---|---|---|---|
| Within the fascia | 1 (16.4%) | 0 (0%) | 10 (20.8%) | 8 (57.1%) | |
| Over the fascia | 5 (83.6%) | 2 (100%) | 38 (79.1%) | 6 (42.8%) | |
| Total | 6 (8.6%) | 2 (2.9%) | 48 (68.5%) | 14 (20%) | 0.05 |

The cricothyroid fascia was a thin layer of tissue on its muscle and this table demonstrates the position of the EBSLN to the fascia.

**TABLE 5.** Relationship of the Nerve to the Cricothyroid and Inferior Constrictor Muscle

| Muscle | Type 1a | 1b | 2 | 3 | *P* |
|---|---|---|---|---|---|
| Within muscle | 2 (33.3%) | 0 (0%) | 11 (22.9%) | 7 (50%) | |
| Over the muscle | 4 (66.7%) | 2 (100%) | 37 (77.1%) | 7 (50%) | |
| Total | 6 (8.6%) | 2 (2.9%) | 48 (68.5%) | 14 (20.0%) | 0.30 |

The relationship of EBSLN to cricothyroid muscle and inferior constrictor muscle was taken in to consideration. There was a thin layer of fascia over these muscles. This fascia was teased and the nerve was searched within the muscle bundles. This table gives the percentage nerve within or on the surface of the muscle according to the types.

the afferent fibers that mediate impulses from the cricothyroid joint and the mucous lining inside the cricothyroid membrane.[12,13]

This was more applicable when the search was made within the muscle or fascia over the muscle. Furthermore, some authors have described supplementary motor innervations of some of the intrinsic laryngeal muscles by the EBSLN[8,13] giving a false positive identification.

The percentage of initially identified fiber which does not yield EMG tracings corresponds to the percentage of failed identification in some series. This graphic representation was seen as a smooth bell shaped curve as demonstrated in Figure 2. This particular finding is also confirmed in a large study[14] where 14% of the visually identified structure did not evoke a CT muscle contraction using a neurostimulator. These EBSLN which failed detection can be found when one continues the dissection, to either superomedial or inferomedial aspect of the CT. The location of the nerve is well described to be in the avascular space of cricothyroid (between the STV and larynx), the space where EBSLN is commonly identified.[15–17] Opening up this space is limited at times due to the branches of the STV entering the larynx. The area of the avascular space in a given patient also varies. Apart from these limitations, the percentage of the nerve seen within the avascular space is limited as the EBSLN types move away from type 1, which was seen in our series (Table 2). This particular aspect and its various types is not addressed by earlier articles as this can also modify the location of the nerve. In Table 2, it is shown that this space was used to find up to 80% of the EBSLN in type 1a and 2, where 50% of type 3 cannot be found in this space. This may form a guideline for a researcher, but for a clinician this space can be used to dissect the STV and the superior pole away from the CT to avoid injury, rather than identifying it as the majority of the nerves in a clinical scenario are types 1a and 2 which forms up to 75%.

## Flaws in the Identification of EBSLN

There are also conflicting studies on whether to identify the EBSLN before ligating the superior pole vessels or not. But


Copyright © Lippincott Williams & Wilkins. Unauthorized reproduction of this article is prohibited.

**TABLE 6.** EBSLN Classification

| Cernea (Cadaver) | Kierner (Cadaver) | Criteria | Friedman (Live) | Selvan (Live) | Criteria |
|---|---|---|---|---|---|
| Type 1 (68% SG, 23% LG) | Type1 (42%) | Crosses STA >1 cm above upper pole | Superficially to the inferior constrictor (IC) muscle | Type 1a 5 (17%) | Within 1 cm from the entry of the vessels into the gland either anterior or intertwined to STV or within 3 cm from cricoid cartilage |
| Type 2a (14% SG, 15% LG) | Type 2 (30%) | Crosses STA <1 cm above upper pole | Deep to the inferior constrictor muscle (1 cm proximal to the IC–CT junction). | Type 1b 2 (10%) | Posterior to the vessels, within 1 cm from the entry of the STV close to insertion of cricothyroid muscle |
| Type 2b (14% SG, 54% LG) | Type 3 (14%) | Crosses STA under cover of upper pole | | Type 2 9 (19%) | Within 1–3 cm from the entry of the STV into the gland. Or within 3–5 cm from cricoid cartilage |
| Not described | Type 4 (14%) | Descends dorsal to STA and crosses the STA in the upper pole | Deep to the inferior constrictor muscle | Type 3, 7 (50%) | 3–5 cm from the entry of the STV into the gland. Or more than 5 cm from cricoid cartilage |

SG indicates small goiter; LG, large goiter.

**TABLE 7.** EBSLN Identification Rate (ID Rate)

| Source | Evaluation Method | ID Rate % | Stimulus Strength |
|---|---|---|---|
| Jonas and Bahr | Neuromonitoring | 37.8 | — |
| Lore et al | Intraoperative | 33 | — |
| Teitelbaum and Weing | Intraoperative | — | — |
| Aina et al | Nerve stimulator | 88 | 2 mA |
| Jansson et al | Intraoperative | — | — |
| Lennquist et al | Inspection of the CT muscle | 72 | — |
| Lekacos et al | Intraoperative | — | — |
| Kark et al | Intraoperative | 84 | — |
| Reeve et al | Intraoperative | 59 | — |
| Friedman et al | Nerve stimulator | 90 | 2 mA |
| Selvan et al | On table electromyography and CMAP recording | 100 | 0.5 mA |

we have found that the identification of these nerves usually can be difficult and wrongly interpreted because of the following reasons:

1. Type 1b (2.86%) that is posterior can be missed.
2. In type 2, 19% and in type 3, 50% were not found in avascular cricothyroid space.
3. Visually identified fiber by the fellow surgeon was not corresponding to the nerve in 15% in type 2 and 79% in type 3. Muscle dissection was critical in identifying a high percentage of these types, possibly a cause of lower reported identification in previous studies.[4,5]
4. When the nerve was not found in avascular cricothyroid space, it was either found superomedial or posteromedial to the CT. Access to this area may be limited especially when performing minithyroidectomy.
5. In video endoscopic surgeries, the incidence of identification is between 50% and 65%. Even with magnification, in 35% to 40% of the patients, the nerve is not identified routinely.[18]

From this study we conclude that, injury to the EBSLN can be avoided by ligating the STV on the thyroid capsule after releasing the upper pole from its loose areolar attachment to the CT. Importantly, the posterior dissection of the gland to release the upper pole from the cricothyroid muscle needs to be emphasized which will help to delineate the vessels to ligate them individually. Identification of EBSLN may not be applicable in all cases, especially in type 2 and 3; more over there is a paradigm shift in the skin incision length and endoscopic techniques. In a randomized study, where 1 group operated with ligation of the STV on the capsule and in the other group the STV was ligated after the identification of EBSLN; the injury pattern was evaluated by stroboscopic methods and it was reported that there was no difference in injury rate between the 2 groups.[19]

## Anatomic Typing of the EBSLN

In most studies, the uncertainty about the location of the nerve is a well-accepted fact. There are at least 3 studies done on cadavers, which also have contradicting variations in types.[7,11,20.] The types described by Kierner et al and Cernea et al are cadaver based classification.[10,11,22] They are different from other clinical types like Friedman's type.[21] It is important to define clearly the relationship of the STV to the upper pole of the thyroid gland which can vary according to the size and the morphology of the patients. The vessels run medially and enter the pole at its midpoint; more over the upper pole can also vary in size. So the enlarged superior pole position may vary when one compares its relation to larynx and the cricothyroid muscle. Clinically, the vessels (STV) enter the gland much medial and this point becomes critical in preserving the EBSLN (Fig. 7).[23]

In Cernea's classification, the superior thyroid pole (upper pole) was used as a land mark, which can vary with patient's morphology, size of the superior pole, and the overall gland size. This would have lead on to variations in EBSLN types with different studies. The superior pole of the thyroid does not have any attachment except loose areolar tissue around the pole, which may be attached to the CT, inferior constrictor muscle, and prevertebral fascia. This can be dissected off with gentle blunt techniques.[9] To make the intraoperative assessment easier and safer to avoid injury to EBSLN, we have used the entry point of the vessels on to the upper pole as one of the land mark. We have also taken into account the distance from the anterior insertion line of the cricothyroid muscle on the cricoid cartilage, a fixed referral point which can be constant in patients.

In Friedman's types, the cricothyroid-inferior constrictor junction was taken as the land mark for the classification. In thyroid operation, it may be difficult to define this area especially with small

 © 2009 Lippincott Williams & Wilkins

Copyright © Lippincott Williams & Wilkins. Unauthorized reproduction of this article is prohibited.

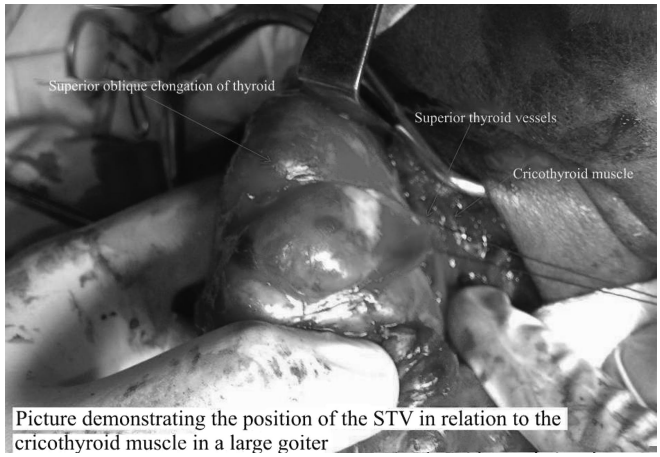


**FIGURE 7.** Intraoperative picture demonstrating the supra oblique elongation of the upper pole of the thyroid and the STV entry point was much lower, medical and relatively constant when it was compared with the superior pole.

incision thyroidectomy. The strength of the neurostimulator used in this study was 2 mA. The stimulation of tissue surrounding the CT or CT itself with this 2 mA can bring a global contraction, as an escalated current was used in this study. This might lead to false localization of the nerve especially the type 2 and 3.[21]

In Kierner type, the land mark used was the bifurcation of the common carotid artery and tracing the superior laryngeal nerve from the Vagus nerve, which was found on an average 4.18 cm distance in the cranial direction. In thyroid operations, it may be cumbersome to identify the common carotid bifurcation and tracing the superior laryngeal nerve.[11]

Type 1b need to be mentioned specially as in our opinion, this is the nerve at highest risk of injury and fortunately it was found in <3%. This type 1b comes posterior to STV and gets in to the anterior insertion line of CT on the cricoid cartilage. This can be easily missed in a thyroid operation and ligated with the posterior branch of the STVs.

Type 2 nerves can also be at risk especially when the STV is ligated high or if there is unusual enlargement of the upper pole and sufficient attention is not given to dissect the pole from the CT. This can be avoided either by ligating the vessels individually and flush with the gland apart from the usage of blunt dissection to free the upper pole of the gland from CT.

In type 1a and 2, 15% of the nerves were identified wrongly. The chance of identifying these 2 types intraoperatively is quite high and it is statistically significant (Table 3). In addition, only 20% were within the muscle and 80% were seen over the CT fascia (Tables 4, 5). These factors lead to higher identification rates of these 2 types in other series.[16] Type 3 is quite safe as it is high and can hardly be damaged, unless in a locally advanced carcinoma where there is extra thyroidal or nodal disease. Type 3 is quite difficult to recognize as the chance of identifying it wrongly is quite high. In our study as described in Table 3, one can make a wrong identification up to 80%. Statistically, the chance of identifying it wrongly is significant ($P < 0.001$). This was mainly due to the fact that the 50% of the nerve were found either within the CT or inferior constrictor muscle (Table 5). In addition, 60% of the nerve was found within the cricothyroid fascia (Table 4). From these observations, the author concludes that as the types increase the identification rates drops and the chance of false positive rate escalates.

In minimally invasive video-assisted thyroidectomy, a procedure introduced by Miccoli et al in 1998[18] the 30 degree endoscope allows easier identification of the EBSLN, giving a magnified view of the "critical space (avascular space)" during selective ligation of the upper pedicle. They were able to visualize the EBSLN only in 65% of cases.

## Does the Type Vary as the Gland Weight Increases?

In a study involving 13 nerves, Cernea quoted as having a higher incidence of type 2b, an increase from 20% to 54%, according to Cernea classification.[1,24] We had 29% patients with gland weight more than 100 g. We have not found any statistically significant escalation in types (Table 1). The distance between the EBSLN and cricoid cartilage (as a fixed point) also was measured as described. The pattern of different types of nerve is not very different. But in a study done among patients with large goiters by Lopez et al in which the EBSLN injury was evaluated by postoperative EMG, the incidence of nerve damage was quoted as high.[25] But Friedman who compared the injury rate of different authors felt it did not correspond to the weight of the gland.[21] In a randomized study, the injury rate did not increase with the increase in gland weight.[19] This particular finding contradicts the findings of Cernea in which Type 2 EBSLN incidence was increased by 34% with large goiters where the average weight was 435 g. In clinical practice, one comes across rarely with such gland weight. Morton et al also mentioned the decreased reliability of Cernea typing with increased thyroid size and its irrelevance in cases of "buried " variants.[26] In a randomized study, there was no difference in EBSLN injury rate according to the weight of the gland.[27]

Anatomically, the pretracheal fascia and the sternothyroid muscle get attached to the oblique line of thyroid cartilage, which prevents the upper pole of the thyroid gland from extending onto the thyrohyoid muscle; the upper pole also is approximately conical.[9] In goiters, the fascia stretches only to occupy the gland. The entry of STV in to the thyroid gland may not change unless the gland is very large or there is a large lymphoglandular disease; more over the STV enters the gland more medially. The lobe enlarges over the lateral aspect of the STV (Fig. 7). In our experience, the type of nerve does not change significantly with the weight of the gland (range: 100–300 g).

Neuromonitoring of the EBSLN in routine thyroid operations is done in some selected centers. The rate of identification varies. There are reports which mention that the identification rate can be increased by routine use of neurostimulator,[28] but these studies have used endotracheal and CT electrode placement. Placing the electrode in the vocal cord can evoke global stimulation, which can give an alarmingly high false positive rate which is used in different studies to monitor the EBSLN. In a study by Grant et al, using endotracheal electrode and plotting the EMG to monitor recurrent laryngeal nerve, there were 7 false-negative (14%) and 2 false-positive (4%) electromyographic findings.[29] The placement of vocal electrode may not be an ideal position to identify the EBSLN. In a study done by Dackiw et al, using an endotracheal electrode in an attempt to identify the EBSLN, there were tone recorded while dissecting the STV, suggesting possible conduction through the RLN or, perhaps, retrograde conduction through the Vagus nerve.[17] There were also suggestion that a "communicating nerve" and a second source of motor innervation to the thyroarytenoid muscle other than the RLN.[12,13] In a meta analysis by Dralle et al, a comment was made on the limitation of neuromonitoring in preventing recurrent laryngeal nerve injury. In this article, he quoted that neuromonitoring has high negative predictive values (NPV; 92%–100%), but relatively low and variable positive predictive values (PPV; 10%–90%), limiting its utility for intraoperative RLN management.[29,30] In a randomized study using 2 groups, one group identified the nerve and then ligated the STV individually and the other group ligated the STV individually on the gland, did not find any difference in the EBSLN injury rate.[27] In another large study, 14% of the EBSLN

© 2009 Lippincott Williams & Wilkins

Copyright © Lippincott Williams & Wilkins. Unauthorized reproduction of this article is prohibited.

were not identified with the help of neurostimulator,[14] but this may be helpful in recurrent goiters or locally advanced goiters with large lymphoglandular disease. But still the basic principle of dissecting of the upper pole away from the CT and then ligating the STV individually on the thyroid capsule has to be followed.

## Merits of the Current Classification Scheme (Selvan's EBSLN Types)

1. In our study, the identification rate of EBSLN was 100%, which was a significant factor to include all possible variations.
2. Demonstration of current types was done during thyroidectomy operations. The confirmation of the EBSLN was done by mapping (EMG) the CMAP generated from cricothyroid muscle, by stimulating the external laryngeal nerve. EMG, the method considered to be the gold standard to identify the motor nerve was not used in the previous studies.[9,21] The strength of current used in our study to record the EMG was 0.5 mV, which implies that the probe was directly over the nerve and there were no intervening tissues. In Friedman classification,[21] the strength current used to stimulate the EBSLN via a neurostimulator was 2 mA.
3. Cricoid bone is one of the prominent structures to be encountered in thyroidectomy operations and we have used this as one of the landmark to type the EBSLN. This could help a researcher to reproduce the types. More over in Friedman's type, the cricothyroid-inferior constrictor junction was taken as the land mark and its clinical application is limited as in thyroid operation it may be difficult to define this area especially with mini incision thyroidectom**y.**
4. The second referral point used in our classification was the entry point of STV to the thyroid lobe. This is crucial land mark in large goiters as the EBSLN injury can be avoided if the ligation of STV is done individually away from the CT and on the capsule of the lobe. The false positive identification rate was higher as the EBSLN moved away from the superior pole (type 2 and 3).

## CONCLUSION

New EBSLN clinical classification using CMAP of the cricothyroid muscle, will give a better understanding of the EBSLN in the intraoperative period. Importantly, this study identifies type 1a, 1b, 2, and 3 classifications for the EBSLN, of which the type 1b is at the greatest risk during ligation of the STVs in thyroidectomy operations. EBSLN need not be identified in routine thyroidectomy operations as the false positive results can be significant. Even in large goiters, the incidence of nerve at risk does not increase if one can stick to the principle of ligating the STVs individually and close to the capsule of the gland. Further the technique of separating the superior pole completely from the cricothyroid muscle before ligating the STVs individually needs to be emphasized to reduce the injury risk.

## REFERENCES


1. Sappey PC. Nerf laryngé supérieur. In: Sappey PC, ed. *Traitè d'anatomie; Nerologie: Organes Es Sens*. 2nd ed. Paris, France: Delahaye; 1872:350–352.
2. Lennquist S, Cahlin C, Smeds S. The superior laryngeal nerve in thyroid surgery. *Surgery*. 1987;102:999–1008.
3. Espinoza J, Hamoir M, Dhem A. Preservation of the external branch of the superior laryngeal nerve in thyroid surgery. An anatomic study of 30 dissections. *Ann Otolaryngol Chir Cervicofac*. 1989;106:127–134.
4. Page C, Laude M, Legars D, et al. The external laryngeal nerve: surgical and anatomic considerations. Report of 50 total thyroidectomies. *Surg Radiol Anat*. 2004;26:182–185.
5. Ozlugedik S, Acar HI, Apaydin N, et al. Surgical anatomy of the external branch of the superior laryngeal nerve. *Clin Anat*. 2007;20:387–391.
6. Jörg J, Rainer B. Neuromonitoring of the external branch of the superior laryngeal nerve during thyroid surgery. *Am J Surg*. 2000;179:234–236.
7. Mu L, Sanders I. The human cricothyroid muscle: three muscle bellies and their innervation patterns. *J Voice*. In press.
8. Lemere F. Innervation of the larynx. *Am J Anat*. 1932;51:417–437.
9. Williams PL, Warwick R, Dyson M, et al, eds. *Bannister, Gray's Anatomy*. 37th ed. 1989, London, Churchill Livingstone:1459.
10. Cernea CR, Ferraz AR, Nishio S, et al. Surgical anatomy of the external branch of the superior laryngeal nerve. *Head Neck*. 1992;14:380–383.
11. Kierner AC, Aigner M, Bur1an M. The external branch of the superior laryngeal nerve its topographical anatomy as related to surgery of the neck. *Arch Otolaryngol Head Neck Surg*. 1998;124:301–303.
12. Kreyer R, Pomaroli A. Anastomosis between the external branch of the superior laryngeal nerve and the recurrent laryngeal nerve. *Clin Anat*. 2000; 13:79–82.
13. Wu BL, Sanders I, Mu L, et al. The human communicating nerve: an extension of the external superior laryngeal nerve that innervates the vocal cord. *Arch Otolaryngol Head Neck Surg*. 1994;120:1321–1328.
14. Loch-Wilkinson TJ, Stalberg PL, Sidhu SB, et al. Nerve stimulation in thyroid surgery: is it really useful? *ANZ J Surg*. 2007;77:377–380.
15. Aina EN, Hisham AN. External laryngeal nerve in thyroid surgery: recognition and surgical implications. *ANZ J Surg*. 2001;71:199.
16. Aina EN, Hisham AN. External laryngeal nerve in thyroid surgery: is the nerve stimulator necessary? *Eur J Surg*. 2001;167:662–665.
17. Dackiw AP, Rotstein LE, Clark OH. Computer-assisted evoked electromyography with stimulating surgical instruments for recurrent/external laryngeal nerve identification and preservation in thyroid and parathyroid operation. 2002;132:1100–1108.
18. Berti P, Materazzi G, Miccoli M, et al. Visualization of the external branch of the superior laryngeal nerve during video-assisted thyroidectomy. *J Am Coll Surg*. 2002;195:573–574.
19. Bellantone R, Boscherini M, Lombardi CP, et al. Is the identification of the external branch of the superior laryngeal nerve mandatory in thyroid operation? Results of a prospective randomized study. *Surgery*. 2001;130:1055–1059.
20. Rocha de Oliveira L, Lázaro da Silva A. Superior laryngeal nerve anatomy in corpses not preserved in formaldehyde. Contribution to the operative technique. *Acta Cir Bras.* 2007;22:220-228.
21. Friedman M, LoSavio P, Ibrahim H. Superior laryngeal nerve identification and preservation in thyroidectomy. *Arch Otolaryngol Head Neck Surg*. 2002;128:296–303.
22. Cernea CR, Ferraz AR, Furlani J, et al. Identification of the external branch of the superior laryngeal nerve during thyroidectomy. *Am J Surg*. 1992;164: 634–639.
23. Brunicardi FC, Anderson DK, BIlliar TR, et al, eds. *Schwartz's Principles of Surgery*. 8th ed. 2004, USA, McGraw-Hill Professional Publishing:1399.
24. Cernea CR, Nishio S, Hojaij FC. Identification of the external branch of the superior laryngeal nerve (EBSLN) in large goiters. *Am J Otolaryngol*. 1995;16:307–311.
25. Hurtado-Lopez LM, Pacheco-Alvarez MI, Montes-Castillo Mde L, et al. Importance of the intraoperative identification of the external branch of the superior laryngeal nerve during thyroidectomy: electromyographic evaluation. *Thyroid.* 2005;15:449–454.
26. Morton RP, Whitfield P, Al-Ali S. Anatomical and surgical considerations of the external branch of the superior laryngeal nerve: a systematic review. *Clin Otolaryngol*. 2006;31:368–374.
27. Bellantone R, Boscherini M, Lombardi CP, et al. Is the identification of the external branch of the superior laryngeal nerve mandatory in thyroid operation? Results of a prospective randomized study. 2001;130:1055–1059.
28. Zentralbl Chir. Identification and surgical anatomy of the external branch of the superior laryngeal nerve. 2002;127:425–428.
29. Yarbrough D, Thompson G, Kasperbauer J, et al. Grant Intraoperative electromyographic monitoring of the recurrent laryngeal nerve in reoperative thyroid and parathyroid surgery. *Surgery*. 2004;136:1107–1115.
30. Dralle H, Sekulla C, Lorenz K, et al. Intraoperative monitoring of the recurrent laryngeal nerve in thyroid surgery. *World J Surg*. 2008;32:1358–1366.


 © 2009 Lippincott Williams & Wilkins

Copyright © Lippincott Williams & Wilkins. Unauthorized reproduction of this article is prohibited.