Patient: Runjhun Kumari 20-Jan-2017 (3 yrs)
Recorded: Wednesday, January 29, 2020 1:26:55 PM
Heart Rate: 141 bpm **Duration:** 30s

Instant Analysis: Possible atrial fibrillation

AliveCor

Mains filter: 50Hz Scale: 25mm/s, 10mm/mV

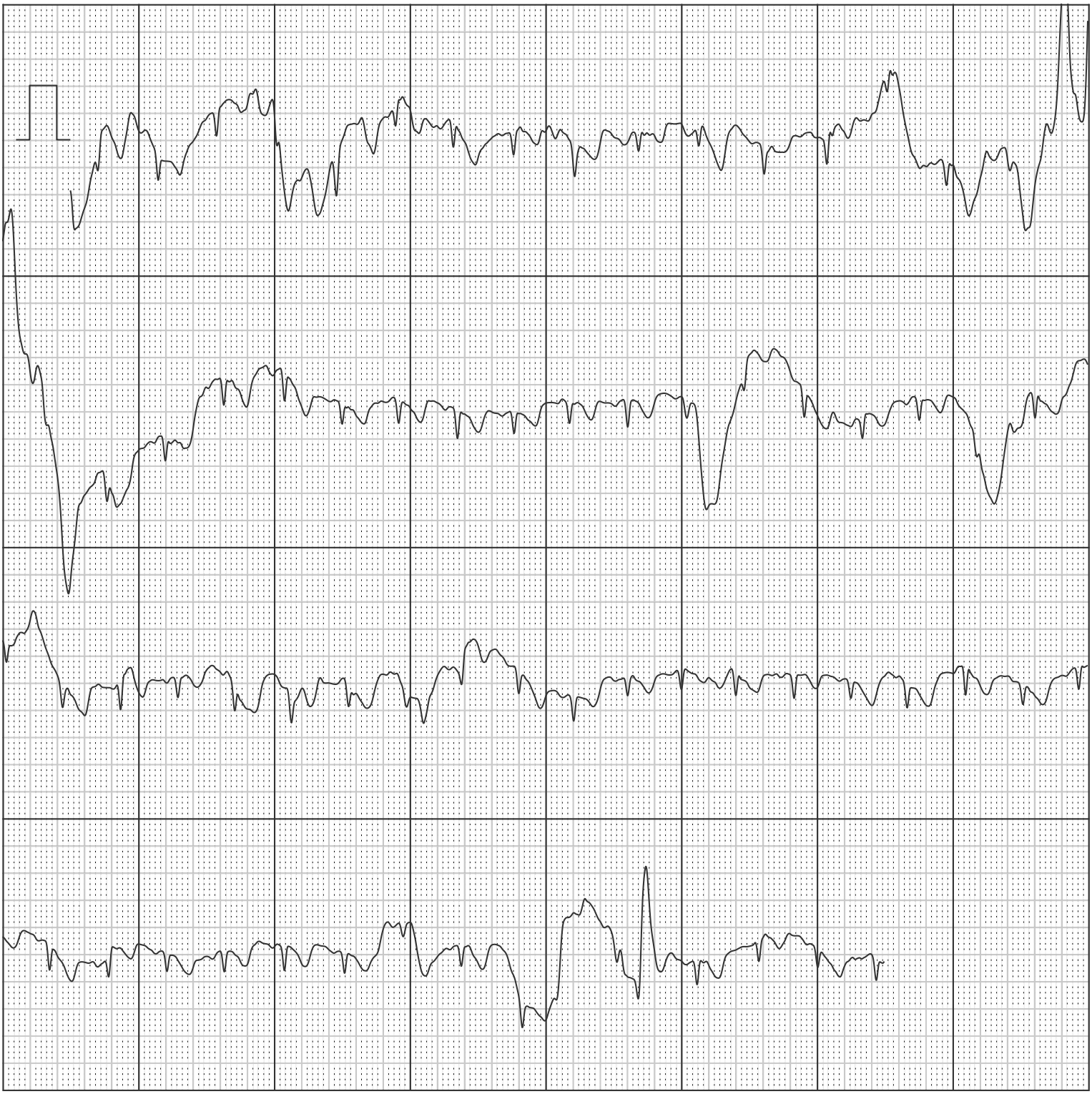

© 2020, AliveCor, aliveecg 5.7.4-06029d739, UUID: 64965e49-7984-49e7-a515-a6d49ffed312 / ebrff3gbhgu0anlaihaksanx0