Explain the structures of muscular tissues with one example each
Difference between skeletal, smooth and cardiac muscle

Muscular tissues are of three types

1. Skeletal muscle tissue
2. Cardiac muscle tissue
3. Smooth muscle tissue

Structure

Characteristics	Skeletal muscle	Cardiac muscle	Smooth muscle
Appearance	Long cylindrical fiber, multinucleated, striated	Branched cylindrical fiber, uni or bi nucleated, striated. *Each muscle are separated by intercalated disc, which help in combining each cardiac muscle cell, this assist in transmitting the nerve impulses throughout the heart during contraction.*	Fiber is thick in middle and tapered at ends, single nucleus, non striated
Location	Attached to bones	Heart	Walls of GIT, blood vessels, respiratory system
Connective tissue	Endomesyium, perimysium and epimysium	Endomysium	Endomysium
Sarcoplasmic reticulum	Abundant	Little	Very little
Autorythmicity	No	Yes	Yes
Speed of contraction	Fast	Moderate	Slow
Nervous control	Volunatary(somatic nervous system)	Involuntary(ANS)	Involuntary(ANS)
Neurotransmitter	Acetylcholine	Acetylcholine and noradrenalin	Acetylcholine and noradrenalin

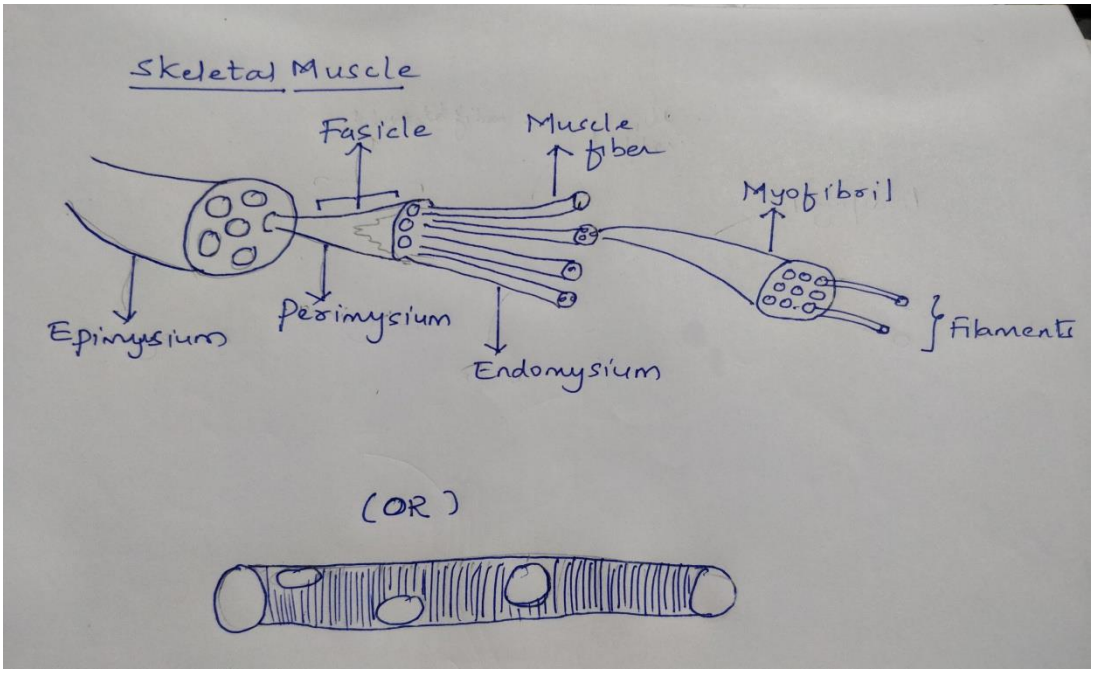
Skeletal Muscle
Fasicle
Muscle fiber
Myofiboil
Epimysium
Perimysium
Endomysium
filaments
(OR)


Cardiac Muscle

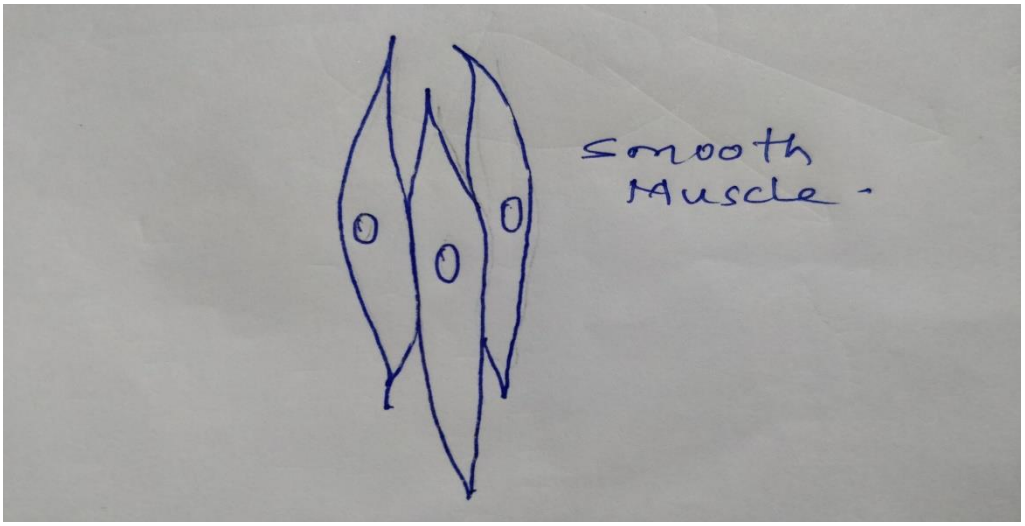
Smooth Muscle.