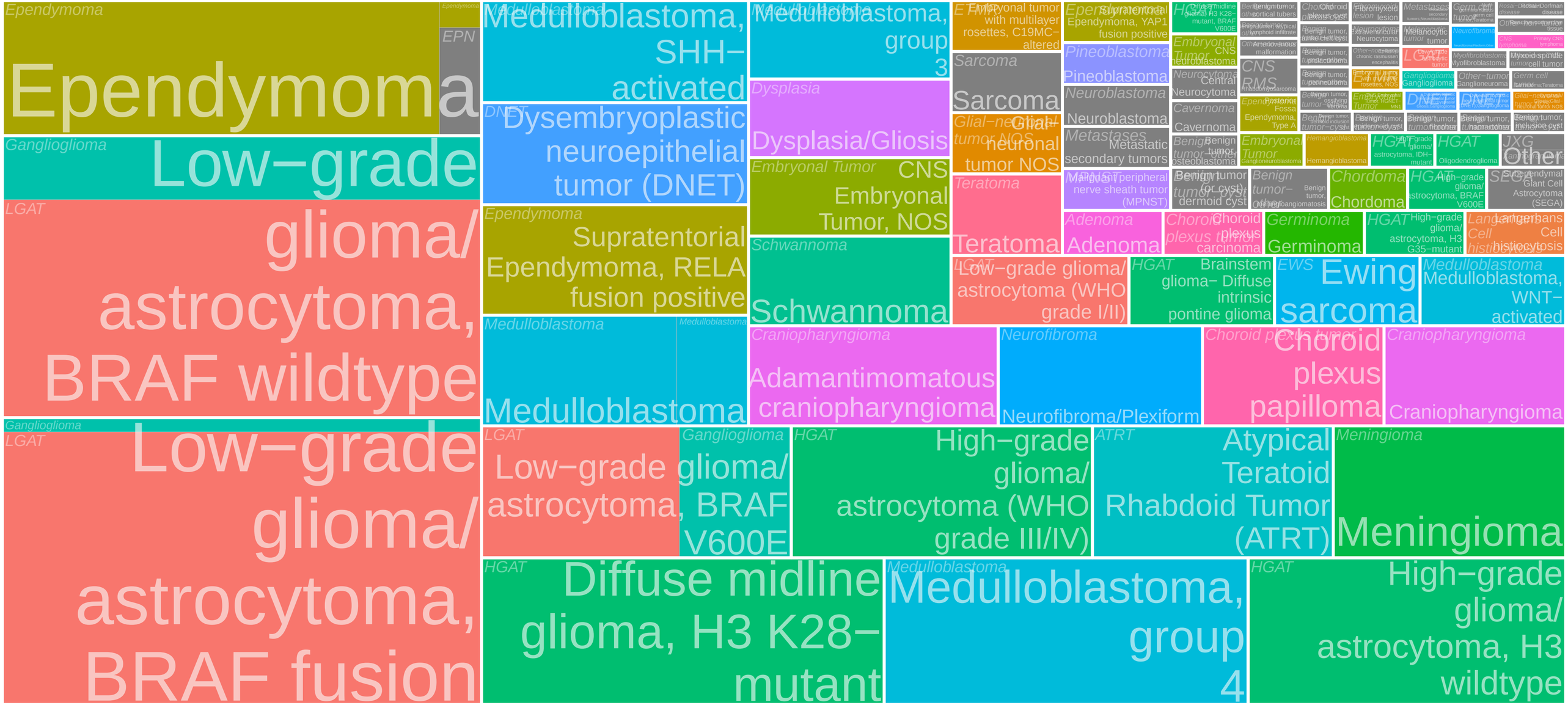
Ependymoma
Ependymoma
EPN
Medulloblastoma
Medulloblastoma, SHH−activated
Medulloblastoma
Medulloblastoma, group 3
Embryonal tumor with multilayer rosettes, C19MC−altered
Supratentorial Ependymoma, YAP1 fusion positive
Diffuse midline glioma, H3 K28−mutant, BRAF V600E
Benign tumor, cortical tubers
Choroid plexus cyst
Fibromyxoid lesion
Metastases
Germ cell tumor
Rosai−Dorfman disease
Other neoplasms of the tissue
Benign tumor, atypical lymphoid infiltrate
Extravascular Neurocytoma
Melanocytic tumor
Neurofibroma
CNS lymphoma
Primary CNS lymphoma
Arteriovenous malformation
Benign tumor, prolactinoma
Chronic rasmussen encephalitis
Myofibroblastoma
Mixed glioneuronal tumor
Ganglioglioma
Other−tumor
Sanglioneuroma
Germ cell tumor
Teratoma
Benign tumor, ossifying fibroma
Embryonal Tumor
Benign tumor, epidermoid cyst
Benign tumor, fibroma
Benign tumor, hamartoma
Benign tumor, inclusion cyst
Ganglioglioma
Dysplasia
Dysplasia/Gliosis
Embryonal Tumor
CNS Embryonal Tumor, NOS
Schwannoma
Schwannoma
Sarcoma
Sarcoma
Glial−neuronal tumor NOS
Glial−neuronal tumor NOS
Teratoma
Teratoma
Pineoblastoma
Pineoblastoma
Neuroblastoma
Neuroblastoma
Metastases
Metastatic secondary tumors
Central Neurocytoma
Neurocytoma
Cavernoma
Cavernoma
Rhabdomyosarcoma
CNS RMS
Posterior Fossa Ependymoma, Type A
Ganglioglioma
Embryonal Tumor
Ganglioneuroblastoma
Hemangioblastoma
Hemangioblastoma
Benign tumor, osteoblastoma
Benign tumor
Malignant peripheral nerve sheath tumor (MPNST)
Benign tumor (or cyst)
Benign tumor−other
Benign tumor, dermoid cyst
Benign tumor−other
Neurofibromatosis
Chordoma
Chordoma
Adenoma
Adenoma
Choroid plexus tumor
Choroid plexus carcinoma
Germinoma
Germinoma
HGAT
High−grade glioma/ astrocytoma, IDH−mutant
HGAT
Oligodendroglioma
JXG
Other
HGAT
High−grade glioma/ astrocytoma, BRAF V600E
SEGA
Subependymal Giant Cell Astrocytoma (SEGA)
HGAT
High−grade glioma/ astrocytoma, H3 G35−mutant
Langerhans Cell histiocytosis
Langerhans Cell histiocytosis
Ganglioglioma
Low−grade glioma/ astrocytoma, BRAF fusion
LGAT
Low−grade glioma/ astrocytoma, BRAF wildtype
LGAT
Low−grade glioma/ astrocytoma (WHO grade I/II)
HGAT
Brainstem glioma− Diffuse intrinsic pontine glioma
EWS
Ewing sarcoma
Medulloblastoma
Medulloblastoma, WNT−activated
Ependymoma
Supratentorial Ependymoma, RELA fusion positive
Medulloblastoma
Medulloblastoma
Medulloblastoma
Craniopharyngioma
Adamantimomatous craniopharyngioma
Neurofibroma
Neurofibroma/Plexiform
Choroid plexus tumor
Choroid plexus papilloma
Craniopharyngioma
Craniopharyngioma
LGAT
Low−grade astrocytoma
Ganglioglioma
Ganglioglioma, BRAF V600E
HGAT
High−grade glioma/ astrocytoma (WHO grade III/IV)
ATRT
Atypical Teratoid Rhabdoid Tumor (ATRT)
Meningioma
Meningioma
HGAT
Diffuse midline glioma, H3 K28−mutant
Medulloblastoma
Medulloblastoma, group 4
HGAT
High−grade glioma/ astrocytoma, H3 wildtype