Vemurafenib Response in 2 Patients With Posttransplant Refractory *BRAF* V600E–Mutated Multiple Myeloma

J.P. Sharman,[1] J. Chmielecki,[2] D. Morosini,[2] G.A. Palmer,[2] J.S. Ross,[2,3] P.J. Stephens,[2] J. Stafl,[1] V.A. Miller,[2] S.M. Ali[2]

Clinical Practice Points

- Multiple myeloma is commonly associated with genomic alterations that result in hyperactivation of the mitogen-activated protein kinase pathway.
- *BRAF* (v-raf murine sarcoma viral oncogene homolog B) V600E activating mutations have been observed in 4% of multiple myeloma cases.
- Patients with *BRAF* V600E–mutated myeloma may have an unusually aggressive clinical course associated with prominent extramedullary disease and a short duration of response to standard therapies.
- Vemurafenib, a *BRAF* V600E–specific inhibitor and an FDA approved agent for treatment of melanoma, also has clinical activity in *BRAF* V600E mutation–positive multiple myeloma.

Clinical Lymphoma, Myeloma & Leukemia, Vol. 14, No. 5, e161-3 © 2014 Elsevier Inc. All rights reserved.
Keywords: Mitogen-activated protein kinase, Mutation, Refractory myeloma, Vemurafenib, V600E

Introduction

BRAF (v-raf murine sarcoma viral oncogene homolog B) V600E activating mutations have been observed in melanoma, non–small-cell lung cancer, colorectal carcinoma, and a wide variety of additional malignancies, yet only some of these diseases have been tested for responses to *BRAF* V600E–specific inhibitors.[1,2] *BRAF* V600E and other less potent activating *BRAF* alterations have also been described in multiple myeloma[3]; however, the clinical response to BRAF-targeted therapy for *BRAF* V600E–mutated multiple myeloma is largely unknown. This report presents 2 posttransplant/conventional therapy–resistant patients with multiple myeloma with *BRAF* V600E mutations that were identified by a clinical next-generation sequencing–based assay and were subsequently treated with vemurafenib.

Case Presentations

Patient 1

A 65-year-old man presented with a 5-cm palpable skull lesion. Serum protein electrophoresis found a monoclonal immunoglobulin G (IgG) κ spike of 6 g/dL and 324 mg/dL of serum free κ light chains. Diagnostic workup for myeloma included a 24-hour urine collection (which found excretion of 5.2 g of κ light chain), a bone marrow biopsy (which found a diffuse infiltration with plasma cells notable for expression of CD56), normal metaphase cytogenetic analysis, and a normal myeloma fluorescence in situ hybridization (FISH) panel. Based on an albumin of 4.6 g/dL and a β2-microglobulin of 4.9 mg/L, he was diagnosed with stage II myeloma by the International Staging System (ISS) criteria and falls within the standard risk group as per Mayo Clinic Criteria.

Skeletal survey found numerous lytic bone lesions and an atypical mediastinal mass. Subsequent computed tomography (CT) confirmed a 6-cm mass within the upper posterior mediastinum consistent with extramedullary plasmacytoma.

Initial therapy consisted of lenalidomide, bortezomib, and dexamethasone. After 6 months of therapy, the palpable skull lesion resolved, and repeat CT found disappearance of the mediastinal mass. However, the IgG κ decreased to 1.7 g/dL, suggesting only a partial response to therapy. To minimize disease burden before autologous stem cell transplant, he received 2 cycles of VD-PACE (bortezomib/dexamethasone–cisplatin/doxorubicin/cyclophosphamide/etoposide) followed by cyclophosphamide mobilization. The patient proceeded to transplant with an IgG κ paraprotein level of 0.7 g/dL. He received conditioning melphalan of 200 mg/m^2 and completed his transplant uneventfully.

The patient began maintenance lenalidomide therapy on post-transplant day number 60, because his IgG κ remained elevated at

[1]Willamette Valley Cancer Institute, Eugene, OR
[2]Foundation Medicine Inc, Cambridge, MA
[3]Albany Medical College, Albany, NY

Submitted: Mar 21, 2014; Revised: May 22, 2014; Accepted: Jun 4, 2014; Epub: Jun 11, 2014

Address for correspondence: J.P. Sharman, MD, Director, Hematology Research, US Oncology, Willamette Valley Cancer Institute, 520 Country Club Rd, Eugene, OR 97401
E-mail contact: Jeff.Sharman@USOncology.com

2152-2650/$ - see frontmatter © 2014 Elsevier Inc. All rights reserved.
http://dx.doi.org/10.1016/j.clml.2014.06.004

1.3 g/dL. By day 90, he had developed several painful sites, and positron emission tomography (PET) scan found likely multifocal recurrence of myeloma. The patient was switched to carfilzomib but experienced early progression, as evidenced by a rising IgG κ and worsening bony pain, which necessitated palliative radiotherapy. A pelvic lesion biopsy was performed to obtain tissue for genomic profiling.

Sequencing of the coding sequence of 182 cancer-related genes and 37 introns of 14 genes frequently rearranged in cancer to a median depth of 868× found that the recurrent myeloma harbored an activating *BRAF* V600E mutation, as well as *MCL1* (myeloid cell leukemia 1), *MDM4* (p53 regulator), and *IKBKE* (inhibitor of kappa light polypeptide gene enhancer in B-cells, kinase epsilon) gene amplification (all estimated at 6 copies) and a homozygous deletion of *CDKN2C* (cyclin-dependent kinase inhibitor 2C [p18, inhibits CDK4]). The patient had experienced considerable decline in functional status (Eastern Cooperative Oncology Group performance status 3) and was largely confined to bed. In light of the aggressive nature of his disease, which was refractory to conventional agents, he was offered vemurafenib, a highly specific inhibitor of *BRAF* V600E.

Within 4 days of starting vemurafenib, the patient experienced a clinically significant reduction in pain. Despite prior chronic narcotic use, he was able to discontinue most pain medications within a few weeks and was able to resume manual labor. His IgG κ fell from 2.5 to 1.3 g/dL and his κ free light chain fell from 41 to 7 mg/dL within 1 month. Repeat PET imaging could not be obtained secondary to previous pathologic fractures. The patient tolerated vemurafenib well.

Approximately 7 weeks after initiation of vemurafenib, the patient began experiencing neurologic symptoms. He was admitted to the hospital, and a lumbar puncture found plasma cells within the cerebrospinal fluid. Palliative care was chosen, and he died shortly thereafter.

Patient 2

A 54-year-old man, a physician, initially presented with persistent rib pain. Chest imaging found a 5.2-cm lesion arising from the left fifth rib. Biopsy of this lesion found infiltrating plasma cells consistent with a plasmacytoma. Serum protein electrophoresis identified 0.1 g/dL IgG κ and 17 mg/dL of free κ light chains, and bone marrow biopsy found a dense infiltrate of malignant plasma cells with normal metaphase cytogenetic data and no FISH abnormalities. Based on a β2-microglobulin level of 5.1 mg/L and an albumin level of 4.8 g/dL, his disease was stage II by ISS criteria. Additional testing found elevated lactate dehydrogenase at 3 times the reference upper limit.

Initial therapy consisted of lenalidomide/bortezomib/dexamethasone (RVD). After 8 cycles of therapy, repeat bone marrow biopsy found 6% plasma cell infiltrate. The patient underwent uneventful autologous stem cell transplant, followed by lenalidomide maintenance therapy. He was able to resume working on posttransplant day 100.

Nine months after transplant, surveillance of serum free light chains identified a rise in κ free light chain level. Repeat bone marrow sampling identified 5% clonal plasma cells, and PET scan found 2 fluorine-18 fluorodeoxyglucose—avid new lytic bone lesions (Figure 1). He initiated pomalidomide and dexamethasone, but after 3 months of therapy, the regimen was stopped, because κ light chain increased from 54 to 117, and PET imaging identified numerous new lesions. Carfilzomib and dexamethasone were initiated, with the subsequent addition of cyclophosphamide, but progression of disease ensued as repeat bone marrow biopsy found 90% marrow involvement with plasma cells and 2% circulating plasma cells after 5 months. Repeat PET scanning found several new bone lesions, which coincided with sites of increasing pain.

The pretreatment biopsy of the rib lesion was submitted for genomic profiling. The coding sequence of 236 cancer-related genes and 47 introns from 19 genes frequently rearranged in cancer were sequenced to a median depth of 1073×. The myeloma harbored a *BRAF* V600E mutation as well as homozygous deletions of *BRCA1* (breast cancer 1), *RB1* (retinoblastoma 1), and *NOTCH2* (notch 2). After extensive discussion of risks and unknown benefits, the patient was started on vemurafenib, 960 mg twice daily.

Within 1 month, the κ free light chain level decreased by 90%, and it normalized after 2 months. Repeat PET scan at this time found near-resolution of all hypermetabolic lesions. The patient developed grade 1 dermatitis and required treatment of a squamous cell carcinoma that developed during vemurafenib treatment. At the time of this report, the patient's response was ongoing and at 4 months' duration.

Discussion

Activating genomic alterations in the mitogen-activated protein kinase signaling pathway are the most frequent oncogenic driver mutations in multiple myeloma.[3] Whereas mutations in *NRAS*

Figure 1 Positron Emission Tomography Scan of Patient 2, Before (Left) and After (Right) 2 Months of Vemurafenib Treatment

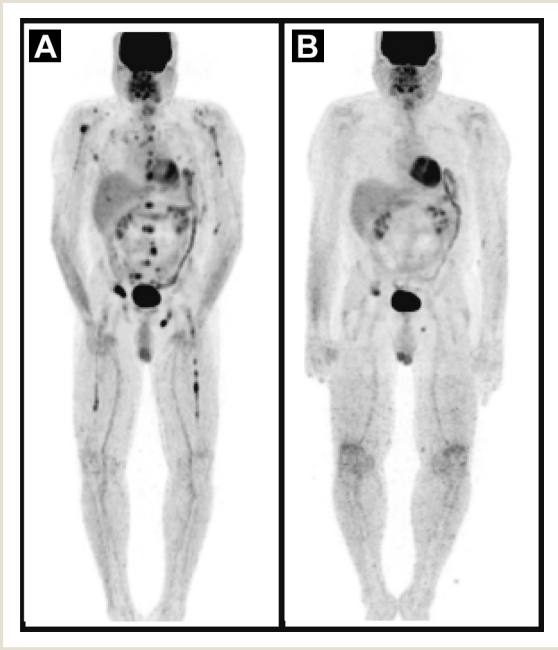

(neuroblastoma RAS viral (v-ras) oncogene homolog) and *KRAS* (Kirsten rat sarcoma viral oncogene homolog) may occur in 40% to 50% of myeloma cases, *BRAF* mutations are less frequent, occurring in approximately 2% to 4% of primary myelomas,[4] with the majority of these alterations consisting of *BRAF* V600E activating mutations.

Andrulis et al[5] retrospectively identified 7 of 379 myeloma cases as being mutated for *BRAF* V600E via mutation-specific immunohistochemistry and noted an aggressive phenotype associated with a short duration of response to conventional therapy and a high frequency of extramedullary disease (4 of 7 patients). A single patient with *BRAF* V600E mutation−positive myeloma was treated with vemurafenib and experienced a durable response. In a second study, a patient with *BRAF* V600E mutation−positive myeloma was also treated with vemurafenib but had early progression of disease.[6]

This report describes 2 patients with *BRAF* V600E−mutation multiple myeloma treated with vemurafenib. For patient 1, the early progression of myeloma within the central nervous system (CNS) that occurred contemporaneously with a dramatic systemic response suggests vemurafenib may have failed to penetrate into the sanctuary site of the CNS, a known limitation of vemurafenib in treating cerebral metastases of melanoma. Although the presence of other genomic alterations in multiple myeloma may also influence the long-term response to vemurafenib in the *BRAF* V600E−mutated cases, larger studies will be needed to validate the roles of potential therapy response−modifying factors. Both patients had an unusually aggressive phenotype of myeloma associated with extramedullary disease, brief duration of disease control after autologous transplant, and rapid acquisition of resistance to conventional agents. However, upon initiation of vemurafenib treatment, both patients rapidly experienced improved paraprotein levels and improved clinical performance status. For future patients with myeloma, identification of *BRAF* V600E mutation may provide an option for targeted treatment at the time of relapse after conventional cytotoxic therapy following autologous bone marrow transplant. In that regard, a phase II study testing targeted *BRAF* therapy in multiple myeloma is ongoing (NCT01524978). In addition, for the majority of relapsed/refractory myelomas that are found to be *BRAF* wild type, clinical genomic profiling has the potential to identify other genomic alterations that may predict responses to non−*BRAF* targeted therapies.

Conclusion

Patients with BRAF V600E−mutated myeloma may have an unusually aggressive clinical course associated with prominent extramedullary disease and a short duration of response to standard therapies. Vemurafenib has clinical activity in this form of multiple myeloma.

Disclosure

J.C., D.M., P.J.S., G.A.P., J.S.R., V.A.M., and S.M.A. are employees of and have equity interest in Foundation Medicine Inc. J.S. and J.P.S. state that they have no conflicts of interest.

References

1. Machnicki MM, Stoklosa T. BRAF—a new player in hematological neoplasms [published online February 2, 2014]. *Blood Cells Mol Dis* 2014; 53:77-83.
2. Rahman MA, Salajegheh A, Smith RA, Lam AK-Y. B-Raf mutation: a key player in molecular biology of cancer. *Exp Mol Pathol* 2013; 95:336-42.
3. Lohr JG, Stojanov P, Carter SL, et al, Multiple Myeloma Research Consortium. Widespread genetic heterogeneity in multiple myeloma: implications for targeted therapy. *Cancer Cell* 2014; 25:91-101.
4. Chapman MA, Lawrence MS, Keats JJ, et al. Initial genome sequencing and analysis of multiple myeloma. *Nature* 2011; 471:467-72.
5. Andrulis M, Lehners N, Capper D, et al. Targeting the BRAF V600E mutation in multiple myeloma. *Cancer Discov* 2013; 3:862-9.
6. Bohn OL, Hsu K, Hyman DM, Pignataro DS, Giralt S, Teruya-Feldstein J. BRAF V600E mutation and clonal evolution in a patient with relapsed refractory myeloma with plasmablastic differentiation [published online December 17, 2013]. *Clin Lymphoma Myeloma Leuk* 2014; 14:e65-8.