Injury, Int. J. Care Injured 49 (2018) 505–510

Contents lists available at ScienceDirect

Injury

journal homepage: www.elsevier.com/locate/injury

Full length article

Fracture-related infection: A consensus on definition from an international expert group

WJ. Metsemakers[a,s,*], M. Morgenstern[b], M.A. McNally[c], T.F. Moriarty[d], I. McFadyen[e], M. Scarborough[c], N.A. Athanasou[f], P.E. Ochsner[g], R. Kuehl[h], M. Raschke[i], O. Borens[j], Z. Xie[k], S. Velkes[l], S. Hungerer[m], S.L. Kates[n], C. Zalavras[o], P.V. Giannoudis[p,q], R.G. Richards[d], M.H.J. Verhofstad[r]

[a] Department of Trauma Surgery, University Hospitals Leuven, Belgium
[b] Department of Orthopaedic and Trauma Surgery, University Hospital Basel, Switzerland
[c] The Bone Infection Unit, Nuffield Orthopaedic Centre, Oxford University Hospitals, Oxford, United Kingdom
[d] AO Research Institute Davos, Davos, Switzerland
[e] Department of Orthopaedic Surgery, University Hospitals of North Midlands, Stoke-on-Trent, United Kingdom
[f] Department of Osteoarticular Pathology, Nuffield Department of Orthopaedics, Rheumatology and Musculoskeletal Science, University of Oxford, Oxford, United Kingdom
[g] Medical University Basel, Switzerland
[h] Division of Infectious Diseases and Hospital Epidemiology, University Hospital of Basel, Switzerland
[i] Department of Trauma and Reconstructive Surgery, University Hospital of Münster, Germany
[j] Orthopedic Department of Septic Surgery, Orthopaedic-Trauma Unit, Department for the Musculoskeletal System, CHUV, Lausanne, Switzerland
[k] Department of Orthopaedic Surgery, Southwest Hospital, Third Military Medical University, Chongqing, China
[l] Department of Orthopedic and Trauma Surgery, Rabin Medical Center, University of Tel Aviv Medical School, Israel
[m] Department of Joint Surgery, Trauma Center Murnau, Germany and Institute of Biomechanics, Paracelsus Medical University Salzburg, Austria
[n] Department of Orthopaedic Surgery, Virginia Commonwealth University, USA
[o] Department of Orthopaedic Surgery, Keck School of Medicine, University of Southern California, Los Angeles, USA
[p] Department of Trauma and Orthopaedic Surgery, University Hospital of Leeds, United Kingdom
[q] NIHR Leeds Biomedical Research Unit, Chapel Allerton Hospital, Leeds, United Kingdom
[r] Trauma Research Unit Department of Surgery, Erasmus MC, University Medical Center Rotterdam, Rotterdam, The Netherlands
[s] KU Leuven - University of Leuven, Department Development and Regeneration, B-3000 Leuven, Belgium

ARTICLE INFO

Article history:
Received 2 May 2017
Received in revised form 16 August 2017
Accepted 20 August 2017

Keywords:
Fracture-related infection consensus definition
Fracture
Infection
Consensus
Definition

ABSTRACT

Fracture-related infection (FRI) is a common and serious complication in trauma surgery. Accurately estimating the impact of this complication has been hampered by the lack of a clear definition. The absence of a working definition of FRI renders existing studies difficult to evaluate or compare. In order to address this issue, an expert group comprised of a number of scientific and medical organizations has been convened, with the support of the AO Foundation, in order to develop a consensus definition.

The process that led to this proposed definition started with a systematic literature review, which revealed that the majority of randomized controlled trials in fracture care do not use a standardized definition of FRI. In response to this conclusion, an international survey on the need for and key components of a definition of FRI was distributed amongst all registered AOTrauma users. Approximately 90% of the more than 2000 surgeons who responded suggested that a definition of FRI is required. As a final step, a consensus meeting was held with an expert panel. The outcome of this process led to a consensus definition of FRI.

Two levels of certainty around diagnostic features were defined. Criteria could be confirmatory (infection definitely present) or suggestive. Four confirmatory criteria were defined: Fistula, sinus or wound breakdown; Purulent drainage from the wound or presence of pus during surgery; Phenotypically indistinguishable pathogens identified by culture from at least two separate deep tissue/implant specimens; Presence of microorganisms in deep tissue taken during an operative intervention, as confirmed by histopathological examination. Furthermore, a list of suggestive criteria was defined. These require further investigations in order to look for confirmatory criteria.

* Corresponding author.
E-mail address: willem-jan.metsemakers@uzleuven.be (W. Metsemakers).

http://dx.doi.org/10.1016/j.injury.2017.08.040
0020-1383/© 2017 The Author(s). Published by Elsevier Ltd. This is an open access article under the CC BY-NC-ND license (http://creativecommons.org/licenses/by-nc-nd/4.0/).

In the current paper, an overview is provided of the proposed definition and a rationale for each component and decision. The intention of establishing this definition of FRI was to offer clinicians the opportunity to standardize clinical reports and improve the quality of published literature. It is important to note that the proposed definition was not designed to guide treatment of FRI and should be validated by prospective data collection in the future.
© 2017 The Author(s). Published by Elsevier Ltd. This is an open access article under the CC BY-NC-ND license (http://creativecommons.org/licenses/by-nc-nd/4.0/).

Introduction

Fracture-related infection (FRI) is one of the most challenging musculoskeletal complications in trauma surgery. Currently, estimating the impact of FRI has been hampered by the lack of a clear definition [1]. Interestingly, this issue was previously raised in an AO/ASIF scientific supplement publication by Arens et al. in 1996, wherein the authors stated in a combined clinical and

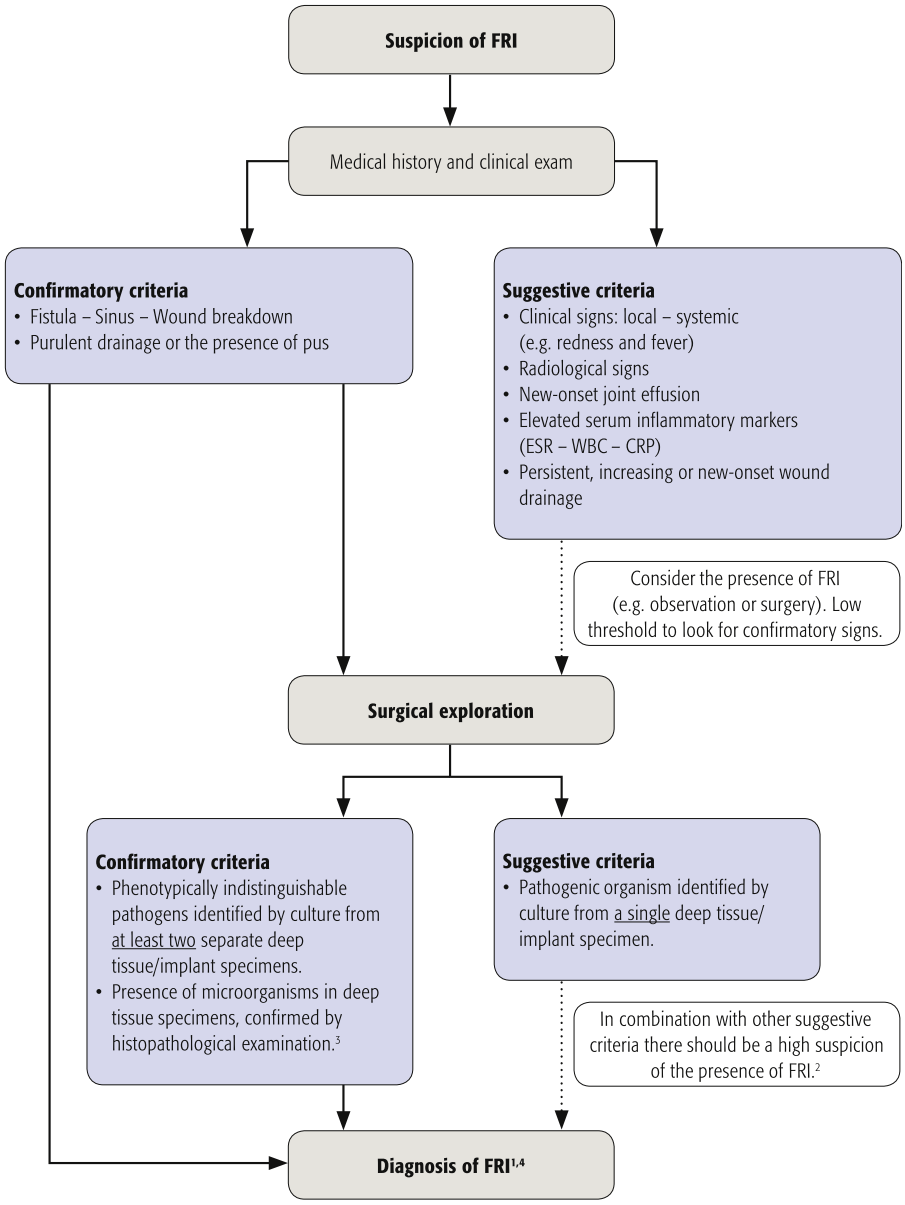

[1] In cases of purulent drainage or fistula/sinus/wound breakdown, the presence of pathogens identified by culture is not an absolute requirement (e.g. in the case of chronic antibiotic suppression).
[2] If the positive culture is from sonication fluid, it is highly likely that FRI is present. This is especially true when virulent bacteria (i.e. *Staphylococcus aureus*) are present.
[3] The presence of microorganisms is confirmed by using specific staining techniques for bacteria and fungi.
[4] Future research is required on the following criteria: acute inflammatory cell infiltrate on histopathological examination (e.g. PMN count), molecular diagnostics (e.g. PCR) and nuclear imaging (e.g. WBC scintigraphy).

Fig. 1. Descriptive flow chart of FRI.

experimental study on FRI: '*It is astonishing that in all papers in which infection is mentioned, the term 'infection' is not defined*' [2]. In fact, this was confirmed by a recent systematic review, which showed that only a minority of randomized controlled trials (2%) in fracture care use any kind of standardized definition of infection [3].

The lack of a clear definition of FRI, mirrors the situation for Prosthetic Joint Infection (PJI) identified many years ago [4,5]. The situation for PJI [6] and diabetic foot infection for example [7], has improved with consensus definitions emerging in recent years. However, until now, no consensus definition for infection in patients with a fracture has been available. Trauma surgeons realize that neither the definition for PJI, nor the Centers for Disease Control (CDC) guidelines can be easily extrapolated to fracture cases and that a definition for FRI needs to be developed. This was recently confirmed by an international survey for registered AOTrauma users. In this survey, surgeons were asked about the need for a working definition of FRI. Approximately 90% of the more than 2000 surgeons who responded suggested that a definition of FRI is required (AO Foundation; data on file, 2016).

Therefore, a recent effort was made, with the support of the AO Foundation, to develop such a consensus definition. The consensus process was designed specifically to address only one issue; the development of this *Definition* of FRI. Comparable to the description by Cats-Baril et al. for the New definition on PJI [8], our consensus process had three phases: (1) a phase were experts exchanged ideas through a modified Delphi process [8,9] which was primarily performed with planned videoconferences and through email; (2) a phase where participants worked face-to-face to address specific topics that were agreed upon in phase 1 and vote on resolutions; and (3) a publication phase. During the first exchange of ideas (phase 1), it was identified that four main topics should be addressed to provide knowledge and standards for such a definition of FRI. The selected topics were: *Classification*, *Location*, *Terminology* and *Diagnostic criteria*. The second phase, the consensus meeting, was convened in December 2016 (Davos, Switzerland) [10], hosted by the AO Foundation, and composed of a group of experts, representing various international organizations (AO Foundation, European Bone and Joint Infection Society (EBJIS)) and prominent orthopaedic trauma hospitals and academic centers that have a major interest in FRI. As the management of FRI should be a multidisciplinary effort [11], physicians with different backgrounds were included (i.e. infectious disease specialists, orthopaedic trauma surgeons and clinical pathologists). Scientific input was also provided by researchers active in this field. Prior to the meeting, the experts were asked to review and consider the published literature on definitions of infection developed for PJI and other orthopaedic conditions. During the meeting, separate sessions addressed the four main topics previously mentioned. Finally, a first concept of the consensus definition was proposed, which was further clarified and described during phase 3.

In the following text an overview is provided of the proposed definition.

Definition of fracture-related infection

This consensus paper describes a proposal for defining infection related to a fracture. It does not attempt to classify infection, describe anatomical variations, provide a complete set of terminology, or outline and guide treatment. Further work is ongoing regarding these topics.

In the definitions that describe infection after prosthetic joint replacement, there is a consensus on the need to use clinical, laboratory and radiological features to confirm or exclude the presence of infection [6]. This approach is also appropriate for FRI.

It was accepted that some features of FRI can be regarded as pathognomonic of infection and should be given more weight in the definition. Other less specific features may suggest an infection, but may also be present in some patients without infection. Therefore, we defined two levels of certainty around the diagnostic features. Criteria could be confirmatory (infection definitely present if a confirmatory criterion is met) or suggestive (features associated with infection and requiring further investigation).

In the expert panel meeting, each criterion was discussed separately with the evidence for its inclusion. Fig. 1 shows a suggested flow chart that clinicians can use in daily practice (clinical routine and research) to diagnose and define FRI.

Confirmatory criteria for FRI

1. Fistula, sinus or wound breakdown (with communication to the bone or the implant).
2. Purulent drainage from the wound or presence of pus during surgery.
3. Phenotypically indistinguishable pathogens identified by culture from at least two separate deep tissue/implant (including sonication-fluid) specimens taken during an operative intervention. In case of tissue, multiple specimens ($\geq$3) should be taken, each with clean instruments (not superficial or sinus tract swabs). In cases of joint effusion, arising in a joint adjacent to a fractured bone, fluid samples obtained by sterile puncture may be included as a single sample.
4. Presence of microorganisms in deep tissue taken during an operative intervention, as confirmed by histopathological examination using specific staining techniques for bacteria or fungi.

Suggestive criteria for FRI

1. Clinical signs – any one of:
   - Pain (without weight bearing, increasing over time, new-onset)
   - Local redness
   - Local swelling
   - Increased local temperature
   - Fever (single oral temperature measurement of $\geq$38.3°C (101°F))
2. Radiological signs – any one of:
   - Bone lysis (at the fracture site, around the implant)
   - Implant loosening
   - Sequestration (occurring over time)
   - Failure of progression of bone healing (i.e. non-union)
   - Presence of periosteal bone formation (e.g. at localizations other than the fracture site or in case of a consolidated fracture)
3. A pathogenic organism identified by culture from a single deep tissue/implant (including sonication-fluid) specimen taken during an operative intervention. In case of tissue, multiple specimens ($\geq$3) should be taken, each with clean instruments (not superficial or sinus tract swabs). In cases of joint effusion arising in a joint adjacent to a fractured bone, a fluid sample obtained by sterile puncture is permitted.
4. Elevated serum inflammatory markers: In musculoskeletal trauma, these should be interpreted with caution. They are included as suggestive signs in case of a secondary rise (after an initial decrease) or a consistent elevation over a period in time, and after exclusion of other infectious foci or inflammatory processes:
   - Erythrocyte sedimentation rate (ESR)
   - White blood cell count (WBC)

- C-reactive protein (CRP)

5. Persistent, increasing or new-onset wound drainage, beyond the first few days postoperatively, without solid alternative explanation.
6. New-onset of joint effusion in fracture patients. Surgeons should be aware that FRI can present as an adjacent septic arthritis in the following cases:
   - Implant material which penetrates the joint capsule (e.g. femoral nailing)
   - Intra-articular fractures

Discussion

Over the past few decades, there has been a growing awareness of the fact that there is no published definition of FRI. An obvious reason is the complexity of the issue. Similarly to PJI, FRI can manifest in a wide variety of clinical scenarios. However, for FRI there are not only multiple anatomical locations, but also multiple fracture patterns, different degrees of soft-tissue injury as well as different patient conditions (poly- vs. isolated trauma), which makes inclusion of all FRI patients into one definition difficult. It should however be possible to include the majority of patients in a single definition, if all the specific characteristics of FRI and musculoskeletal trauma patients in general are considered. Currently, the scarcity of scientific evidence regarding diagnostic and treatment concepts, precludes the development of a definition for FRI that is based on sound evidence. A possible solution was described by Cats-Baril et al. in a paper on the development process for the New definition of PJI: '*The lack of evidence for many aspects of clinical practice compels the medical community to seek alternatives for development of best practices. A consensus meeting by international experts is one such alternative*' [8]. Therefore, part of the aforementioned consensus process consisted of organizing a meeting composed of experts.

Although the group of experts overall agreed on the definition and the value of the different components, there are issues that need further consideration. The discussion surrounding these issues is presented in detail below within the four main discussion topics (*Classification, Location, Terminology and Diagnostic criteria*).

Classification

There are multiple classifications described in the literature that subdivide FRI into discrete groupings such as acute and chronic infections, or early, delayed and late onset infections [1,12–14]. One of the key questions for the experts was: should there be a single definition for FRI, or should a definition be subdivided into separate definitions for each classification (e.g. acute and chronic infection)? During the consensus meeting there was a *unanimous* decision that there should only be one single definition for FRI.

Two primary reasons were proposed for this decision: Firstly, a subdivision would make such a definition unnecessarily complex and difficult to use in daily practice. Secondly, the available classifications are time-related. These time windows are, to the best of our knowledge, not based on scientific evidence, which supports the view that they are poorly defined for FRI (e.g. time since injury, or time since onset of symptoms) and somewhat arbitrary (e.g. a 6 week transition from acute to chronic infection). All these concerns pose serious problems from a definition point of view [3]. Of course, the participants did agree that acute and chronic infections are different entities that may require different treatment strategies; however, it should not impact upon the way clinicians define FRI.

The experts agreed, that in a later phase, a similar process should be followed to achieve consensus on a classification of FRI to help develop treatment guidelines.

Location

A second challenge in developing a definition for FRI emerges with the location of the infection within the surgical site or wound, and includes descriptions such as '*superficial incisional infections*' [3]. The CDC published guidelines for surgical site infection (SSI), which distinguish between superficial incisional, deep incisional and organ/space infections [15–17]. Bonnevialle et al. state that the term 'superficial infection' is at best arbitrary [18], and poses particularly challenging problems in FRI. The depth of bacterial colonization can only be assessed by tissue samples taken under the subcutaneous tissue layer. This means that superficial swabs are no longer acceptable for diagnosis and every wound must be opened to take appropriate samples [18]. In FRI, this would require the surgeon to open the surgical wound and expose both the implant and the fracture site in many cases (e.g. ankle fractures). If the cultures are positive, this then defines a deep infection. Furthermore, in clinical studies regarding FRI, these terms (e.g. superficial and deep) are often used inaccurately or inappropriately, which makes comparison of literature difficult. In clinical practice, the presence of confirmatory or suggestive signs of an infection should be sufficient to alert clinicians of the need for treatment. The specifics of this treatment may be related to the nature of the infection (e.g. superficial cellulitis or deep infected non-union) but this is outside the remit of this definition proposal.

Unlike PJI, there can be numerous anatomical areas (i.e. humerus, tibia) involved in FRI. Although each area has its own features, this definition does not guide treatment principles. Subdividing a definition according to anatomical locations would make it unnecessarily complex. Also, the criteria used to diagnose an infection are not dependent on the anatomical location of the infection.

During the consensus meeting, there was a *unanimous* decision that there should not be a subdivision of the definition for FRI (e.g. superficial and deep infections, or anatomical locations). The experts accepted that there might be superficial infections that do not communicate with the fracture or implant (e.g. cellulitis, pin site infection) but for the purposes of a definition (and data collection), it is important that surgeons define the presence of infection, not its extent, localization or classification. The superficial nature of a FRI can only be assumed in retrospect, it cannot be used as an entity that guides treatment. Regarding anatomical locations, these can be implemented in future treatment concepts (e.g. classification).

Terminology

In the current clinical literature, numerous terms are used with respect to FRI (i.e. posttraumatic osteomyelitis, osteïtis, deep infection). Often, no distinction is made between the terms osteitis and osteomyelitis. Although the term osteomyelitis is used clinically to signify a bone infection in the English literature [19], in certain parts of the world, FRI or bone infection is often referred to as osteitis (i.e ostéite in French speaking countries). Tiemann and Hofmann suggest that the main difference between osteitis and osteomyelitis is the way in which the infection arises in the bone [20]. The term osteitis refers to a bone infection (starting with cortical bone involvement) most commonly caused by bacteria, that may lead to the complete destruction of the infected bone. In contrast, osteomyelitis refers to a primary infection of the bone marrow (myelitis) with subsequent involvement of the cortical bone and periosteum. The clinical and investigative findings of these diseases may be very similar and it can be sometimes quite difficult to differentiate between the two [20]. Furthermore, in FRI, terms like osteomyelitis or osteitis are not useful as the main issue is the presence of bacteria at the fracture site and around the implant, rather than the semantics of the pathogenesis of the infection.

During the consensus meeting, there was a *unanimous* decision that more uniformity is required in the medical terminology of infection in musculoskeletal trauma patients. Furthermore, the experts agreed that terms such as osteomyelitis or osteitis should be used with caution in clinical studies, as both are very difficult to distinguish from one another in a clinical setting and, as was shown in preclinical studies [1], in early cases of infection are not even present.

The experts also agreed that a more comprehensive term was required, which encompassed infections with and without implants and included infection of all parts of the bone (cortical, medullary, epiphyseal). *Fracture-related infection* (FRI) was introduced as a more general term. The experts suggest that in the future, for reasons of uniformity, this term would be used in clinical publications on patients with infected fractures, in case no further detailed information (e.g. histopathology) would be available on the degree of bone involvement.

Diagnostic criteria

The inclusion of diagnostic criteria in the definition of FRI was a *unanimous* decision of the expert panel. Numerous clinical signs and diagnostic studies were considered. It was recognized that some features are only present when the fracture is infected (pathognomonic criteria, which confirms the diagnosis of infection) and other features may indicate an infection, but could be present for other reasons (criteria suggesting the diagnosis of infection). Based on these criteria, the definition of FRI was subdivided into *Confirmatory* and *Suggestive* criteria (Fig. 1). Again, it is important to state that this proposal is limited to the diagnosis of infection and does not attempt to classify infections or provide guidance for treatment. The goal of describing suggestive criteria is to stimulate the treating clinician to perform further investigations in order to look for confirmatory criteria (Fig. 1, dotted line). One such suggestive criterion, for example, is persistent, increasing or new-onset wound drainage. This should prompt deep sampling for culture, which is most frequently done as part of a surgical debridement.

The panel *unanimously* agreed that some criteria were confirmatory of infection, namely fistula, sinus, or wound breakdown. The presence of these signs define the ongoing communication between the fracture or implant and a contaminated epithelial surface with the transfer of pathogens to the fracture or implant environment where their presence will cause infection, even if indolent. Other local clinical signs (i.e. pain, redness) were included as suggestive signs. The panel agreed that, although these signs are subjective, the soft tissue status in musculoskeletal trauma patients is a crucial aspect that should be included in the definition of FRI.

There are a few criteria that need to be addressed separately because they posed some difficulties during the consensus process. These will be discussed below.

Scientific data describing the histopathology of FRI is limited [20]. In contrast to the definition for PJI, the expert panel did not include the presence of an acute inflammatory cell infiltrate on histopathological examination (i.e. PMN count). The reason for this is the lack of clear scientific evidence and, more specifically, agreement on a cut off value above which FRI can be reliably diagnosed. At the present time there is still no standardized, reproducible protocol described for the evaluation of histopathological samples obtained during surgery for FRI [21]. In daily clinical practice, histopathology findings are often presented descriptively rather than in a standardized objective manner, which makes it difficult for the clinician to interpret. The influence of fracture healing and infection on PMN count therefore requires further study if it is ever to become a reliable diagnostic parameter for FRI. Recently, a histopathological osteomyelitis evaluation score (HOES) has been developed to facilitate the diagnosis [21], but this score will need validation in large clinical trials. The experts nevertheless agreed that the presence of microorganisms in deep tissue taken during an operative intervention, as confirmed by histopathological examination using specific staining techniques, is a pathognomonic sign for infection. The goal of this definition is to include the majority of FRIs and due to the increasing prevalence of specific entities like tuberculosis (Ziehl-Neelsen stain) [22] and invasive fungal infections (Grocott methenamine silver stain), especially in immunocompromised patients, there was a *strong consensus* to include this sign in the confirmatory criteria. Gram staining is one of the most known staining techniques used for the identification of both Gram positive and Gram negative bacteria. Due to low sensitivity, the experts stated that it should only be taken into consideration if positive. Overall the results of a Gram stain should be interpreted with caution (e.g. cases of contamination).

Over the past few decades various studies have investigated the performance of molecular diagnostics, more specific Polymerase Chain Reaction (PCR), using specimens of different origins, predominantly in the setting of PJI [21]. Studies related to FRI are scarce. To our knowledge, over the recent years, only one study has been published [21]. The results revealed that tissue cultures were superior to PCR for the diagnosis of FRI. Future research on this topic is therefore necessary.

Radiological examination is crucial in the evaluation of patients with FRI. Not only to look for signs of infection, but also to evaluate implant loosening and bone healing. Different nuclear imaging techniques have been introduced to help improve the diagnosis of infection. WBC scintigraphy is one of the most commonly used diagnostic modalities in this field. As was true for PCR, most studies on these new imaging techniques were performed in peripheral osteomyelitis including PJI and despite the widely available data on WBC scintigraphy in peripheral osteomyelitis in general, there is a lack of studies focusing on FRI [22].

The experts agreed with a *strong consensus* that PCR, acute inflammatory cell infiltrate on histopathological examination (e.g. PMN count) and nuclear imaging techniques (e.g. WBC scintigraphy) should, due to the current lack of scientific data, not be included in the current definition of FRI. The experts acknowledge that, particularly in longstanding cases of infection, PCR, nuclear imaging techniques and the presence of an acute inflammatory infiltrate could be useful adjunctive diagnostic modalities, but require validation in well designed, prospective clinical studies before their inclusion in the diagnostic criteria of FRI.

The experts acknowledge that this definition of course also has it limitations. As previously mentioned, research solely focusing on FRI is scarce, which makes it difficult to have a sound scientific basis for such a definition. On the other hand, this does not mean that there should not be an attempt to improve daily clinical practice by the development of such a definition. Furthermore, this definition may be revised in the future on the basis of solid clinical data from studies that may use this definition. One final limitation is that this consensus was derived from discussions within a relatively small group of experts. Increasing the number of participants within the group would be attractive, however, for this first definition, the inclusion of only professionals with significant expertise and experience on this topic lends validity to the definition.

Conclusion

In conclusion, a definition of FRI has been designed based on a stepwise approach. The major stimulus behind this work is to offer clinicians the opportunity to standardize clinical reports and improve the quality of published literature. This consensus definition should be validated by prospective data collection in

order to gather evidence of its use in clinical studies and to prove that it can become a valuable tool in comparative research.

Conflict of interest

All authors declare no conflict of interest with respect to the preparation and writing of this article.

Acknowledgements

The authors wish to thank the AO Foundation and the EBJIS for their support of this work. Dr. Jan Puetzler and Willemijn Boot are thanked for their administrative work during the consensus meeting.

References

[1] Metsemakers WJ, Kuehl R, Moriarty TF, Richards RG, Verhofstad MH, Borens O, et al. Infection after fracture fixation: current surgical and microbiological concepts. Injury 2016.
[2] Arens S, Hansis M, Schlegel U, Eijer H, Printzen G, Ziegler WJ, et al. Infection after open reduction and internal fixation with dynamic compression plates–clinical and experimental data. Injury 1996;27(Suppl 3):SC27–33.
[3] Metsemakers WJ, Kortram K, Morgenstern M, Moriarty TF, Meex I, Kuehl R, et al. Definition of infection after fracture fixation: a systematic review of randomized controlled trials to evaluate current practice. Injury 2017.
[4] Metsemakers WJ, Moriarty TF, Morgenstern M, Kuehl R, Borens O, Kates S, et al. Letter to the editor: new definition for periprosthetic joint infection: from the workgroup of the musculoskeletal infection society. Clin Orthop Relat Res 2016;474:2726–7.
[5] Zimmerli W, Trampuz A, Ochsner PE. Prosthetic-joint infections. N Engl J Med 2004;351:1645–54.
[6] Parvizi J, Zmistowski B, Berbari EF, Bauer TW, Springer BD, Della Valle CJ, et al. New definition for periprosthetic joint infection: from the Workgroup of the Musculoskeletal Infection Society. Clin Orthop Relat Res 2011;469:2992–4.
[7] Lipsky BA, Berendt AR, Cornia PB, Pile JC, Peters EJ, Armstrong DG, et al. Executive summary: 2012 Infectious Diseases Society of America clinical practice guideline for the diagnosis and treatment of diabetic foot infections. Clin Infect Dis 2012;54:1679–84.
[8] Cats-Baril W, Gehrke T, Huff K, Kendoff D, Maltenfort M, Parvizi J. International consensus on periprosthetic joint infection: description of the consensus process. Clin Orthop Relat Res 2013;471:4065–75.
[9] Akins RB, Tolson H, Cole BR. Stability of response characteristics of a Delphi panel: application of bootstrap data expansion. BMC Med Res Methodol 2005;5:37.
[10] AO Foundation website. A. Fracture-Related Infection discussed by an international group of experts in Davosin December. 2016. https://www.aofoundation.org/Structure/pages/newsdetail.aspx?newslist=https://www.aofoundation.org/News/Lists/News%20Common&newsid=920.
[11] Bose D, Kugan R, Stubbs D, McNally M. Management of infected nonunion of the long bones by a multidisciplinary team. Bone Joint J 2015;9(97-B):814–7.
[12] Borens O, Helmy N. Infected osteosynthesis. Chirurg 2016;87:822–30.
[13] Kleber C, Schaser KD, Trampuz A. Complication management of infected osteosynthesis: therapy algorithm for peri-implant infections. Chirurg 2015;86:925–34.
[14] Willenegger H, Roth B. Treatment tactics and late results in early infection following osteosynthesis. Unfallchirurgie 1986;12:241–6.
[15] Horan TC, Gaynes RP, Martone WJ, Jarvis WR, Emori TG. CDC definitions of nosocomial surgical site infections, 1992: a modification of CDC definitions of surgical wound infections. Infect Control Hosp Epidemiol 1992;13:606–8.
[16] Mangram AJ, Horan TC, Pearson ML, Silver LC, Jarvis WR. Guideline for prevention of surgical site infection, 1999. centers for disease control and prevention (CDC) hospital infection control practices advisory committee. Am J Infect Control 1999;27:97–132 quiz 3–4; discussion 96.
[17] Centers for Disease Control and Prevention. National Healthcare Safety Network (NHSN) Overview. 2016. http://www.cdc.gov/nhsn/pdfs/pscmanual/pcsmanual_current.pdf2016.
[18] Bonnevialle P, Bonnomet F, Philippe R, Loubignac F, Rubens-Duval B, Talbi A, et al. Early surgical site infection in adult appendicular skeleton trauma surgery: a multicenter prospective series. Orthop Traumatol Surg Res 2012;98:684–9.
[19] Lew DP, Waldvogel FA. Osteomyelitis. N Engl J Med 1997;336:999–1007.
[20] Tiemann AH, Hofmann GO. Principles of the therapy of bone infections in adult extremities: are there any new developments. Strategies Trauma Limb Reconstr 2009;4:57–64.
[21] Omar M, Suero EM, Liodakis E, Reichling M, Guenther D, Decker S, et al. Diagnostic performance of swab PCR as an alternative to tissue culture methods for diagnosing infections associated with fracture fixation devices. Injury 2016;47:1421–6.
[22] Govaert GA, Glaudemans AW. Nuclear medicine imaging of posttraumatic osteomyelitis. Eur J Trauma Emerg Surg. 2016;42:397–410.