Retina

Evaluating the Volume of Eyes With Pathologic Myopia Using 3D MRI

Tomonari Takahashi,[1] Tae Yokoi-Igarashi,[1] Hiroyuki Takahashi,[1] Noriko Nakao,[1] Kengo Uramoto,[1] Takeshi Yoshida,[1] Muka Moriyama,[1] Koju Kamoi,[1] Koichiro Kimura,[2] Ukihide Tateishi,[2] and Kyoko Ohno-Matsui[1]

[1]Department of Ophthalmology and Visual Science, Institute of Science Tokyo, Tokyo, Japan
[2]Department of Diagnostic Radiology and Nuclear Medicine, Institute of Science Tokyo, Tokyo, Japan

Correspondence: Hiroyuki Takahashi, Department of Ophthalmology and Visual Science, Institute of Science Tokyo, Yushima1-5-45, Bunkyo-ku, Tokyo 1138519, Japan; t.hiroyuki.oph@tmd.ac.jp.

Received: August 29, 2024
Accepted: February 18, 2025
Published: April 7, 2025

Citation: Takahashi T, Yokoi-Igarashi T, Takahashi H, et al. Evaluating the volume of eyes with pathologic myopia using 3D MRI. *Invest Ophthalmol Vis Sci.* 2025;66(4):13. https://doi.org/10.1167/iovs.66.4.13

Purpose. To determine the volume of eyes and its relationship to the shape and the presence of posterior staphylomas in patients with high myopia (HM).

Methods. We studied 370 eyes of 199 patients with HM (refractive error >8.00 diopters [D] or an axial length ≥26.5 mm) and 44 eyes of 35 control patients without HM (refractive error from −7.50 to +2.50 D). Magnetic resonance imaging (MRI) of the ocular orbit was used to measure the volume of the eye using three-dimensional (3D) MRI. Reconstructed 3D images of eye were classified according to symmetry and steepness of the posterior curvature.

Results. The mean volume was 12.42 ± 2.40 mL of the 370 HM eyes and 9.67 ± 1.41 mL of the 44 non-HM eyes. Thus, the volume of the HM eyes was 1.3 times larger than the mean volume of the non-HM eyes. The mean volume of the eye was significantly smaller in the cylindrically shaped and larger in barrel-shaped eyes than the eyes with other shapes. The mean eye volume in the HM eyes with a posterior staphyloma was not significantly different from that of HM eyes without a posterior staphyloma.

Conclusions. The volume of HM eyes is larger than non-HM eyes and is associated with steepness of posterior curvature but not with the presence of a posterior staphyloma, suggesting that local outward protrusion of the posterior eye wall is not directly caused by global expansion of eyes and should be monitored specifically in HM eyes.

Keywords: 3D MRI, pathologic myopia, high myopia, posterior staphyloma

Pathologic myopia (PM) is a major cause of irreversible vision loss and blindness worldwide, especially in eastern Asian countries.[1–7] The META-analysis for pathologic myopia (META-PM) study categorized eyes with PM by the presence of the complications in the fundus, including posterior staphylomas and myopic maculopathy equal to or more severe than diffuse choroidal atrophy.[6–9] Earlier studies have shown that ocular complications were detected more frequently in eyes with high myopia (HM), and the best-corrected visual acuity was worse in eyes with a staphyloma than eyes without a staphyloma.[10] Although the presence of a staphyloma is an important feature of PM and has a great impact on the visual acuity and anatomic progression of PM, it has been difficult to identify a staphyloma objectively because they are large and extend beyond the field of view of conventional fundus cameras.

To overcome this difficulty, Moriyama et al.[11] developed a technique called three-dimensional magnetic resonance imaging (3D MRI) that can determine the shape of the eye. They classified the shape of highly myopic eyes into four types: the barrel type, cylindrical type, nasally distorted type, and temporally distorted type, based on the symmetry and the radius of curvature of the posterior pole of the eye. MRI-based volume measurements have been established, especially in volume measurements of the prostate gland. At least eight MRI studies evaluated the volume and shape of the eye.[11–18] Relevant to our study, Nagra et al.[19] used 3D MRI images to determine the volume of the eyes of 67 adults whose refractive error ranged from −10.56 to +4.38 diopters (D). The average volume was 8.17 ± 1.14 mL. They also showed that the volume of the eye was correlated with the axial length (AL) of the eye. However, the mean AL of their subjects was 24.51 ± 1.47 mm, and severely elongated eyes (e.g., axial length >30 mm) were not studied.

Although eye shape analyses using 3D MRI images have been performed, it is still not clear whether a staphyloma was the final process in the continuum of AL elongation or whether staphyloma was a phenomenon independent from the elongation of the AL. We have examined both types of eyes: eyes with a large volume without a staphyloma and eyes with a relatively small volume with a deep staphyloma at the Myopia Center of the Tokyo Medical and Dental University.[10] These observations allowed us to

Copyright 2025 The Authors

This work is licensed under a Creative Commons Attribution-NonCommercial-NoDerivatives 4.0 International License.

suggest that increases in the ocular volume may not be related to the formation of staphylomas. However, the relationship between the volume of an eye and the presence of posterior staphyloma has not been investigated yet in large case cohorts.

Thus, the purpose of this study was to compare the ocular volume of HM to that of non-HM eyes and also to determine the effect of a posterior staphyloma on the volume of the eye. To our knowledge, this is the first large-scale study to use 3D MRI for evaluating the correlation between the ocular volume and posterior staphyloma.

Materials and Methods

The procedures used in this study were approved by the Ethics Committee of Institute of Science Tokyo (#M2000-2278), and they conformed to the tenets of the Declaration of Helsinki. A signed informed consent was obtained from all participants.

The medical records of patients with HM who were examined by 3D MRI (SYNAPSE VINCENT; Fujifilm, Tokyo, Japan) to determine the shape of the eye in the primary position between April 2010 and August 2014 were analyzed. For controls, the medical records of non-HM patients examined by 3D MRI during the study period were evaluated. Some non-HM participants were current or former staff members at the Institute of Science Tokyo, and others were patients who had eye diseases such as strabismus. There were no cases with severe strabismus that could affect the visual function, including binocular vision and stereopsis in non-HM participants.

The inclusion criteria were patients with HM who had been examined by 3D MRI for the investigation of the eye shape and volume. The eye volume is defined as the total volume of the anterior chamber, posterior chamber, and vitreous chamber. HM was defined as a myopic refractive error (spherical equivalent) of >8.0 D or an axial length ≥26.5 mm according to the definition of the Ministry of Health and Welfare, Japan.

The exclusion criteria were a history of vitreoretinal or glaucoma surgeries that could have affected the shape of the globe or those having other ocular disorders causing HM or pathologic myopia, such as congenital stationary night blindness, retinitis pigmentosa, or Stickler syndrome. Patients with media opacities, including nuclear cataract or strabismus fixus, which is HM-related acquired strabismus due to the enlarged globe from whom good fundus photographs and optical coherence tomography (OCT) images were difficult to obtain, were also excluded.

Patients underwent a comprehensive ophthalmologic examination, including measurements of the axial length (IOL Master; Carl Zeiss Meditec, Jena, Germany) and refractive error with an autorefractometer (ARK-730; Nidek, Nagoya, Japan) without cycloplegia, stereoscopic dilated fundus examination, and color fundus photography (TRC-50DX [Topcon, Tokyo, Japan] or Optos 200Tx scanning laser ophthalmoscope [Optos PLC, Dunferm-line, Scotland, UK]). OCT images were acquired by swept source OCT (DRI Triton; Topcon Corporation, Tokyo, Japan) to evaluate macular complications for each patient. The data used in this study were taken during a single visit, and the average value of three or more reliable measurements was collected as the data for axial length and refractive error before the MRI scan. This study is a retrospective review of prospectively collected MRI images in combination with other clinical data.

3D MRI

The 3D MRI was performed using the 1.5-T MR system (Signa HDxt 1.5T; General Electric Healthcare, Waukesha, WI, USA) with an eight-channel phased-array head coil. This technique was used to obtain high-contrast delineation of the edges of the eye and was described in detail.[11] The data set of 3D CUBE T2WI was processed to the 3D volume-rendering reconstruction (VR) and multiplanar reconstructions (MPRs) by a volume analyzer workstation (SYNAPSE VINCENT; Fujifilm). The voxel size was 0.86 mm (length) × 0.86 mm (width) × 1.2 mm (height). Two authors (TT and TI) manually identified the margins of the globe on the VR data with reference to the MPR image and carefully removed the tissues on the outside of the globe (Supplementary Fig. S1). Finally, the total ocular volume was calculated automatically by counting the voxels based on the segmentation of the globe. We measured the volume twice and used the average for the numerical data. The measurement was conducted without knowing the previous measurement data.

To calculate the vertical and lateral length of the eye using the 3D MRI images, the views of the eye from six directions (anterior, posterior, superior, inferior, nasal, and temporal) were incorporated into the software of the 3D MRI images. A central axis line was drawn automatically by the software, and vertical and lateral lines were drawn automatically based on the central axis (Supplementary Fig. S1). The details of this procedure have been reported in our previous publications.[11]

Classification of Eye Shapes Based on 3D MRI Images

The eye shape was quantitatively and objectively evaluated based on symmetry and pointedness of the posterior part of the eye wall, as described in our previous publication.[20] The eye shapes were classified into five types automatically: spherical, nasally distorted, temporally distorted, cylindrical (curvatures of the nasal half and temporal half were approximately equal and more curved than a circle), and barrel (curvature of the nasal half and temporal half was flatter than a circle).

Definition of Staphylomas

The 3D MRI allowed us to view a staphyloma from all angles. Six views of the eye were analyzed by the 3D MRI software for the detection of a staphyloma. A staphyloma was identified by observing an outpouching or a notch of the outer surface of the vitreous cavity viewed in the T2-weighted 3D MRI images as in an earlier study.[11]

Especially in the HM group, we determined the effect of the eye shape, staphyloma presence, myopic maculopathy, or the various ocular complications associated with high myopia on the eye volume. Myopic maculopathy with various kinds of fundus lesions associated with high myopia was diagnosed according to META-PM study classification.[21] The diagnosis of myopic traction maculopathy (MTM) was made on cross-sectional OCT images according to the criteria reported by Panozzo and Mercanti.[22] Eyes with MTM include those with myopic retinoschisis, vitreomacular traction, retinal thickening, lamellar macular hole, and foveal retinal detachment. Myopic and glaucoma-like optic neuropathy (MGON) were diagnosed by the loss of visual fields due to stretching and distortion of the optic nerve disc in highly

myopic eyes or eyes with glaucoma after confirming that the impact of the retinal lesions on the visual field was not present.[23]

Statistical Analyses

The SPSS 22.0 software (IBM-SPSS, Chicago, IL, USA) was used for all statistical analyses. The values of the main parameters are presented as the means ± standard deviations. The baseline clinical characteristics were compared between eyes with HM and non-HM using χ^2 tests and Student's *t*-tests. The ocular biometric values were compared using Student's *t*-tests. The significance of the correlations between the ocular volume and other numerical data was determined by Spearman's rank correlation coefficient. In the HM group, the difference of eye volume was compared among eyes with various eye shapes or macular complications using Kruskal–Wallis or Mann–Whitney *U* tests. A *P* value of <0.05 was taken to be statistically significant.

The measurement of volume was examined twice by two authors (TT, TI) to assess the repeatability. Interclass and intraclass correlation coefficients (ICCs) were calculated for interobserver comparison. ICC was considered "good" if ICC >0.75 and "excellent" if ICC >0.9. We also performed multiple regression analyses to determine the significance of the correlations between the volume of the eye and various ocular parameters. The dependent variable was the volume of the eye, and the independent variables were age, sex, axial length, eye shape, the existence of a staphyloma, and myopic maculopathy.

Results

The data of 370 eyes of 199 consecutive patients (41 men, 20.6%) with HM and 44 eyes of 35 patients (6 men, 17.1%) with non-HM were analyzed. The mean age of 370 patients with HM and 44 non-HM patients was 61.25 ± 12.87 (range, 29–88) and 71.4 ± 9.86 (range, 39–82), respectively. The clinical characteristics of the HM eyes are compared to those of the non-HM eyes in Table 1. Twenty-three eyes were excluded because of strabismus fixus caused by extremely long axial length. In 82 eyes, fundus photographs and/or OCT images were not examined or, if examined, not clear enough to determine the type of lesions of myopic maculopathy or myopic traction maculopathy. These cases were excluded, and the remaining 309 eyes were further analyzed for their myopic complications.

Eye Shape and Staphyloma Determined by 3D MRI Images

The shape of the eye and the staphyloma data determined from the 3D MRI images of 289 eyes of 155 patients (32 men, 20.6%), whose 3D MRI images are analyzed in detail, are summarized in Supplementary Table S2. Interestingly, the temporally distorted type was found only in the HM eyes, suggesting that this shape may be unique to HM. The differences in the prevalence of the different shapes between HM and non-HM eyes were not significant (Supplementary Table S1).

In contrast, a staphyloma was present in 201 of the 270 eyes (74.4%) with HM, and no staphyloma was found in the non-HM eyes. None of the spherically shaped eyes had a staphyloma. The differences in the frequency of staphylomas for each eye shape were not significant except for the spherical type.

Comparison of the Volume Between HM Eyes and Non–HM Eyes

The distribution of the eye volume in HM and non-HM eyes is shown in Figure 1. The mean eye volume was 9.67 ± 1.41 mL (7.88–14.79 mL) in the non-HM eyes and 12.42 ± 2.40 mL (8.17–24.95 mL) in the HM eyes. The mean eye volume in the HM eyes was approximately 1.3 times larger than in the non-HM eyes. The largest eye volume was about 25.0 mL, which was three times larger than the mean volume of the non-HM eyes.

The comparison of the biometric factors, including the axial length, vertical length, lateral length, and volume of

Table 1. Clinical Characteristics of Eyes With HM and Non-HM

Characteristic	HM	Non-HM	*P* Value
Eyes (patients)	370 (199)	44 (35)	
Sex (male/female)	41/158	6/29	0.705
Age (range), y	61.25 ± 12.87 (29–88)	71.4 ± 9.86 (39–82)	<0.01*
Refractive error (range), D	−14.76 ± 5.93 (−44 to −7.5)	−2.73 ± 2.58 (−7.5 to +2.5)	<0.01*
Myopic maculopathy†			
Category			
0	9 (2.9)	9 (47.4)	
1	91 (29.4)	5 (26.3)	
2	90 (29.1)	5 (26.3)	
3	57 (18.4)	—	
4	62 (20.1)	—	
Myopic traction maculopathy†			
Absent	245 (79.2)	19 (100.0)	
Present	64 (20.7)	—	
History of MGON†			
Absent	239 (77.3)	19 (100.0)	
Present	70 (22.7)	—	

Values are presented as number (%) or mean ± SD.
* Mann–Whitney *U* test.
† The incidence of myopic maculopathy, myopic traction maculopathy, and MGON was investigated for 309 eyes whose fundus photo and OCT images are available.

Investigative Ophthalmology & Visual Science

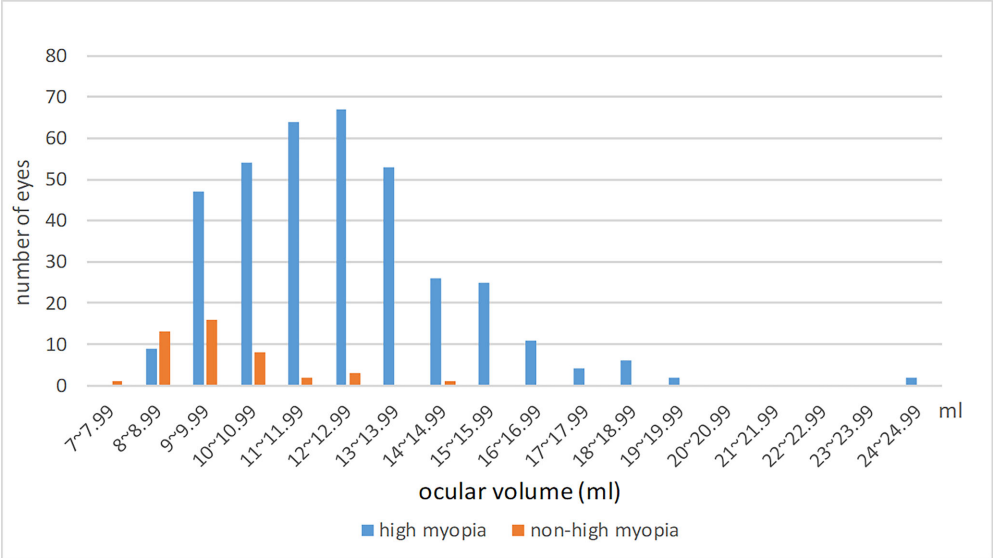

Figure 1. Distribution of volumes in HM and non-HM eyes. The mean eye volume in HM eyes was around 1.3 times larger than that of non-HM ones. The largest eye volume was about 25.0 mL, which was three times larger than the mean volume of non-HM.

Table 2. Results of Biometric Values in Eyes With HM and Non-HM

Characteristic	HM	Non-HM	*P* Value
Number of eyes	370	44	
Volume, mL	12.42 ± 2.40 (8.17–24.95)	9.67 ± 1.41 (7.88–14.79)	<0.001**
Axial length, mm	30.17 ± 2.35 (25.99–40.0)	24.73 ± 1.08 (22.46–26.42)	<0.001**
Vertical length, mm	24.2 ± 1.31 (21.8–29)	23.9 ± 0.82 (22.3–25.7)	0.109
Lateral length, mm	25.3 ± 1.81 (22.2–32.4)	24.7 ± 1.12 (22.6–26.2)	0.04*

Values are presented as mean ± SD (range).
* $P < 0.05$.
** $P < 0.01$, Mann–Whitney *U* test.

the eyes between the HM and non-HM groups, is shown in Table 2. The AL, lateral length, and ocular volume were significantly larger in HM eyes than in the non-HM control eyes (axial length: HM, 30.17 ± 2.35 vs. non-HM, 24.73 ± 1.08, $P < 0.001$; lateral length: HM, 25.3 ± 1.81 vs. non-HM, 24.7 ± 1.12, $P = 0.04$; volume: HM, 12.42 ± 2.40 vs. non-HM, 9.67 ± 1.41, $P < 0.001$). However, there was no significant difference in the vertical length (HM, 24.2 ± 1.31 vs. non-HM, 23.9 ± 0.82 mm, $P = 0.109$).

On 3D MRI images, the barrel shape was most commonly seen in both the HM and non-HM groups, and the distribution of eye shape was not significantly different between the two groups (Supplementary Table S1). Temporally distorted eye shape and posterior staphylomas were seen only in the HM group but not in the non-HM group.

Comparison of the Volume Among Highly Myopic Eyes With Different Eye Shape

In HM eyes, the volume tended to be the largest in eyes with the barrel shape, followed by the temporally distorted type, the nasally distorted type, the spherical type, and the cylindrical type. The volume was significantly smaller in the cylindrical type than the other types (Table 3 and Fig. 2A). The eyes with the spherical shape had significantly shorter ALs than the other eye shapes (Fig. 2B). However, there were

Table 3. Effect of Eye Shape on Biometric Values in Eyes With HM

	Eye Shape					
Characteristic	Spherical	Cylindrical	Nasal	Barrel	Temporal	*P* Value
Number of eyes	23	63	74	80	30	
Volume, mL	12.1 ± 1.53	11.56 ± 2.04	12.62 ± 2.51§	13.12 ± 2.13§	12.95 ± 3.48§	0.004*
AL, mm	28.34 ± 1.38	29.67 ± 2.17	30.15 ± 2.45†	30.49 ± 2.06†	31.36 ± 2.41†‡	<0.001**
Vertical length, mm	24.14 ± 0.69	23.82 ± 0.94	24.20 ± 0.96	24.38 ± 0.89	24.59 ± 1.48	0.125
Lateral length, mm	24.42 ± 0.78	24.48 ± 1.15	24.74 ± 1.60	24.84 ± 1.07	25.28 ± 2.25	0.139

* $P < 0.05$.
** $P < 0.001$, Kruskal–Wallis test.
§ $P < 0.05$ compared to volume of cylinder type.
† $P < 0.05$ compared to axial length of spherical type.
‡ $P < 0.05$ compared to axial length of cylinder type, Bonferroni test.

Investigative Ophthalmology & Visual Science

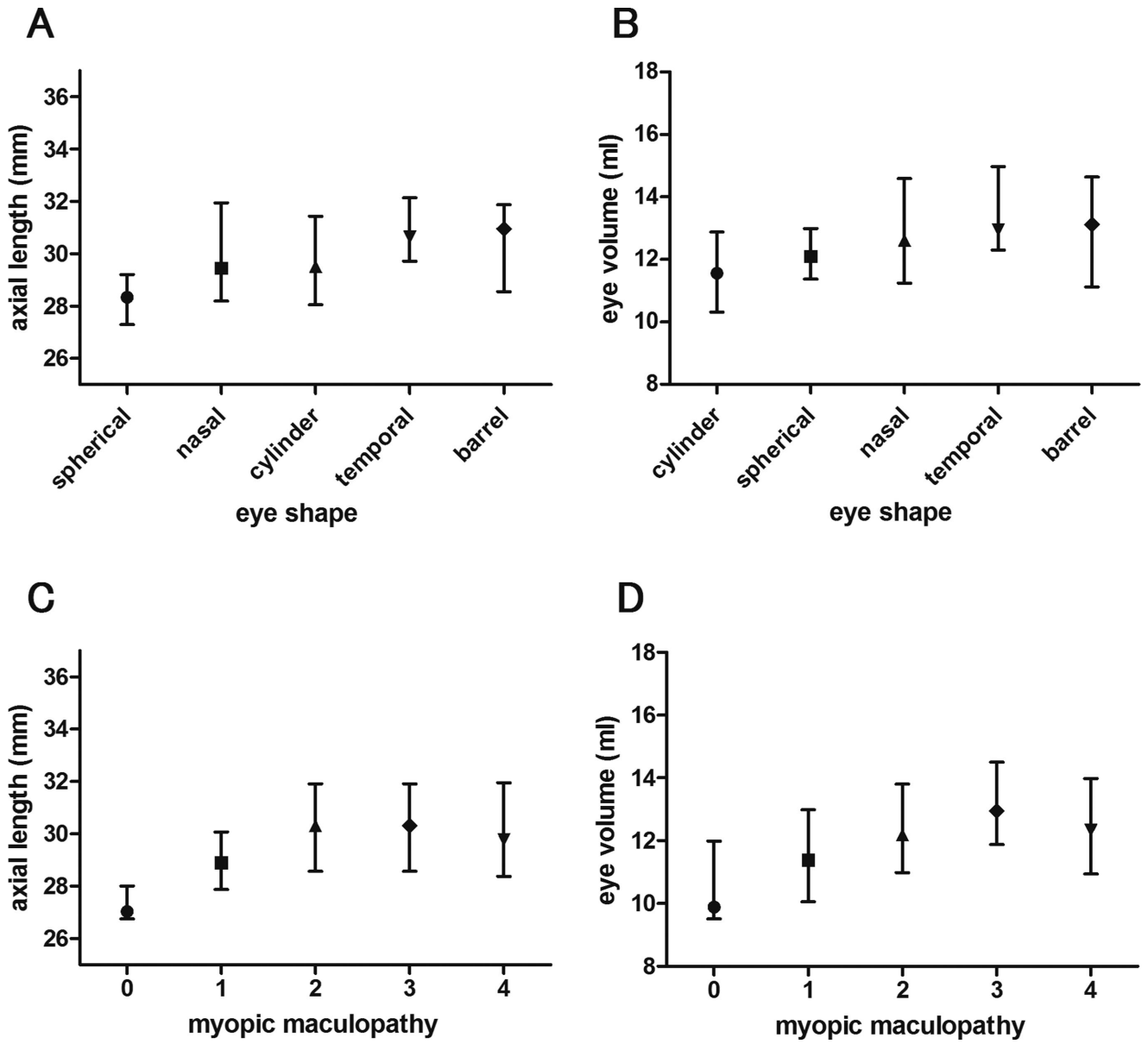

Figure 2. Changes in axial length and volume based on the eye shape and myopic maculopathy. (**A**) Association between eye shape and axial length. The spherical type had the shortest axial length. (**B**) Cylindric type had the smallest volume. (**C**) Association with myopic maculopathy (using META-PM classification) and axial length; axial length is larger with the increase in the category of myopic maculopathy. (**D**) Association with myopic maculopathy (META-PM classification) and volume; volume is larger depending on the severity of the myopic maculopathy. *$P < 0.05$, Kruskal–Wallis test. BCVA, best-corrected visual acuity; MNV, myopic macular neovascularization; PM, pathologic myopia; staphyloma, posterior staphyloma.

no significant differences in the vertical lengths and lateral lengths for the different eye shapes (Kruskal–Wallis test; $P = 0.125$, 0.139). Thus, the cylindrical type had the smallest volume because the scleral shape of the posterior pole was conical. Representative cases are shown in Supplementary Figures S2, S3, and S4.

Comparison of the Volume Between Highly Myopic Eyes With and Without Staphyloma

The mean volume of HM eyes with a staphyloma was 12.28 ± 2.58 mL with a range of 8.17 to 24.95 mL, which was not significantly different from the 12.66 ± 2.26 mL with a range of 8.88 to 18.17 in HM eyes without a staphyloma ($P = 0.292$; Table 4). However, the difference in the AL between HM eyes with (29.42 ± 1.94 mL) and without (30.42 ± 2.40 mL) a staphyloma was significant ($P = 0.006$). The differences in the lateral and vertical lengths of HM eyes with and without a staphyloma were not significant ($P = 0.927$ and $P = 0.618$). Regarding the eye shape, the presence of staphyloma was not different among eyes with different eye shapes in HM eyes.

Relationship Between Ocular Volume and Ocular Comorbidities in High Myopia

The mean volume of HM eyes with grade 2, 3, and 4 myopic maculopathy was larger than that of those with grade 0 but

Investigative Ophthalmology & Visual Science

Table 4. Comparisons of Biometric Values in HM Eyes With or Without Staphyloma

Characteristic	Posterior Staphyloma		*P* Value
	Not Present	Present	
Number of eyes	69	201	
Volume, mL	12.66 ± 2.26	12.28 ± 2.58	0.292*
Axial length, mm	29.42 ± 1.94	30.42 ± 2.40	0.006*
Vertical length, mm	24.4 ± 0.92	24.41 ± 1.06	0.618*
Lateral length, mm	24.5 ± 1.24	24.7 ± 1.4	0.927*

* Mann–Whitney *U* test.

not with grade 1. The mean AL of HM eyes with grade 2, 3, and 4 myopic maculopathy was longer than that of those with grades 0 and 1 (Supplementary Table S2). However, the presence of MTM, myopic macular neovascularization, or MGON was not associated with the volume and the AL of the HM eyes.

Multiple Regression Analysis to Determine Significance of the Different Ocular Characteristics on Volume of Eye

The results of multiple regression analysis showed that the ocular volume was significantly associated with a longer AL, younger age, and absence of a staphyloma ($P < 0.001$; standardized partial regression coefficient = 0.629, $P = 0.001$; standardized partial regression coefficient = −0.195, $P = 0.09$; standardized partial regression coefficient = −0.144, respectively; Supplementary Table S3). Thus, the longer the AL and the younger the age, the larger the eye volume. On the other hand, the presence of a posterior staphyloma was negatively correlated with the eye volume. There was no significant association between sex, category of myopic maculopathy, eye shape, and ocular complications related to the high myopia.

Measurement Repeatability

We measured the volume twice and used the average for the numerical data. There were no cases with large deviations of the numerical data. The average intra- and interobserver ICCs were equally high, reaching 0.89 and 0.86, which suggested that the eye volume measurements using 3D MRI were repeatable. We also compared the measurement data about axial length. Axial length was measured in two ways: 3D MRI and IOL master. The ICC was 0.96, which suggested that the measurement was objectively valid.

Discussion

Our results showed how large HM eyes can become compared to non-HM eyes.

The mean eye volume in HM eyes was approximately 1.3 times larger than that of non-HM eyes. The largest volume was about 25.0 mL, which was three times larger than the mean volume of non-HM eyes (mean volume: 9.67 ± 1.41). Interestingly, the volume of some of the HM eyes was very large, and there were 21 eyes whose eye volume exceeded 16 mL (Supplementary Figures S2 to S4).

There was a significant difference in the AL and lateral length between the HM eyes and non-HM eyes. However, the difference between the vertical lengths was not significant. These findings indicated that HM eyes were enlarged by the expansion of the lateral and axial lengths. Earlier studies[11,20] also reported that HM eyes were long horizontally when viewed from the posterior, as was found in our study. Although the reasons for this have not been determined, the larger lateral orbital space may be the one explanation. Regarding the relationship with orbital space, Chau et al.[24] reported that orbital space does not have a correlation with eye size in adult humans. Ye et al.[25] reported that the eyeball and orbit rapidly developed synergically in early postnatal years and matured at around 8 or 9 years old. It is considered that there is a relationship between orbital space and ocular expansion associated with the emmetropization process, but after that, orbital space is unlikely to relate to myopic ocular expansion.[24,25] On the other hand, there is periocular soft tissue around the eye, which would allow a greater expansion in the posterior and lateral direction. Orbital pulley systems consist of collagen, elastin, and smooth muscles. The lateral rectus pulley and lateral rectus–superior rectus band comprise dense collagen and may contribute to globe dilation in myopia, which may lead to a more laterally stretched eye shape than vertically.[26]

The barrel-shaped eyes were more common than the other types of non-HM eyes. The barrel-shaped eyes were detected in 36.8% of the eyes followed by nasal, spherical, and cylindrical all at 21.1% (Supplementary Table S1). Statistically, there was no significant difference in the prevalence of different eye shapes between the HM and non-HM eyes. The reason why both HM and non-HM eyes have a barrel shape in common remains an open question. It has been reported that the eye shape shifts from a circular to an elliptical form as the equatorial region of the eyeball expands after the period of postnatal growth.[27] Although we did not analyze the age-dependent difference of eye shape, we believe that equatorial extension makes eye shapes elliptical or barrel shaped.

The temporally distorted type eye was found in only HM eyes, and none of the non-HM eyes had this shape. Temporal distorted shape was considered to be caused by a posterior outpouching of macular sclera that is mainly due to a formation of macular staphyloma. In contrast to the temporal distorted shape, the nasally distorted shape is considered to be caused by a posterior displacement of the optic disc due to peripapillary atrophy or peripapillary intrachoroidal cavitations[28–31] in addition to peripapillary staphyloma. The former two lesions have been reported to occur in mild or moderately myopic eyes as well. This suggests that the asymmetrical eye shape can also occur in non-HM eyes, but the temporally distorted shape is still limited to HM eyes.

In HM eyes, the volume was the smallest in cylindrical-shaped eyes, and there was a significant difference in the eye volume between the cylindrical type and the other types except the spherical type (Fig. 2A). There was also a significant difference in the AL among the different eye shapes (Table 3). The AL was shorter in spherical- and cylindrical-shaped eyes than in the other types. In addition, the vertical length was the shortest in cylindrical-shaped eyes, although the difference was not significant. In cylindrical-shaped eyes, a posterior focal area protruded, and the scleral curvature of the surrounding area was flattened in some of the eyes. These findings suggested that the smallest eye volume in cylindrical-shaped eyes was not only because the posterior scleral pole was conical but also because the axial and vertical lengths were shorter. However, this conclusion needs further investigations, including longitudinal observations.

Investigative Ophthalmology & Visual Science

Based on the 3D MRI images, a staphyloma was found in 73.6% of HM eyes, whereas none of the non-HM eyes had it. In HM eyes, the prevalence of a staphyloma was not significantly different among the different eye shapes. A staphyloma was not detected in spherical-shaped eyes but was almost equally distributed among the other shaped eyes. To our knowledge, the relationship between eye shapes and staphyloma has not been studied with 3D MRI, and our data suggest that the formation of a staphyloma and the eye shape are independent phenomena.

The difference in the eye volume and AL between HM eyes with and without staphyloma was not significant. This suggested that staphyloma formation may be an independent phenomenon apart from that controlling the AL increases. The elongation of the AL is mainly caused by an expansion of the equatorial region of the sclera, while staphylomas involve mainly the posterior pole. Thus, the areas involved are different for axial elongation and staphyloma development.

Interestingly, staphyloma formation tended to be correlated with reduced eye volume according to our multiple regression analysis. This may be explained by the flattening of the scleral curvature anteriorly in staphylomas, as reported for inferior staphylomas.[32] Staphylomas affect the posterior pole of the eye, which contains visually important tissues such as the macular retina and the optic nerve. Thus, our results support the concept that a staphyloma not only affects the AL but also is a much more important factor in affecting the vision in HM eyes, as Curtin[33] suggested.

This study has some limitations. First, this study was a single-center study, and there may have been selection bias of the participants. Thus, the results cannot be applied to all HM cases. Second, we might have missed some staphyloma cases because the resolution of 3D MRI was lower than ultra-widefield OCT. Third, there could have been variance of the ocular volume because two observers manually identified the margin of the globes on the virtual reality. Although its repeatability was good, this manual step could have induced some variance of measured values. Fourth, the number of non-HM cases was small, which made the comparisons of the HM and non-HM data less generalizable. In addition, the refractive power of eyes in the non-HM group ranged widely from +2.5 to −7.5 D. Although statistical analysis was not available due to the limited number of eyes, the mean volume of eyes increased in the order of high myopia, moderate or low myopia, and emmetropia or hyperopia (Supplementary Table S4). Fifth, we could not include strabismus fixus cases because we could not take clear OCT and fundus images. Strabismus fixus cases could have large eye volume and specific eye shape.

In conclusion, 3D MRI-based volumetry showed that HM eyes had larger eye volume than non-HM eyes. There was no significant difference in the eye volume between HM eyes with and without staphylomas. However, multivariable regression analysis showed that posterior staphyloma formation was correlated with reduced eye volume, which was possibly due to flattening of scleral curvature anteriorly in staphyloma.

Acknowledgments

The authors thank Duco Hamasaki of the Bascom Palmer Eye Institute, University of Miami, for his critical discussion and final manuscript revision.

Disclosure: **T. Takahashi**, None; **T. Yokoi-Igarashi**, None; **H. Takahashi**, None; **N. Nakao**, None; **K. Uramoto**, None; **T. Yoshida**, None; **M. Moriyama**, None; **K. Kamoi**, None; **K. Kimura**, None; **U. Tateishi**, None; **K. Ohno-Matsui**, Santen (C), Cooper Vision (C), Topcon (C), Eye Rising (C)

References

1. Xu L, Wang Y, Wang S, Jonas JB. High myopia and glaucoma susceptibility the Beijing Eye Study. *Ophthalmology*. 2007;114:216–220.
2. Liang IC, Shimada N, Tanaka Y, et al. Comparison of clinical features in highly myopic eyes with and without a dome-shaped macula. *Ophthalmology*. 2015;122:1591–1600.
3. Iwase A, Araie M, Tomidokoro A, et al. Prevalence and causes of low vision and blindness in a Japanese adult population: the Tajimi Study. *Ophthalmology*. 2006;113:1354–1362.
4. Wong TY, Ferreira A, Hughes R, Carter G, Mitchell P. Epidemiology and disease burden of pathologic myopia and myopic choroidal neovascularization: an evidence-based systematic review. *Am J Ophthalmol*. 2014;157(1):9–25.e12.
5. Holden BA, Fricke TR, Wilson DA, et al. Global prevalence of myopia and high myopia and temporal trends from 2000 through 2050. *Ophthalmology*. 2016;123(5):1036–1042.
6. Ohno-Matsui K, Spaide RF, Yanuzzi LA, et al. *Pathologic Myopia*. 2nd ed. New York: Springer; 2021.
7. Ohno-Matsui K, Wu PC, Yamashiro K, et al. IMI pathologic myopia. *Invest Ophthalmol Vis Sci*. 2021;62:5.
8. Flitcroft DI, He M, Jonas JB, et al. IMI—defining and classifying myopia: a proposed set of standards for clinical and epidemiologic studies. *Invest Ophthalmol Vis Sci*. 2019;60:M20–M30.
9. Ohno-Matsui K, Lai TY, Lai CC, Cheung CM. Updates of pathologic myopia. *Prog Retin Eye Res*. 2016;52:156–187.
10. Ohno-Matsui K. Proposed classification of posterior staphylomas based on analyses of eye shape by three-dimensional magnetic resonance imaging and wide-field fundus imaging. *Ophthalmology*. 2014;121:1798–1809.
11. Moriyama M, Ohno-Matsui K, Hayashi K, et al. Topographic analyses of shape of eyes with pathologic myopia by high-resolution three-dimensional magnetic resonance imaging. *Ophthalmology*. 2011;118:1626–1637.
12. Atchison DA, Jones CE, Schmid KL, et al. Eye shape in emmetropia and myopia. *Invest Ophthalmol Vis Sci*. 2004;45:3380–3386.
13. Atchison DA, Pritchard N, Schmid KL, Scott DH, Jones CE, Pope JM. Shape of the retinal surface in emmetropia and myopia. *Invest Ophthalmol Vis Sci*. 2005;46:2698–2707.
14. Lim LS, Chong GH, Tan PT, et al. Distribution and determinants of eye size and shape in newborn children: a magnetic resonance imaging analysis. *Invest Ophthalmol Vis Sci*. 2013;54:4791–4797.
15. Gilmartin B, Nagra M, Logan NS. Shape of the posterior vitreous chamber in human emmetropia and myopia. *Invest Ophthalmol Vis Sci*. 2013;54:7240–7251.
16. Lim LS, Yang X, Gazzard G, et al. Variations in eye volume, surface area, and shape with refractive error in young children by magnetic resonance imaging analysis. *Invest Ophthalmol Vis Sci*. 2011;52:8878–8883.
17. Kneepkens SCM, Marstal K, Polling J-R, et al. Eye size and shape in relation to refractive error in children: a magnetic resonance imaging study. *Invest Ophthalmol Vis Sci*. 2023;28;64(15):41.
18. Hamzaoui D, Montagne S, Granger B, et al. Prostate volume prediction on MRI: tools, accuracy and variability. *Eur Radiol*. 2022;32(7):4931–4941.

Investigative Ophthalmology & Visual Science

19. Nagra M, Gilmartin B, Logan NS. Estimation of ocular volume from axial length. *Br J Ophthalmol*. 2014;98:1697–1701.
20. Moriyama M, Ohno-Matsui K, Modegi T, et al. Quantitative analyses of high-resolution 3D MR images of highly myopic eyes to determine their shapes. *Invest Ophthalmol Vis Sci*. 2012;53:4510–4518.
21. Ohno-Matsui K, Kawasaki R, Jonas JB, et al. International photographic classification and grading system for myopic maculopathy. *Am J Ophthalmol*. 2015;159:877–883.e877.
22. Panozzo G, Mercanti A. Optical coherence tomography findings in myopic traction maculopathy. *Arch Ophthalmol*. 2004;122:1455–1460.
23. Ohno-Matsui K, Shimada N, Yasuzumi K, et al. Long-term development of significant visual field defects in highly myopic eyes. *Am J Ophthalmol*. 2011;152:256–265.e251.
24. Chau A, Fung K, Pak K, Yap M, et al. Is eye size related to orbit size in human subjects? *Ophthalmic Physiol Opt*. 2004;24(1):35–40.
25. Ye F, Ji Y, Chen Y, He F, Fan X. Orbital growth is associated with eyeball size: a study using CT-based three-dimensional techniques. *Curr Eye Res*. 2022;47(2):317–324.
26. Kono R, Poukens V, Demer JL. Quantitative analysis of the structure of the human extraocular muscle pulley system. *Invest Ophthalmol Vis Sci*. 2002;43(9):2923–2932.
27. Ishii K, Iwata H, Oshika T. Quantitative evaluation of changes in eyeball shape in emmetropization and myopic changes based on elliptic Fourier descriptors. *Invest Ophthalmol Vis Sci*. 2011;52:8585–8591.
28. Spaide RF, Akiba M, Ohno-Matsui K. Evaluation of peripapillary intrachoroidal cavitation with swept source and enhanced depth imaging optical coherence tomography. *Retina*. 2012;32:1037–1044.
29. Toranzo J, Cohen SY, Erginay A, Gaudric A. Peripapillary intrachoroidal cavitation in myopia. *Am J Ophthalmol*. 2005;140:731–732.
30. Wei YH, Yang CM, Chen MS, Shih YF, Ho TC. Peripapillary intrachoroidal cavitation in high myopia: reappraisal. *Eye (Lond)*. 2009;23:141–144.
31. Freund KB, Ciardella AP, Yannuzzi LA, et al. Peripapillary detachment in pathologic myopia. *Arch Ophthalmol*. 2003;121:197–204.
32. Shinohara K, Moriyama M, Shimada N, et al. Analyses of shape of eyes and structure of optic nerves in eyes with tilted disc syndrome by swept-source optical coherence tomography and three-dimensional magnetic resonance imaging. *Eye (Lond)*. 2013;27:1233–1241.
33. Curtin BJ. The posterior staphyloma of pathologic myopia. *Trans Am Ophthalmol Soc*. 1977;75:67–86.

Investigative Ophthalmology & Visual Science