Accepted Manuscript



Hypertrophic Mental Tubercles of the Mandible

Bonnie L. Padwa, DMD, MD, Nicole Beck, BA, Cory M. Resnick, DMD, MD

PII: S0278-2391(18)30269-6

DOI: 10.1016/j.joms.2018.03.011

Reference: YJOMS 58197

To appear in: *Journal of Oral and Maxillofacial Surgery*

Received Date: 12 January 2018

Revised Date: 6 March 2018

Accepted Date: 12 March 2018

Please cite this article as: Padwa BL, Beck N, Resnick CM, Hypertrophic Mental Tubercles of the Mandible, *Journal of Oral and Maxillofacial Surgery* (2018), doi: 10.1016/j.joms.2018.03.011.

This is a PDF file of an unedited manuscript that has been accepted for publication. As a service to our customers we are providing this early version of the manuscript. The manuscript will undergo copyediting, typesetting, and review of the resulting proof before it is published in its final form. Please note that during the production process errors may be discovered which could affect the content, and all legal disclaimers that apply to the journal pertain.

ACCEPTED MANUSCRIPT

Hypertrophic Mental Tubercles of the Mandible

Bonnie L. Padwa, DMD, MD[a], Nicole Beck, BA[b], Cory M. Resnick, DMD, MD[c]

[a]Associate Professor, Harvard School of Dental Medicine, Oral Surgeon in Chief, Department of Plastic and Oral Surgery, Boston Children's Hospital, Boston, MA
[b]Dental Student, Harvard School of Dental Medicine, Boston, MA
[c]Assistant Professor, Harvard School of Dental Medicine, Department of Plastic and Oral Surgery, Boston Children's Hospital, Boston, MA

Address correspondence and reprint requests:

Bonnie L. Padwa, DMD, MD

Department of Plastic and Oral Surgery

Boston Children's Hospital

300 Longwood Avenue, Boston, MA 02115

Phone: 617-355-6259

Fax: 617-738-1657

E-mail: Bonnie.Padwa@childrens.harvard.edu

Running Title: Hypertrophic Mental Tubercles

ABSTRACT

Purpose: Enlarged mental tubercles are rare benign exostoses that occur in children. The purpose of this study was to report a case series of patients with hypertrophic mental tubercles and propose a theory for their etiopathogenesis.

Patients and Methods: This is a retrospective case series of patients with hypertrophic mental tubercles. Medical records were reviewed for age, sex, clinical presentation, findings on physical examination and radiographic images, and management details. Descriptive data were summarized.

Results: The sample included 14 patients (71% males) who presented at a mean age of 12.9 ± 4.8 years **(**range: 6 – 21 years). The majority of subjects had bilaterally enlarged mental tubercles (n=8); unilateral cases were primarily on the left side (5/6). On clinical examination, a bony prominence in the parasymphyseal region was noted on palpation and occasionally by visual inspection. There was no tenderness to palpation or overlying skin changes. Typical radiographic features included asymmetry along the inferior border of the mandible in the parasymphyseal region on panoramic radiograph and prominence/enlargement of the mental tubercles on computed tomography scan. There was no evidence of cortical expansion, perforation or periosteal reaction. Three patients requested contouring of the hypertrophied tubercles.

Conclusions: Hypertrophic mental tubercles are rare bony exostoses that occur in children in a region where a confluence of facial muscles attach to the mandible. The etiology likely involves bone deposition occurring in an area of muscle pull.

ACCEPTED MANUSCRIPT

INTRODUCTION

Exostoses are localized, benign osseous projections that typically occur on the lingual aspect of the mandible. In a series of 2,478 subjects, the prevalence of mandibular tori was 7.75% with equal distribution between males and females [1]. These growths occur infrequently in children (incidence 1.48% in the 1st and 2nd decades of life) [1]. There are several case reports of exostoses occurring in other areas of the mandible [2-6]. To our knowledge, however, prominence of the mental tubercle(s) in children has only been reported in two patients [7, 8].

The purpose of this paper was to present our experience with enlarged mental tubercles of the mandible in children. The specific aims were to (1) document the presenting features and radiographic findings and (2) propose an etiopathogenic theory.

MATERIALS AND METHODS

To address the study question, we implemented a retrospective case series of children with hypertrophied mental tubercles occurring along the inferior border of the mandible. This study was approved by the Institutional Review Board of the Center for Applied Clinical Investigation at Boston Children's Hospital (protocol #X05-08-058).

Study Sample

The study population included subjects who presented to the Department of Plastic and Oral Surgery at Boston Children's Hospital between 2007 and 2016. To be included, subjects had to have unilateral or bilateral hypertrophied mental tubercle(s). Subjects were excluded if the bony prominence was intraoral (i.e. tori) or involved another region of the mandible.

Study Variables

Medical records were reviewed for age, sex, clinical presentation, findings on physical examination and radiographic images, and management details.

RESULTS

Fourteen healthy subjects (71% male) met the inclusion criteria. The mean age at presentation was 12.9 ± 4.8 years **(**range: 6 – 21 years). The majority of subjects had bilaterally enlarged mental tubercles (n=8), although one side was larger than the other side (n=4 left larger than right; n=4 right larger than left). Unilateral cases were primarily on the left side (5/6).

All hypertrophied tubercles were discovered incidentally by the patient and/or family and was the primary reason for evaluation. None of the subjects had subjective complaints of myofascial pain. Two subjects had a history of facial trauma. Two patients reported pain from a football helmet strap rubbing over the area. On clinical examination, a bony prominence on one or both sides of the symphysis occurring along the labial aspect of the inferior border of the mandible was noted by palpation, and was occasionally evident on visual inspection (Fig 1). There was neither tenderness to palpation nor overlying skin change. There was no evidence of masseter hypertrophy.

There were a total of 14 preoperative imaging studies: 6 panoramic radiographs, 3 computed tomography (CT) scans, 2 lateral cephalograms and 2 plain films of the mandible. The prominence was seen on the 3 CT scans and 4 of 6 panoramic radiographs. The hypertrophied mental tubercles could not be identified on the remaining 2 panoramic images, the lateral cephalograms or the plain films. The typical features included asymmetry along the inferior

border of the mandible in the parasymphyseal region on panoramic radiograph (Fig 2) and prominence/enlargement of the mental tubercles, containing normal cortical and trabecular bone, on CT scan (Fig 3). There was no cortical expansion, perforation or periosteal reaction. There was no coronoid elongation.

Three subjects requested contouring of the hypertrophied tubercles: 2 because of discomfort from a football helmet strap rubbing over the prominence and one due to esthetic concerns. For these patients, the bony prominence was accessed from an intraoral approach using a vestibular incision. The mentalis muscle was divided (Fig 4) and the periosteum was stripped from the inferior border of the mandible. A surgical bur was used to remove the prominence and contour the tubercles. In all cases, the contoured bone appeared normal and composed of both cortical and trabecular components. The overlying soft tissues were found to be normal in thickness and character. Symmetric mandibular contour was achieved in all cases. The other 11 subjects were satisfied with an explanation of the bony projection and were managed with observation.

DISCUSSION

The purpose of this study was to present our experience with enlarged mental tubercles of the mandible in children. The specific aims were to (1) document the presenting features and radiographic findings and (2) propose an etiopathogenic theory.

In our series, the hypertrophied mental tubercles were identified by the patient and/or family, and the majority were asymptomatic. Although most could be seen on panoramic radiographs, they were better visualized and characterized on CT. They were not well seen on

lateral cephalograms or plain films. Three subjects requested surgical contouring, and all were found to have normal cortical and trabecular bone in the contoured region.

Mandibular tori along the lingual aspect of the mandible are common intraoral osseous growths consisting of mature cortical and trabecular bone [9]. The mechanism responsible for tori development is unknown, but etiopathogenic theories include genetic factors, masticatory hyperfunction [9], trauma, and continued growth. The genetic theory is based on the finding of a subpopulation of mesenchymal stem cells in some mandibular tori with enhanced osteogenic differentiation secondary to suppression of Notch3 signaling [10]. Alternatively, exostoses may occur due to osseous growth and deformation from muscle tension. The osteogenic-periosteal stretch hypothesis proposed by Singh suggests that, because stress and stretch of the periosteum signals bone deposition, masticatory hyperfunction precipitates overzealous osteogenesis and development of tori [9, 11]. This theory is supported by observations of similar extracranial exostoses, such as retrocalcaneal exostoses, which occur on the heel where the Achilles tendon inserts [12]. Moss' functional matrix theory of facial growth is similar to the osteogenic-periosteal stretch theory, purporting that osseous deposition and resorption occur where muscles attach to periosteum, thereby altering the size and shape of the bone at the point of attachment [13]. Coronoid hyperplasia is illustrative of this concept, as the coronoid process elongates due to temporalis muscle function and becomes hyperplastic in cases of temporalis hyperactivity.

The etiopathogenesis of hypertrophic mental tubercles is likely also due to muscular hyperfunction. The platysma, mentalis, depressor anguli oris and depressor labii inferioris muscles insert on the labial surface of the mandible, and the anterior belly of the digastric muscle attaches to the inferior/lingual border in the parasymphyseal region [14]. The tension created by this confluence of muscles is most likely responsible for the enlarged mental tubercles seen in

some young patients. The finding of normal cortical and trabecular bone within the contoured/removed hypertrophic tubercles supports the theory that their formation is due to an extrinsic (muscular pull) mechanism rather than intraosseous pathology.

In conclusion, hypertrophic mental tubercles are a rare and benign finding that likely occur as a result of excessive muscular pull at the insertions of the facial and digastric muscles. Occasionally, patients will request removal due to irritation of the area or for cosmetic reasons. This resection can be performed from an intraoral approach, and the exostoses are found to contain normal cortical and trabecular bone.

ACCEPTED MANUSCRIPT

REFERENCES

1. Kolas S, Halperin V, Jefferis K, Huddleston S, Robinson HB: The occurrence of torus palatinus and torus mandibularis in 2,478 dental patients. Oral Surg Oral Med Oral Pathol 6:1134, 1953

2. Basha S, Dutt SC: Buccal-sided mandibular angle exostosis - A rare case report. Contemp Clin Dent 2:237, 2011

3. Huang D, He DM, Yang C, Chen MJ, Zhou Q, Dong MJ: Computer-assisted local resection for exostosis osteochondroma of the mandibular condyle. J Craniofac Surg 24:e446, 2013

4. Katz JO, Theisen FC, Mosby EL: Bony exostosis of the mandibular condyle. Oral Surg Oral Med Oral Pathol 75:783, 1993

5. Nayak SS, Nayak VS: A Rare Case of Mandibular Exostoses and its Review. J Clin Diagn Res 10:AJ01, 2016

6. Wood GA, Deister E: Anterior midline neck webbing with microgenia and symphyseal exostosis. Oral Surg Oral Med Oral Pathol 56:128, 1983

7. Westine JR: Bilateral Hypertrophy of Mental Tubercles. A Case Report. Dent Surv 41:49, 1965

8. Yenidunya MO, Yilmaz S: Hypertrophic mental tubercle of the mandible. Plast Reconstr Surg 103:2085, 1999

9. Cortes AR, Jin Z, Morrison MD, Arita ES, Song J, Tamimi F: Mandibular tori are associated with mechanical stress and mandibular shape. J Oral Maxillofac Surg 72:2115, 2014

ACCEPTED MANUSCRIPT

10. Dou XW, Park W, Lee S, Zhang QZ, Carrasco LR, Le AD: Loss of Notch3 Signaling Enhances Osteogenesis of Mesenchymal Stem Cells from Mandibular Torus. J Dent Res 96:347, 2017

11. Singh GD: On the etiology and significance of palatal and mandibular tori. Cranio 28:213, 2010

12. Hanft JR, Chang T, Levy AI, Rosenblum B, Jr., Southerland C, Jr., Weil LS: Grand rounds: Haglund's deformity and retrocalcaneal, intratendinous spurring. J Foot Ankle Surg 35:362, 1996

13. Moss ML, Salentijn L: The primary role of functional matrices in facial growth. Am J Orthod 55:566, 1969

14. Cunningham DJ: In Robinson A (ed) *Cunningham's Textbook of Anatomy*, (ed. 4). Harvard University, Boston, MA, William Wood, 1913, p 155

ACCEPTED MANUSCRIPT

LEGENDS

Fig 1. Bilateral hypertrophic tubercles (left larger than right) in a 14-year-old boy.

Fig 2. Panoramic radiograph of 12-year-old boy with enlarged left mental tubercle.

Fig 3. CT scan of 14-year-old boy with bilateral hypertrophic tubercles (left larger than right), without cortical expansion or perforation.

Fig 4. Enlarged mental tubercles seen after exposure through a vestibular incision.

ACCEPTED MANUSCRIPT

ACCEPTED MANUSCRIPT

ACCEPTED MANUSCRIPT

ACCEPTED MANUSCRIPT

ACCEPTED MANUSCRIPT

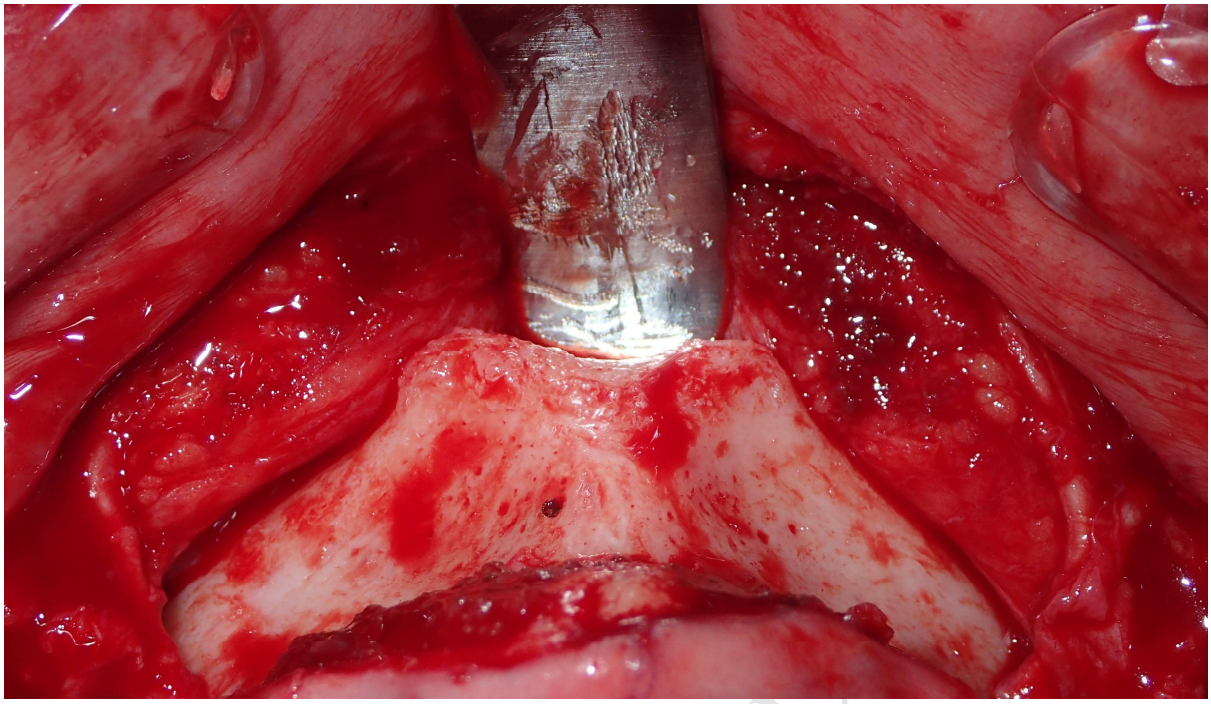

ACCEPTED MANUSCRIPT