2024 4th International Conference on Mobile Networks and Wireless Communications (ICMNWC)

A Comprehensive Analysis of Diabetic Retinopathy using Deep Learning Techniques

1st Raghu B R
Computer Science and Engineering
Srinivasa University
Mangalore, India
br.raghu585@gmail.com

2nd Janapati Venkata Krishna
Computer Science and Engineering
Institute of Engineering and Technology
Mangalore, India
venkatakrishna.janapati@gmail.com

2024 4th International Conference on Mobile Networks and Wireless Communications (ICMNWC) | 979-8-3315-2834-8/24/$31.00 ©2024 IEEE | DOI: 10.1109/ICMNWC63764.2024.10872197

***Abstract*—Diabetic Retinopathy (DR) is a diabetes-related retinal eye disease that affects retina and tissues at the back of the eyes, leading to compromised vision. DR occurs due to high blood sugar levels impairing blood vessels in retina. Diabetes is caused due to insufficient amounts of insulin in blood, which increases glucose levels, making it one of the most common disorders worldwide. People with diabetes experience damages to the nerves and blood vessels which also affect the heart, eyes, brains and kidneys. The stages of DR are: Non-Proliferative Diabetic Retinopathy (NPDR) that includes mild to moderate and severe NPDR, while PDR involves the evaluation of new and abnormal vessels in retinal fundus images. Deep Learning (DL) techniques like Long Short-Term Memory (LSTM), Deep Neural Network (DNN), transformer models, and Bi-directional LSTM(Bi-LSTM) are used to classify and detect DR in images. The evaluation metrics: specificity, sensitivity, accuracy, and F1-score are used to assess DR classification and detection using a DL method.**

Keywords—convolutional neural network- diabetic retinopathy- deep learning -long short-term memory-retinal fundus images.

I. Introduction

Diabetes mellitus (DM) shows significant global health concern that leads to a range of long-term complications, affecting both individuals and the society, particularly during their most peak years [1]. A human eye is composed of pupil, iris, cornea, macula, retina, optic nerve, and vitreous. A cornea, positioned at front of eye, helps in focusing on the incoming light [2]. The pupil and iris regulate the amount of incoming light into eye, while lens focuses light onto retina, the light-sensitive layer at the back of the eye. The retina converts light into electrical impulses, which are then transmitted to brain through the optic nerve [3]. Diabetic Retinopathy (DR) is diabetic eye disease that affects retina due to Diabetes Mellitus (DM). DR damages retinal tissue and blood vessels, causing them to leak fluid, which results in compromised vision. This damage causes various difficulties for diabetes patients [4]. The early diagnosis of diseases is crucial in healthcare, as early-stage conditions are manageable. Every year, millions of people worldwide are diagnosed with diabetes, which elevates blood glucose levels due to insufficient insulin production [5].

Patients with diabetes who are affected over a long period of 10 to 15 years often develop DR complications. Statistics indicate that 80% of people who suffer from diabetes, also suffer from DR [6]. The stages of DR include various conditions such as Exudates (EXs), Microaneurysms (MAs), Haemorrhages (HEs), abnormal Foveal Avascular Zone (FAZ), Neovascularization, abnormal structure of the Optic Disc (OD), and Cotton Wool Spots (CWSs) [7]. DR is a microvascular complication of DM with conditions such as vision-threatening diabetic retinopathy (VTDR), severe non-proliferative diabetic retinopathy (NPDR), diabetic macular edema (DME), and PDR. These conditions cause vision impairment and need early clinical treatment [8]. The automated classification and detection of DR typically involve three phases. The initially phase involves identifying lesions from fundus images, while the second phase comprises extracting the key features, and the third phase is designing a classifier [9]. Methods such as Grading Prediction Block (GPB), Egret Swarm Optimization algorithm (ESO), hybrid Convolutional Neural Network (CNN) models, and Deep Neural Network with Butterfly Optimization Algorithm (DNN-BOA) are employed to classification and detection of DR in images [10].

The rest of this paper is presented as follows: Section 2 explains taxonomy for classification and detection of diabetic retinopathy. Section 3 represents comparative analysis of various models. Section 4 discuss the problem statements related to DR detection using DL. Section 5 provides the conclusion of the paper.

II. Taxonomy

DL-based DR is mainly divided as classification and detection. Various DL methods such as CNN, LSTM, Bi-LSTM, DNN, and Transformer models are employed for classification and detection of DR and its severity levels. Fig. 1 illustrates taxonomy of DL-based DR classification and detection methods.

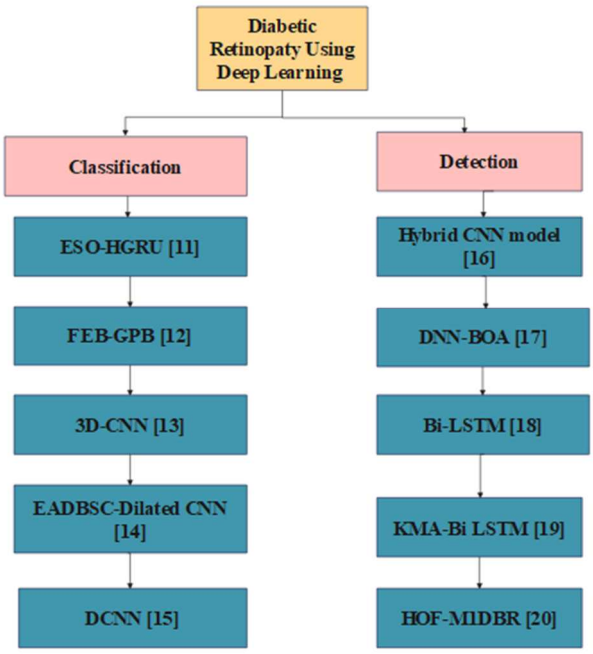

Fig. 1. Taxonomy of DR using DL methods

979-8-3315-2834-8/24/$31.00 ©2024 IEEE

Authorized licensed use limited to: Shah and Anchor Kutchhi Engineering College. Downloaded on April 19,2026 at 09:03:40 UTC from IEEE Xplore. Restrictions apply.

A. Deep Learning-based Classification

DL-based classification is the method of using Dl models such as neural networks to categorize input data into predefined classes. DR can be classified as mild DR, moderate DR, No DR, severe DR, proliferative DR. DL classification algorithms such as 3 -Dimensional Convolutional Neural Network (3D-CNN) and Deep CNN (DCNN), are commonly used for DR detection and classification.

1) ESO-HGRU: Alajlan and Razaque [11] developed an Egret Swarm Optimization algorithm-based Hybrid GRU (ESO-HGRU) to DR classification. The developed ESO-HGRU algorithm was an integration of CNN and Bi-directional Gated Current Unit (GRU), designed to identify DR by analysing the interdependencies among the different stages of the disease. Initially, input data was pre-processed through data augmentation techniques such as rotation and horizontal/vertical flip. A hybrid CNN-Bi-GRU model extracted information using egret swarm optimization for DR classification. The DR was classified into five phases as: moderate, severe, mild, no DR, and Proliferative DR. a combination of CNN and Bi-GRU allows a method for efficiently capture both temporal and spatial features in retinal images. However, training the ESO with CNN-BI-GRU required extra resources in terms of time and hardware which was a barrier in resource-constrained environments and healthcare settings.

2) FEB-GPB: Gu et al. [12] designed an intelligent DR classification system for fundus images and for its classification into five phases as, moderate, severe, mild, no DR, or the proliferative stage. The developed approach followed two key mechanisms namely, Grading Prediction Block (GPB) and Feature Extraction Block (FEB). The FEB was utilized for feature extraction from images of fundus, while the transformer mechanism provided fine-grained attention and enabled the capture of areas impacted by exudates and retinal hemorrhages. The GPB used for classifying into five stages of DR employed residual attention to efficiently focus on various regions associated with the different classes of DR. Transformers employed self-attention mechanisms that permitted the DR method to weigh the importance of various portions of the image. However, the transformer required large datasets, where obtaining sufficient labelled data was challenging. This limitation also caused potential overfitting or inadequate generalization.

3) 3D-CNN: Khaparde et al. [13] implemented a DR classification apporach using fundus images to improve treatment-based on the severity levels. The developed DL framework was an attention-based 3 Dimensional CNN (3D-CNN). The images were taken from real world benchmark datasets and passed into the preprocessing stage to remove unnecessary distortions. The pre-processed image was then moved onto the segmentation phase through an attention-based Swing U-Net to highlight the affected areas. The 3D-CNN was utilized for classification and segmentation of output images to categorize the DR images. The 3D-CNN analysed spatial features in multiple dimensions, allowing it to capture intricate patterns in the fundus images that were indicative of the severity levels of DR. However, data requirements necessitated large volumes of labelled fundus images to avoid overfitting and ensure generalization across diverse patient populations.

4) EADBSC-Dilated CNN: Thomas and Jerome [14] developed an Extended Adaptive Density-Based Spatial Clustering (EADBSC) and Improved Dilated Ensemble CNN model for DR classification. The images of fundus were taken from publicly available datasets like Messidor, Eye PACS, and from Chaithanya Eye hospital in Kerala. Firstly, these images were pre-processing using Contrast Limited Adaptive Histogram Equalization with Unsharp (CLAHEU) technique with a bilateral filter to noise reduction. Thick blood vessel segmentation was performed using EADBSC technique during the segmentation phase. The output of the segmentation phase was taken as input in the classification phase, while the ensemble CNNs such as Inception, Res Net, Mobile Net, and an improved Dilated Ensemble CNN determined the images, indicating DR or normal cases. The EADBSC approach was efficient in identifying and segmenting thick blood vessels in fundus images, which were important indicators of DR. However, the combination of EADBSC and Improved Dilated Ensemble CNN was highly reliant on the adequate tuning of hyperparameters.

5) DCNN: Dayana and Emmanuel [15] developed an optimal feature selection method for categorizing severity phases of DR in images based on DCNN. The pre-processing stage removed noise and improved contrast in images. After that, Coherence Enhancing Energy Based Regularized Level Set Evolution process is utilized for segmentation of blood vessel in the green channel fundus image. Candidate lesion regions were detected using an Attention-based Fusion Network (AFU-Net), while the texture and shape structures were extracted with optimal subsection of features chosen through Improved Harris Hawk Optimization algorithm. Lastly, the DCNN classified the stages of DR, while the DCNN model weights were reorganized using the same optimization algorithm.

B. Deep Learning -based Detection

Deep learning-based detection approach to deep learning models automatically identified and located specific patterns, regions, or objects of attention within an image. Detection focused on identifying specific areas in the image where irregularities were present. The techniques like hybrid Convolutional Neural Network (CNN), DNN and DNN-BOA have been used to detect patterns in images.

1) Hybrid CNN model: Toğaçar [16] developed CNN-based hybrid model for DR detection with the aim to improve the performance of CNN through preprocessing techniques. The hybrid CNN model followed three primary steps. In the primary phase, the Morphological Gradient approach was deployed to prevent parasitism noise in every image with the extraction of ocular vessels in images of fundus using segmentation method. In secondary phase, datasets like Asia Pacific Tele-Ophthalmology Society (APTOS), Eye PACS, and Messidor-2 were trained by transfer learning method and activation function where the last fully-connected layers were extracted for every class. Lastly, Atom Search Optimization (ASO) was used to select most dominant activation class from the extracted features for each category. The developed model enhanced feature learning and model's ability to detect

Authorized licensed use limited to: Shah and Anchor Kutchhi Engineering College. Downloaded on April 19,2026 at 09:03:40 UTC from IEEE Xplore. Restrictions apply.

patterns in images of fundus which resulted in better classification accuracy for different stages of DR. However, the hybrid model led to increased complexity and training time, making it challenging to implement settings for clinical development.

2) DNN-BOA: Rachapudi et al. [17] developed a model for DR detection-based on DNN with Butterfly Optimization Algorithm (DNN-BOA), which followed four phases: classification, pre-processing, segmentation and feature extraction. In stage of pre-processing, noise was eliminated from images using CLAHE filters. In the segmentation stage, Optic Disc (OD) was removed, and blood vessels and exudates were eliminated fully with resembling of fundus images. The exudates were segmented through MEM approach, while the features were extracted in the third phase through Gray Level Co-occurrence Matrix (GLCM) approach. In final stage, extracted features were categorized through DNN optimized with DNN-BOA to control various stages of DR. The BOA offered faster convergence and better optimization of DNN parameters, potentially increasing the presentation of the model and categorizing DR. However, the combination of BOA and DNN increased computational complexity and required extra processing time, especially in clinical diagnosis settings.

3) Bi-LSTM: Phridviraj et al. [18] introduced Bi-directional extended short-term memory-based DR system that employed retinol fundus images for classify and detect various grades of DR. In the preprocessing stage, DR model used Multiscale Retinex with Chroma city Preservation (MSRCP) process for improve contrast of fundus images with less modification to the medicinal features. MSRRCP was particularly designed to optimize image processing outcomes and the strength of MSRCP was its ability to highlight important features in the image.

4) KMA-Bi LSTM: Abirami and Kavitha [19] implemented Komodo Mlipir Algorithm (KMA) to optimize an Attention Bidirectional LSTM (ABi-LSTM) depending on automated diagnostic system for initial detection of DR in images of fundus. A retinal images from MESSIDOR and IDRiD databases and the severity levels of DR were recognized through grading. The attention-based Bi-LSTM metrices such as batch size, number of input layers, learning rate, and L2 regularization coefficient were optimized through KMA. The KMA and optimized ABi-LSTM technique categorized and detected DR abnormalities as NPDR, non-DR, moderate and severe NPDR. The attention-based Bi-LSTM system with KMA activated hyperparameter tuning process and improved the classification accuracy.

5) HOF-M1DBR: Krishnamoorthy et al. [20] designed a DR detection apporach based on a Hybrid Oppositional Frefy and Modified 1D Bidirectional recurrent (HOF-M1DBR) which detected DR using fundus images. The designed model grouping with DCNN, GRU and M1BiLSTM module was used for learning complex features. The Messidor-1 and APTOS-2019 datasets were useful for execution of cropping, smoothing, resizing and denoising of images. The M1DBR validated the model's accuracy, and Opposition-Based Learning-Fire Fly (OBL-FF) method was used for optimize weighting function. DR detection in fundus images was performed efficiently by differentiating DR into four stages from the extracted features.

III. Comparative Analysis

Diabetic Retinopathy using DL is assessed with the evaluation of the existing detection and classification approaches to improve the performance. Table1 represents the comparative analysis of existing methods.

TABLE I. Comparative Analysis of DR using DL Approaches

Author Name	Data set	Methodology	Performance Metrics	Training and Testing information
Alajlan and Razaque [11]	Idrid, APTOS 2019 blindness detection, Zenodo	ESO with CNN-Bi-GRU	Precision = 99.1%, Recall = 98.9%, F-measure = 99 %	Total images = 5590, Training= 3662, Testing = 1928
Gu et al. [12]	DDR and IDRiD	GPB	Sensitivity (SE) = 0.8140, Specificity (SP) = 0.8245, Accuracy = 0.8235	Total images= 13,673, Training = 6835, Testing =4105, Validation =2733
Khaparde et al. [13]	DIARETDB1, Retinal fundus Images Glaucoma Analysis (RIGA)	3 Dimensional CNN (3D-CNN)	Precision = 81.25 %, SP = 96 %, F1 score = 94.73 %, SE = 92.85 %	NA
Thomas and Jerome [14]	Public Messidor, Eye PACS, and the Chaithanya Eye hospital Kerala in house clinical datset.	DCNN	Accuracy = 99.19%	Training = 70%, Testing = 30%
Krishnamoorthy et al. [20]	Messidor-1 and APTOS-2019	OBL-FF	Accuracy = 98.9%	Training set = 80%, Testing set= 20%
Khan et al. [21]	Kaggle, Eye PACS dataset 97.5% of accuracy, 94.17% of recall, and 93.53% of f1-score, 95% of precision.	VGG- NiN	Precision = 95 %, Recall = 94.17%, Accuracy = 97.5 %, F1 score = 93.53%	NA
Bhimavarapu and Battineni [22]	1.DIARETDB0, 2.DRIVE, 3. CHASE	Improved CNN	Accuracy = 96.64%, SE = 97.96%, SP = 98.79%	1.Total = 130, Training = 110, Testing = 20 2.Total = 40, Training = 34, Testing = 8 3.Total = 32, Training = 28, Testing = 4
Chen et al. [23]	SMOTE synthetic dataset	NASNET -Large	Accuracy = 90 – 99 %	Training= 80%, Validation = 20%
Saeed et al. [24]	EyePACS and Messidor	ACNN	SE = 99.72 %, SP = 99.99%	Training = 80%, Validation = 10%, Testing = 10%

Authorized licensed use limited to: Shah and Anchor Kutchhi Engineering College. Downloaded on April 19,2026 at 09:03:40 UTC from IEEE Xplore. Restrictions apply.

Qureshi et al. [25]	EYEPACS dataset	active deep learning and CNN	SP = 92.20%, SE = 95.10%, Accuracy = 98%, F-Measure = 93%	NA

IV. Problem Statement

The problems in recent research analytics of DL-based DR classification and detection models are described in this section. Table 2 represents the problem statements DR detection using DL methods.

TABLE II. Problem Statement of DR using DL

Problem	Description
Data Imbalance	Data imbalance in DR increased because of severe phases such as Proliferative DR, which are rarer when compared to no DR and mild cases. This leads to fewer examples of critical phases in training datasets.
Preprocessing issue	Preprocessing in DR is challenging due to the factors of image quality, differences in resolution, noise and illumination, which can obscure important features.
Classification issue	Subtle differences between stages like minor microaneurysms in earlier phases versus haemorrhages, made it difficult for models to differentiate between them.
Segmentation issue	Segmenting the disease portions in retinal images was challenging because of the presence of other substances like exudates, microaneurysms and small lesions, which led to inaccurate classification results.

V. Conclusion

The DL-based Diabetic Retinopathy models are used to identify and diagnose eye diseases through classification and detection on fundus images. Datasets such as DIARETDB1, Retinal fundus Images Glaucoma Analysis (RIGA), Chaithanya Eye Hospital's (Kerala) in-house clinical dataset, and publically available Messidor, and Eye PACS were used for preprocessing fundus images. The phases of DR included Exudates (EXs), abnormal structure of Optic Disc (OD), Microaneurysms (MAs), Haemorrhages (HEs), Cotton Wool Spots (CWSs), abnormal Foveal Avascular Zone (FAZ), and Neovascularization. These models employed classification and detection methods such as 3 -Dimenisonal CNN (3D-CNN), DCNN, hybrid CNN, and DNN-BOA for the stages of pre-processing, segmentation, feature extraction and classification. These techniques categorized and detected DR abnormalities as NPDR, non-DR, moderate, and severe NPDR. The measures used to evaluate the efficacy of the predictive models are, recall, precision, sensitivity and F1score.

References

[1] N. Gundluru, D. S. Rajput, K. Lakshmanna, R. Kaluri, M. Shorfuzzaman, M. Uddin, and M. A. R. Khan, "Enhancement of detection of diabetic retinopathy using Harris hawk's optimization with deep learning model," Comput. Intell. Neurosci, vol. 2022, p. 8512469, May 2022.

[2] S. Sunkari, A. Sangam, V. P. Sreeram, M. Suchetha, R. Raman, R. Rajalakshmi, and S. Tamilselvi, "A refined ResNet18 architecture with Swish activation function for Diabetic Retinopathy classification," Biomed. Signal Process. Control, vol. 88A, p. 105630, February 2024.

[3] E. AbdelMaksoud, S. Barakat, and M. Elmogy, "A computer-aided diagnosis system for detecting various diabetic retinopathy grades-based on a hybrid deep learning technique," Medical & Biological Engineering & Computing, vol. 60, pp. 2015–2038, May 2022.

[4] B. Menaouer, Z. Dermane, N. El Houda Kebir, and N. Matta, "Diabetic retinopathy classification using hybrid deep learning approach," SN Comput. Sci, vol. 3, p. 357, July 2022.

[5] A. Joshi, and K. K. Sharma, "Graph deep network for optic disc and optic cup segmentation for glaucoma disease using retinal imaging," Phys. Eng. Sci. Med, vol. 45, pp. 847–858, June 2022.

[6] B. N. Bansode, K. M. B. Bakwad, A. S. Dildar, and G. S. Sable, "Deep CNN-based feature extraction with optimised LSTM for enhanced diabetic retinopathy detection," Computer Methods in Biomechanics and Biomedical Engineering: Imaging & Visualization, vol. 11, pp. 960–975, November 2023.

[7] D. Das, S. K. Biswas, and S. Bandyopadhyay, "Detection of diabetic retinopathy using convolutional neural networks for feature extraction and classification (DRFEC)," Multimedia Tools Appl, vol. 82, pp. 29943–30001, November 2022.

[8] X. Zhang, L. Fan, D. Li, Q. Wei, X. Han, B. Zhang, H. Chen, Y. Zhang, B. Mo, B. Hu, D. Ding, X. Li, W. Yu, and Y. Chen, "Automated detection of severe diabetic retinopathy using deep learning method," Graefe's Archive for Clinical and Experimental Ophthalmology, vol. 260, pp. 849–856, September 2021.

[9] A. Bilal, G. Sun, Y. Li, S. Mazhar, and A. Q. Khan, "Diabetic retinopathy detection and classification using mixed models for a disease grading database," IEEE Access, vol. 9, pp. 23544–23553, February 2021.

[10] A. Haider, M. Arsalan, C. Park, H. Sultan, and K. R. Park, "Exploring deep feature-blending capabilities to assist glaucoma screening," Appl. Soft Comput, vol. 133, p. 109918, January 2023.

[11] A. M. Alajlan, and A. Razaque, "ESOA-HGRU: Egret swarm optimization algorithm-based hybrid gated recurrent unit for classification of diabetic retinopathy," Artif. Intell. Rev, vol. 56, pp. 1617–1646, September 2023.

[12] Z. Gu, Y. Li, Z. Wang, J. Kan, J. Shu, and Q. Wang, "Classification of diabetic retinopathy severity in fundus images using the vision transformer and residual attention," Comput. Intell. Neurosci, vol. 2023, p. 1305583, January 2023.

[13] A. Khaparde, S. Chapadgaonkar, M. Kowdiki, and V. Deshmukh, "An attention-based Swin U-Net-Based segmentation and hybrid deep learning-based diabetic retinopathy classification framework using fundus images," Sens. Imaging, vol. 24, p. 20, June 2023.

[14] N. M. Thomas, and S. A. Jerome, "Diabetic retinopathy detection using EADBSC and improved dilated ensemble CNN-based classification," Multimedia Tools Appl, vol. 83, pp. 33573–33595, September 2023.

[15] A. M. Dayana, and W. R. S. Emmanuel, "Deep learning enabled optimized feature selection and classification for grading diabetic retinopathy severity in the fundus image," Neural Comput. Appl, vol. 34, pp. 18663–18683, June 2022.

[16] M. Toğaçar, "Detection of retinopathy disease using morphological gradient and segmentation approaches in fundus images," Computer Methods and Programs in Biomedicine, vol. 214, p. 106579, February 2022.

[17] V. Rachapudi, K. S. Rao, T. S. M. Rao, P. Dileep, and T. L. D. Roy, "Diabetic retinopathy detection by optimized deep learning model," Multimedia Tools Appl, vol. 82, pp. 27949–27971, February 2023.

[18] M. S. B. Phridviraj, R. Bhukya, S. Madugula, A. Manjula, S. Vodithala, and M. S. Waseem, "A bi-directional Long Short-Term Memory-based Diabetic Retinopathy detection model using retinal fundus images," Healthcare Anal, vol. 3, p. 100174, November 2023.

[19] A. Abirami, and R. Kavitha, "A novel automated komodo Mlipir optimization-based attention BiLSTM for early detection of diabetic retinopathy," Signal, Image Video Process, vol. 17, pp. 1945–1953, January 2023.

[20] S. Krishnamoorthy, Y. Weifeng, J. Luo, and S. Kardy, "H1DBi-R Net: Hybrid 1D Bidirectional RNN for Efficient Diabetic Retinopathy Detection and Classification," Artif. Intell. Rev, vol. 56, pp. 2759–2787, October 2023.

[21] Z. Khan, F. G. Khan, A. Khan, Z. U. Rehman, S. Shah, S. Qummar, F. Ali, and S. Pack, "Diabetic retinopathy detection using VGG-NIN a deep learning architecture," IEEE Access, vol. 9, pp. 61408–61416, April 2021.

Authorized licensed use limited to: Shah and Anchor Kutchhi Engineering College. Downloaded on April 19,2026 at 09:03:40 UTC from IEEE Xplore. Restrictions apply.

[22] U. Bhimavarapu, and G. Battineni, "Deep learning for the detection and classification of diabetic retinopathy with an improved activation function," In Healthcare, MDPI , vol. 11, p. 97, December 2022.

[23] P. N. Chen, C. C. Lee, C. M. Liang, S. I. Pao, K. H. Huang, and K. F. Lin, "General deep learning model for detecting diabetic retinopathy," BMC Bioinf, vol. 22, p. 84, November 2021.

[24] F. Saeed, M. Hussain, and H. A. Aboalsamh, "Automatic diabetic retinopathy diagnosis using adaptive fine-tuned convolutional neural network," IEEE Access, vol. 9, pp. 41344–41359, March 2021.

[25] I. Qureshi, J. Ma, and Q. Abbas, "Diabetic retinopathy detection and stage classification in eye fundus images using active deep learning," Multimedia Tools Appl, vol. 80, pp. 11691–11721, January 2021.

Authorized licensed use limited to: Shah and Anchor Kutchhi Engineering College. Downloaded on April 19,2026 at 09:03:40 UTC from IEEE Xplore. Restrictions apply.