2023 3rd International Conference on Advance Computing and Innovative Technologies in Engineering (ICACITE) | 979-8-3503-9926-4/23/$31.00 ©2023 IEEE | DOI: 10.1109/ICACITE57410.2023.10182642

An Efficiency way to analyse Diabetic Retinopathy Detection and Classification using Deep Learning Techniques

K Sudhakar Reddy
Reaearch Scholar
Department of CSE
School of Engineering
Malla Reddy University
Hyderabad, Telangana, India
kasamsudha86@gmail.com

M. Narayanan
Professor
Department of CSE,
School of Engineering
Malla Reddy University
Hyderabad, Telangana, India
narayananmecse@gmail.com

***Abstract*—Lesions develop on the retina of the eyes as a result of the progressive eye condition known as diabetic retinopathy (DR), which is brought on by type-2 diabetes. In especially for the working-age population in sustainable nations, it is thought that Diabetes Retinopathy is the main cause of blindness in diabetes patients. The aim of the treatment appears to be to maintain the patient's degree of eyesight because the issue is chronic. Diabetic retinopathy must be accurately identified in order to fully protect the patient's vision. The major issue with DR detection is manual diagnosis, which is time-consuming, expensive, and labor-intensive. A retinal scan of the patient's eyes must also be evaluated by an ophthalmologist as part of the treatment. The latter also appears to be more challenging, particularly in the early phases of the ailment when sickness indications are less obvious in the photos. Early detection of diabetic retinopathy has become easier because of deep learning algorithms, and images of the retinal fundus (DR) may now be analysed using machine learning.There are various stages of diabetic retinopathy, and the early stages are symptomless. Ophthalmologists can spot some retinal issues, but they can't always determine their root causes or stages of development. Ophthalmologists advise retina specialists to treat disease as a result. Bayesian neural networks (BNNs) had been used to benchmark the binary categorization of diabetic retinopathy as referable or non-referable in the current system. We suggest developing a Convolution neural network (CNN) and data analysis method to categorise diabetic retinopathy based on clinical data, predicting whether the patient is diabetic or not and identifying its stage with estimation, employing measurements are needed to maximise the intended performance measure with different datasets and clinical lesion images.**

Keywords*—Bayesian neural networks, Convolution neural network, Recurrent Neural Network, Deep Learning, Non-proliferative, Proliferative, Diabetic, Diabetic Retinopathy, Mellitus.

I. Introduction

In the past ten years, For the purposes of biometric human identification and the acquisition of vital health data, the analysis of internal eye and retinal fundus images has become increasingly important. Glaucoma and diabetic retinopathy are just two of the ailments that the human visual system aids in the early diagnosis of. One of the most important and delicate organs in the human body is the eye. The retina, the optic disc, the macula, and the retina are all located inside the eye, which is facing the lens. During an eye exam, it can be noticed by peering through the pupil. The retina is light-sensitive. Ophthalmologists manually review retinal pictures. [1].

Blood arteries all over the body, but particularly those in the kidneys and eyes, are impacted by diabetes. when there is damage to the blood vessels in the eyes, the condition is known as Diabetic Retinopathy (DR).

One of the main causes of blindness worldwide and a significant public health concern is diabetic retinopathy. It is a micro vascular disorder that can affect people with diabetes. Vision will be hampered as diabetic retinopathy progresses, and blindness may result. A diabetic person is more prone to develop diabetic retinopathy if their condition is left untreated for a long time. The signs of retinal illness appear when it is advanced. Patients with diabetes may not initially be aware that they are sick. It is possible for diabetic patients to first be unaware of their disease. Early diagnosis of diabetic retinopathy is essential for avoiding complications in the future. Ophthalmologists use the fundus retinal pictures to diagnose retinopathy in their patients.

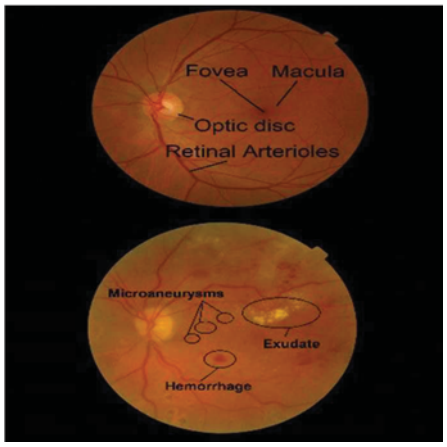

Fig. 1. Demonstrates a normal retina (top) and diabetic retinopathy (bottom) in an illustration. [1].

Diabetes retinopathy, a disorder where high blood sugar levels harm and injure the tiny blood vessels of the retina, causes them to leak and break, is one of the most prevalent consequences of diabetes. As a result, insufficient oxygenation of the retina may result in aberrant vascular development and further harm.

If left untreated, diabetic retinopathy can cause serious visual loss or damage. The National Health Service of the United Kingdom claims that 4,200 more persons in the

Authorized licensed use limited to: Shah and Anchor Kutchhi Engineering College. Downloaded on April 14,2026 at 14:10:44 UTC from IEEE Xplore. Restrictions apply.

country are at risk of acquiring retinopathy-related visual loss. In England alone, 1,280 new cases of diabetic retinopathy-related blindness are reported each year.[4].

The current DR screening procedure takes a long time and is complicated by a shortage of ophthalmologists with the necessary training. Fluorescein angiography is performed, the pupil of the eye is dilated to expand it, a specific camera is used to take an image of the retina, and the doctor examines the patient. According to estimates, approximately 5 million people worldwide, or 5% of the global blindness rate, experienced diabetic retinopathy in 2002. Additionally, a major issue is the lack of qualified clinicians in rural areas where the prevalence of diabetic patients is very high. The five stages of diabetic retinopathy are No DR, Mild Non-Proliferative DR (NPDR), Moderate Non-Proliferative DR, Severe Non-Proliferative DR, and Proliferative DR[5].

II. Literature Survey

In the past and more recently, Along with our investigation, a few techniques designed to detect retinopathy have been examined. The first publication examined was entitled "Development and Validation of a Deep Learning Algorithm for Detecting Diabetic Retinopathy in Retinal Fundus Photographs." [2]. The automatic detection of diabetic retinopathy in retinal fundus images was accomplished in this study using a deep learning technique. To prevent bias, the data set was first rated by a sample of 54 ophthalmologists, who gave each image a score between 3 and 7. The specificity and sensitivity of the deep convolution neural network were respectable.

The retina's blood vessels exhibit minute swellings or bulges during this early stage of diabetic retinopathy. Micro aneurysms are the medical term for these expanded regions. The most prevalent and serious eye problem associated with diabetes is diabetic retinopathy, which damages the retina and may even result in blindness. Compared to untreated control eyes, PRP considerably reduced—by at least 50%—the chance of major vision loss. There was evidence of PDR with high risk in the eyes. More than five years have passed since the study's follow-up.

A. Examinations of Traditional Methods:

- Image Processing and Data Mining Techniques were proposed by Argade et al. for the automatic detection of diabetic retinopathy.– Mukherjee et al. recommended a different conventional strategy. They conducted their investigation using image processing, which comprises histogram equalisation for contrast enhancement and background levelling. The following steps are optical disc detection, blood vessel extraction, and exudate detection. [9].

B. Evaluation of Machine Learning Methods:

Using a combination of classification algorithms, including alternating decision trees, AdaBoost, Naive Bayes, Random Forest, and SVM, Bhatia et al. suggested a machine learning model for diagnosing diabetic retinopathy and achieved maximum accuracy of 90%, sensitivity of 94%, and F1-score of 90%. In order to detect diabetic retinopathy, Lab hade et al. used soft computing techniques [6]. They employed a variety of classifiers, including SVM, Random Forests, Gradient Boost, AdaBoost, and Gaussian Naive Bayes.

- Mohammadian et al.[1] proposed a comparison of nine well-known machine learning classifiers for the detection of diabetic retinopathy, and the best proposed methodology was reviewed in this article with its own benefits.

Evaluation of the approach

1) Details of the dataset

After analysing with the various research papers, we have taken the best mayuresh et.al paper for our proposed work and it is based The Kaggle1 dataset was used in their experimental design, which, to the best of our knowledge, is the largest dataset of fundus pictures for diabetic retinopathy organised by EyePacs. There are 53,576 unnamed photos among the 88,702 total photographs in the EyePACS collection, whereas 35126 are labelled. Because our objective required us to classify the different stages of diabetic retinopathy based on the supervised learning issue, we only used the annotated images from this dataset.

In the future, The full dataset can be used with a semi-supervised learning method. The dataset is split into two classes based on the type and severity of DR severity. The analysis used a dataset that represented the distribution of different DR classes.

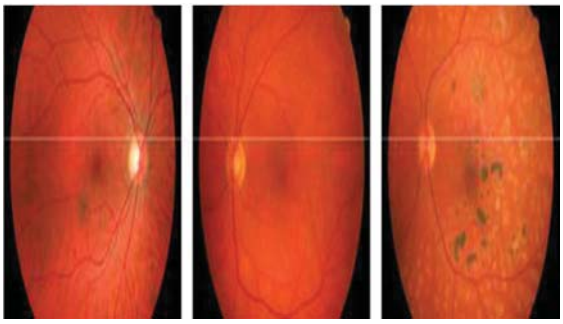

Fig. 2. Thresholding

To collect the data prior to providing it to the model. The images are first resized while keeping the 1349 x 1024 aspect ratio in mind. It helps keep images from losing features. The size of the images is then randomly decreased to 1024 by 1024pixels.

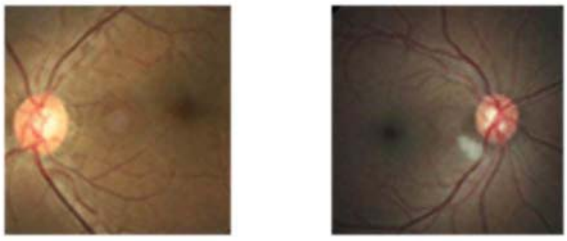

Fig. 3. MODEL VGG-NiN

In the proposed method, the VGG16 [11], SPP [12], and NiN [13] are well stacked. Figure 3 and Table 2 depict the block diagram and complex architecture of the suggested model, respectively. The VGG16 [11-16] will accept an RGB image with a size of 224x244 as input. A series of convolutional (conv) layers with layers of three three receptive layers is used to process the image after it has passed through a block of three fully linked layers. The conv layers may accommodate inputs of different sizes.

Authorized licensed use limited to: Shah and Anchor Kutchhi Engineering College. Downloaded on April 14,2026 at 14:10:44 UTC from IEEE Xplore. Restrictions apply.

III. CATEGORIES OF DIABETIC RETINOPATHY

Diabetes-related retinopathy (DR) causes damage to the retina's tissue. Some early warning signs include floaters, black spots in the field of vision, blurry vision, and trouble identifying colours. A patient with moderate symptoms may benefit from diabetes control. Advanced cases of DR could necessitate surgical intervention, such as laser therapy. Clinically, diabetic retinopathy is divided into five stages. [5]

A. There are no diabetic retinal diseases.

This is the eye's initial, healthy phase, as seen in the accompanying figure.No.4

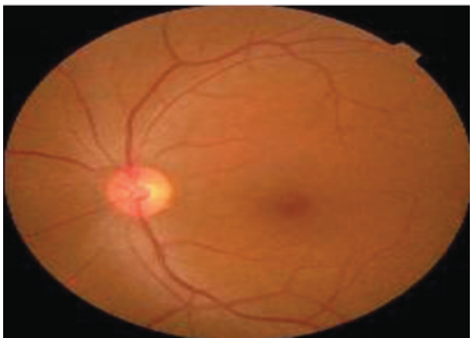

Fig. 4. No Diabetic Retinopathy

B. Mild diabetic retinal disease

This second phase of Micro aneurysms, which are small spherical swellings inside tiny blood vessels of the light-sensitive layer, are what give DR its characteristic appearance. And it is represented in the figure.5.

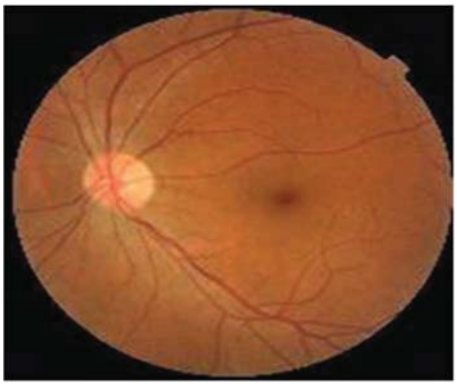

Fig. 5. Mild Diabetic Retinopathy

C. Modest Diabetic Retinopathy

This is the third phase of the DR, and as can be seen in the next Figure 6 The size and frequency of micro aneurysms have increased significantly, which prevents blood from reaching the retina.

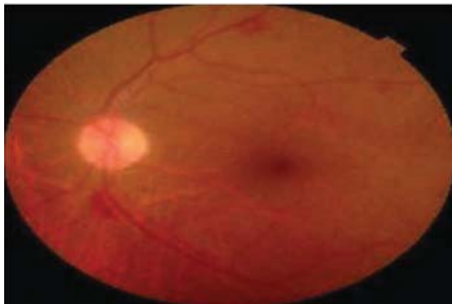

Fig. 6. Moderate Diabetic Retinopathy

D. Significant Diabetic Retinopathy

The fourth stage of the disease results in a significant rise in blood artery occlusion, which reduces blood flow to different parts of the retina. As seen in the next Fig., 7 Lack of nutrients and blood supply is compensated for by the growth of new blood vessels.

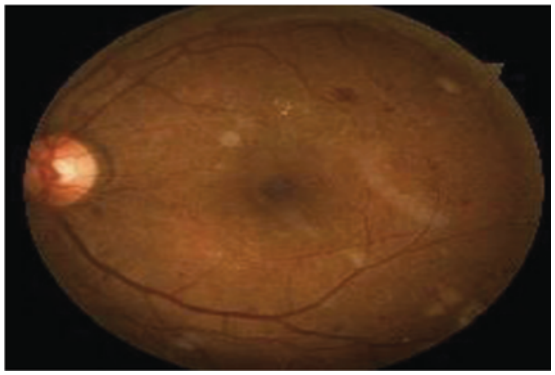

Fig. 7. Severe Diabetic Retinopathy

E. Retinopathy with Proliferative Diabetes

This is the fifth and most severe stage of DR, It shows that the retina's signal to the brain causes a noticeable rise in new blood vessels to form. These particular blood arteries are fragile, easily damaged, and prone to blood and fluid leakage into the retina. As can be shown in the following Fig.8 ongoing leakage may result in vision loss or even blindness. [7].

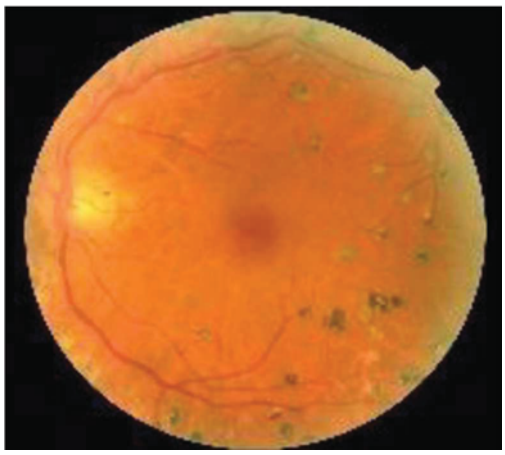

Fig. 8. Proliferative Diabetic Retinopathy

F. DR impacted Level stage by stage:

After careful consideration and a thorough examination using many references, the following suggestions have been made addressing the DR problem. Having high blood pressure or cholesterol increases a person's risk of developing diabetic retinopathy. Therefore, lowering your cholesterol and blood pressure will lessen your risk of losing your vision. Treatment does not provide a cure for diabetic retinopathy, although it can halt or stop the disease's progression. Given that diabetes is a chronic condition, more retinal ageing and visual loss are potentially conceivable. You should continue to undergo routine eye exams even after you have started therapy for diabetic retinopathy. You might eventually require additional medical care. Keeping blood glucose levels steady (DR) is now the best strategy to treat dry retina and diabetic macular edoema (DME). For situations that call for more complex

Authorized licensed use limited to: Shah and Anchor Kutchhi Engineering College. Downloaded on April 14,2026 at 14:10:44 UTC from IEEE Xplore. Restrictions apply.

treatment, laser therapy, anti-VEGF therapy, and other therapies can be required.

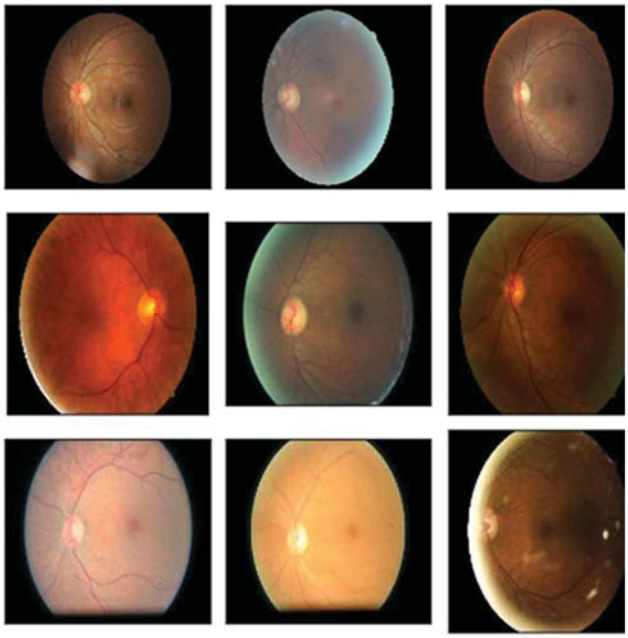

Fig. 9. Random images[4]

G. CNN's Architecture and Summary:

The guidelines for design technique are examined using a variety of journal references. We proposed the Deep-convolution Neural Network architecture that was employed. The input layer of the system can accept a 1000 x 1000 pixel greyscale image as input.

The next stage is a combination of three sets of convolution. A Max-Pooling Layer, a Convolution Layer, and a ReLU (Rectified Linear Unit) layer make up each set.



Fig. 10. Deep Convolution Network[9]

It is identified using the "4-2-1 rule." Any of the following symptoms, including diffuse intraregional haemorrhages, venous beading in two or more quadrants, or micro aneurysms in one or more quadrants, are used to diagnose the patient. Anti-VEGF medications are among those recommended for the treatment or prevention of diabetic retinopathy. Corticosteroids are an additional form of medication that has some advantages. Eye physicians can use lasers to cause the blood vessels in your retina to constrict and stop leaking as part of a laser treatment to lessen edoema. The only medication, according to Dr. Mark Former of Former Eye Centres in New York City, that has been approved for the early treatment of diabetic retinopathy in an effort to halt the emergence of major retinal problems is known as "Eylea." All cutting-edge laser treatments are accepted nowadays.

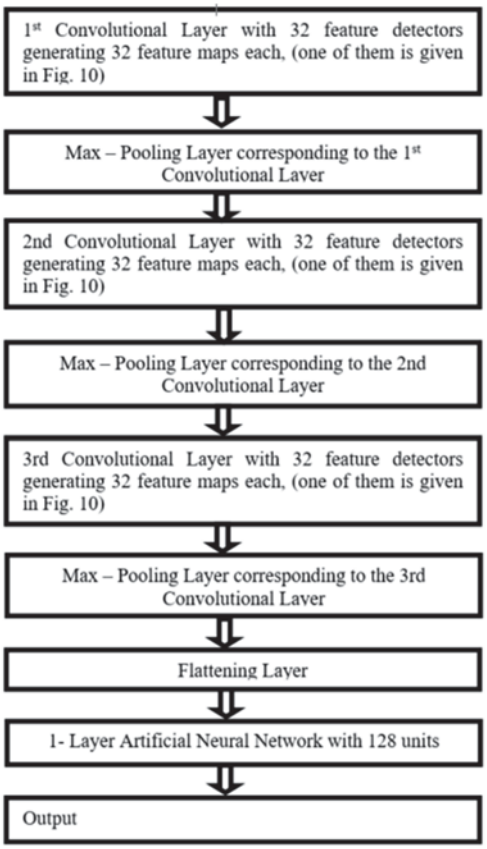

Fig. 11. Summary of CNN Layer[9]

H. An illustration comparing CNN and other techniques:

The figure 12 includes a few technologies that have been studied and investigated. This analysis shows that the kaggle-based dataset methodology provides acceptable accuracy in identifying retina abnormalities early on.

Additionally, fig.13 compares the rates of diabetes retinal diagnosis based on various age factors.

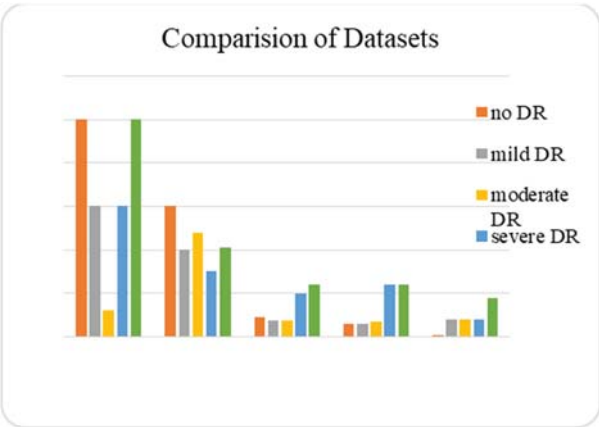

Fig. 12. Analysis of the results of several procedures.

Authorized licensed use limited to: Shah and Anchor Kutchhi Engineering College. Downloaded on April 14,2026 at 14:10:44 UTC from IEEE Xplore. Restrictions apply.

The table1 compares the speed at which databases load, accuracy detection, early-stage retina detection, success rate, failure rate, and performance measure.

This investigation shows that the Kaggle-based dataset methodology detects retina abnormalities early on with an acceptable degree of accuracy.

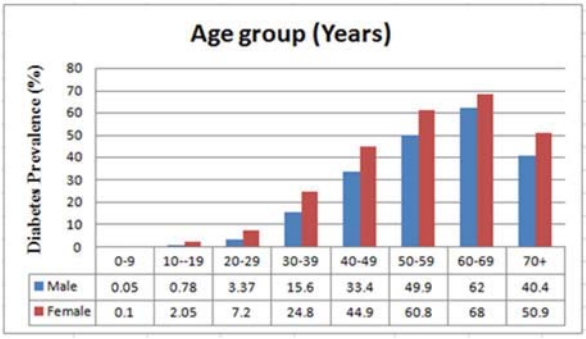

Fig. 13. Age-related diabetes prevalence comparison diagram.

TABLE I. DATABASE ACCURACY DETECTION METHODOLOGY

	Speed of dataset load in %	Accuracy	Early detection rate %	Rate of Success	Rate of Failure
Kaggle with CNN	99	99	99	99.9	0.1
SCT	96	98	93	95	5
VGG16	95	93	92	92	8
SPP	98	93	96	95	5
NIN	90	95	95	93	7

IV. CONCLUSION

After examining several research journal papers, the following suggestion might be taken into account in order to identify diabetic retinopathy illness in its early stages. The capacity of currently used manual testing is being strained by the rise of diabetic patients. The development of new algorithms based on deep CNN with data analysis methods is necessary for the diagnosis of diabetic retinopathy in the modern world. Patients can profit from early diabetes detection and reduce negative health effects like blindness by using such technologies. Using images of the retinal fundus, the diagnosis could be automatically made. Micro haemorrhages and aneurysms, commonly referred to as HEM, are the initial symptoms of diabetic retinopathy (DR), and all the problems will be resolved fast because of their likeness to typical human body components. It is now known that diabetic retinopathy is an inflammatory neuro-vascular consequence of the underlying systemic disease, occurring before to the current clinically diagnosed micro vascular damage. Additionally, it suggests that by using this technology, all diseases and inflammatory tissue can be quickly diagnosed and improved.

REFERENCES

[1] Mohamed Chetoui,Moulay A. Akhloufi, “Diabetic Retinopathy Detection Using Machine Learning and Texture Features”, 978-1-5386-2410-4/18©2018 IEEE.

[2] AmolPratapraoBhatkar, Dr. G.U.Kharat, “Detection of Diabetic Retinopathy in Retinal Images using MLP classifier”, 978-1-4673-9692-9/15 © 2015 IEEE, DOI 10.1109/iNIS.2015.30.

[3] MayureshShelar,SonaliGaitonde, AmudhaSenthilkumar (Assistant Prof.),MradulMundra,AnuragSarang, “Detection of Diabetic Retinopathy and its Classification from the Fundus Images”, 978-1-7281-5875-4/21©2021 IEEE.

[4] Yashal Shakti Kanungo,BhargavSrinivasan, Dr. SavitaChoudhary, “Detecting Diabetic Retinopathy using Deep Learning”, 978-1-5090-3704-9/17© 2017 IEEE.

[5] SumitThorat, AkshayChavan ,Pratik Sawant, Sharvika Kulkarni, NitinSisodiya, Prof. AnandKolapkar, “Diabetic Retinopathy Detection by means of Deep Learning”, 978-0-7381-1327-2/21©2021 IEEE.

[6] Zubair Khan ,FiazGul Khan, Ahmad Khan, Zia Ur Rehman , Sajid Shah , SehrishQummar , Farman Ali , Sangheon Pack (Senior member IEEE) , “Diabetic Retinopathy Detection Using VGG-NIN a Deep Learning Architecture”, Vol.9 , 2021.

[7] SatwikRamchandre, BhargavPatil, ShardulPharande, Karan Javali, HimangiPande, “A Deep Learning Approach for Diabetic Retinopathy detection using Transfer Learning”, 978-1-7281-9744-9/20©2020 IEEE.

[8] Anuj Jain,ArnavJalui,JahanviJasani ,YashLahoti, Prof. RuhinaKarani , “Deep Learning for Detection and SeveritybClassification of Diabetic Retinopathy”.

[9] NavoneelChakrabarty, “Deep Learning Method for the detection of Diabetic Retinopathy”, 978-1-5386-5002-8/18©2018 IEEE.

[10] Saranya. P, Umamaheswari .K.M., Dr. M.Sivaram, ChiragJain,DeparbanBagchi, “Classification of Different Stages of retinopathy using Convolutional Neural Networks”, 978 -1- 7281 -9491 -2/21©2018 IEEE.

[11] U. Raghavendra, H. Fujita, S. Bhandary, A. Gudigar, J. H. Tan, and U. R. Acharya, “Deep convolution neural network for accurate diagnosis of glaucoma using digital fundus images,” in Information Sciences, vol. 441, May 2018, pp. 41–49.

[12] K. He, X. Zhang, S. Ren, and J. Sun, Deep Residual Learning for Image Recognition, IEEE Conference on Computer Vision and Pattern Recognition (CVPR), 2016.

[13] M. Manjramkar, ”Survey of Diabetic Retinopathy Screening Methods,” 2018 2nd International Conference on Trends in Electronics and Informatics (ICOEI), Tirunelveli, 2018, pp. 1-6.

[14] [14]Z. A. Omar, M. Hanafi, S. Mashohor, N. F. M. Mahfudz and M.Muna’im, ”Automatic diabetic retinopathy detection and classification system,” 2017 7th IEEE International Conference on System Engineering and Technology (ICSET), Shah Alam, 2017, pp. 162-166.

[15] L. Math and R. Fatima, ``Adaptive machine learning classi_cation for diabetic retinopathy," Multimedia Tools Appl., vol. 80, pp. 5173_5186, Oct. 2020.

[16] YuchenWu ,Ze Hu, “Recognition of Diabetic Retinopathy BasedonTransfer Learning” 2019 IEEE 4th International Conference on Cloud Computing and Big Data Analytics.

Authorized licensed use limited to: Shah and Anchor Kutchhi Engineering College. Downloaded on April 14,2026 at 14:10:44 UTC from IEEE Xplore. Restrictions apply.