2023 3rd International Conference on Intelligent Technologies (CONIT)
Karnataka, India. June 23-25, 2023

Classification of Diabetic Retinopathy Using Image Pre-processing Techniques

Kavya Duvvuri
Dept. of Computer Science & Engineering
Amrita School of Computing,
Amrita Vishwa Vidyapeetham
Bengaluru, India
krishnakavya.duvvuri@gmail.com

Harshitha Kanisettypalli
Dept. of Computer Science & Engineering
Amrita School of Computing,
Amrita Vishwa Vidyapeetham
Bengaluru, India
harshithakanisettypalli@gmail.com

Masabattula Teja Nikhil
Dept. of Computer Science & Engineering
Amrita School of Computing,
Amrita Vishwa Vidyapeetham
Bengaluru, India
masabattulatejanikhil@gmail.com

Suja Palaniswamy*
Dept. of Computer Science & Engineering
Amrita School of Computing,
Amrita Vishwa Vidyapeetham
Bengaluru, India
p_suja@blr.amrita.edu

2023 3rd International Conference on Intelligent Technologies (CONIT) | 979-8-3503-3860-7/23/$31.00 ©2023 IEEE | DOI: 10.1109/CONIT59222.2023.10205586

***Abstract* — Most diseases that affect humans cause an effect on the eyes which is observed first by a physician while treating a patient. Eye diseases are conditions that affect the functioning of the eye and lead to loss of vision. Globally, at least 2.2 billion people have near or distant vision impairment. Most of these eye diseases have long-term effects so, early detection of the eye disease is very important to avoid the consequences. Some eye diseases include cataracts, glaucoma, diabetic retinopathy, and retinal detachment, etc. Almost 10% of people are facing an eye disease called diabetic retinopathy (DR). In this paper, multiclassification of DR images has been done after performing a few preprocessing techniques like erosion, histogram equalization, and comparing the accuracy of the CNN model before and after the pre-processing. The classification model yielded an accuracy of 86.4% on retinal fundus images filtered from the Kaggle DR detection database. The obtained results show that the proposed preprocessing methods are best suitable for diagnosing diabetic retinopathy from retinal fundus images.**

Keywords— Diabetic Retinopathy, Feature Extraction, CNN, Deep Learning, Multi Classification

I. INTRODUCTION

Nearly 10% of people have had diabetic retinopathy in recent years. Diabetic retinopathy is a chronic eye illness that causes blood vessels to protrude from the retina and obstructs the flow of fluid out of the eye. It is important to visually identify the symptoms of diabetic retinopathy.

There are 4 different stages in diabetic retinopathy which are classified as mild, moderate, severe no proliferative, and proliferate DR. In the first stage of DR balloon-like swellings in some areas of blood vessels in the retina called as microaneurysms are seen. In the second stage, the blood vessels get damaged, resulting in blood leaking into the retina tissue. In the third stage of DR, more blood vessels get damaged and make a greater impact on the vision of the eye. The final stage is when the complete blood vessels are damaged. So, it is important to ensure the early detection of diabetic retinopathy.

Different morphological image processing techniques are available for understanding different regions of images and analyzing them, such as, erosion, dilation, and contrast enhancement. In this paper, morphological and erosion techniques have been used to pre-process diabetic retinopathy images in order to enhance the accuracy of the classification model. Morphological image processing is a technique that is used to change the shape of the object. Erosion is the morphological technique used to change the dimensions of the object.

In the first section of the paper, a brief introduction to diabetic retinopathy and the literature considered. A brief introduction to the convolutional neural network model considered is given in Section 2 and followed by feature extraction techniques in Section 3, while Section 4 discusses the details of methodology and results of the work done and then is followed by a conclusion in Section 5. In this paper different preprocessing techniques are applied to DR images and the preprocessing technique uses the CNN model described in Section 2.

II. LITERATURE SURVEY

K. Duvvuri et al, in [1], give a single-layered CNN model for the binary classification of grayscale retinal images into two different categories: DR positive and DR negative. An accuracy of 94% and validation of 92.32% were obtained by the model. The explainability of the model was checked using an Explainable Artificial Intelligence (X-AI) technique called Gradient-Weighted Class Activation Map (Grad-CAM).

S. M. Islam et al, in [2], analyze the importance of image enhancement in medical image analysis and various image enhancement techniques are given. The method developed for image enhancement has been tested on images of low contrast and a conclusion has been given while showing an improvement in the performance of the model when the images are enhanced.

Authorized licensed use limited to: Shah and Anchor Kutchhi Engineering College. Downloaded on April 19,2026 at 11:11:35 UTC from IEEE Xplore. Restrictions apply.

Artificial intelligence using deep learning trends and their applications in the healthcare industry has been presented by Sundararajan et al. in [3]. Deep learning is trending in the ophthalmic field to extract the fundus and optical coherence, which improves the performance in detecting conjunctivitis.

Krishna et al. identified that glaucoma can be detected from retinal fundus images [4] where glaucoma is a disease that causes blindness if not treated for a long duration. Cup-to-Disc Diameter ratio is the main factor considered to determine the presence of glaucoma. Glaucoma detection has been done using segmentation of optic disc and cup, followed by calculation of CDR ratio. The algorithm used is based on the threshold that is used in the detection, CDR values are given to the SVM model for the classification. The given approach has given better accuracies and less computational power when compared to other approaches.

S. M. Sundara et al. in [5], illustrate the evaluation of segmentation algorithms for white blood cells. In this paper, five segmentation methods have been considered: Morphological Operations, Saliency-Itti Koch model, Color Based Segmentation, Graph Based Segmentation, and Watershed Segmentation. In the concept of image segmentation, Color is the main factor to be considered. The blood cells present in microscopic images have been segmented using the above-mentioned segmentation techniques. Finally, it is found that Saliency-Itty Koch model-based segmentation gives the best accuracy comparatively and the analysis of the performance is based on dice similarity.

The authors of the paper [6], have worked on differentiating expert optometrists and non-experts using eye-gaze patterns that have been collected by the detection of the optic disc of fundus retinal images. The count of eye fixations has been used for identifying the differences. Tadepalli et al. in [7] experimented on the inter- and intra-observer variabilities in the measurement of aqueous flare with a custom-made ocular spot fluorometer. Their findings suggest that this tool could be a reliable method for monitoring the progression of ocular diseases associated with aqueous flare. However, the study's small sample size and the fact that it was conducted at a single center limit the generalizability of the results. Future studies with larger sample sizes and multiple centers are needed to confirm these findings.

Tadepalli et al. in [8] have provided information on the reliability of aqueous flare measurements using a custom-made ocular spot fluorometer in patients with uveitis. Their findings suggest that this tool is a reliable method for monitoring the progression of uveitis and evaluating treatment efficacy. However, the study's sample size was limited to a single center and the measurement interval was only 1 week, which may limit the generalizability of the findings. Further studies with larger sample sizes and longer follow-up periods are needed to confirm these results.

Kulkarni and Amudha in [9] proposed an innovative approach for optic disc detection using eye gaze information and image processing algorithms. Their findings suggest that the proposed system is accurate and efficient in detecting the optic disc and could be useful in various ophthalmological applications. However, the study's small dataset size limits the generalizability of the results, and further studies with larger datasets and diverse populations are needed to confirm these findings.

Only binary classification of DR images has been carried out so far [1], and in this work we have proposed a method for multiclass classification with certain pre-processing techniques for better accuracies.

III. Proposed Methodology

Convolutional Neural Network (CNN) is a deep learning technique, CNN model has been used to train the pre-processed DR images. Trained CNN model has one convolutional layer, one max pooling layer, one flatten layer, and three dense layers. The convolution layer has 32 filters with 3x3 kernel size and ReLU activation function is used. The max pooling layer is of 2x2 pool size and then a flatten layer to change into single dimension. Three dense layers with 128 neurons in the first layer, 32 neurons in the second layer, and 5 neuron in the last dense layer. ReLU action function is used in the first dense layer and softmax function in the last dense layer. Adam optimizer has been used in the CNN model architecture.

The proposed CNN model architecture has been shown in Fig. 1.

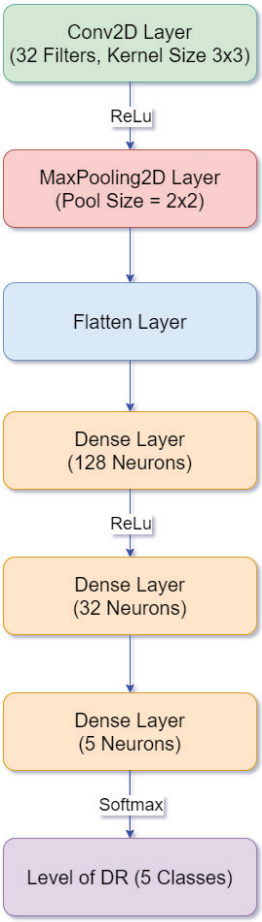

Fig. 1. Network Architecture Diagram

Feature extraction is extracting features from an image that helps in the identification of the original image from the given data. Feature extraction is the transformation of input data to numerical data which preserves the original data set. Feature extraction can also be termed as a dimensionality

Authorized licensed use limited to: Shah and Anchor Kutchhi Engineering College. Downloaded on April 19,2026 at 11:11:35 UTC from IEEE Xplore. Restrictions apply.

reduction technique as it is redefining the dataset into a set of feature vectors without redundant data [10].

A. Erosion

Erosion (⊖) is a morphological operation. Morphological transformation on an image is performed for multiple purposes like enhancing the contrast. Morphological operations are applied on binary images or grayscale images. Erosion is removing pixels on the boundaries of object. Erosion is used for shrinking the image pixels. It shrinks the image and results in thinning of extrusions. Eroding is performed with reference to the structuring element.

B. Histogram Equalization

Histogram is a graphical representation of pixels values for each intensity value of an image. Histogram equalization in image processing is used for contrast improvement. Histogram equalization is stretching the range of intensity values by spreading the frequent intensities.

C. Gradient weighted Class Activation Maps (Grad-CAM):

Grad-CAM stands for Gradient-weighted class activation mapping. It is basically an explainable AI framework which unravels the black box CNN model by highlighting the significance of the particular feature. Explainable AI may visually assist the user in understanding where the model is looking in a picture that is of the greatest significance for generating the prediction. The output of the grad Cam model is a heatmap for that class label. Grad Cam makes uses of gradient of the classification score with respect to the feature maps which are extracted by the CNN model in the last layer of the CNN network. Class Activation maps are generally the linear combination of the weights of the model and the feature maps and are computed for class label. The steps involved in computing the activation maps are as follows:

- Obtain the feature maps that are extracted by the CNN network.
- Obtain the weights that link the Flattening layer to the class of the SoftMax layer (in case of multi classification model).
- $Class\ Activation\ maps = Feature\ maps * Weights$

$$y^c = \sum_k w_k^c * \frac{1}{z} * \sum_i \sum_j A_{ij}^k$$

Where y^c is the output of activation maps for the class C.

w^c is the weights of the kth feature map.

z is the total number of pixels in the feature map.

A_{ij} is the pixel value of the feature map at position (i,j)

The weights of the Grad-Cam is as shown in Eq. 2

$$w_k^c = \frac{1}{z} * \sum_i \sum_j \frac{dy^c}{dA_{ij}^k}$$

Counter Factual Explanations:

$$w_k^c = \frac{1}{z} * \sum_i \sum_j -\frac{dy^c}{dA_{ij}^k}$$

IV. Results and Discussion

In this paper, we considered Diabetic Retinopathy dataset from Kaggle [11]. The dataset consists of 3662 diabetic retinal images. We have taken a dataset of 2594 training images and 1068 testing images with 70-30% train-test split where 296 images with mild DR, 799 images with moderate DR, 235 images with proliferate DR, 154 images with severe DR and 1442 images with no DR for training, and 74 images with mild DR, 200 images with moderate DR, 60 images with proliferate DR, 39 images with severe DR and 363 images with no DR for testing. All the retinal images in the dataset are in grayscale.

In image processing, the first step in the process is to identify the prominent features in the image which helps in removing the unwanted features from the image to make the model learn things faster and in an efficient manner.

Pre-processing steps of images considered in this paper include performing morphological operations, enhancement by histogram equalization, and single channel extraction. Then these images are trained with CNN model. The accuracy obtained using the pre-processed image dataset is compared with the accuracy obtained in [1]. The original image considered before all the operations is given in Fig. 2.

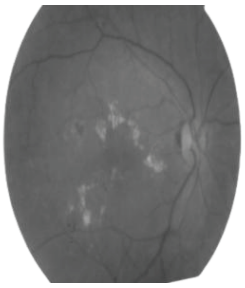

Fig. 2. Original Image

This technique helped in removing the lighter part of the image i.e., elimination of the pupil. It is observed that DR is not affecting the edges of the retina i.e., edges of the retina have no prominence in detecting the diabetic retinopathy. Erosion technique helps in eroding the edges of eye which removes the non-prominent features for detection of diabetic retinopathy. The image that is generated after performing the erosion is again removed from the original image to obtain an image with only key features which is as shown in Fig. 3. The output image is defined as shown in eq. 1.

$$Output\ Image = Input\ Image - Eroded\ Image \quad (1)$$

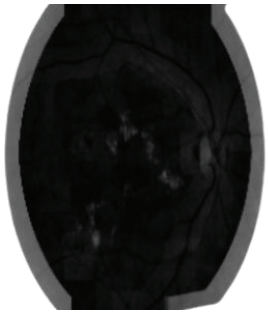

Fig. 3. Output Image

Authorized licensed use limited to: Shah and Anchor Kutchhi Engineering College. Downloaded on April 19,2026 at 11:11:35 UTC from IEEE Xplore. Restrictions apply.

The output that is generated after the erosion process is enhanced using histogram processing in order to increase the visibility of bulged blood vessels and blood leakage into the retinal tissues. The image enhancement is done using adaptive histogram processing where we divide the image into smaller blocks and perform the histogram equalization. The enhanced image is shown in Fig. 4.

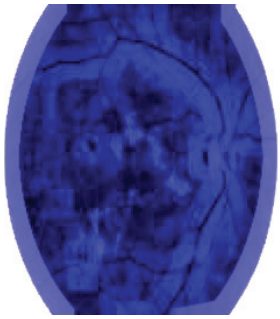

Fig. 4. Enhanced image after histogram equalization

The image after enhancement has three channels: red, green, and blue. But as the image originally considered was grayscale, all the three channels contain the same numeric values. Thus, any one of the three channels can be extracted for the further processing. The image after extracting green channel in the RGB image is given in Fig. 5.

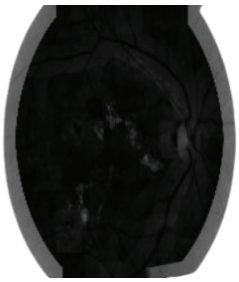

Fig. 5. Image after extraction of green channel

The flowchart given in Fig. 6 represents the pre-processing of the target diabetic retinopathy images.

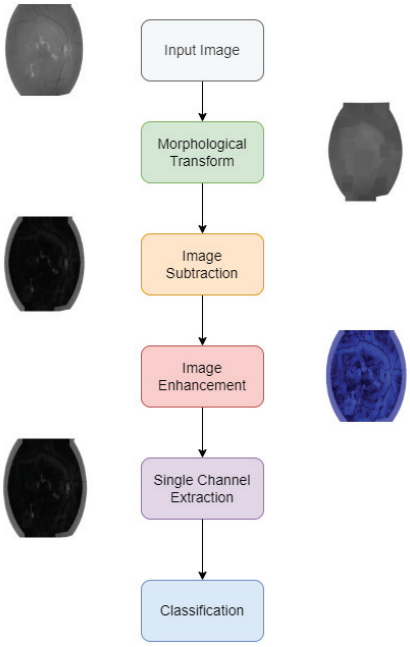

Fig. 6. Flowchart for the Pre-Processing of Images

Once the pre-processing is done, the resultant images are given to the single-layer CNN model for the classification of the image into either a DR effected image or a normal image. The process flow is shown in Fig. 7.

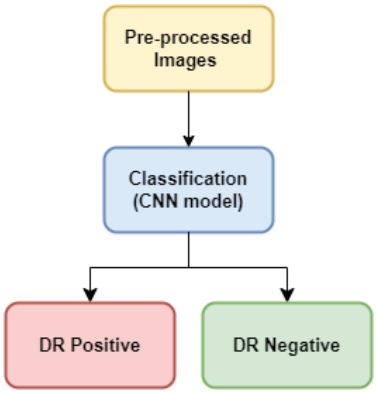

Fig. 7. Flow chart for the classification

The training and testing accuracy values obtained after training the proposed CNN model and other pre-trained models like, Alex Net, VGG16 and ResNet50 are tabulated in Table 1.

TABLE I. ACCURACY OF MODELS

Model	Before Pre-processing		After Pre-processing	
	Training Accuracy	Validation Accuracy	Training Accuracy	Validation Accuracy
Proposed CNN	80.00	71.10	86.00	73.33
Alex Net	72.00	28.67	77.00	37.17
VGG-16	44.00	49.32	62.00	49.32
ResNet-50	32.00	49.32	46.00	49.12

From Table 1 it is evident that the accuracy of all the CNN model increased while training with images after pre-processing, when compared with original accuracy achieved while training images before pre-processing. When trained by pre-processed DR images there is an increase in accuracy. The explainability of the model can also be testing by using the explainable AI technique, Grad-CAM. Fig. 8 shows the pre-processed image of a retina containing DR and fig. 9 shows the application of Grad-CAM on the pre-processed DR image.

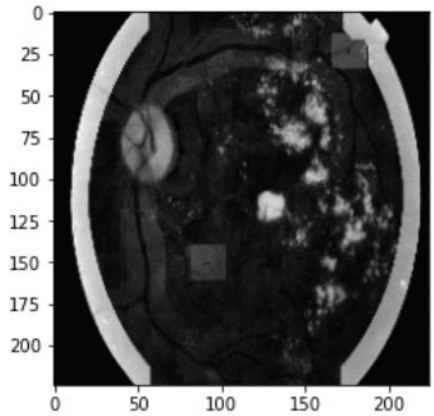

Fig. 8. Pre-processed Image with DR

Authorized licensed use limited to: Shah and Anchor Kutchhi Engineering College. Downloaded on April 19,2026 at 11:11:35 UTC from IEEE Xplore. Restrictions apply.

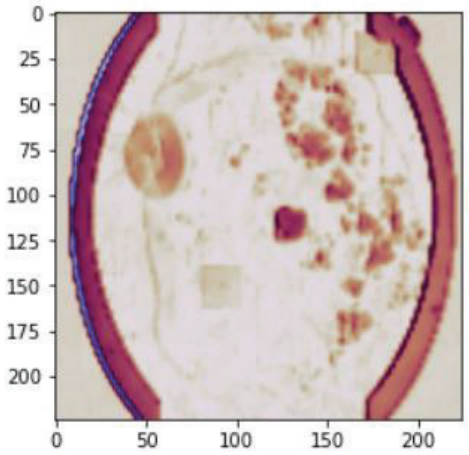

Fig. 9. Grad-CAM on Pre-processed Image with DR

Fig. 10 shows a pre-processed retinal image that contains no DR and fig. 11 shows the application of Grad-CAM on the image containing no DR.

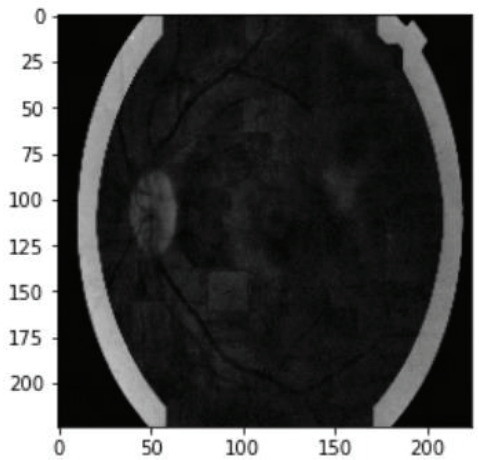

Fig. 10. Pre-processed Image with No DR

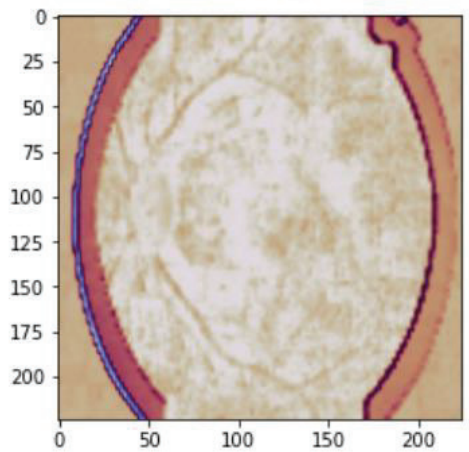

Fig. 11. Grad-CAM on Pre-processed Image with No DR

In Fig. 11 the white cloudy regions which are specific to DR have been highlighted, while in Fig. 13 the entire retina is empty indicating no DR containing region present, hence, proving that the model has learnt the most significant features from the pre-processed training images.

V. Conclusion

In this work, we have proposed a few pre-processing techniques to our earlier work and found that the proposed pre-processing techniques have improved the accuracy. The accuracy of the model for the pre-processed images is 96.4% and the validation accuracy is 93.26%. The accuracy and validation accuracy are higher than those obtained without pre-processing the image with the CNN model, in our earlier work. The XAI technique of Grad-CAM has been applied to the pre-processed images to understand the basis of classification. The relevant area of the fundus which contributes to DR has been identified and highlighted correctly, which implies that the model has been able to capture correct features to make the classification. This shows that the pre-processing techniques, erosion, and contrast enhancement, work well for helping to gain better accuracy for DR images. Pre-processing techniques differ from application to application as the significant regions in an image are different. It can be concluded that the pre-processing technique shown in this paper is best suited for the application of DR classification. As a future implementation, other pre-processing techniques may be studied and applied on DR images to improve the classification accuracy. The work can still be improved by extracting more features from the retina.

VI. Future Implementation

The proposed methodology has been interpreted using an explainable AI framework called Grad-CAM which can visually show the user where the retina was damaged. A GUI can be created which can take the retina image as an input and shows the effected regions of the retina in the display.

References

[1] K. Duvvuri, S. Chethana, S. S. Charan, V. Srihitha, T. K. Ramesh, and S. K S, “Grad-CAM for Visualizing Diabetic Retinopathy,” in *2022 3rd International Conference for Emerging Technology (INCET)*, 2022, pp. 1–4. doi: 10.1109/INCET54531.2022.9824598.

[2] S. M. Islam and H. S. Mondal, “Image Enhancement Based Medical Image Analysis,” in *2019 10th International Conference on Computing, Communication and Networking Technologies (ICCCNT)*, 2019, pp. 1–5. doi: 10.1109/ICCCNT45670.2019.8944910.

[3] S. K. Sundararajan and S. P. D., “Detection of Conjunctivitis with Deep Learning Algorithm in Medical Image Processing,” in *2019 Third International conference on I-SMAC (IoT in Social, Mobile, Analytics and Cloud) (I-SMAC)*, 2019, pp. 714–717. doi: 10.1109/I-SMAC47947.2019.9032705.

[4] R. Krishnan, V. Sekhar, J. Sidharth, S. Gautham, and G. Gopakumar, “Glaucoma Detection from Retinal Fundus Images,” in *2020 International Conference on Communication and Signal Processing (ICCSP)*, 2020, pp. 628–631. doi: 10.1109/ICCSP48568.2020.9182388.

[5] S. M. Sundara and R. Aarthi, “Segmentation and Evaluation of White Blood Cells using Segmentation Algorithms,” in *2019 3rd International Conference on Trends in Electronics and Informatics (ICOEI)*, 2019, pp. 1143–1146. doi: 10.1109/ICOEI.2019.8862724.

[6] N. Kulkarni and Amudha J., “Comparison of experts and non-experts gaze pattern for the target as optic disc in the fundus retinal images”, International Journal of Applied Engineering Research, vol. 12, no. 14, pp. 4106–4112, 2017.

[7] Tadepalli, Sirisha, Hadiya Farhath Pattan, Bongoni Vishwanath, Prema Padmanabhan, Rachapalle Reddi Sudhir, Surekha Paneerselvam, Abhilash Ravi Kumar, Jyotirmay Biswas, and Sangly P. Srinivas. "Inter and intra-observer variabilities in the measurement of aqueous flare with a custom-made ocular spot fluorometer." Investigative Ophthalmology & Visual Science 62, no. 8 (2021): 1426-1426.

[8] Tadepalli, Sirisha, Hadiya P. Farhath, Rachapalle R. Sudhir, Prema Padmanabhan, Jyothirmay Biswas, Sangavi Saravana, Mehal Rathore,

Authorized licensed use limited to: Shah and Anchor Kutchhi Engineering College. Downloaded on April 19,2026 at 11:11:35 UTC from IEEE Xplore. Restrictions apply.

Surekha Paneerselvam, Abhilash Ravikumar, and Sangly P. Srinivas. "Reliability of Aqueous Flare Measurements During Uveitis by a Spot Fluorometer." Journal of Ocular Pharmacology and Therapeutics 38, no. 1 (2022): 66-73.

[9] N. Kulkarni and Amudha J., "Eye gaze– based optic disc detection system", Journal of Intelligent & Fuzzy Systems, vol. 34, no. 3, pp. 1713 - 1722, 2018.

[10] Sorzano, Carlos Oscar Sánchez, Javier Vargas, and A. Pascual Montano. "A survey of dimensionality reduction techniques." arXiv preprint arXiv:1403.2877 (2014).

[11] https://www.kaggle.com/sovitrath/diabetic-retinopathy-224x224-grayscale-images

Authorized licensed use limited to: Shah and Anchor Kutchhi Engineering College. Downloaded on April 19,2026 at 11:11:35 UTC from IEEE Xplore. Restrictions apply.