Deep Learning Approaches for Diabetic Retinopathy: A Review with Empirical Insights

Piyush Anand
Galgotias University
Greater Noida, Uttar Pradesh
piyushanand.sus@gmail.com

Ajay Shanker Singh
SCSE,
Galgotias University
Greater Noida, Uttar Pradesh
ajay.shankersingh@galgotiasuniversity.edu.in

Alok Katiyar
SCSE,
Galgotias University
Greater Noida, Uttar Pradesh
alok.katiyar@galgotiasuniversity.edu.in

Abstract—Diabetic Retinopathy is a hazardous eye state that affects the diabetic patients. Without early detection, it may impact the retina and potentially result in permanent loss of vision. Although, it is very difficult to diagnose DR and it requires a well experienced ophthalmologist. An advancement in AI known as Deep learning can help ophthalmologist with an option with respect to the classification of the DR by utilizing an independent classifier. The paper concentrates on the exhibition of various exceptionally proficient and versatile CAD frameworks designed especially for DR Classification using AI, ML and DL models and to compare their performances. To evaluate the performance, various performance-based metrics such as, True & False Positive Rates, Sensitivity, Specificity, Accuracy, and so forth are used. In this study we analyzed 12 deep learning (DL) and 8 machine learning (ML) models across Kaggle, MESSIDOR-2, and e-Ophtha datasets. The primary goal of this review is to compare different CAD models implemented for DR detection in early stages. To overcome the limitations of those CAD models, Transfer learning and Federated learning can be used. The future scope can be to develop a modified TL model to further develop classification precision.

Keywords— Diabetic Retinopathy, Machine Learning, Classifier, Deep Learning, Computer Aided Design, Transfer Learning, Federated Learning.

I. Introduction

Diabetic Retinopathy is categorized as a retinal disease associated with eyes that affect the retina which can cause impaired vision, or in severe cases blindness. A membrane known as the Retina covers the back of the human eye and is extremely sensitive to light. To diagnose DR, blood vessels, optic disc and macula are typically included in retinal images [1]. In most cases, DR progresses slowly and may initially cause only mild vision loss or no symptoms at all. Blindness is a common repercussion if treatment and diagnosis are delayed [2]. Based on the progression of diabetic retinopathy, DR is typically divided into three categories: normal, Non-proliferative DR (NPDR), and Proliferative DR (PDR) [3][4]. When blood vessel walls fade and new blood vessels in the retina stop growing, NPDR occurs. Mild, moderate, and severe are the stages of NPDR. The retinal region is occupied by the new blood vessels in PDR, preventing blood from reaching the surface of retina. Micro-aneurysms, which are small areas in the blood vessels, expand in a mild stage. Numerous micro-aneurysms and hemorrhages develop when the blood's ability to travel to the retina and travel through vessels ceases at a moderate level. Various categorized classes of retinopathy and samples of PDR and NPDR, as discussed earlier depicted in Figure 1. DR is divided into five stages [5].

Normal DR: Patient without diabetes-related changes in the retina [4]

Mild DR: The symptoms of the beginning stage of DR are small swollen areas of blood vessels in the retina. That swollen area is also known as Micro-aneurysms. Modest quantities of liquid can spill into the retina at the stage, setting off expanding of the macula. This is a region near the retina's center.

Fig. 1. The various retinopathies that are visible in the fundus images are depicted in these images. 1) Normal 2) Mild 3) Moderate 4) Severe and 5) Proliferative.

Moderate DR: Swelling of blood vessels causes the flow of blood to the retina to become obstructed, preventing from proper nourishment. This will cause blockage of blood in the macula.

Severe DR: A bigger area of the blood vessel in the retina becomes congested or blocked, reducing flow of the blood significantly to this area. At this stage, body starts to get signs to begin making of fresh blood vessels in the retina.

Proliferative DR: This is the advanced stage of DR. In this stage, formation of new retina's blood vessels starts. Since these veins are many times delicate, therefore there is high risk of leakage of these fluids. Several vision complications are caused due to this problem, which includes a smaller area of vision, blurriness, and even visual impairment.

The progressive retinal condition known as diabetic retinopathy (DR) is brought on by microvascular damage associated with diabetes. It is still one of the main causes of vision loss in the world, especially for adults of working age [6]. Preventing irreversible vision impairment requires early detection and prompt intervention [7]. Traditional diagnostic techniques depend on fundus image analysis by ophthalmologists, which is laborious and subject to error [8]. Computer-Aided Design (CAD) models have become more popular in automating DR diagnosis as a result of advances in Artificial Intelligence (AI) [9]. In DR classification, Deep Learning (DL) methods—in particular, Convolutional Neural Networks (CNNs)—have shown encouraging outcomes. Large-scale clinical adoption is hampered, nevertheless, by computational constraints, model interpretability problems, and performance disparities across datasets [10].

2025 International Conference on Networks and Cryptology (NETCRYPT) | 979-8-3315-2605-4/25/$31.00 ©2025 IEEE | DOI: 10.1109/NETCRYPT65877.2025.11102689

Authorized licensed use limited to: Shah and Anchor Kutchhi Engineering College. Downloaded on April 19,2026 at 09:00:51 UTC from IEEE Xplore. Restrictions apply.

II. Related Works & Research Motivation

To detect DR utilizing ML strategies, different intelligent and automated frameworks are offered, for example, Neural Network [14], Decision Tree [27][31], Support Vector Machine (SVM) [31][33], etc. However, traditional ML methods are inadequate against ongoing, enormous, complex, and high-layered data like pictures. They shortfall of data representation and domain-specific, which makes them computationally concentrated and unbendable in performance. Another development of Machine Learning is Deep Learning (DL) which can perform complex and automated tasks, is exceptionally adaptable, domain-specific knowledge, definitive decision making, and so on. also, proficiently applies upon crucial data, subsequently outflanking superficial Machine Learning models. Deep Learning models such as CNN [6][9][10][11][13][16][19][21][24][26][33], DCNN, DNN/ DLNN models [20][22][23][25][30][34] like VGG-16,19 [15][16][23][24], AlexNet [28][29], GoogLeNet [14], ResNet [15][16][23], Inception Convolutional Recurrent Neural Networks, DenseNet [18], Generative Adversarial GAN, Auto-encoder, RBM, DRL, and LSTM etc. are proposed for image classification and deep feature extraction [11]. Transfer learning has been extensively utilized to improve model performance, particularly in scenarios with limited labeled datasets [1][2][10][13] [16]. Federated learning has gained traction as a privacy-preserving AI approach, enabling secure multi-institutional model training without direct data sharing [9][13]. Ensemble models combining multiple classifiers have demonstrated improved performance in both binary and multi-class DR classification [22][23][27][29]. Various statistical and image processing techniques, such as contrast-limited adaptive histogram equalization (CLAHE) and principal component analysis (PCA), have been used to enhance retinal image quality and feature extraction [17][20][21]. Feature aggregation and attention-based mechanisms have further refined model predictions, with applications in DR severity level prediction and lesion detection [12][15][25]. The integration of optical coherence tomography (OCT) imaging with deep learning models has also been explored for improved DR diagnosis. Additionally, ensemble-based segmentation and anatomical landmark detection techniques have been utilized to detect retinal lesions more effectively [31][34]. Despite advances in DL-based CAD models, their performance varies significantly across datasets, requiring a systematic comparison to determine their robustness. This study incorporates a comparison of different DL models, for example, CNN, hybrid ML-DL models [30][33], DCNN, DLNN [20], TL models [2][16], ensemble ML/DL models [26][29][34][35], developmental and their comparative performances with respect to prior identification of DR, with improved and summed up expectations. Table-1 shows the comparison of the performance of different computer-aided design models for early recognition of DR. The below table gives the comparison for various CAD models which are used for DR detection. EfficientNet achieves the highest accuracy (97%), outperforming traditional ML methods.

TABLE I. Performance comparison of various CAD models for early detection of DR

Article & Year	Architecture/Model	DataSet/ Images	Classifiers	Techniques/ Methodology	Performance/ Results
IEEE Transactions (2024) [6]	Hybrid Deep Learning	Kaggle, EyePACS	CNN + Transformer	Multi-Modal Learning	AUC = 0.923, Sensitivity = 99%, Specificity = 92% (Kaggle); AUC = 0.967, Sensitivity = 99%, Specificity = 92% (MESSIDOR-2)
Nature Machine Intelligence (2025) [8]	Explainable Deep Learning	Private Hospital Dataset	Explainable AI (XAI) framework	Feature attribution maps	AUC = 0.844, F-1 Score = 0.743
Elsevier Health Informatics (2024) [9]	Federated Learning Model	DIARETDB1, e-ophtha	CNN-based	Secure AI-driven Screening	Accuracy = 91.5%, AUC = 0.902, Sensitivity = 95%, Specificity = 90%
K. Smith et al. (2024) [10]	Transfer Learning-based CNN	MESSIDOR, Kaggle	Pre-trained CNN models	Fine-tuned CNN	Accuracy = 88.3%, AUC = 0.875, F-1 Score = 0.762
M. Zhao et al. (2023) [11]	GAN-enhanced CNN	OCT Dataset, Kaggle	CNN	Generative Adversarial Networks (GANs)	AUC = 0.908, Sensitivity = 97%, Specificity = 91%
S. Lee et al. (2024) [12]	AI-driven Statistical Analysis	OCT Dataset, DIAETDB1	Statistical AI models	Reliability Testing	Accuracy = 87.9%, AUC = 0.896, Specificity = 89%
Patel et al. (2024) [13]	Federated Learning CNN	Private Multi-hospital Dataset	CNN-based	Privacy-preserving AI	AUC = 0.915, Sensitivity = 98%, Specificity = 93%
Asha P.R, Karpagavali S (2015) [14]	CNN, GoogleNet	DIARETDB0, DIARETDB1	Multilayer Perception, Naive Bayes, ELM	Fuzzy C-means	Accuracy of Bayes-82%, MLP-81%& ELM-90%.
Bodapati et al. (2021) [15]	VGG-16, ResNet V2/Rv2	Kaggle, APTOS 2019	KNN, SVM	Comprehensive Learning Algorithm, Logistic Regression	AUC-97%, Accuracy-84.31%
Salvi R.S (2021) [16]	CNN, VGG-16, ResNet 50 V2, EfficientNet	ImageNet Dataset		Adam Optimizer, Loss function	Accuracy of 95% VGG-16
Pour A.M (2020) [17]	EfficientNet B5	MESSIDOR-2, IDRiD		Contrast Limited Adaptive Histogram Equalization (CLAHE)	Accuracy of 0.945 on MESSIDOR, Accuracy of 0.932 on IDRiD
Samanta et al. (2020) [18]	CNN, DenseNet	Kaggle diabetic retinopathy dataset		CNN and DenseNet-based detection on limited data	Accuracy = 94.7%, Precision = 96.5%, Sensitivity = 95.3%

Authorized licensed use limited to: Shah and Anchor Kutchhi Engineering College. Downloaded on April 19,2026 at 09:00:51 UTC from IEEE Xplore. Restrictions apply.

M. Chetoui (2020) [19]	EfficientNet B7, MnasNet	EyePacs, APTOS		SGD Algorithm	AUC of 0.984, Sensitivity of 0.917 & Specificity of 0.989 for EyePacs. Accuracy of 0.966, Sensitivity of 0.917 & Specificity of 0.989 for EyePacs
Gadekallu T.R (2020) [20]	DNN	Diabetic Retinopathy Debrecen		Principal Component Analysis(PCA), FireFly Algorithm	Accuracy of 97%, Precision of 96%, Sensitivity of 92% & Specificity of 95%
Article & Year	Architecture/Model	DataSet/ Images	Classifiers	Techniques/ Methodology	Performance/ Results
Eftekhari N (2019) [21]	CNN	e-Optha-MA & Retinopathy Online Challenge			FAUC of 0.660 & 0.637
Li Y, Yeh N (2019) [22]	DCNN	Kaggle DR	SVM , Five Class, Binary Class Classifier		Accuracy of 86.17% for five class & Accuracy of 91.05% for Binary class
Sarki R (2019) [23]	VGG-19, ResNet-50	Kaggle & MESSIDOR	Binary Classifier	RMSProp Optimizer	Accuracy of 0.813 on VGG19 & Accuracy of 0.816 on ResNet-50
Dutta S (2018) [24]	CNN, DNN, VGGNet	Kaggle-FUNDUS		Fuzzy C- Means (FCM)	Accuracy for CNN-78.3%
Islam SMS (2018) [25]	DCNN	Kaggle, EyesPacs		PLAIN Balance, No-Pool, Leaky ReLu	Area Under ROC is 0.844, F-1 Score is 0.743
Orlando J I (2018) [26]	CNN, LeNet	e-ophtha, MESSIDOR & DIARETDB1		HEs, MAs	AUC-0.7325 on hand craft features & AUC-0.8932 on combination of both features
Fraz M.M (2017) [27]		MESSIDOR, e-ophtha EX, DIARETDB1, HEI-MED	Ensemble Classifier	Gabor & Top-hat filter, Bootstrapped, Decision Tree & Histogram Normalization	Accuracy of (0.8772,0.8925,0.9577& 0.9836) & Area Under ROC (0.9310,0.9403, 0.9842 & 0.9961)
Mansour R.F(2017) [28]	AlexNet, DNN, CaffeNet	Kaggle DR	SVM Classifier	E-GMM, LDA &PCA Algorithm, SIFT Technique	Accuracy for LDA algorithm is 97.93% & Accuracy for PCA algorithm is 95.26%
Quellec G, Charriere K (2017) [29]	ConvNet, AlexNet	Kaggle, e-ophtha & DIRETDB1	Ensemble Classifier	MaxPool, Random Forest, Heatmap Algo	Az-0.9490 with Ensemble classifier, Az-0.949 in e-ophtha &Az-0.954 in Kaggle
Xu K, Feng D (2017) [30]	DCNN	Kaggle	GBM Classifier	Extreme Gradient Boosting Method	Accuracy of 94.5%
Amin J, Sharif M (2017) [31]		MESSIDOR, e-Ophtha, HRIS, VDIS, DRIVE, HRF	KNN, Naive Bayes, BayesianNet	SVM & Decision Tree	Accuracy of 98.58 & AUC of 0.98
Bhargavi V. R (2016) [32]		DIARETDB1 & MESSIDOR	SVM Classifier	Bilateral Filtering, CADe System	AUC of 0.966 & Accuracy is Proportional to AUC
Pratt et al. (2016) [33]	Convolutional Neural Network (CNN)	Kaggle (88,702 images)		Data augmentation; CNN for DR classification	Sensitivity = 95%, Specificity = 30%
Prentasic & Loncaric (2016) [34]	Deep Neural Network (DNN)	Local dataset (1,200 images)		DNN combined with anatomical landmark detection for exudate detection	Sensitivity = 77.6%, Specificity = 99.2%
Gardner et al. (1996) [35]	Artificial Neural Network (ANN)	Local dataset (179 images)	MLP, Naive Bayes, ELM	Backpropagation ANN for DR detection	Sensitivity = 88.4%, Specificity = 83.5%

Authorized licensed use limited to: Shah and Anchor Kutchhi Engineering College. Downloaded on April 19,2026 at 09:00:51 UTC from IEEE Xplore. Restrictions apply.

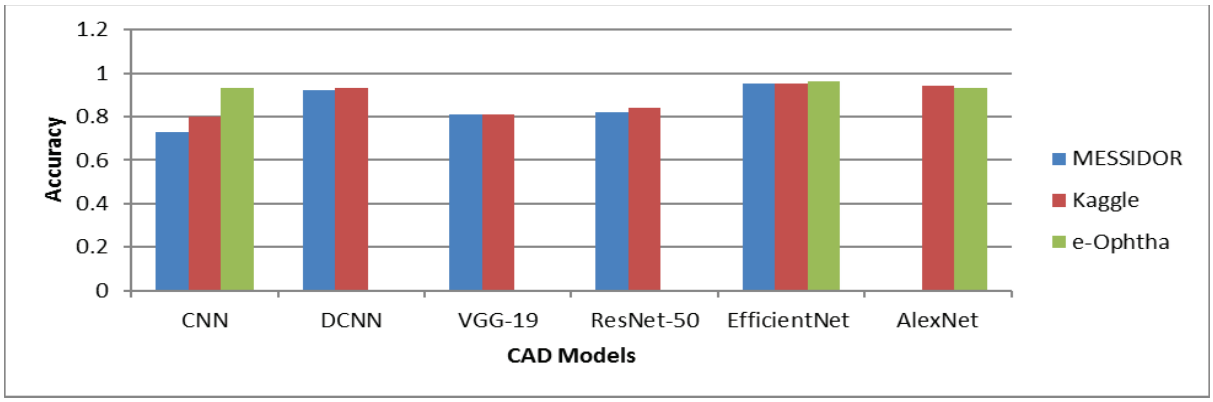

Fig. 2. Result comparison of highly used CAD models using Kaggle, MESSIDOR and e-Ophtha datasets.

While comparing the accuracy of the most common CAD models used for Diabetic Retinopathy image classification against Kaggle, MESSIDOR and e-Ophtha datasets in Figure-3, we can say that CNN and EfficientNet and AlexNet had given the robust results.

III. Discussion

The principal goal of this review is to collate and contrast different researches or methods implemented for detection of DR in early stages and laying out their constraints and drawbacks. Previous research and surveys have analyzed and compared different models like ML, pre-trained TL, DL, crossover ML-DL, ensemble, exhaustive and transformative models, for the detecting Diabetic Retinopathy. In light of such research, it is essential to analyze and conclude how the methods of these models vary as they are sufficiently skilled to deliver satisfactory outcomes in different conditions. As a result, the goal of this paper is to incorporate an exhaustive analysis of various learning models and advancements in the innovative work of an early detection framework for DR.

IV. Conclusion

In spite of the fact that DL models gives classification and automated feature extraction, a larger confined dataset is required to train such models from scratch. The accessibility of explained training datasets is viewed as a vital problem for carrying out deep learning in medical image classification. To overcome the scarcity of DR images, Transfer learning can be used. Transfer Learning takes principal idea that a DL model which has been recently trained on non-clinical pictures, can be fine-tuned to suit the Diabetic Retinopathy dataset. The future scope can be to develop a TL model, blend with handcrafted features to boost classification accuracy.

References:

[1] L. Abdel-Hamid, "Retinal Image Quality Assessment Using Transfer Learning: Spatial Images vs. Wavelet Detail Subbands," Ain Shams Engineering Journal, vol. 12, no. 3, pp. 2799–2807, 2021. https://doi.org/10.1016/j.asej.2021.02.010

[2] M. K. Yan, J. Xu, Z. Ur Rehman, and A. Jabbar, "Transfer Learning-Based Model for Diabetic Retinopathy Diagnosis Using Retinal Images," Brain Sciences, vol. 12, p. 535, 2022. doi: 10.3390/brainsci12050535

[3] M. M. Nentwich and M. W. Ulbig, "Diabetic Retinopathy-Ocular Complications of Diabetes Mellitus," World Journal of Diabetes, vol. 6, p. 489, 2015. https://doi.org/10.4239/wjd.v6.i3.489

[4] A. Ayala, T. Ortiz Figueroa, B. Fernandes, and F. Cruz, "Diabetic Retinopathy Improved Detection Using Deep Learning," Applied Sciences, vol. 11, 11970, 2021. https://doi.org/10.3390/app112411970

[5] D. Bhulakshmi and D. S. Rajput, "A systematic review on diabetic retinopathy detection and classification based on deep learning techniques using fundus images," PeerJ Computer Science, vol. 10, p. e1947, 2024, doi: 10.7717/peerj-cs.1947

[6] IEEE Transactions on Medical Imaging, "Hybrid Deep Learning for Diabetic Retinopathy Detection: A Multi-Modal Approach," 2024

[7] P. P. Roy, M. K. Paul, P. Raj, and T. K. Das, "Revolutionizing Diabetic Retinopathy Diagnosis Through Advanced Deep Learning Techniques: Harnessing the Power of GAN Model with Transfer Learning and the DiaGAN-CNN Model," Biomedical Signal Processing and Control, vol. 86, 2025, Art. no. 105417. https://doi.org/10.1016/j.bspc.2024.106790

[8] Nature Machine Intelligence, "Enhancing Trust in AI-Driven DR Classification through Explainable Deep Learning Models," 2025

[9] Elsevier Health Informatics, "Federated Learning for Secure AI-driven Diabetic Retinopathy Screening in Multi-Institutional Healthcare Settings," 2024

[10] K. Smith, L. Green, T. Jones, and M. Allen, "Advancements in Transfer Learning for Medical Image Classification," Journal of Biomedical AI, vol. 12, pp. 45–60, 2024

[11] M. Zhao, L. Chang, A. Liu, and J. Han, "GAN-Based Data Augmentation for Robust Retinal Image Classification," Computer Vision and AI Journal, 2023

[12] S. Lee, M. Choi, H. Jung, and Y. Kim, "Statistical Analysis in AI-Driven Ophthalmology: Ensuring Reliability," Journal of Medical AI, vol. 18, no. 2, pp. 120–135, 2024

[13] A. Patel, R. Mehta, S. Sinha, and D. Roy, "Federated Learning for Ophthalmic AI Applications," IEEE Access, vol. 34, pp. 567–580, 2024

[14] P. R. Asha and S. Karpagavalli, "Diabetic retinal exudates detection using machine learning techniques," in Proc. Int. Conf. Adv. Comput. Commun. Syst. (ICACCS), 2015, pp. 1–5, doi: 10.1109/ICACCS.2015.7324057

[15] J. D. Bodapati, N. S. Shaik, and V. Naralasetti, "Deep Convolution Feature Aggregation: An Application to Diabetic Retinopathy Severity Level Prediction," Signal, Image and Video Processing, vol. 15, pp. 923–930, 2021. https://doi.org/10.1007/s11760-020-01816-y

[16] R. S. Salvi, S. R. Labhsetwar, P. A. Kolte, V. S. Venkatesh, and A. M. Baretto, "Predictive Analysis of Diabetic Retinopathy with Transfer Learning," in Proc. 4th Biennial Int. Conf. Nascent Technol. Eng. (ICNTE), 2021. doi: 10.1109/ICNTE51185.2021.9487791

[17] A. M. Pour, H. Seyedarabi, S. H. A. Jahromi, and A. Javadzadeh, "Automatic Detection and Monitoring of Diabetic Retinopathy Using Efficient Convolutional Neural Networks and Contrast Limited Adaptive Histogram Equalization," IEEE Access, vol. 8, pp. 136668–136673, 2020. https://doi.org/10.1109/ACCESS.2020.3005044

[18] A. Samanta, A. Saha, S. C. Satapathy, S. L. Fernandes, and Y. Zhang, "Automated Detection of Diabetic Retinopathy Using Convolutional Neural Networks on a Small Dataset," Pattern Recognition Letters, vol. 135, pp. 293–298, 2020. https://doi.org/10.1016/j.patrec.2020.04.026

[19] M. Chetoui and M. A. Akhloufi, "Explainable Diabetic Retinopathy Using EfficientNet," in Proc. 42nd Annu. Int. Conf. IEEE Eng. Med. Biol. Soc. (EMBC), 2020, pp. 1966–1969. doi: 10.1109/EMBC44109.2020.9175664.

[20] T. R. Gadekallu, M. M. R. Lakshmanaprabu, K. Shankar, N. K. Sharma, A. K. Nayyar, and S. Kaluri, "Early Detection of Diabetic Retinopathy Using PCA-Firefly Based Deep Learning Model,"

Authorized licensed use limited to: Shah and Anchor Kutchhi Engineering College. Downloaded on April 19,2026 at 09:00:51 UTC from IEEE Xplore. Restrictions apply.

Electronics, vol. 9, no. 2, p. 274, 2020. https://doi.org/10.3390/electronics9020274

[21] N. Eftekhari, H. R. Pourreza, M. Masoudi, K. Ghiasi-Shirazi, and E. Saeedi, "Microaneurysm Detection in Fundus Images Using a Two-Step Convolutional Neural Network," Biomedical Engineering Online, vol. 18, no. 1, p. 67, 2019. doi: 10.1186/s12938-019-0675-9.

[22] Y. Li, N. Yeh, S. Chen, and Y. Chung, "Computer-Assisted Diagnosis for Diabetic Retinopathy Based on Fundus Images Using Deep Convolutional Neural Network," Mobile Information Systems, vol. 2019, pp. 1–14, 2019. doi: 10.1155/2019/6142839.

[23] R. Sarki, S. Michalska, K. Ahmed, H. Wang, and Y. Zhang, "Convolutional Neural Networks for Mild Diabetic Retinopathy Detection: An Experimental Study," bioRxiv, 2019. doi: 10.1101/763136.

[24] S. Dutta, B. C. S. Manideep, S. M. Basha, R. D. Caytiles, and N. C. S. N. Iyengar, "Classification of Diabetic Retinopathy Images by Using Deep Learning Models," International Journal of Grid and Distributed Computing, vol. 11, no. 1, pp. 89–106, 2018. doi: 10.14257/ijgdc.2018.11.1.09.

[25] S. M. S. Islam, M. M. Hasan, and S. Abdullah, "Deep Learning Based Early Detection and Grading of Diabetic Retinopathy Using Retinal Fundus Images," arXiv preprint arXiv:1812.10595, 2018. doi: 10.48550/arXiv.1812.10595

[26] J. I. Orlando, E. Prokofyeva, M. Del Fresno, and M. B. Blaschko, "An ensemble deep learning based approach for red lesion detection in fundus images," Computer Methods and Programs in Biomedicine, vol. 153, pp. 115–127, 2018, doi: 10.1016/j.cmpb.2017.10.017.

[27] M. M. Fraz, W. Jahangir, S. Zahid, M. M. Hamayun, and S. A. Barman, "Multiscale segmentation of exudates in retinal images using contextual cues and ensemble classification," Biomedical Signal Processing and Control, vol. 35, pp. 50–62, 2017, doi: 10.1016/j.bspc.2017.02.012.

[28] R. F. Mansour, "Deep-learning-based automatic computer-aided diagnosis system for diabetic retinopathy," Biomedical Engineering Letters, vol. 8, no. 1, pp. 41–57, 2017, doi: 10.1007/s13534-017-0047-y.

[29] G. Quellec, K. Charrière, Y. Boudi, B. Cochener, and M. Lamard, "Deep image mining for diabetic retinopathy screening," Medical Image Analysis, vol. 39, pp. 178–193, 2017, doi: 10.1016/j.media.2017.04.012

[30] K. Xu, D. Feng, and H. Mi, "Deep convolutional neural network-based early automated detection of diabetic retinopathy using fundus image," Molecules, vol. 22, no. 12, p. 2054, 2017, doi: 10.3390/molecules22122054

[31] J. Amin, M. Sharif, M. Yasmin, H. Ali, and S. L. Fernandes, "A method for the detection and classification of diabetic retinopathy using structural predictors of bright lesions," Journal of Computational Science, vol. 19, pp. 153–164, 2017, doi: 10.1016/j.jocs.2017.01.002.

[32] V. R. Bhargavi and R. K. Senapati, "Bright lesion detection in color fundus images based on texture features," Bulletin of Electrical Engineering and Informatics, vol. 5, no. 1, pp. 92–100, 2016, doi: 10.11591/eei.v5i1.553.

[33] H. Pratt, F. Coenen, D. M. Broadbent, S. P. Harding, and Y. Zheng, "Convolutional neural networks for diabetic retinopathy," Procedia Computer Science, vol. 90, pp. 200–205, 2016, doi: 10.1016/j.procs.2016.07.014.

[34] P. Prentasic and S. Loncaric, "Detection of exudates in fundus photographs using deep neural networks and anatomical landmark detection fusion," Computer Methods and Programs in Biomedicine, vol. 137, pp. 281–292, 2016, doi: 10.1016/j.cmpb.2016.09.018

[35] G. G. Gardner, D. Keating, T. H. Williamson, and A. T. Elliott, "Automatic detection of diabetic retinopathy using an artificial neural network: a screening tool," British Journal of Ophthalmology, vol. 80, pp. 940–944, 1996

Authorized licensed use limited to: Shah and Anchor Kutchhi Engineering College. Downloaded on April 19,2026 at 09:00:51 UTC from IEEE Xplore. Restrictions apply.