Brain Tumor Detection Report

Report Generated: December 06, 2025 at 11:22 AM

Patient Information

Name:	ABC
Age:	40
Gender:	Male
Contact:	04544321123
Email:	hiuy@gmail.com

Prediction Results

Prediction Result:	Tumor Detected
Tumor Type:	Glioma
Confidence Score:	99.24%
Tumor Stage:	III

MRI Image Analysis

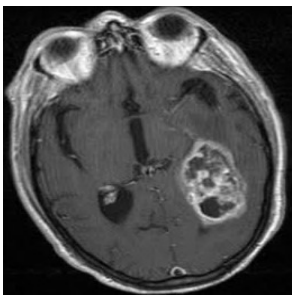

Original MRI

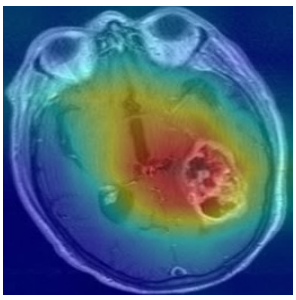

Grad-CAM

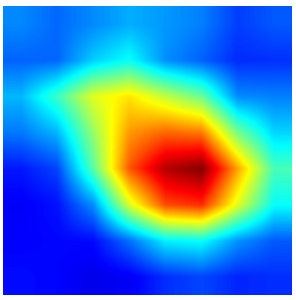

Heatmap

Tumor Growth Analysis

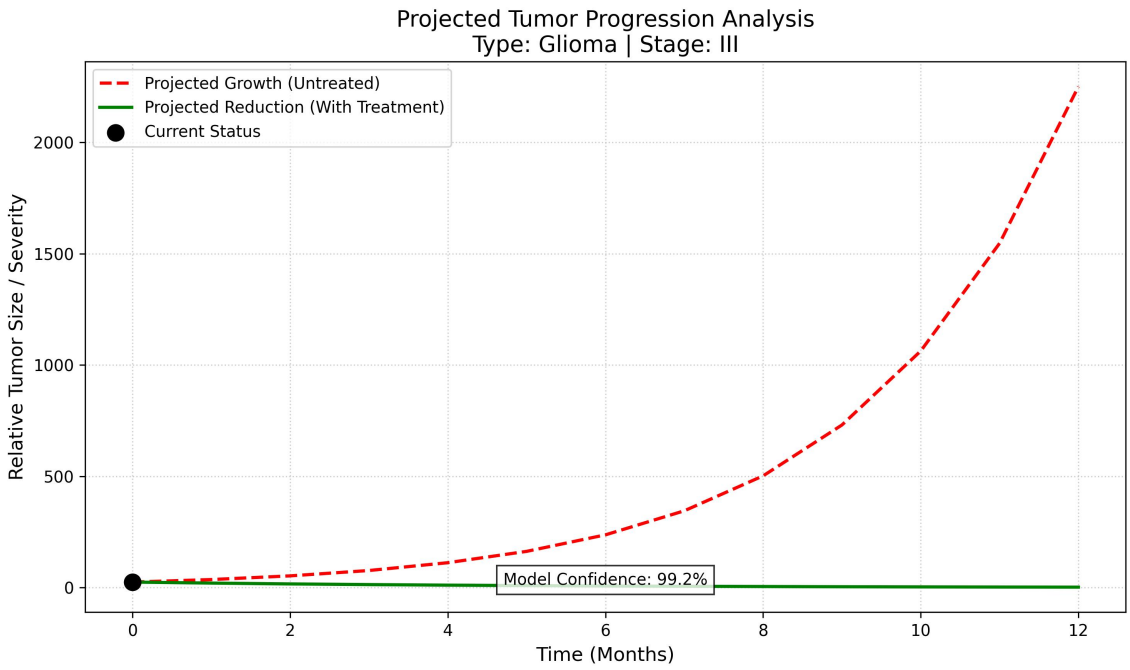

Figure: Projected tumor progression based on current stage and type.

Image Analysis Features:

Image Size:	257x307 pixels
Mean Intensity:	73.85
Edge Density:	13.45%
Contour Count:	186

Detailed Analysis

Description: A type of tumor that occurs in the brain and spinal cord, arising from glial cells.

Cell Structure Analysis: Gliomas show irregular, pleomorphic cells with hyperchromatic nuclei. They often infiltrate surrounding brain tissue and may show areas of necrosis.

Stage Description: Anaplastic glioma (Grade III)

Characteristics: Rapidly growing, anaplastic cells

Recommended Treatment: Surgery + radiation + chemotherapy

Prognosis: Poor - 30% 5-year survival

Common Symptoms: Seizures, Headaches, Personality changes, Memory problems, Difficulty speaking

Treatment Options: Surgical resection when possible, Chemotherapy, Radiation therapy, Targeted therapy, Clinical trials for advanced cases

Risk Assessment:

Severity:	High
Survival Rate:	Varies by grade (20-80%)

Doctor's Notes

Additional Notes:	

Doctor's Signature: _____

Date: _____

This report is generated by an AI-powered brain tumor detection system.

For clinical decisions, please consult with qualified medical professionals.

Report ID: 20251206112259