TRINAY CLINICAL GLAUCOMA REPORT

ID: f74e716a-faa9-446d-b9a6-4c4293b66155

AI-Assisted Optic Nerve, CDR & Retinal Vessel Screening

Date: 15 Oct 2026

PATIENT DEMOGRAPHICS

Patient Name:	**Aviraj abasaheb murkute**	Age / Gender:	**20 yrs / Male**	Phone:	**9762481967**
Patient ID:	**1**	Examined Eye:	**Right Eye**	Operator:	**Dr. Aviraj Murkute**

DIAGNOSTIC VERDICT: NORMAL / LOW RISK

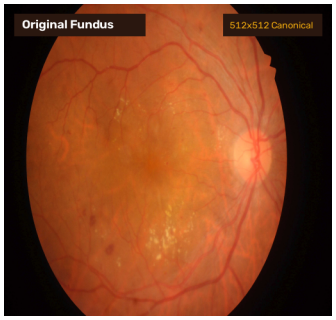
Glaucoma Prob: 10.1%

Optic nerve and CDR within expected physiologic bounds. Routine follow-up.

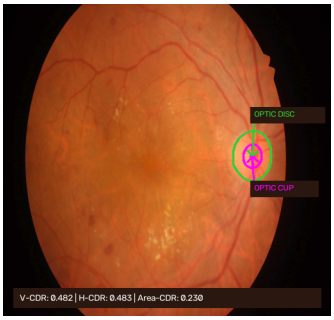
QUANTITATIVE MORPHOLOGICAL & CDR MEASUREMENTS

Vertical CDR:	**0.4819**	(Threshold: < 0.65)	Horizontal CDR:	**0.4833**	(Threshold: < 0.65)
Area CDR:	**0.2303**	(Ratio: Cup / Disc Area)	Cup Inside Ratio:	**1.0000**	(Anatomical concentricity)
Optic Disc Area:	**3956 px**	(Disc Detection: PASS)	Optic Cup Area:	**911 px**	(Cup Detection: PASS)

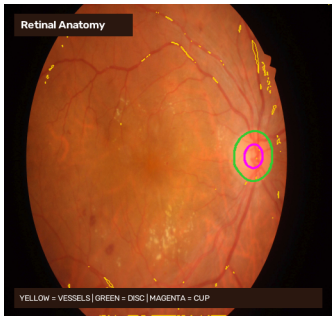
VISUAL EVIDENCE & OPTICAL LANDMARKS




1. Original Fundus



2. Optic Disc/Cup



3. Retinal Vessels



4. Grad-CAM / XAI

RECOMMENDED CLINICAL ACTION & REFERRAL TIMELINE

AI-assisted screening: Normal optic nerve head parameters within physiological baseline limits. Routine annual eye care follow-up recommended.

TRINAY CLINICAL GLAUCOMA REPORT — DOCTOR & PATIENT SUMMARY

Patient: Anita Devasena Murugan (F) | Examined Eye: Right Eye

DOCTOR'S CLINICAL TRIAGE SUMMARY (FOR ATTENDING CLINICIAN)

Quantitative structural assessment of the optic nerve head demonstrates a healthy, well-perfused neuroretinal rim. Vertical and horizontal cup-to-disc ratios (CDR) conform to normal physiological limits (< 0.65) and adhere to standard ISNT anatomical contours.

Clinical Findings: No focal notching, cup excavation, disc hemorrhage, or nerve fiber layer defect detected. Retinal vascular caliber and vascular density appear normal. Recommendation: Continue routine preventive annual ophthalmic surveillance.

PATIENT COUNSELING & EXPLANATION (SIMPLE & UNDERSTANDABLE)

What this means for you: The optic nerve at the back of your eye looks healthy, strong, and well-supported today. There are no signs of glaucoma damage or nerve thinning. Having your eyes checked once a year is the best way to keep your optic nerves healthy and ensure your vision stays clear.

CLINICAL PRECAUTIONS & ACTIONABLE GUIDELINES (FOR PATIENT & CAREGIVER)

- Schedule routine annual comprehensive dilated eye exams to maintain your healthy optic nerve baseline.
- Stay well-hydrated throughout the day and engage in regular cardiovascular exercise (walking, swimming).
- Protect eyes from blunt trauma with appropriate protective eyewear during sports or home maintenance.

CLINICAL SPECIALIST VERIFICATION & ATTESTATION

Reviewing Specialist: _____ Signature & Date: _____

Clinical Registration / License: _____ *(Licensed Ophthalmologist / Retina Specialist)*

REGULATORY & MEDICAL DISCLAIMER

TRINAY Glaucoma Screening is an AI-assisted decision support system for triage and early detection. This report does not constitute a definitive medical diagnosis. All findings must be clinically correlated by a licensed ophthalmologist.