A Manual of History Taking And Clinical Examination

3rd Edition

Dr. Ratindra Nath Mondal

Scanned with CamScanner

Table of contents

		Page no
Chapter 1:	**Communication skills for medical professionals**	
	Introduction	1
	Greetings and introduction	1
	History taking	1
	Clinical examination	3
	Report checking and prescription writing	3
	Counseling	3
	Follow up	4
	Prognosis	4
	Sharing bad news	4
Chapter 2:	**History taking and clinical examination**	
	History taking	6
	Components of history taking	6
	Particulars of the patient	6
	Importance of different points of particulars of the patient	7
	Chief complaints	8
	History of present illness	8
	Elaboration of some common symptoms	9
	Pattern of fever	9
	Cough	12
	Haemoptysis	13
	Haematemesis	13
	Breathlessness	14
	Elaboration of abdominal pain	14
	Elaboration of headache	15
	Vomiting	16
	Elaboration of jaundice	16
	Edema	17
	Elaboration of Hypertension	17
	Elaboration of diabetes mellitus	18
	History of past illness	18
	Drug/ treatment history	19
	Family history	19
	Personal history	19
	Socio-economic history	19
	Immunization history	20
	Menstrual history (in case of female)	20
	General physical examination	21
	Appearance	22
	Ptosis	22

Scanned with CamScanner

Table of contents	Page no

Body build 23
Nutritional status 24
Behaviour 26
Decubitus 26
Anaemia 26
Jaundice 28
Cyanosis 31
Clubbing 33
Koilonychia 35
Leuconychia 35
Edema 35
Dehydration 37
Pulse 37
Blood pressure 37
Temperature 37
Respiratory rate 38
JVP (Jugular venous pulse) 38
Thyroid gland 39
Lymph node 43
Bony tenderness 45
Gynaecomastia 45
Skin condition 46
Hair distribution 48
Tremor 48

Chapter 3: Respiratory system
Introduction 50
Presenting complaints of the respiratory system
Breathlessness 50
Cough 52
Haemoptysis 54
Chest pain 56
Clinical examination of the respiratory system 57
Examination of upper respiratory tract examination 57
Examination of the chest
Inspection 58
Palpation 62
Percussion 66
Auscultation 68
Putting it together 70
Pleural effusion 70

Scanned with CamScanner

Table of contents | Page no

Consolidation 71
Collapse 72
Fibrosis 72
Asthma 73
COPD 73

Chapter 4: Cardiovascular system

Introduction 74
Presenting complaints of CVS 75
Chest pain 76
Fatigue 78
Palpitation 78
Syncope 79
Presyncope 79
Dizziness 80
Peripheral edema 81
Clinical examination of cardiovascular system 81
Examination of arterial pulse 81
Measurement of blood pressure 88
Examination of JVP 90
Examination of precordium 90
Inspection 90
Palpation 92
Percussion 96
Auscultation 96
Percussion and auscultation of the lung base 102
Putting it together 103
Mitral stenosis 103
Mitral regurgitation 104
Aortic stenosis 105
Aortic regurgitation 105
Ventricular septal defect (VSD) 106
Atrial septal defect (ASD) 107

Chapter 5: Alimentary system

Introduction 108
Presenting complaints of alimentary system 108
Abdominal pain 109
Vomiting 111
Diarrhoea 113
Heart burn 114
Dyspepsia 115

Scanned with CamScanner

Haematemesis 116
Melaena 116
Lower gastrointestinal bleeding 116
Rectal bleeding 117
Flatulence 117
Constipation 117
Tenesmus 119
Abdominal distension 119
Dysphagia 120
Weight loss 121
Clinical examination of alimentary system 123
Examination of mouth and oral cavity 123
Examination of the Abdomen includes 126
Inspection 126
Palpation of the abdomen 130
Percussion of the abdomen 145
Auscultation of the abdomen 147

Chapter 6: Nervous system

Introduction 149
Presenting complaints of the nervous system 150
Headache 150
Facial pain 151
Dizziness, blackout, funny turns 151
Loss of consciousness/ Unconsciousness 151
Seizure / Convulsion 152
Delirium 153
Dementia 153
Paraesthesia 153
Numbness 153
Vertigo 153
Abnormal movements 154
Chorea 154
Nystigmus 154
Clinical examination of nervous system 155
Assessment of higher psychic function/ mental function 156
Examination of the cranial nerves 162
Examination of the motor system 184
Examination of the sensory system 197
Examination of signs of meningeal irritation 199

Scanned with CamScanner

Table of contents | Page no

Chapter 7: **Locomotor system**

Introduction 202

Common presenting complains of the locomotor/musculoskeletal system 202

Arthritis 202

Stiffness 204

Synovitis 204

Back pain 204

Neck pain 205

Oral ulcer 205

Alopecia 206

Raynaud's phenmenon 206

Scleroderma/Skin tightening 206

Muscle pain and weakness 207

Extra-articular manifestations 207

GALS screening 208

How to examine a joint? 214

Examination of individual joints 216

The spine 216

Thoracic spine 217

Lumbar spine 217

Additional/Special test for lumbar spine 218

The sacroiliac joints 220

The shoulder joint 220

The elbow joint 222

The wrist joint 224

Examination of hands 224

Examination of hip joint 228

Examination of knee joint 229

Examination of ankle joint and foot 231

Chapter 8: **Renal system**

Introduction 233

Common Presenting complaints of renal system disorders 233

Dysuria 233

Frequency 233

What is haematuria 233

Oliguria 234

Anuria 234

Polyuria 234

Nocturia 235

Unrinary incontinence 235

Acute glomerulonephritis (AGN) 236

Nephrotic syndrome (NS) 237

Scanned with CamScanner

The exchange of information between individuals, by means of speaking, writing or using a common system of signs or behaviour is communication.

Communication of doctors usually related with the patient, patient's attendant/guardians and medical stuffs (nurses, ward boy). Among them the patient is the main one.

What is 'doctor and patient cycle'?

This is the total path that the patient needs to complete during consultation. Components are

1. Patient enter the consultation room
2. Greetings between doctor and patient
3. History taking
4. Relevant clinical examination
5. Suggesting investigation
6. Report checking, diagnosis and prescription writing
7. Sharing the diagnosis with the patient/breaking the sad news and
8. Necessary counseling
9. Telling the prognosis
10. Fix a follow date

A doctor must be skilled in every step of 'doctor and patient cycle'.

Greetings and introduction

There should be warm greetings between doctor and patient. This builds confidence of the patient and he becomes easier to the doctor. This can be giving salaam or hi/hello or good evening or good noon etc, followed by I am Dr. Salam and you....

History taking

a) Patient part (patient says his/her complaints)

1. This is hearing the story from the patient.
2. If you don't hear properly you will miss the story.
3. Should not interrupt the patient.

b) Query part (physician ask to clarify symptom or to identify more problems, which patient fails to mention).

In query part following questions may be asked

1. Do you have any fever? Usually patient fail to mention low grade fever, so we should ask about it.
2. What about your appetite? Loss of appetite is called anorexia. Anorexia commonly occur due to infectious disease, drugs e.g. aspirin, iron, metronidazole etc. Fever due to any cause is usually associated with anorexia. If any patient complaint fever but his appetite is normal then probably it is not fever.

Scanned with CamScanner

3. Do you have cough? Cough may be due to common cold, pharyngitis, RTI, asthma, pulmonary tuberculosis, bronchial carcinoma etc. Commonly fever and cough indicate infection in respiratory tract.

4. Do you have chest pain? Common causes of chest pain in practice are IHD (ischaemic heart disease), pneumonic consolidation, GERD (Gastro esophageal reflux disease), musculoskeletaal chest pain. Among the IHD, chest pain of stable angina occurs only in exertion or exercise or walking, so this should be asked.

5. Do you have palpitation? Palpitaion is very common symptom experienced by everyone in daily life. If palpitaion occurs without any precipitant (e.g. anxiety, fear, bad news) or palpitaion during walking or exertion this may be due to underlying cardiac problem.

6. Do you have abdominal pain?

7. Do you have any burning sensation during micturition or foul smelling urine or cloudy urine, urgency, incomplete evacuation of bladder? UTI may be present with one or more symptoms mentioned above, besides urgency, incomplete evacuation of bladder is common in BPH (benign prostatic hyperplasia).

8. What is about your sleep? This is very important, sleeplessness may indicate severity of the problem e.g. if a patient come with LBP and he complaints sleeplessness then its likely that his LBP is severe. Besides sleeplessness is commonly due to anxiety neurosis, low level of physical activity, excess tea and coffee intake and thyrotoxicosis. Excessive sleepiness (or somnolence) is usually due to depression and hypothyroidism.

9. Are you taking any medicine of hypertension or DM or any other disease? Present medication history is important because without this drug dose titration is not possible. Besides if any patient is not taking the antihypertensive or antidiabetic drug regularly then he/she needs proper counseling regarding importance of regular drug intake.

10. Are you taking any tobacco products or alcohol? This history is required to assess overall risk factors of the patient. And if any patient uses tobacco or alcohol, he/she should be counseled to stop it.

Following points are important during history taking

1. Eye contact-it is better to look at the eyes of the patient while taking history.
2. Partnership-consider the patient as a partner rather than student or servant. This will help yielding more history.
3. Communication-way of communication with the patient will be the patient's own language. Doctors should use the simple words and ask simple question which is easily understandable for the patient. In case of difficulty an interpreter may be necessary.
4. Time-patient like the doctor who spend more time with the patient.

Scanned with CamScanner

Common things which patient do not like during history taking

1. Doctor is not listening the patient.
2. Doctor is busy with other thing like mobile or TV.
3. Doctor shows some non-verbal behavior.
4. Stop the patient in midway of telling the history.

Clinical examination

1. Should start after taking consent of the patient.
2. Prior counseling relaxes the patient completely.
3. Particular precautions for female patient.

Start with the general physical examination then proceed to systemic examination. The system which fitted with the patient's complaints that should be examined first then serially examine all the other system. As for example- if a patient present with the complaints of cough and chest pain, then his respiratory system should be examined first then other system.

Advice investigation

After completion of examination, relevant investigations should be advised if necessary.

Report checking and prescription writing

When the patient will come back with the investigation reports, those needs to thoroughly check up, co-relate with the history and clinical examination and finally diagnosis should be made. After that share the diagnosis with the patient (particular attention should be taken to disclose bad diagnosis; discuss at the end of this chapter). Along with the diagnosis, treatment option like medical vs surgical treatment, cost of the drugs should be discussed with the patient. Finally prescription should be written.

Counseling

Counseling is the assistance and guidance provided by a doctor in resolving patient's problem. This is very important in patient management. Patient should counsel about his/her disease (communicable or non-communicable; curable or non-curable etc), dietary advices, lifestyle advices that will be necessary to recover from the disease etc. As for example-a hypertensive patient should be counseled like this-"hypertension is a non-curable disease, for control of blood pressure apart from drugs, you should avoid excess salt intake, stop tobacco use, avoid fatty foods and you have to walk for minimum 30 minutes daily".

Scanned with CamScanner

Follow up

Follow up is the further observation of a patient to

1. Monitor earlier treatment (to see the outcome after taking the drugs)
2. Any adverse effect of the drug
3. See the disease progression
4. Detect new complication
5. Improve adherence to treatment (particularly in diabetic and hypertensive patients where drug needs to be taken for lifelong period).

Follow up is must for diabetic, hypertensive, stroke, IHD, CKD and cancer patient. If a hypertensive patient is taking the antihypertensive drug but he is not in schedule follow up then his blood pressure may not be controlled with the drug and he may develop complications.

Prognosis

Prognosis is the likely outcome of the disease. This is the main thing what patient wants to know from the doctor. Particular precaution should be taken in case of poor outcome diseases like cancer, stroke etc. Briefly tell the patient about the prognosis. As for example-in asthma patient, your prognosis is good. On the other hand in COPD patient, it is irreversible disease; you need to control it and its risk factors like smoking should be stopped, if you able to do that you will be fine.

Sharing bad news

Preparation

- Environment-ideally a quiet, comfortable, private room.
- Choosing the right person to give the news? It is better to give the news to the guardian of the patient, like parents of the patient, husband or wife of the patient, in case of old age patient either son or daughter should be choosen. But ideally patient should be asked about the right person to give the news.
- Introduce any members of the team like assistant registrar, indoor medical officer, students, nurse etc.
- Consider whether there may be cultural differences between doctor and patient or patient's guardian; if the patient cannot understand the doctor then a converter should be present.

Scanned with CamScanner

Sharing the news

- Explore what is known by the patient/family already. Example-patient's guardian already knows the diagnosis, then present condition of the patient should describe.
- Know as much about the case as you can start. Minimize interruptions and do not appear rushed.
- Give information with honesty but sensitivity. It is better to tell that your son is suffering from a bad disease (acute leukaemia) but he is in early stage rather that your son is suffering from blood cancer.
- Try to use simple language which the patint's guardian can understand. Example-try not to use medical term like bronchial carcinoma, metastasis etc, you can use-cancer of the chest and it spread from the chest etc.
- Do not take all the hope away-find some reason to be optimistic. Example-there are many treatment options with good outcome.
- Listen to what the guardian say and allow time for questions.
- Do not impose the truth but if the patient asks, do not lie.
- Avoid false reassurances. Example-after treatment he will be normal as before.
- Acknowledge that dealing with uncertainty is often harder than knowing the diagnosis.
- Give the patient's guardian sufficient information to be able to make any decisions with you.
- Try not to let your own opinions, if patient or guardian push you to make a decision for them. Example-you should tell the treatment options with advantages and disadvantages of each for the patient but not give the decision which one should be started, treatment options will be chosen by the patient's guardian.
- Recognize and acknowledge the feelings of the parents or patient may have, such as anger.
- Show empathy but do not lose control.
- Try not to overload with too much information.
- Don't stay too long. Closure can be difficult.
- Leaving a nurse with the parents for a period of time.

Scanned with CamScanner

History taking

History taking is an art; it is learnt by practice. Understanding of the patient's complaints is pivotal to the diagnosis of the disease and subsequently its management. An astute physician spends more time to take history, because a complete history lead the physician towards diagnosis in most of the cases. Moreover if the problems of the patient cannot be identified from history, it will be not possible to solve those. So, proper history taking is essential before physical examination, otherwise many findings may be missed. It is to be mentioned that history taking is a never ending process. Even after completing physical examination, one may have to retake the history because of an important finding about which the patient did not mention earlier.

Components of history taking

1. Particulars of the patient
2. Chief complaints
3. History of present illness
4. History of past illness
5. Treatment history/drug history
6. Family history
7. Personal history
8. Socioeconomic history
9. Immunization history
10. Menstrual history (in case of female)

Physical examination

1. General physical examination
2. Systemic examination
3. Salient feature
4. Provisional/clinical diagnosis
5. Differential diagnosis
6. Investigation
7. Final diagnosis
8. Management
9. Follow up
10. Prognosis

Particulars of the patient-those includes

1. Name
2. Age
3. Sex
4. Relegion:
5. Marital status:
6. Occupation:
7. Address:
8. Date and time of admission:
9. Date and time of examination:

Scanned with CamScanner

Importance of different points of particulars of the patient

Name: It is important because

1. Name is the patient's identification.
2. Can recognize the sex and religion of the patient.
3. Patient gets confidence if doctor calls him by name.

Age: Prevalence of some diseases is more common at specific age. Example: breathlessness in childhood usually due to asthma, bronchitis, pneumonia etc and breathlessness in old age is usually due to heart failure, COPD etc. Chest pain in young age is usually due to musculoskeletal chest pain, pneumonia etc, where as chest pain in old age is usually due to myocardial infarction, bronchial carcinoma with metastasis etc.

Sex: Incidence and prevalence of different diseases is different in male and female. Male to female ratio of SLE is 1:9 and male to female ratio of reactive arthritis is 15:1. Hemophillia is the disease of male (X-linked disease, female are the carrier but male are the sufferer).

Religion: Among Hindus who are strictly vegetarians may suffer from megaloblastic anaemia (due to deficiency of B12. Vitamin B12 predominately come from animal source, which present in liver, egg etc)

Marital status: Some problems of the married male and female differs from that of unmarried male and female. Newly married female may suffer from urethritis (honey moon urethritis). Pregnancy must be excluded by asking LMP (last menstrual period) before suggesting a X-ray in a married woman of reproductive age. Because X-ray is fetotoxic.

Address: Is important

1. To communicate with the patient.
2. To identify the endemic zone of different diseases e.g. goiter is endemic in north Bengal (Rangpur), malaria is endemic in Chittagong, kala-azar is endemic in Rajshahi, Mymenshingh.

Date and time of admission: This may indicates severity of the patient. Patient who admitted at midnight is usually critically ill.

Date and time of examination: Important for monitoring & follow up of the patient.

Presentation of particulars of the patient (Presentation usually should be in past tense but some present conditions of the patient can be present in present tense) Mr. Zamal Uddin 65 years, male, muslim, married came from Haragas, Rangpur admitted in Rangpur Medical College Hospital on 9th October at 2 PM and I have examined him on 10th October at 10 AM.

Scanned with CamScanner

Chief complaints

Definition: Among the presenting complaints, these are the chief complains that compelled the patient to seek medical attention. Chief complaints usually less than three (one to three) in number but not more than five.

How to write chief complaints: Chief complaints should be written in order of

1. Duration of symptoms or severity of symptoms.
2. Should be written in patient's own language/medical term should not be written, because chief complaints are patient's language.

Example: Mr. Zamal Uddin complained of fever, nausea, loss of appetite for 7 days. He also complained of chest pain for 5 days and coughing out of blood for 3 days.

So, his chief complaints are (according to the duration of symptoms)

1. Fever for 7 days.
2. Chest pain for 5 days.
3. Coughing out of blood for 3 days.

Besides chief complaints can be written according to the severity of the symptoms

1. Chest pain for 5 days.
2. Coughing out of blood for 3 days.
3. Fever for 7 days.

Presentation (particulars + chief complaints) (Presentation usually should be in past tense but some present conditions of the patient can be present in present tense) Mr. Zamal Uddin 65 years, male, muslim, married came from Haragas, Rangpur admitted in Rangpur Medical College Hospital on 9th October at 2 PM and I have examined him on 10th October at 10 AM. His chief complaints are fever for 7 days, chest pain for 5 days and coughing out of blood for 3 days.

History of present illness

This is the elaboration of the chief complaints but also contain other complaints/information.

Contents of history of present illness

1. Elaboration of the chief complaints (in the above given example fever, chest pain and coughing out of blood should be elaborated).
2. Elaboration of the other complaints/information gathering during history taking (in the above given example nausea and loss of appetite should be elaborated).
3. Important negative (relevant) history to exclude differential diagnoses (in the above given example to exclude UTI history of burning sensation during micturition, frequency of micturition should be mentioned).
4. History of appetite, bowel, bladder, sleep pattern and weight loss or gain.
5. History of chronic co-morbid diseases like diabetes, hypertension, IHD, CKD, asthma, tuberculosis, cancer, liver disease etc should be mentioned.

Scanned with CamScanner

Presentation of the history of present illness (presentation usually should be in past tense but some present conditions of the patient can be present in present tense) According to the statement of the patient he was reasonably alright 7 days back then he developed fever which was high grade, continued, did not come with chills and rigor, highest recorded temperature was 104° F, fever used to subside after taking paracetamol, he had no history of travelling to malaria or kala-azar endemic zone. He also complained of right sided chest pain for 5 days, pain was severe, burning in character, aggravated after coughing and relieved after taking drugs and there was no radiation. He also complained of coughing out of blood total 6 times in last 3 days, about 100 ml in each episode, sputum was mixed with blood. Patient also complained of nausea and loss of his appetite. His bowel, bladder, sleep pattern is normal and there is no history of significant weight loss. He is normotensive and not known diabetic. With all the above complaints he admitted in this hospital for better management.

Elaboration of some common symptoms

Fever: Fever is the regulated elevation of the body temperature above the customary set point of the hypothalamic thermostat (elevation of body temperature above the normal daily variation is fever). Normal body temperature is 97.7–99.5°F. Physiologically temperature is lower at morning and higher at evening. Variation is typically 0.9°F. Morning temperature of >98.9°F (roughly >99°F) or an evening temperature of >99.9°F (roughly >100°F) is fever.

Pattern of fever

1. Continued fever
2. Remittent fever
3. Intermittent fever

Continued fever

Definition: Fever which present for 24 hours of the day, never touch the baseline and fluctuates between 1°C is continued fever. Example: Typhoid fever, abscess etc.

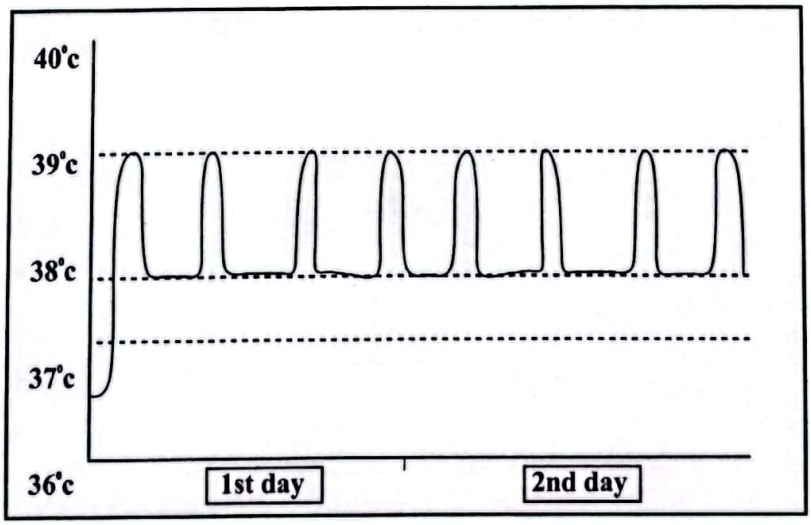

Graph 1 : Continued fever

Scanned with CamScanner

Remittent fever

Definition: Fever which present for 24 hours of the day, never touch the baseline and fluctuates between 2°C is remittent fever. Example: Rickettisial fever (Rocky mountain fever).

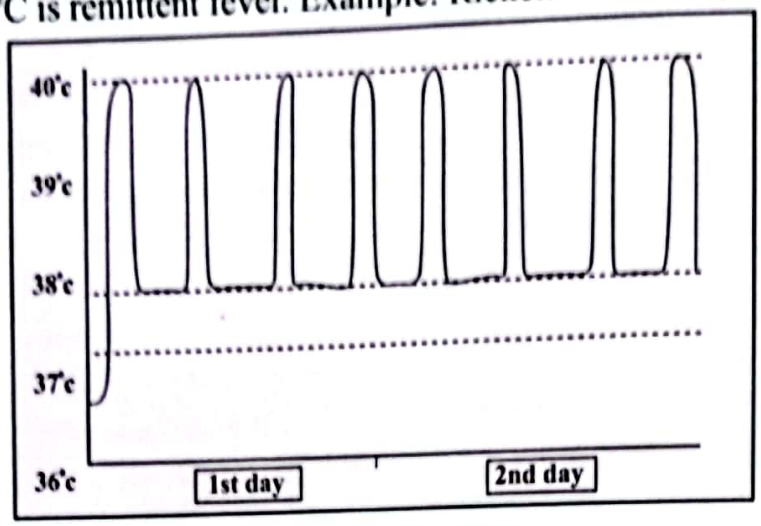

Graph 2 : Remittent fever

Intermittent fever

Fever which present only for few hours of the day and touch the baseline in the rest of the time.

3 types

1. Quatidian fever: Here paroxysm of fever occurs daily. e.g. Kala-azar.

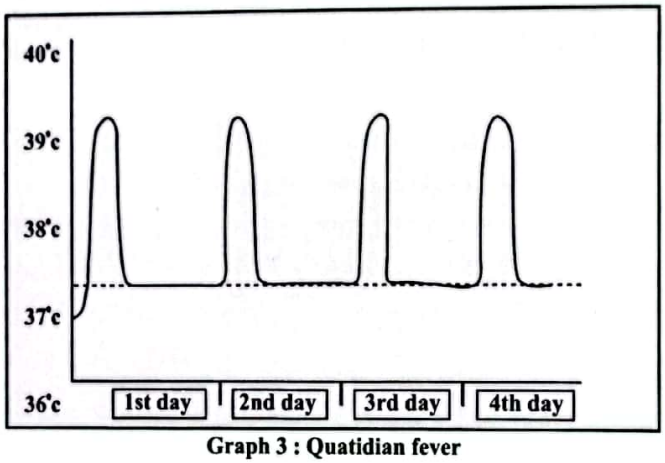

Graph 3 : Quatidian fever

2. Tertian fever: Here paroxysm of fever occurs in every alternative day or come on every 48 hours. e.g. Benign tertian malaria.

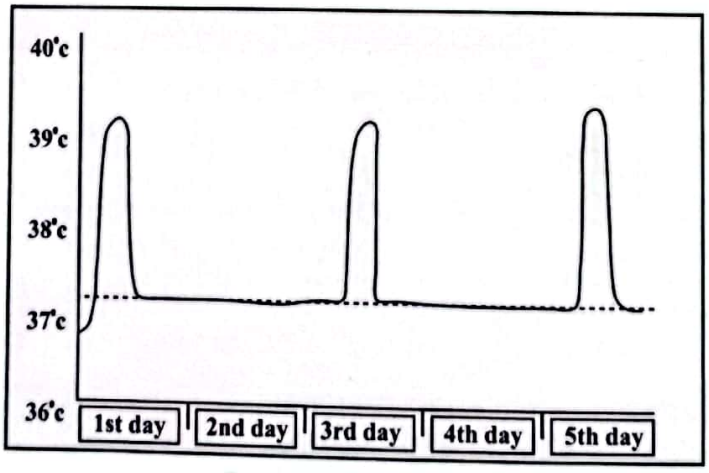

Graph 4 : Tertian fever

Scanned with CamScanner

3. Quartan fever: Here paroxysm of fever occurs in every third day or every 72 hours. e.g. Quartan malaria.

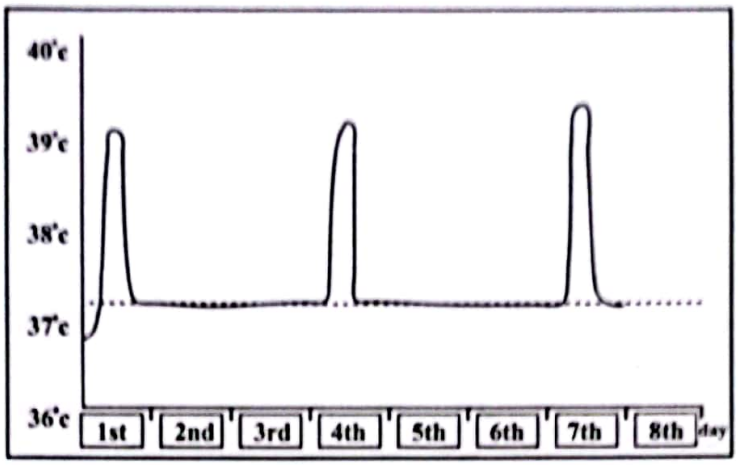

Graph 5 : Quartan fever

If a patient present with fever following history should be taken:

1. Duration of fever- this is very important to search cause of fever. Example- fever of less than 7 days is usually due to viral fever; fever for more than 7 days may be due to typhoid fever, pneumonia, upper UTI, malaria etc. Fever for more than 1 month may be due to tuberculosis, lymphoma, malignancy, SLE etc.
2. Grading of fever

   Low grade fever: 37.3-38°C (99.2 F-101°F) (e.g. Tuberculosis)

   Moderate fever: 38-39°C (101F-103.74^{O}F)

   High fever: 39.1-41°C (103.74F-109.6^{O}F) (viral fever, pneumonia, liver abscess, pyelonephritis, malaria, lymphoma etc.)
3. Pattern of fever- continued, remittent or intermittent.
4. If irregular/intermittent fever then timing of the fever-whether fever usually come in the morning, evening or night. Low grade fever usually come at the evening is usually due to tuberculosis.
5. Highest recorded temperature (for grading of fever).
6. Whether fever comes with chills & rigor- fever usually comes with chills and rigor is malaria, liver abscess, pneumonia, acute pyelonephritis, acute cholangitis etc.
7. Fever subsides spontaneously or with antipyretic or after taking some specific drugs, if so elaboration of that drug history (name and dose of the drug).
8. History of travelling to malaria/kala-azar endemic zone. If a patient develops fever after returning from malaria endemic zone, then this is usually due to malaria.

Scanned with CamScanner

Malaria endemic zones of Bangladesh: Among 64 districts of Bangladesh 13 are malaria endemic. Among the 13 districts following districts are highly endemic of malaria-Khagrachari, Bandarban, Rangamati, Chittagong and Cox's bazaar. Others are Kurigram, Sherpur, Netrokona, Mymensingh, Habigong, Sylhet, Maulovibazar and Sunamgong.

Kala-azar endemic zones of Bangladesh: Mymensingh, Tangail, Sirajgang, Pabna, Natore, Rajshahi, Jamalpur.

Filarial endemic zone of Bangladesh-North Bengal (Nilphamari).

Presentation of fever: According to the statement of the patient he was suffering from fever for 7 days, which was high grade, continued, did not come with chills and rigor, highest recorded temperature was 104° F, fever subsided after taking paracetamol and he had no history of travelling to malaria or kala-azar endemic zone.

Cough

Cough is a forced expulsive maneuver, usually against a closed glottis and which is associated with a characteristic sound. A cough can be classified by its duration, character, quality and timing. The duration can be either acute (of sudden onset) if it is present less than three weeks, subacute if it is present between three to eight weeks and chronic when lasting longer than eight weeks. If a patient present with cough following history should be taken:

1. Duration–long term dry cough may be due to asthma, short duration of cough with productive sputum may be due to pneumonia.
2. Productive or not- if productive then following history needs to be taken:
   a. Amount of sputum- copius amount of sputum occurs in bronchiectasis, lung abscess, empyema thoracics.
   b. Colour of sputum-rusty colour sputum occurs in pneumococcal pneumonia.
   c. Foul smelling present or not-foul smelling sputum occurs in lung abscess, empyema thoracics.
   d. Presence of blood or not. Presence of blood (haemoptysis) indicate bronchial carcinoma, pulmonary tuberculosis etc.
   e. Disturbance of sleep by cough-usually occur in uncontrolled asthma and LVF patient.
3. Diurnal variation of cough-aggravation of cough in morning usually occurs in uncontrolled asthma and cough of COPD aggravated as the day progress.
4. Relation of cough with exposure to dust, cold, pollen etc-asthma usually aggravated on exposure to cold, dust, pollen etc.
5. Seasonal variation of cough-some asthma patient aggravated in winter season and some aggravated during the changing period of season.

Scanned with CamScanner

Presentation of cough: According to the statement of the patient he was suffering from cough for 7 days. Cough is productive, sputum is small in amount, whitish in colour, not foul smelling, does not contain any blood and more marked in the morning, aggravated on exposure to cold, dust and there is no seasonal variation of the cough.

Haemoptysis: Coughing out of blood is called haemoptysis. If a patient present with haemoptysis following history should be taken:

1. Duration/ frequency- haemoptysis of shorter duration may be due to lung cancer, haemoptysis occurs intermittently for years- bronchitis or non-specific RTI.
2. Amount of blood-small or profuse. Profuse/massive (500 mL or more of expectorated blood over a 24 hour period or bleeding at a rate 100 mL/hour or more) amount of haemoptysis occurs in bronchiectasis, tuberculosis, lung cancer etc.
3. Appearance of blood- blood streaking the sputum in smokers may be due to bronchial carcinoma.

Presentation of haemoptysis: Mr. Kamal complaining of coughing out of blood for 7 days, which occurred 1 to 2 times daily, moderate in amount, fresh blood came out with sputum.

Haematemesis: Vomiting out of blood is called haematemesis. Following history should be taken when a patient present with haematemesis:

1. Duration/frequency
2. Amount of blood-small amount or blood streaking in vomits may occur due to repeated vomiting without any significant cause. Amount can be expressed in milliliter (ml) or amount by cup. Example-about 200 ml or 2 cup of blood was present in each episode.
3. History of abdominal pain(PUD)-usually present in bleeding PUD.
4. History of CLD/ jaundice- present in bleeding due to ruptured esophageal varices (occurs in CLD with portal hypertension).
5. History of taking NSAIDs-NSAIDs may cause gastric erosion and haematemesis.
6. History of weight loss, loss of appetite, vomiting, abdominal mass- these features present in carcinoma of stomach.
7. History of passage of black tarry stool (melaena), it usually associated with haematemesis.

Presentation of haematemesis: According to the statement of the patient he was suffering from vomiting out of blood 4 times for 2 days, about 200 ml in each episode. He said that he took pain killer for his knee pain before onset of this illness, but he denied any history of weight loss, jaundice, swelling of the abdomen. He did not pass any black tarry stool during or after the episode of blood vomiting.

Scanned with CamScanner

Breathlessness: An abnormal awareness of breathing which occurs either at rest or an unexpectedly at low level of exertion. Following history should be taken when a patient present with breathlessness:

1. Duration of breathlessness
   a) Long history –asthma, COPD
   b) Sudden onset, severe -acute LVF.
2. Mode of onset
   a) Sudden –LVF, pneumothorax.
   b) Gradual – asthma,COPD.
3. Severity/grading of breathlessness-severe breathlessness usually present in acute exacerbation of COPD, acute severe asthma, acute LVF etc.
4. Relation with exertion-usually breathlessness of any cause aggravate on exertion but this is more marked in heart failure patient.
5. History of orthopnea-breathlessness while lying flat (usually occurs in heart failure patient).
6. History of paroxysmal nocturnal dyspnoea- sleep disturbance due to breathlessness (usually occurs in heart failure patient).
7. Associated features e.g. palpitation, chest pain, cough etc. (usually indicate heart failure).
8. Aggravating factor e.g. asthma aggravated on exposure to cold, dust, pollen etc.
9. Relieving factor e.g. asthma patient get relief of symptoms after use of salbutamol (tablet or inhaler or nebulization); heart failure patient improves after sitting and use of diuretic.

Presentation of breathlessness: According to the statement of the patient he is suffering from breathlessness for 7 days, which is severe, gradual in onset, aggravated after exposure to dust, relieve in sitting position, he cannot sleep due to breathlessness, but there is no history of chest pain, palpitation.

Elaboration of abdominal pain

1. Duration- long term abdominal pain usually due to PUD, abdominal pain of short duration usually due to acute cholecystitis, acute pancreatitis, acute appendicitis, ureteric colic etc.
2. Site- pain of right upper abdomen usually resulting from cholecystitis, pain of right iliac fossa due to appendicitis.
3. Severity- mild pain usually due to PUD. Severe abdominal pain due to acute cholecystitis, acute pancreatitis, acute appendicitis, ureteric colic etc.

Scanned with CamScanner

4. Character- abdominal pain may be burning, pricking, penetrating, compressive etc. Burning epigastric pain usually occurs in PUD.
5. Radiation- pain of cholelithiasis (gall bladder stone) radiates to right shoulder, pain of ureteric stone radiates from loin to inner aspect of the thigh etc.
6. Aggravating factor- whether pain aggravated after taking food, movement etc. Pain of duodenal ulcer aggravate in empty stomach and pain of gastric ulcer aggravate after taking food.
7. Relieving factor- whether pain is relieved after taking food, drugs etc. Pain of duodenal ulcer improves after taking food and gastric ulcer relieve in empty stomach.
8. Associated symptoms (if any).

Presentation of abdominal pain.

Md. Bokul complaints of upper abdominal pain for 10 days, pain is severe, burning in character, aggravate after taking food, relieve in empty stomach, there is no radiation.

Elaboration of headache

1. Duration-headache of longer duration is usually of nonserious aetiology. e.g. tension headache, migraine etc; headache of shorter duration are usually of serious pathology like intracranial space occupying lesion, encephalitis, intracranial haemorrhage etc.
2. Site-unilateral headache usually occurs in migraine, headache that can be pointed with finger is usually of benign pathology.
3. Diurnal variation- headache more marked in the morning usually due to raised intracranial pressure (ICP), headache more marked in the evening usually due to tension headache.
4. In case of intermittent headache-duration of an episode, history of photophobia, phonophobia etc. Each episode of migrainous headache persist 1-4 days and usually associated with photophobia.
5. Aggravating factor –migraine headache usually precipitated by light and sound exposure.
6. Relieving factor- headache due to raised ICP relieve after taking NSAID.
7. History of nausea/ vomiting-early morning vomiting in headache patient usually indicate raised ICP due to any cause commonly ICSOL (intracranial space occupaying lesion).

Presentation of headache: Mr. Rahim complaints of headache for 10 days, headache is severe in the morning, gradually improve as the day progress, aggravate after coughing and relieve after taking drugs, do not associate with vomiting.

Scanned with CamScanner

Vomiting- Following history should be taken when a patient present with vomiting:

1. Duration of vomiting-intermittent vomiting for years is usually benign (may be due to anxiety).
2. Frequency of vomiting.
3. Vomitus

   a) Amount

   b) Content –digested or undigested or partially digested food materials. Undigested food materials present in case of gastric outlet obstruction (GOO).

   c) Bile stained or not-bile stained vomitus usually indicates small intestinal obstruction distal to the opening of common bile duct.

   d) Presence of blood or not.
4. Timing of vomiting- vomiting immediately after taking food indicating gastric outlet obstruction (GOO).
5. Vomiting projectile or not- projectile vomiting usually occur in gastric outlet obstruction.

Presentation of vomiting: Mr. Bokul complaints of vomiting for 10 times in last 2 days, vomitus contains undigested food materials, small in amount, not bile stained, does not contain any blood and not projectile.

Elaboration of jaundice

1. Duration-to classify acute or chronic condition. Mild jaundice without any GI symptoms present for long time, may be due to thalassemia.
2. Prodromal features present or not –those are fever, bodyache, myalgia, arthralgia or arthritis, anorexia, nausea, vomiting, abdominal pain. Presence of prodromal features indicate viral hepatitis.
3. Generalized itching, steatorrhoea, dark urine, abdominal pain (usually present in obstructive jaundice)
4. History related to etiology of hepatocellular jaundice-history of unscreened blood transfusion, IV drug abuse, history of surgery, history of unprotective sexual exposure.

Presentation of jaundice: Mr. Ramjan Ali complaints of yellow colouration of eyes and urine for 1 month, he also said that he was suffering from fever, bodyache, nausea, vomiting before onset of this illness, he did not complaint of any itching, dark urine, passage of bulky & frothy stool, unscreened blood transfusion, needle sharing and unprotective sexual exposure.

Scanned with CamScanner

Edema: Accumulation of excess fluid in the interstitial spaces and serous cavities is called edema. A generalized infiltration of edema fluid into subcutaneous connective tissue is called anasarca. Following points to be noted during history taking of edema:

1. Duration of edema. Edema particularly in leg developed occasionally (after long journey) for long time is normal without any underlying cause, this is particularly seen in female patient.
2. Site of first appear –first appeared in

   Face –problem usually in kidney e.g. AGN, NS.

   Leg- problem usually in heart e.g. CCF.

   Abdomen- problem usually in liver e.g. CLD.
3. History of sore throat, skin lesion, decrease urine output, passage of high colour urine (indicate AGN/nephritic syndrome).
4. History of chest pain, palpitation, breathlessness (indicates heart failure).
5. History of jaundice-present in CLD.
6. History of steatorrhoea (bulky, frothy, foul smelling and difficult to flash from the pan-present in malabsorption).
7. History of cold intolerance, weight gain, somnolence, voice change, constipation and menorrhagia-present in hypothyroidism.
8. Drug history: OCP (oral contraceptive pill), NSAIDs, steroid, calcium channel blockers (amlodipine) etc.

Presentation of edema: Mrs Maloti Rani complained of swelling of whole body for 2 months, swelling first appeared in face then gradually involved the whole body. She also complained of reduction of urine out, passes of high colour urine, but she did not complain of any chest pain, breathlessness, palpitation, yellow colouration of eyes & urine, pain in throat, skin lesion, cold intolearance and somnolence.

Elaboration of hypertension

1. Duration of hypertension-patient with history of hypertension for long time may present with any of the complications (stroke, CKD, IHD).
2. Basis of diagnosis of hypertension-whether diagnosed incidentally or during routine check up or when the patient presented with any complication of hypertension.
3. Present medication-name and dose of the drug, taking regularly or irregularly.
4. Status of follow up-regular or irregular, blood pressure control or uncontrolled during follow up.

Scanned with CamScanner

5. Presence of complication or not.

   (Complication of hypertension: Stroke, IHD, CKD, Hypertensive retinopathy, PVD etc).

Presentation of hypertension: Md. Robin was diagnosed as a case of hypertension 5 years back, during routine checkup, since then he is taking tablet tenoloc 50 mg once daily regularly, he is in regular follow up and his blood pressure was controlled during follow up. He does not have any complication of hypertension.

Elaboration of diabetes mellitus

1. Duration- patient with history of DM for long time may present with any of the complications (stroke, CKD, IHD) of DM.
2. Basis of diagnosis-incidental diagnosis or diagnosed when presented with complication etc.
3. Treatment history- types of treatment (life style modification, oral antidiabetic drug, insulin) and taking regularly or irregularly.
4. Follow up status-regular or irregular.
5. Follow up blood sugar-controlled or uncontrolled, if uncontrolled then causes of uncontrolled DM like irregular dietary and lifestyle modifications, irregular taking drugs etc.
6. Knowledge about identification and management of hypoglycemia.
7. History of acute complications e.g. hypoglycaemia or hyperglycaemia.
8. History of chronic complications e.g. IHD, stroke, PAD, retinopathy, nephropathy.
9. History of foot ulcer.

Presentation of DM: Mr. Salauddin was diagnosed as a case of diabetis mellitus 10 years back on the basis of symptoms and blood sugar testing; after diagnosis he was put on life style modification and tablet gluconor 1mg daily. After that he was under regular follow up and his blood sugar was controlled. He is able to identify and manage hypoglycaemia. He has no history of acute or chronic complications of diabetes mellitus.

History of past illness: This includes

1) Any past illness that is related to the present illness including its management.
2) History of any major illness.
3) History of any surgical intervention.

Presentation of history of past illness: Mr Rahim was suffering from fever 2 years back and was admitted in Rangpur Medical College hospital for 10 days, there he received 7 days course of inj. ceftriaxone 1 gm 12 hourly, after that he recovered.

Scanned with CamScanner

Drug/ treatment history: This includes

1) The name of the drugs that the patient has taken for the present illness (dose & duration of the drugs and effect of the drug intake should be noted).

2) Any drugs he/she is taking for any chronic illness.

3) Any diagnostic procedures like lymph node biopsy, CSF study etc.

4) Any intervention like blood transfusion, ascites and pleural fluid paracentesis etc.

Presentation of treatment history: For the presenting complaints the patient consulted with a registered doctor and took tablet napa (500 mg) 3 times daily and cap. seclo (20 mg) 2 times daily but he had no significant improvement.

Family history: This includes

1. Health status of the patient's family members (parents, brothers and sisters).
2. Whether any family members suffering from similar type of illness/ disease.
3. In case of death of any family members-cause of death.
4. Is there any illness that run in the patient's family e.g. thalassemia, haemophilia etc.

Presentation of family history: Mr Rahim's parents, one brother & one sister are alive & healthy. None of them are suffering from similar type of illness.

Personal history: This includes

1. Occupation of the patient.
2. Smoking history-this should be expressed in pack year {1 pack year = (number of sticks/20) ×year}.
3. If stopped smoking then duration and causes of stopping smoking.
4. History of alcohol intake and parentral drug abuse.

Presentation of personal history: Md Rahim is a farmer and smoker. He smoked about 10 pack years & stopped smoking 6 months back due to cough & breathlessness, and he is not alcoholic & there is no history of parentral drug abuse.

Socio-economic history: This includes

1. Social position of the patient (upper, middle or lower class).
2. Drinks tube well water or not.
3. Use sanitary latrine or not.

Presentation of socio-economic history: He is belongs to middle class family, drinks tube well water and use sanitary latrine.

Scanned with CamScanner

Immunization history: This includes name of the vaccines he/she has taken, commonly ask about EPI schedule, hepatitis B vaccine etc.

Presentation of immunization history: The patient was immunized according to EPI schedule. But he did not take any other vaccine.

Menstrual history (in case of female) following history should be taken

Age of menarchae

Menstrual cycle (28 ±2)

Menstrual period (3-7 days)

LMP (first day of last menstrual period)

Dysmenorrhoea present or not

Menorrhagia present or not

Para and gravida (in case of pregnant lady).

Presentation

Mrs shefali's age of menarche was 13th year, menstrual cycle (28 ±2), menstrual period 3-4 days, her LMP was 3rd october, there is no history of dysmenorrhoea and menorrhagia.

Presentation of history

Mr. Zamal Uddin 65 years, male, muslim, married came from Haragas, Rangpur admitted in Rangpur Medical College Hospital on 9th October at 2 PM and I have examined him on 10th October at 10 AM. His chief complaints are fever for 7 days, chest pain for 5 days, coughing out of blood for 3 days. According to the statement of the patient he was reasonably alright 7 days back, then he developed fever which is high grade, continued, does not come with chills and rigor, highest recorded temperature was 104° F, fever subsided after taking paracetamol, he had no history of travelling to malaria or kala-azar endemic zone. He also complained of right sided chest pain for 5 days, pain is severe, burning in character, used to aggravate after coughing and relieved after taking drug (mention name if patient can tell) and there is no radiation. He also complained of coughing out of blood total 6 times for 3 days, about 100 ml in each episode, blood was mixed with sputum. Patient also complained of nausea and loss of his appetite during the course of his illness. His bowel, bladder, sleep pattern is normal and there is no history of significant weight loss. He is normotensive and not known diabetic. With all the above complaints he admitted in this hospital for better management.

Scanned with CamScanner

2 years back, he was suffering from fever and was admitted in Rangpur Medical College hospital for 10 days, after that he recovered. For the presenting complaints the patient consulted with a registered doctor and took tablet napa (500 mg) 3 times daily and cap. seclo (20 mg) 2 times daily but did not get significant improvement. His parents, one brother & one sister are alive & healthy. At present none of them are suffering from similar type of illness. He is a farmer and smoker. He smoked about 10 pack years & stopped smoking 6 months back due to cough & breathlessness and he is not alcoholic & there is no history of parentral drug abuse. He belongs to a middle class family, drinks tube well water and use sanitary latrine. The patient was immunized according to EPI schedule but he did not take any other vaccine.

General physical examination

Points to be noted during general physical examination

1. Appearance
2. Body build
3. Nutritional status
4. Behaviour
5. Decubitus
6. Anaemia
7. Jaundice
8. Cyanosis
9. Clubbing
10. Koilonychia
11. Leuchonychia
12. Oedema
13. Dehydration
14. Pulse
15. Blood pressure
16. Temperature
17. Respiratory rate
18. JVP
19. Thyroid gland
20. Lymph nodes
21. Bony tenderness
22. Skin condition
23. Hair distribution
24. Spider naevi
25. Gynaecomastia
26. Others-any other important findings should be noted like IV canula, catheter in situ, AV fistula, tattoo mark etc.

Scanned with CamScanner

Appearance- many diseases can be diagnosed by looking at the face. Examples are given below:

Puffy face usually occurs in

a) AGN (acute glomerulonephritis)

b) Nephrotic syndrome

Butterfly rash

a) SLE (figure 1)

Moon face

a) Cushing syndrome

Deviation of the mouth to the opposite side

a) Facial nerve palsy

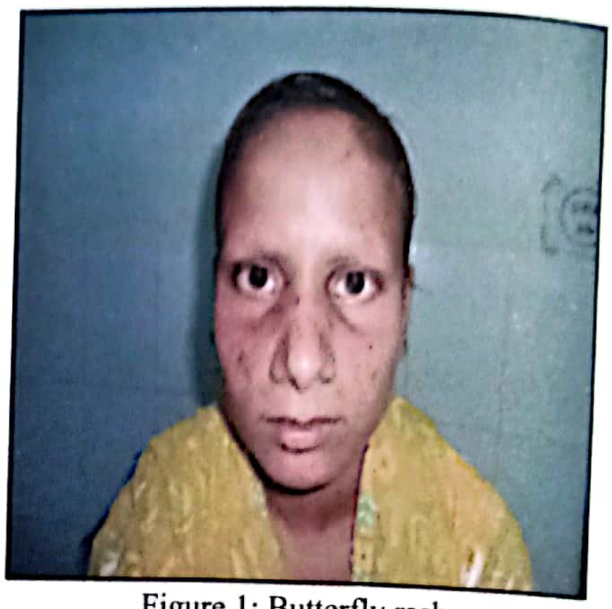

Figure 1: Butterfly rash

Ptosis

Drooping of the upper eye lid and inability to open it is called ptosis. It may be unilateral or bilateral. Normally upper eyelid covers 1-2 mm of the cornea but never touch the margin of the pupil, in ptosis it touches the pupil or beyond pupil.

Causes of unilateral ptosis

1. Congenital
2. 3rd nerve palsy
3. Horner's syndrome

Causes of bilateral ptosis

1. Myasthenia gravis
2. Ocular and oculo-pharyngeal myopathy
3. Neurotoxic snake bite
4. Bilateral 3rd nerve palsy

Figure 2: Bilateral partial ptosis. This was a case of neurotoxic snake bite, later this patient developed complete ptosis.

Scanned with CamScanner

Ptosis also may be partial or complete.

Causes of partial ptosis (figure 2)

1. Congenital (unilateral)
2. Myasthenia gravis (bilateral)
3. Horner's syndrome (unilateral) (components of Horner's syndrome are- partial ptosis, miosis, enopthalmus and anhydrosis).

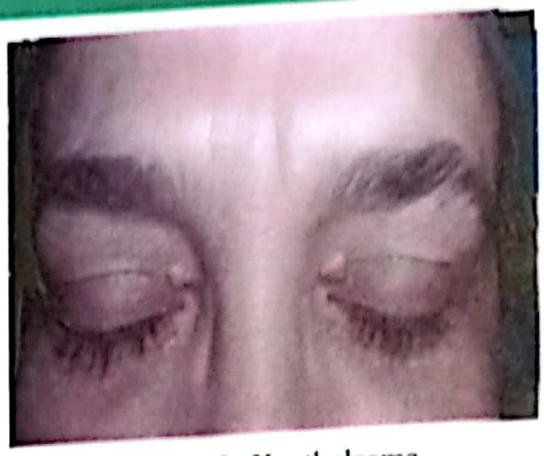

Figure 3: Xanthelasma

Causes of complete ptosis

1. Congenital
2. 3rd nerve palsy
3. Neurotoxic snake bite

Lid retraction: Normally upper eyelid covers 1-2 mm of the cornea, when the upper lid is away from the cornea is called lid retraction. (Figure 4)

1. Thyrotoxicosis

Xanthelasma

1. Familial hypercholesterolemia (Figure 3)

Frontal bossing

1. Thalassemia

Anxious face

1. Thyrotoxicosis
2. Anxiety neurosis

Depressed face

1. Major depressive illness
2. Hypothyroidism

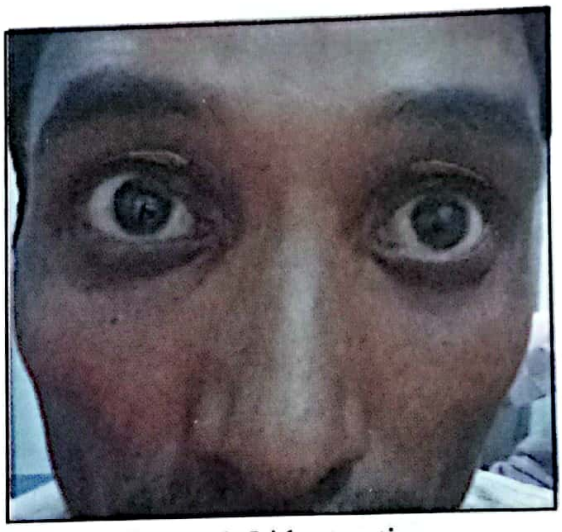

Figure 4: Lid retraction.

Body build

It is the skeletal framework of the body. It varies from region to region e.g. average height of the Asian people differs from the European people. When any patient is taller than the usual height of that region he/she is said to have tall stature and vice versa.

Causes of tall stature

1. Constitutional (parents tall, children are tall)
2. Marfan's syndrome
3. Hypogonadism due to any cause
4. Gigantism
5. Homocysteinuria
6. Klinefelter syndrome

Scanned with CamScanner

Causes of short stature

1. Constitutional (parents short, children are short)
2. Down's syndrome
3. Turner's syndrome
4. Cretinism
5. Achondroplasia

Nutritional status

This is assessed by

1. BMI (body mass index)
2. Waist-hip ratio
3. Mid upper arm circumference (MUAC)
4. Axillary fold thickness

In adult BMI and waist-hip ratio commonly used.

BMI (body mass index)

BMI = Weight in kg/ height in meter square

Normal BMI =18.5-24.9 kg/m^2

Over weight = 25-29.9 kg/m^2

Obese = 30-39.9 kg/m^2

Morbid obese >40kg/m^2

Under weight < 18.4 kg/m^2

Waist-hip ratio

Waist-hip ratio is the measurement of the central obesity. This is the ratio of the waist circumference at the level of the midway between highest point of the iliac crest and costal margin and hip circumference at the level of the greater trochanter (figure 5).

Figure 5: Measurement of the waist (right) and hip (left).

Scanned with CamScanner

Normal waist-hip ratio (WHR) <0.90 in male and <0.85 in female.

What is central obesity?

Waist-hip ratio (WHR) >0.90 in male and >0.85 in female is called central obesity. Central obesity ia a important risk factor for developing cardiovascular diseases.

Mid-Upper Arm Circumference (MUAC)

It is the circumference of the left upper arm, measured at the mid-point between the tip of the shoulder and the tip of the elbow (olecranon process and the acromium) (Figure 6).

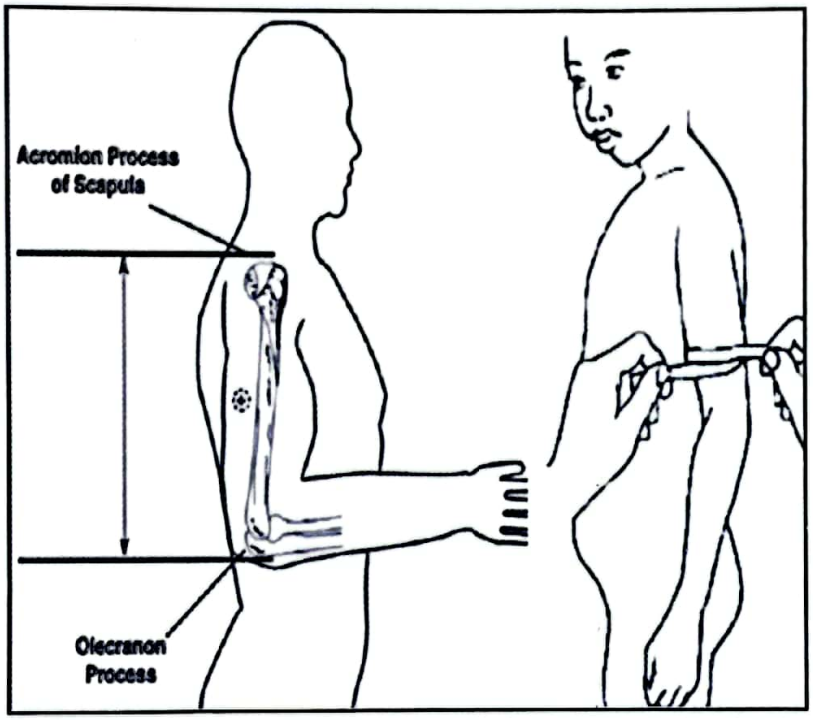

Figure 6: Mid-upper arm curcumference measurement.

MUAC is recommended for use with children between six and fifty-nine months of age and for assessing acute energy deficiency in adults during famine.

Mid arm circumference interpretation

YELLOW COLOUR-MUAC of between 125mm (12.5cm) and 135mm (13.5cm), indicates that the child is at risk for acute malnutrition and should be counseled and followed-up for Growth Promotion and Monitoring (GPM).

GREEN COLOUR -MUAC over 135mm (13.5cm), indicates that the child is well nourished.

Scanned with CamScanner

Behaviour

Whether the patient is co-operative or not. A non-co-operative patient may indicate electrolyte imbalance (hyponatraemia), encephalitis, encephalopathy or suffering from any psychiatric illness.

Decubitus

Decubitus is the posture in which the patient feels comfortable.

Example:

1. In acute left ventricular failure- patient feels better in sitting position (propped up position).
2. In acute pancreatitis-patient feels better in sitting and leaning forward (Mohammedan prayer position) (figure 7).

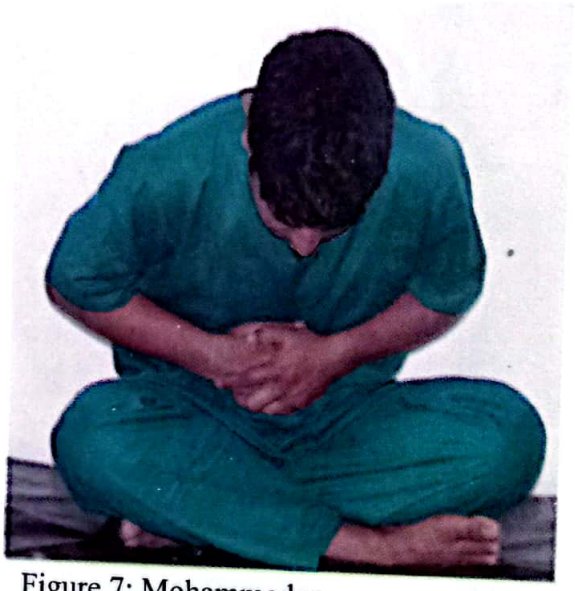

Figure 7: Mohammedan prayer position

Anaemia

Anaemia may be defined as a clinical condition characterized by pale colouration of the skin and mucous membrane due to reduced hemoglobin below the normal physiological range in respect to the age and sex of the individual. In adult normal hemoglobin is 14-17 gm/dl, if any adult's hemoglobin is <14 gm/dl then he/she has anaemia.

Sites of examination of anaemia

1. Lower palpebral conjunctiva
2. Dorsum of the tongue
3. Palmar creases
4. Nail bed
5. Sole of the feet
6. Skin of the whole body

Scanned with CamScanner

Steps of examination of anaemia

1. Greetings and consent.
2. Patient should be in lying position.

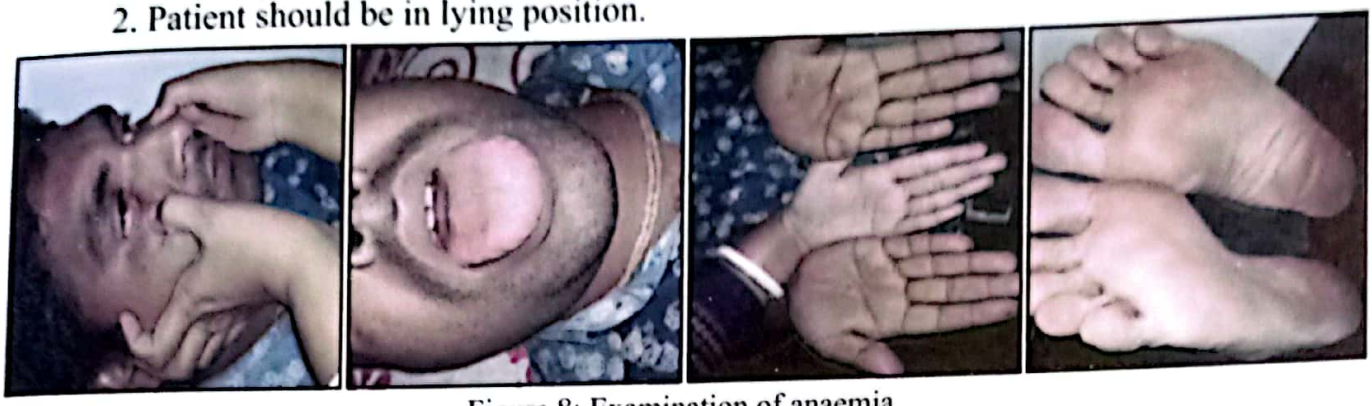

Figure 8: Examination of anaemia.

3. Evert the both lower eyelids by thumbs and ask the patient to look upwards (to see lower palpebral conjunctiva) (figure 8).
4. Ask the patient to protrude the tongue and inspect the dorsum (upper surface) of the tongue.
5. Ask the patient to place both hands in front with palm upwards and look to the palmar creases and place the examiner's left hand in between them (to compare).
6. Turn the both hands of the patient to see the nail bed of both hands and place the left hand of the examiner in between them to compare.
7. Go to the patient's foot end and inspect the sole of the foot.
8. Thank the patient.

Grading of anaemia

1. Mild anaemia: Hb 9-12 gram/dl e.g. anaemia of chronic disease.
2. Moderate anaemia: Hb 6-<9 gram/dl, e.g. anaemia due to mild to moderate blood loss .
3. Severe anaemia: Hb <6 gram/dl, e.g. aplastic anaemia, acute leukaemia etc.

Common causes of anaemia in practice

1. Helminthiasis
2. Blood loss due to menorrhagia, bleeding piles, PUD, carcinoma stomach
3. Anaemia of chronic disease e.g. Tuberculosis, Rheumatoid arthritis etc.
4. Haemolytic anaemia
5. Acute leukaemia
6. Aplastic anaemia

A simple way to diagnose cause of anaemia

	Anaemia	Jaundice	Bleeding manifestation (gum bleeding, purpura etc)	Lymphade nopathy	Bony tenderness	Hepatosple enomegally
Acute leukaemia	Present	Absent	Present	Present	Present	Present
Thalassemia	Present	Present (mild)	Absent	Absent	Absent	Present
Aplastic anaemia	Present	Absent	Present	Absent	Absent	Absent

Scanned with CamScanner

Jaundice

Jaundice is a clinical condition characterized by yellow colouration of the skin, mucous membrane, eyes and urine due to excess accumulation of bilirubin in blood. Normal serum total bilirubin is 0.3 to 1.9 mg/dL, jaundice is usually clinically evident only if serum total bilirubin is more than 3 mg/dL.

Bilirubin metabolism

1. Bilirubin is produced from the catabolism of haem. Daily 425 and 510 mmol (250–300 mg) of unconjugated bilirubin is produced. Bilirubin in the blood is normally almost all unconjugated, because it is not water-soluble, so cannot pass into the urine. Pre-hepatic (haemolytic) jaundice occurs due to excess production of bilirubin as occurs in haemolytic anaemia (thalassemia). Jaundice due to haemolysis is usually mild because a healthy liver can excrete a bilirubin load six times greater than normal before unconjugated bilirubin accumulates in the plasma.

2. Unconjugated bilirubin is taken up by hepatocytes, where it is conjugated by UDP-glucuronyl transferase, producing bilirubin mono- and diglucuronide (figure 9). Impaired conjugation by this enzyme is a cause of inherited hyperbilirubinaemias (Gilbert's syndrome). In hepatocellular (hepatitis) jaundice, both conjugation of bilirubin and excretion to bile canaliculi is impaired.

3. These conjugated bilirubin are water-soluble and is excreted in the bile and passes into the duodenal lumen via bile duct. In large intestine, conjugated bilirubin is metabolized by colonic bacteria to form stercobilinogen, which may be further oxidized to stercobilin. Both stercobilinogen and stercobilin are then excreted in the stool, contributing to its brown colour. Obustructive jaundice occurs when conjugated bilirubin cannot excrete due to biliary obstruction, which results in reduced stercobilinogen in the stool, and the stools become pale.

4. A small amount of stercobilinogen (4 mg/day) is absorbed from the bowel and is excreted in the urine, where it is known as urobilinogen or, following further oxidization as urobilin.

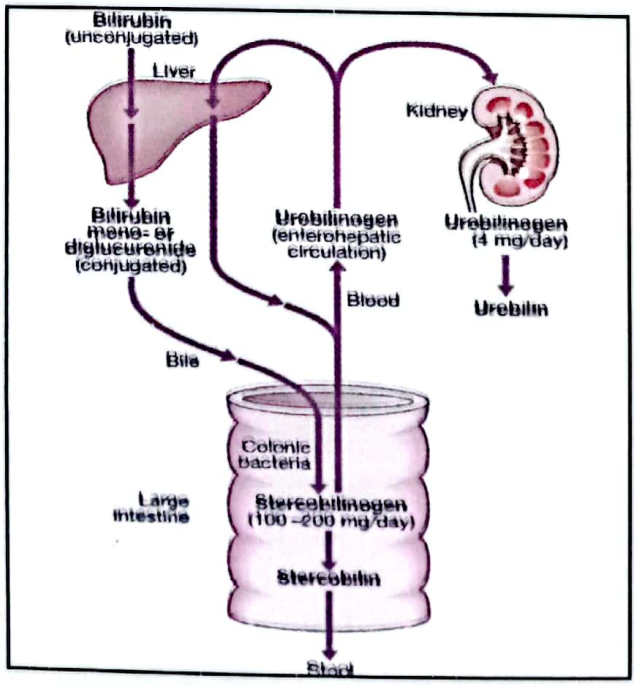

Figure 9: Bilirubin metabolism

Scanned with CamScanner

Sites of examination of jaundice

1. Upper sclera
2. Under surface of the tongue
3. Palm of the hands
4. Sole of the feet and
5. Skin of the whole body.

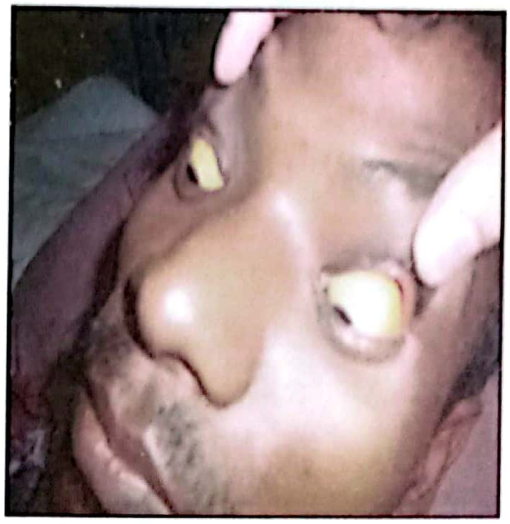

Figure 10: Examination of jaundice.

Steps of examination of jaundice

1. Greetings and consent.
2. Patient should be in lying position.
3. Elevate the both upper eyelids by the left thumb and index finger; and ask the patient to look downwards (to see the upper sclera) (figure 10).

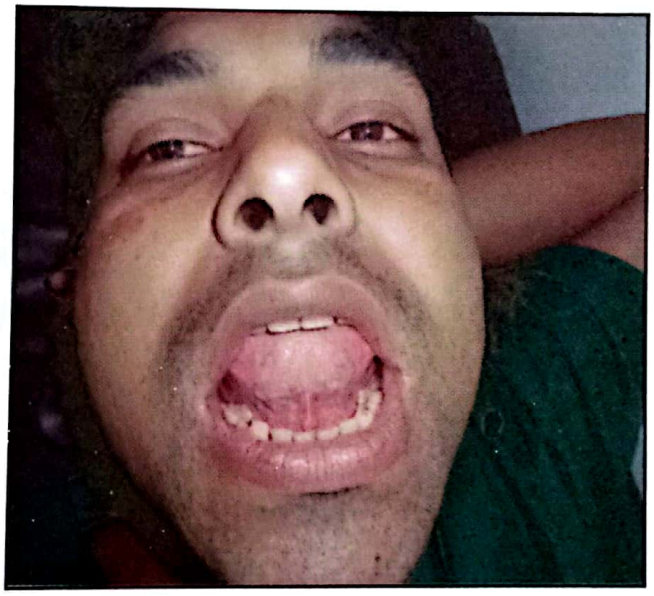

Figure 11: Examination of jaundice
(in under surface of the tongue).

4. Ask the patient to protrude the tongue and touch the hard palate, then inspect the under surface of the tongue (figure 11).
5. Ask the patient to place both hands in front with palm upwards and look to the palmar creases and place the examiner's left hand in between them (to compare).
6. Turn the both hands of the patient to see the nail bed of both hands and place the left hand of the examiner in between them to compare.
7. Go to the patient's foot end and inspect the sole of the feet.
8. Thank the patient.

Scanned with CamScanner

Types of jaundice

1. Prehepatic (haemolytic jaundice)
2. Hepatic (hepatocellular jaundice)
3. Posthepatic (obstructive jaundice)

Clinical grading of jaundice

1. Mildly icteric e.g. haemolytic jaundice (Thalassemia), malaria, septicaemia.
2. Moderately icteric e.g. hepatocellular jaundice (hepatitis).
3. Severely icteric e.g. obstructive jaundice due to any causes.

Prehepatic (haemolytic jaundice)

Occurs due to excess breakdown of RBC, results in increase production of bilirubin, which fail to conjugate in liver. So, in this type of jaundice predominantly unconjugated hyperbilirubinaemia occurs.

Causes of prehepatic (haemolytic jaundice)

1. Heriditary haemolytic anaemia (thalassaemia)
2. Malaria
3. Septicaemia and
4. Poisonous snake bite (hematotoxic snake bite).

Hepatic (hepatocellular) jaundice: Here damaged hepatocyte cannot conjugate bilirubin, besides conjugated bilirubin cannot excrete through damaged intrahepatic billiary channels. So, in this type of jaundice both unconjugated and conjugated bilirubin increased.

Causes of hepatic jaundice

1. Acute viral hepatitis
2. Drug induced hepatitis (antitubercular drugs- rifampicin, pyrazinamide; paracetamol, atrovastatin, methotrexate etc)

Features of acute viral hepatitis:

1. Prodormal symptoms (fever, nausea, vomiting, arthralgia etc) before onset of jaundice.
2. Jaundice
3. Liver-palpable, tender.

Obstructive jaundice: In this type of jaundice conjugated bilirubin cannot excrete due to obstruction in bile duct.

Scanned with CamScanner

Causes of obstructive jaundice

1. Stone in common bile duct (choledocholithiasis)
2. Carcinoma of the head of the pancreas and
3. Cholangiocarcinoma.

Features of obstructive jaundice:

1. Deep jaundice
2. Dark urine
3. Steatorrhoea (pale, frothy, bulky, foul smelling stool, difficult to flush from the pan)
4. Generalized itching
5. Usually patient have abdominal pain

Common causes of jaundice in clinical practice

1. Acute viral hepatitis
2. Obstructive jaundice due to any cause
3. Drug induced hepatitis
4. Haemolytic anaemia
5. Malaria
6. Septicemia

How to differentiate haemolytic, hepatocellular and obstructive jaundice clinically?

Points	Haemolytic jaundice	Hepatocellular jaundice	Obstructive jaundice
Prodormal symptoms	Absent	Usually present	Absent
Severe abdominal pain	Usually absent	Usually absent	Present
Generalized itching	Absent	Usually absent	Present
History of steatorrhoea	Absent	Absent	Usually present
Severity of jaundice	Mild	Mild to moderate	Severe
Fever, history of unscreened blood transfusion	Absent	May be present	Absent
Liver and spleen	Usually palpable	Liver enlarge, tender	Not palpable
Abdominal mass	Absent	Absent	May be present

Cyanosis

Cyanosis may be defined as bluish colouration of the tongue, tip of the fingers and toes due to accumulation of excessive reduced hemoglobin in blood. Cyanosis usually occur when more than 5gm/dl reduced hemoglobin accumulate in blood.

Scanned with CamScanner

Sites of examination of cyanosis

1. Tip of the nose
2. Ear lobule
3. Lips
4. Tongue
5. Tip of the fingers and toes

Figure 12: Peripheral cysnosis

Steps of examination of cyanosis

1. Greetings and consent.
2. Patient should be in lying position.
3. Look at the tip of the nose and both ear lobule of the patient.
4. Look at the lips and ask the patient to open the mouth and look at the tongue.
5. Look at the tip of the fingers of the patient.
6. Go to the patient's foot end to see the tip of the toes.
7. Thank the patient.

Types of cyanosis

1. Central cyanosis
2. Peripheral cyanosis

What are the differences between central and peripheral cyanosis?

Central cyanosis	Peripheral cyanosis
1. Must affect the tongue.	1. Never affect the tongue, usually affect the periphery.
2. Affected part warm.	2. Affected part cold.
3. Application of warmth-cyanosis persists.	3. Application of warmth-cyanosis disappear.
4. Application of O_2 -cyanosis disappears.	4. Application of O_2 -cyanosis may not disappear.
5. Due to inadequate oxygenation in lungs.	5. Due to vasoconstriction on exposure to cold.

Common causes of cyanosis in clinical practice

1. Acute exacerbation of COPD
2. Acute left ventricular failure
3. Acute exacerbation of asthma
4. Congenital cyanotic heart diseases (e.g. TOF-tetralogy of Fallot's)

What is congenital heart disease?

Congenital heart diseases are the diseases of heart that present from birth. Those may be acyanotic and cyanotic.

Scanned with CamScanner

What is congenital acyanotic heart disease?

Those heart diseases present from birth but cyanosis is usually absent. Cyanosis may appear when shunt reverse occurs. Examples are VSD (ventricular septal defect), ASD (atrial septal defect), PDA (persistent ductus arteriosus).

(Normal shunt in heart means-blood flows from left side of the heart to right side of the heart through VSD or ASD due to hight pressure blood of the left side of the heart, shunt reverse means blood flows from right to left side of the heart through VSD or ASD due to development of pulmonary hypertension.)

What is congenital cyanotic heart disease?

Congenital cyanotic heart diseases are the diseases of heart that present from birth and cyanosis must be present. Examples are Tetralogy of Fallot's (TOF), transposition of the great vessels, total anomalous pulmonary venous return, persistent truncus arteriosus, Ebstein anomaly etc.

What are the components of tetralogy of Fallot's (TOF)?

1. Pulmonary stenosis
2. Right ventricular hypertrophy
3. Ventricular septal defect (VSD) and
4. Overriding of the aorta

Clubbing

Edema and swelling of the base of the nail bed is called clubbing.

Changes of clubbing

1. Edema and swelling of the base of the nail bed.
2. Loss of angle between the nail base and nail bed.
3. Loss of longitudinal ridges of the nail plate.
4. Increased convexity of the nail from side to side and above downwards.
5. In advanced stage
   - -Parrot's beak
   - -Drumstick appearance.

Causes of clubbing

A. Familial clubbing

B. Acquired causes

Respiratory causes

1. Bronchial carcinoma
2. Lung abscess
3. Bronchiectasis
4. Empyema thoracis
5. Advanced stage of pulmonary tuberculosis

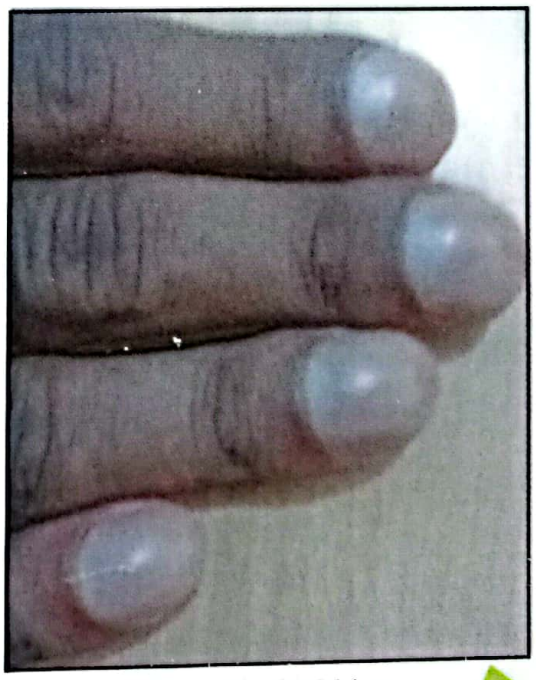

Figure 13: Clubbing.

Scanned with CamScanner

Cardiovascular system causes
1. Congenital cyanotic heart disease
2. Infective endocarditis

Hepatobilliary causes
1. Cirrhosis of liver
2. Primary billiary cirrhosis.

Gastrointentinal causes
1. IBD (inflammatory bowel disease)

Endocrine disease
1. Grave's disease



Figure 14: Examination of clubbing (inspection of the fingers).

Steps of examination of clubbing

1. Greetings and consent.
2. Patient should be in sitting/ supine position.
3. Ask the patient keep both hands (with palm downward) in front and place the examiner's left hand in between them (to compare). Look at the base of the nail bed of the patient (at a profile view) and compare (figure 14).
4. Ask the patient to keep both thumbs together so that one nail will be on another and see any gap present or not (Schamroth's windows test) (figure 15). Normally a 'lozenge' shape gap is present. In case of clubbing this gap disappear.

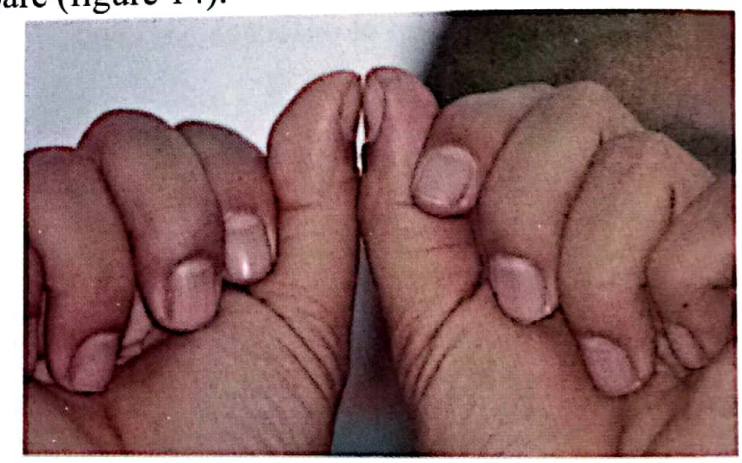

Figure 15: Shamroth's windows test.

5. Palpate the base of the nail bed, ask the patient to take the hand in front, fix the tested finger by examiner's both middle finger and thumbs and palpate by the both index fingers.
6. Go to the patient's foot end and inspect the toes (to see the presence or absence of clubbing in toes) (figure 16).
7. Thank the patient.

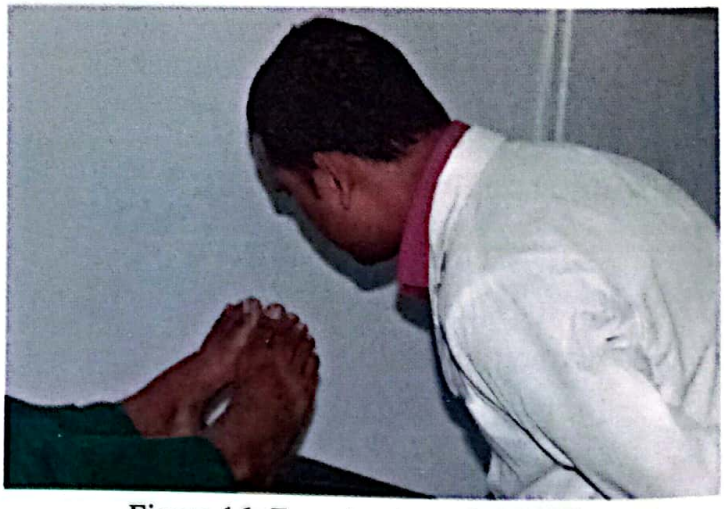

Figure 16: Examination of clubbing (inspection of the toes).

Scanned with CamScanner

Koilonychia

Koilonychia is the changes of nail characterized by flattening, thinning, ridging and spoon shaped in advanced stage.

Stages of koilonychia

1st stage: Dryness, brittle and ridging of the nail plate (figure 17).

2nd stage: Flattening and thinning of the nail plate.

3rd stage: Spooning or concave shape of the nail (figure 17).

Causes of koilonychia

1. Iron deficiency anaemia
2. Trauma (in garage mechanics)

Figure 17: Advanced stage of koilonychia, look spoon shape and brittleness of the nail

Leuconychia

Leuconychia means whitening of the nail (figure 18).

Causes (hypoalbuminia due to any cause)

1. CLD (common cause)
2. Nephrotic syndrome
3. CKD (chronic kidney disease)
4. Malnutrition (malabsorption)

Figure 18: Leuconychia

Edema

Accumulation of excessive fluid in the interstitial spaces and serous cavities is called edema.

Sites of examination of edema

1. Over the medial malleolous in ambulant patient.
2. Over the sacrum in bed ridden patient.

Procedure of edema examination

1. Greetings and consent.
2. Patient should be in lying position and expose both legs.

Figure 19: Examination of leg edema.

Scanned with CamScanner

3. Sustained pressure (for 5 seconds) should be given with the both thumbs a little above the medial malleolous of both sides and look at the patient's face (figure 19).

4. If pit is present then patient have edema. Then wait for 1 minute, if pit persist after 1 minute then it is pitting edema and if pit disappear then it is non-pitting edema. If there is no pit then patient doesn't have any edema.

5. Thank the patient.

Types of edema (according to site of involvement)

1. Generalized edema
2. Localized edema

Generalized edema (anasarca)

Generalized edema refers to edema that affects the whole body.

Causes are

1. CCF (congestive cardiac failure)
2. Cirrhosis of liver
3. Nephrotic syndrome
4. CRF (chronic renal failure)
5. Malnutrition (hypoprotenaemia)

Causes of localized edema

Localized edema is that involve localized organ or localized area of the body. As for example-edema of one leg or limb. Causes are

1. Inflammatory edema

2. Edema due to venous/lymphatic obstruction e.g. DVT, superior vena caval obstruction, inferior vena caval obstruction etc.

According to the presence of pit or not edema may be

1. Pitting edema-edema that pits on pressure. Examples are CCF, Cirrhosis of liver, Nephrotic syndrome, CRF (chronic renal failure) etc.

2. Non-pitting edema-do not pit on pressure.

Causes of non-pitting edema

1. Hypothyroidism
2. Filariasis
3. If pitting edema persisting for long time.

Scanned with CamScanner

Dehydration

It is a clinical condition where excess water loss from the body and it occurs when loss of fluid is more than intake. Dehydration needs to identify and correct as early as possible, because prolonged dehydration may result in AKI.

Causes of dehydration

1. Diarrhoea due to any cause
2. Vomiting due to any cause
3. Inadequate fluid intake in chronic illness patient

Clinical grading of dehydration

1. No sign of dehydration
2. Some signs of dehydration
3. Severe dehydration

Clinically dehydration should be assessed by asking the patient about thirst and urine output; looking at the eyes and skin pinch over the abdomen.

Points	No sign of dehydration	Some signs of dehydration	Severe dehydration
Appearance	Normal	Lethargic	Obtunded
Eyes	Normal	Sunken	Very sunken
Tongue	Normal (wet)	Dry	Very dry
Skin pinch	Goes back normally	Goes back slowly	Goes back very slowly
Pulse	Normal	Rapid, low volume	Very fast, thready
Blood pressure	Normal	Normal or low, orthostatic hypotension present	Very low (shock)
Urine output (definitive sign)	Normal	Reduce	Grossly reduce

Pulse

Pulse should be examined at the radial artery for rate and rhythm. Arterial pulse should be counted when the patient is at rest and for 15 seconds if rhythm is regular and for 1 minute if rhythm is irregular. For details see CVS.

Blood pressure

Blood pressure should be measured at the arm (brachial artery) in sitting position by a sphygmomanometer. Both auscultatory and palpatory method should be used. For details see CVS.

Temperature

Temperature should be measured by a thermometer inserting in mouth for one minute. Commonly axillary temperature is measured.

Scanned with CamScanner

Respiratory rate

It should be counted over 30 seconds, start to count when patient's attention is directed elsewhere. It is convenient to do this when the patient thinks you are still counting the pulse. Normal respiratory rate is 14-18 respirations/ minute in adult. For details see respiratory system.

JVP (Jugular venous pulse)

Anatomy

There are two jugular veins-external and internal. External jugular veins drain into the subclavian veins. The internal jugular veins join with the subclavian veins to form the brachiocephalic veins (figure 20). Finally, the left and right brachiocephalic veins join to form the superior vena cava, which delivers deoxygenated blood to the right atrium of the heart.

Internal jugular venous pulsation is examined to see the JVP, because it is direct continuity with the superior vena cava and reflect right atrial pressure more accurately. The external jugular vein is more superficial, prominent and generally easier to see, but as it traverses the deep fascia of the neck, it prone to kinking and remain as obstructed; so, it is not examined to see the JVP.

Jugular venous pulse has two components

1. Jugular venous pressure
2. Jugular venous waveform.

Jugular venous pressure

- ✓ The JVP reflects central venous or right atrial pressure (normally less than 7 mmHg or 9 cm H2O) and indirectly, right ventricular function.
- ✓ The sternal angle is approximately 5 cm above the right atrium, so the normal JVP should be not more than 4 cm above this angle when the patient lies at 45°.
- ✓ If the JVP is low, the patient may have to lie flat for it to be seen; if high, the patient may need to sit upright

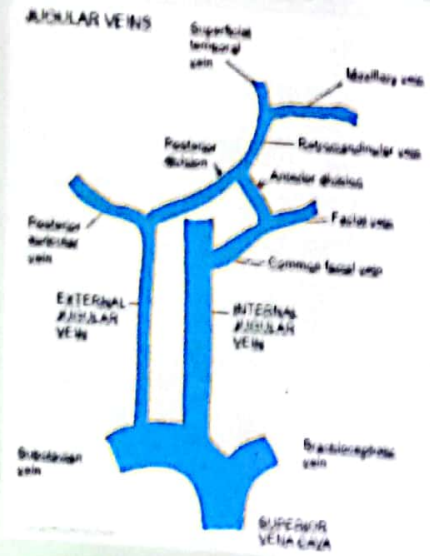

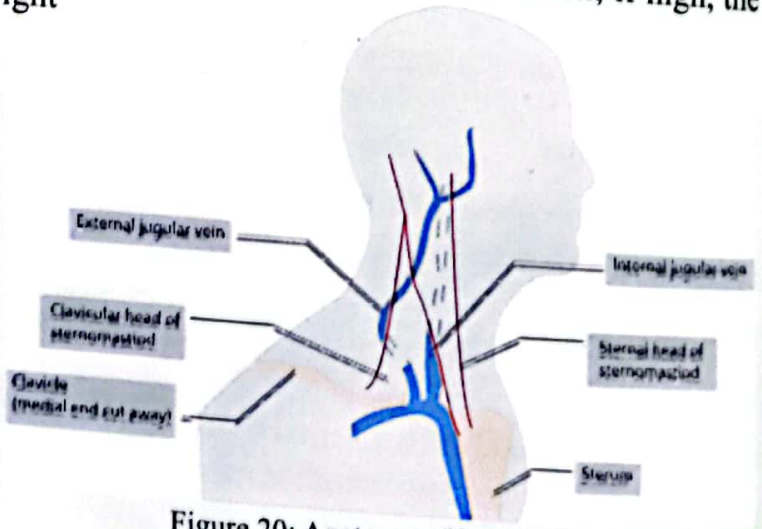

Figure 20: Anatomy of jugular vein

Scanned with CamScanner

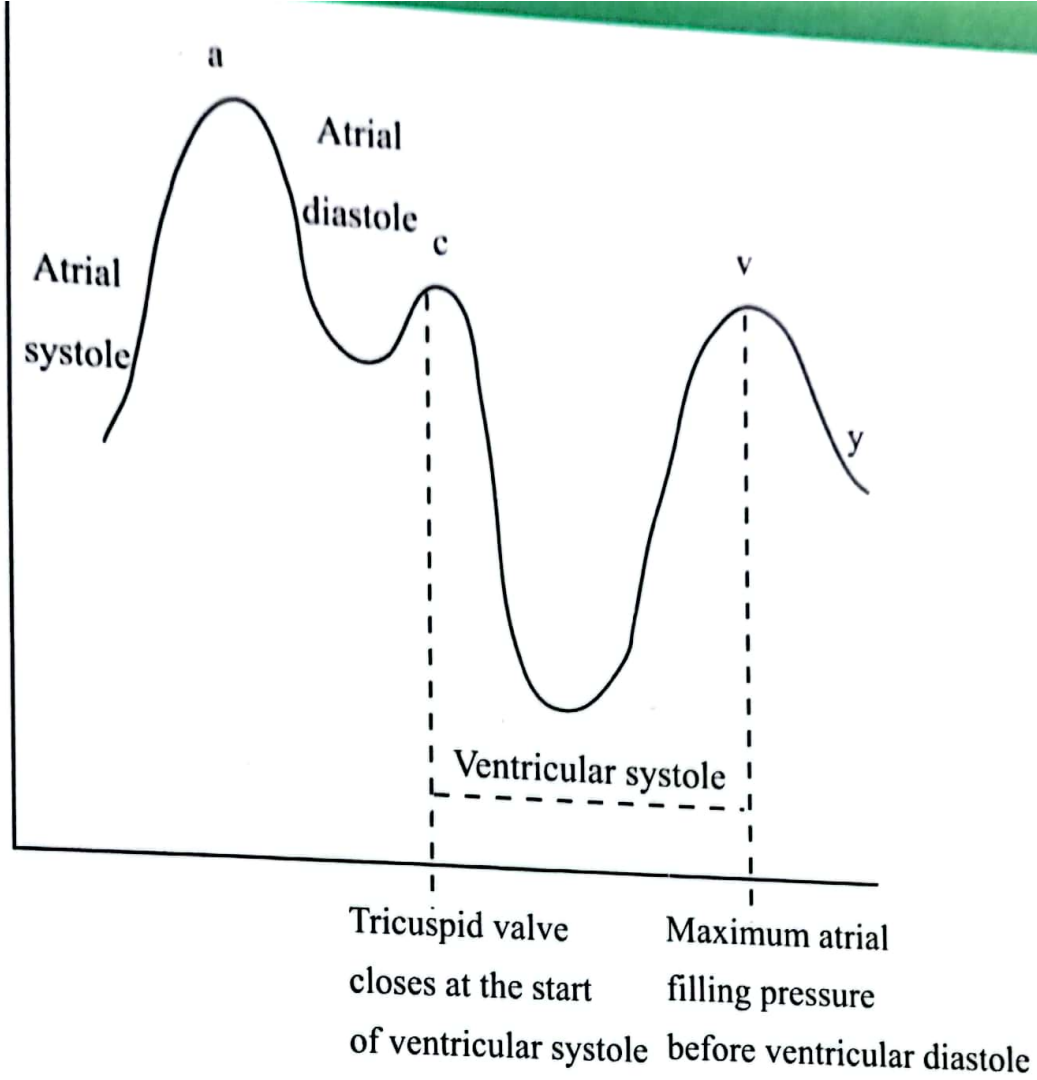

Graph 6 : JVP wave

- The "a" wave corresponds to right atrial contraction.
- The " c " wave corresponds to closure of the tricuspid valve.
- The "x " descent due to downward displacement of the tricuspid valve cusp.
- The " v " wave corresponds to peak pressure in right atrium during ventricular systole.
- The "y" descent corresponds to the rapid emptying of the atrium into the ventricle following the opening of the tricuspid valve.

✓ The absence of 'a' waves may be seen in atrial fibrillation.

✓ Cannon 'a' wave or increased amplitude 'a' wave is associated with AV dissociation (third degree heart block), when the atrium is contracting against a closed tricuspid valve.

✓ Giant 'a' wave occurs in tricuspid stenosis.

✓ Giant 'v' wave occurs in tricuspid regurgitation.

Scanned with CamScanner

Sequence of examination of JVP

1. Greetings and consent.
2. First ask for back rest of the patient (bed which has facility to keep the patient at 45 degree angle with the trunk and lower limbs). (Ask examiner-sir I need back rest).
3. If back rest is not available then take the patient at your arm in 45 degree angle (figure 21).

Figure 21: Examination of JVP Measurement of JVP

4. Turn the patient's face to the left side and look across the neck from the right side of the patient (particularly in the angle between sternal and clavicular head of the sternocleidomastoid muscle then along its anterior border).
5. Identify the jugular venous pulsation and its upper limit; put a scale from the upper limit of the pulsation at right angle of the vein and another scale at right angle of the sternal angle. The distance from the sternal angle to the other scale is JVP in cm of H_2O (figure 21).
6. If jugular venous pulsation is not seen across the neck, then give sustained pressure over the upper abdomen for 10 seconds (abdomino-jugular reflux), this will increase venous return to the right atrium and will raise JVP. If still no venous pulsation is seen then JVP is not raised.
7. Thank the patient.

Differences between carotid and jugular pulsation?

Carotid pulsation	Jugular venous pulsation
Rapid outward movement.	Rapid inward movement.
One peak per heartbeat.	Two peaks per heartbeat (in sinus rhythm).
Palpable(can be seen and feel)	Not palpable (can be seen only).
Pulsation unaffected by pressure at the root of the neck.	Pulsation diminished by pressure at the root of the neck.
Independent of respiration.	Height of pulsation varies with respiration.
Independent of position of patient.	Varies with position of patient.
Independent of abdominal pressure.	Increase with abdominal pressure.

Scanned with CamScanner

Causes of raised JVP

1. Congestive cardiac failure
2. Corpulmonale
3. Pulmonary embolism
4. Right ventricular infarction
5. Tricuspid valve disease
6. Cardiac tamponade
7. Constrictive pericarditis
8. Hypertrophic/restrictive cardiomyopathy
9. Superior vena caval obstruction (non-pulsatile engorgement of jugular vein)
10. Iatrogenic fluid overload, particularly in surgical and renal patients

Thyroid gland

Examination of thyroid gland

1. Greetings and consent.
2. Patient should be in sitting position and neck should be exposed.
3. Inspection- first stand in front of the patient then sides of the patient and inspect the neck after asking the patient to swallow.
4. Palpation-from behind place fingers of the both hands on two sides of the neck (at the level of the both lobe of the thyroid gland) and ask the patient to swallow. Feel for the thyroid gland, any swelling of the thyroid gland. (If thyroid gland is enlarged then look for- surface, consistency, tenderness, margin and lower limit) (Figure 22).

Figure 22: Palpation of the thyroid gland.

5. Percussion-to see the retrosternal extension (percuss over the upper part of the sternum). If retrosternal extension is present then percussion will be dull.
6. Auscultation-for bruit. Ask the patient to hold his breath and auscult over the thyroid gland for thyroid bruit.
7. Thank the patient.

Abnormal findings of the thyroid gland examination

1. Diffuse, soft goitre with bruit- Graves' disease.
2. Diffuse, firm goitre- Hashimoto's thyroiditis.
3. Diffuse, tender goitre-Subacute thyroiditis.
4. Solitary nodule-Adenoma, cyst, carcinoma.

Scanned with CamScanner

5. Enlarge thyroid gland with cervical lymphadenopathy-carcinoma of the thyroid gland.

When a thyroid gland will be palpable then thyroid status should be assessed. Normal thyroid status is called euthyroid, but it may be hyperthyroid or hypothyroid.

What are the points to be noted to see the thyroid status?

To assess the thyroid status following history and clinical examination should be done

History

1) Increase appetite
2) Weight loss/gain
3) Sleeplessness/somnolence
4) Heat/cold intolerance
5) Excessive sweating
6) History of diarrhoea or constipation
7) Loss of memory
8) Hoarseness of voice
9) Menstrual abnormalities e.g. menorrhagia

Examination

1. Pulse
2. Blood pressure
3. Tremor in outstretched hands
4. Eye-exopthalmus, lid retraction, lid lag
5. Edema
6. Deep jerks

Hyperthyroidism

History

1. Increase appetite
2. Weight loss
3. Sleeplessness
4. Heat intolerance
5. Excessive sweating
6. History of diarrhoea (hyperdefecation)

Examination

1. Pulse-tachycardia
2. Blood pressure- may be elevated
3. Tremorin outstretched hands-present
4. Eye-exopthalmus, lid retraction and lid lag present.
5. Deep jerks-exaggerated

Hypothyroidism

History

1) Weight gain
2) Somnolence (increase sleep)
3) Cold intolerance
4) Loss of memory
5) History of constipation
6) Hoarseness of voice
7) Menstrual abnormalities e.g. menorrhagia

Examination

1. Pulse-bradycardia
2. Blood pressure- may be elevated
3. Skin-dry, rough
4. Eye- periorbital oedema
5. Edema-non pitting
6. Slow and delayed relaxation of ankle jerk.

Scanned with CamScanner

Lymph node

Group of accessible lymph node in our body

1. Cervical lymph nodes
2. Supraclavicular lymph nodes
3. Axillary lymph nodes
4. Epitrochlear lymph nodes
5. Inguinal lymph nodes
6. Popliteal lymph nodes

Cervical lymph nodes up to 2 cm, axillary nodes up to 1 cm and inguinal nodes up to 1.5 cm in diameter are usually normal without any significant cause.

Figure 23: Palpation of the cervical (right) and axillary lymph nodes (left).

Points to be noted during examination of lymph node

1. Sites of enlargement of the lymph nodes
2. Diameter-measure the length and breadth of the largest and smallest lymph node.
3. Consistency- may be rubbery, firm or hard. Firm consistency occurs in viral infection, leukaemia; rubbery consistency occurs in lymphoma. Hard lymph nodes usually indicate metastasis of malignancy.
4. Tenderness- tender lymph node indicates inflammation. (except TB and HIV infection)
5. Temperature-raised temperature over the lymph node indicates underlying inflammatory etiology.
6. Discrete or matted- in lymphoma lymph nodes are discrete; in tubercular lymphadenitis lymph nodes are matted.
7. Fixity- lymph nodes fixed with the underlying and overlying structure indicates metastasis of malignancy.
8. Discharging sinus- present in tubercular lymphadenitis.

Scanned with CamScanner

Lymphadenopathy: It refers to nodes that are abnormal in either size, consistency or number. There are 2 types of lymphadenopathy.

Localized lymphadenopathy

If lymph nodes are enlarged in only one area it is called localized lymphadenopathy. This is usually due to localized infection. Example-enlarge right sided inguinal lymphadenopathy is due to infection in right lower limb. Submental and submandibular lymphadenopathy is usually due to oral cavity infection.

Generalized lymphadenopathy

Generalised lymphadenopathy can be defined as enlargement of more than two non-contiguous lymph node groups. Example- lymphoma, leukaemia etc, where lymphadenopathy occurs in cervical, axillary, inguinal region.

What are the causes of generalized lymphadenopathy?

A) Infection

1. Viral : Infectious mononucleosis (Epstein bar virus)
2. Bacterial : Tuberculosis, secondary syphilis
3. Protozoal : Toxoplasmosis
4. Fungal : Histoplasmosis

B) Malignancy

1. Acute leukemia
2. Lymphoma
3. Metastatic carcinoma

C) Immunological

1. Systemic lupus erythematosus
2. Felty's syndrome
3. Still's disease
4. Drug hypersensitivity as hydralazine, allopurinol

D) Miscellaneous

1. Sarcoidosis
2. Amyloidosis
3. Lipid storage disease

What are the common causes of generalized lymphadenopathy?

1. Viral infection-Epstein bar virus
2. Lymphoma
3. Acute leukemia
4. Tuberculosis (tubercular lymphadenitis)
5. Metastatic carcinoma

Scanned with CamScanner

Bony tenderness

In acute leukaemia abnormal proliferation of WBC results in increased number of immature WBC in bonemarrow, which occupy all the spaces of bone marrow and due to over populated bonemarrow stretching of the periosteum of the bone occurs, that give rise to bony tenderness when provide gentle pressure. As manubrium sterni is a flat bone (in adult bone marrow usually remain in ends of the long bone and flat bones) and more superficial, so here bony tenderness commonly examined. But this is not a confirmatory test. This test result is subjective.

Steps of examination of bony tenderness

1. Greetings and consent.
2. Patient should be in lying position.
3. Give light pressure over the manubrium sterni with the right thumb and look over the patient's face. If bony tenderness is present patient will wince due to pain (figure 24).
4. Thank the patient.

Figure 24: Examination of bony tenderness.

Causes of bony tenderness

1. Acute leukaemia
2. Multiple myeloma
3. Secondary metastasis of bone

Gynaecomastia

Gynaecomastia is the presence of glandular breast tissue in male. It refers to smooth, firm, mobile, often tender, disc of breast tissue under the areola in the male (figure 25). In adult, gynaecomastia usually results from-

1. Excessive oestrogen stimulation
2. Reduction in circulating androgen
3. Antagonism of androgen action
4. Androgen insensitivity

Figure 25: Gynaecomastia

Causes of gynaecomastia

1. Idiopathic
2. Physiological-in the newborn baby (due to maternal and placental oestrogens), in pubertal boys (in whom oestradiol concentrations reach adult levels before testosterone) and in elderly men (due to decreasing testosterone concentrations)

Scanned with CamScanner

3. Drug-induced
   - ✓ Cimetidine
   - ✓ Digoxin
   - ✓ Anti-androgens (spironolactone, cyproterone acetate)
   - ✓ Some exogenous anabolic steroids (diethylstilbestrol)
4. Hypogonadism
5. Androgen resistance syndrome
6. Oestrogen excess
   - ✓ Liver failure/CLD (impaired oestrogen metabolism).
   - ✓ Oestrogen-secreting tumour (for example, tumour of testis).
   - ✓ HCG-secreting tumour (for example, tumour of testis or lung).

Skin condition

Any pigmentation or any skin changes should be noted.

Macule – A macule is a change in surface color, without elevation or depression and therefore, non-palpable, well or ill-defined (figure 26).

Patches-areas of discoloration that are larger than 1 cm are referred to as patches. Tinea versicolor is the example of macular lesion and patche.

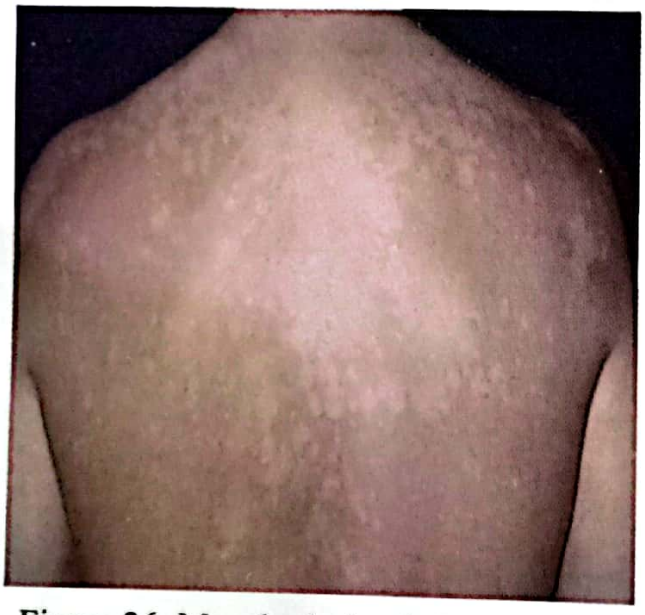

Figure 26: Macular lesion in T. versicolor

Figure 27: Papular lesion in chicken pox

Papule – A papule is a circumscribed, solid elevation of skin with no visible fluid, varying in size from a pinhead to less than 10 mm in diameter at the widest point (figure 27). Example- chicken pox.

Plaque – A plaque has been described as a broad papule, or confluence of papules equal to or greater than 1 cm (10mm) (figure 28). Commonest cause of plaque is psoariasis.

Scanned with CamScanner

Figure 28: Erythematous plaque in psoariasis.

Petechiae is a small (1-2mm) red or purple spot on the body, caused by a minor hemorrhage (broken capillary blood vessels).

Purpura is the appearance of red or purple discolorations on the skin that do not blanch on applying pressure (Figure 30). Causes- platelet disorders (thrombocytopenic purpura) and nonthrombocytopenic purpura. At a glance- petechia (less than 3 mm, Figure 29), purpura (3 mm to 1 cm) or ecchymosis (1 to 3 cm) (Figure 31).

Figure 29: Petechia

Figure 30: Purpura

Figure 31: Ecchymosis

Blister-describe as small bubble on the skin filled with fluid. Vesicular blister occurs in herpes zoster (figure 32).

Figure 32: Blister in H. zoster

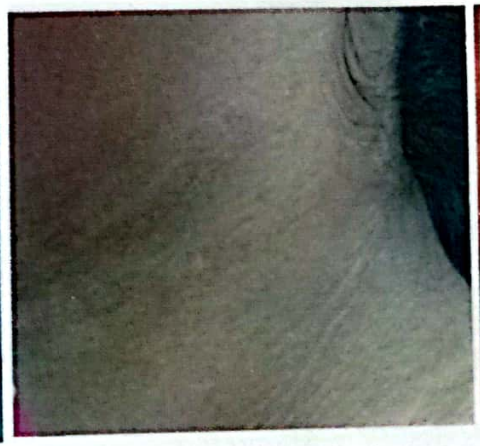

Figure 33: Acanthosis nigricans

Figure 34: Erythema ab igne

Scanned with CamScanner

Brown or dark brown pigmentation: In addison's disease brown or dark brown pigmentation affecting exposed parts such as axillae, palmar creases, lips and oral cavity.

Erythema ab igne- reticular pattern of pigmentation occurs due to repeated exposure of heat (figure 34) e.g. hypothyroidism (to protect from cold), chronic pancreatitis (to relieve from abdominal pain hot water bottle applied over the abdomen).

Acathosis nigricans- is a brownish, velvety thickening of the axillae, groins and sides of the neck (figure 33). In the middle age this usually indicates internal malignancy, but may also occur in obesity.

Erythema nodosum- is a condition in which tender, painful, red nodules appear, typically on the shin of the tibia (figure 34). Causes are-

1. Bacteria e.g. Streptococci, Mycobacteria, Brucella, Mycoplasma, Rickettsia, Chlamydia etc.
2. Viral infection
3. Fungal infection
4. Drugs - e.g. Sulphonamides, oral contraceptives.
5. Systemic diseases- e.g. Sarcoidosis, ulcerative colitis and Crohn's disease.

Figure 34: Erythema nodosum

Xanthoma- are yellow or orange papules or nodules in the skin caused by dermal aggregations of lipid loaded cells. This occurs in familial hypercholesterolaemia.

Hair distribution

Normal pattern of hair distribution present or not. Beard, axillary and pubic hair loss occur in hypogonadism. Decrease frequency of shaving may be the early indicator of hair loss in adult male.

Tremor

Resting tremor occur in parkinsonism, action tremor in cerebeller lesion. Tremor present in out stretched hand in thyrotoxicosis.

Others

Any abnormal findings to be noted e.g. IV canula, catheter, AV fistula, NG tube etc.

Scanned with CamScanner

Presentation: (normal findings of general physical examination)

On general physical examination patient is ill looking, co-operative, body build, nutritional status average, decubitus on choice, not anaemic, not ecteric, clubbing, koilonychia, leukonychia, edema, dehydration are absent. Pulse 80 beats/minute, regular; blood pressure 120/80 mm of Hg, temperature 98F, respiratory rate 14 breaths/minute, JVP not raised, thyroid gland is not enlarged and lymph nodes are not palpable in all the accessible areas, bony tenderness, gynaecomastia absent, skin condition and hair distribution are normal.

Presentation: (abnormal findings of general physical examination suppose- patient have anaemia, jaundice, edema, palpable lymph nodes).

On general physical examination patient is ill looking, co-operative, body build, nutritional status average, decubitus on choice, moderatly anaemic, mildly ecteric, clubbing, koilonychia, leukonychia are absent, edema present, dehydration absent. Pulse 80 beats/minute, regular, blood pressure 120/80 mm of Hg, temperature 98F, respiratory rate 14 breaths/minute, JVP not raised, thyroid gland is not enlarged and lymph nodes are palpable in the cervical regions, these are variable in size, largest one is 4×3 cm in diameter, firm in consistency, non-tender, discrete, overlying temperature is normal, not fixed with the underlying structure or overlying skin and there is no discharging sinus, bony tenderness, gynaecomastia absent, skin condition and hair distribution is normal.

Scanned with CamScanner

The respiratory system is divided into two main components-upper respiratory tract and lower respiratory tract. Upper respiratory tract composed of the nose, nostril, nasal cavity, nasopharynx, oropharynx and the larynx; lower respiratory tract composed of the trachea, the lungs, and all segments of the bronchial tree (including the alveoli). The organs of the lower respiratory tract are located inside the chest cavity. Right lung has 3 lobes upper, middle and lower, separated by oblique fissure and horizontal fissure, where as the left lung has 2 lobes upper and lower separated by oblique fissure. Each lobe has its own pleural coverings, which limit spreading of infection from one lobe to the other. Radiologically each lung is divided into 3 zones - upper, middle and lower. The lung zones do not equate to the lung lobes. For example the lower zone on the right consists of middle and lower lobes. Pleura, the coverings of the lungs has a visceral component that covers the lungs and parietal pleura which covers the inner surface of the chest wall. The space between the visceral and parietal pleura is the pleural cavity. In many diseases this pleural cavity may be filled with fluid (pleural effusion), air (pneumothorax), blood (haemothorax), pus (pyothorax) etc.

Presenting complaints of the respiratory system

1. Breathlessness
2. Cough
3. Haemoptysis
4. Chest pain

Breathlessness

Breathlessness is an abnormal awareness of breathing which occur either at rest or in unexpectedly at low level of exertion. Dyspnoea, shortness of breathing and breathlessness are synonymous. Two types of dyspnoea (acute and chronic) are commonly seen. Acute dyspnoea is defined as dyspnoea arising over the course of 24 to 48 hours, example- dyspnoea in acute LVF, tension pneumothorax etc. Chronic dyspnoea is defined as dyspnoea lasting more than one month, example- dyspnoea of COPD, persistent asthma etc.

Causes of breathlessness (commonly found in Medicine ward) (What are the common causes of breathlessness?)

1. COPD (Acute exacerbation)
2. Asthma (Acute exacerbation or persistent asthma)
3. Heart failure
4. Huge pleural effusion
5. Pneumothorax
6. Anxiety neurosis
7. Pneumonia

Causes of acute dyspnoea

A. CVS causes

a) Acute pulmonary edema due to any cause (commonly acute left ventricular failure due to MI).

Scanned with CamScanner

B. Respiratory causes

a) Acute exacerbation of asthma
b) Acute exacerbation of COPD
c) Pneumothorax (p articularly tension pneumothorax)
d) Pneumonia
e) Psychogenic hyperventilation
f) Pulmonary embolism

] Common causes

g) ARDS (acute respiratory distress syndrome)
h) Inhaled foreign body
i) Laryngeal edema (e.g. anaphylaxis)

C. Others

a) Diabetic ketoacidosis, uraemia etc.

Exertional dyspnoea: Dyspnoea occurring on effort or exertion and relieves on taking rest is called exertional dyspnoea. Exertional dyspnoea is usually chronic.

Causes of exertional dyspnoea:

A) Cardiovascular causes

a) Chronic CCF (congestive cardiac failure)
b) Myocardial ischaemia (stable angina)

B) Respiratory causes

a) COPD (chronic obstructive pulmonary disease)
b) Persistent asthma
c) Huge pleural effusion
d) Interstitial lung diseases e.g. fibrosing alveolitis, pneumoconiosis etc.
e) Chronic pulmonary thromboembolism
f) Bronchial carcinoma (exertional dysponea due to pleural effusion)

C) Others

a) Severe anaemia
b) Obesity

Common causes of exertional dyspnoea (What are the common causes of exertional dyspnoea?)

1. COPD (practically COPD but during exam first stable angina should tell)
2. Myocardial ischemia (stable angina)
3. Persistent asthma
4. Chronic congestive cardiac failure
5. Huge pleural effusion

Scanned with CamScanner

Orthopnoea means difficulty in breathing while the patient is lying down and relieved by sitting or standing position. Orthopnea usually occurs in patient with heart failure, because in lying position there is increase in left atrial and pulmonary capillary pressure and ultimately pulmonary congestion and breathlessness. In advance stage of heart failure patient may choose to sleep in a chair.

Paroxysmal nocturnal dyspnoea (PND)

Sudden onset of breathlessness when the patient sleeps at night, which awakes the patient from sleep is called paroxysmal nocturnal dyspnoea. This symptom is usually corrected by standing upright, which allows gravitational pooling of blood to lower the left atrial and pulmonary capillary pressure. The patient often feeling the need to obtain air at an open window. Paroxysmal nocturnal dyspnoea differs from orthopnea that orthopnea occurs every time when the patient will be in lying condition but paroxysmal nocturnal dyspnoea occurs paroxysmally.

MRC dyspnoea score:

Grade	Impact
1	Not troubled by breathlessness except on vigorous exertion.
2	Shortness of breath when hurrying or walking up inclines.
3	Walks slower than contemporaries because of breathlessness or has to stop for breath when walking at own pace.
4	Stops for breath after walking about 100 metres or stops after a few minutes' walking on the level.
5	Too breathless to leave the house or breathless on dressing or undressing.

Cough-cough is a forced expulsive maneuver, usually against a closed glottis and which is associated with a characteristic sound. It is caused by stimulation of sensory nerves in the mucosa of the pharynx, larynx, trachea and bronchi. The function of cough is to remove secretions or particles, thus cough is a protective phenomenon.

Acute cough is defined as lasting less than 3 weeks. Causes of acute cough are-

1. Viral respiratory tract infection
2. Pharyngitis
3. Bacterial infection (acute bronchitis)
4. Pneumonia
5. Inhaled foreign body
6. Inhalation of irritant dusts/fumes
7. Acute extrinsic allergic alveolitis

Chronic cough which persists for more than 8 weeks. Causes are-

1. Asthma
2. Rhinitis/sinusitis
3. Bronchiectasis
4. Cigarette smoking/smoker's cough
5. Pulmonary tuberculosis
6. Interstitial lung disease (ILD)
7. Bronchial carcinoma
8. GERD (gastroesophageal reflux disease)
9. Postviral bronchial hyper-reactivity
10. Drugs especially ACE inhibitors
11. Irritant dusts/fumes

What is dry cough?

A dry cough refers to a cough that does not produce sputum. Causes of dry cough are-

1. Asthma (chronic dry cough)

Scanned with CamScanner

2. Pharyngitis (with or without tonsilitis)
3. Following common cold (acute dry cough)
4. Inhalation of dust, smoke or powder
5. Viral laryngitis
5. Pneumonia (initially dry cough, later productive cough)

What is productive cough?

A productive cough refers to a cough that produces sputum. Causes of productive cough are

1. Pneumonia
2. Pulmonary tuberculosis
3. Bronchiectasis
4. Lung abscess
5. COPD (chronic bronchitis variety)
6. Empyema thoracics
7. Bronchial carcinoma
8. Pulmonary edema
9. Asthma with respiratory tract infection

What are the causes of massive sputum production?

1. Bronchiectasis
2. Lung abscess
3. Empyema thoracics

Causes of foul smelling sputum

1. Lung abscess
2. Bronchiectasis
3. Empyema thoracics

How colour of sputum helps in diagnosis of diseases?

1. Mucoid sputum- occurs in chronic bronchitis/COPD (if there is no active infection).
2. Yellow sputum- occurs in acute lower respiratory tract infection (live neutrophils) and in asthma (eosinophils).
3. Purulent sputum /green sputum (dead neutrophils) indicates chronic infection in COPD or bronchiectasis. Green colour is due to lysed neutrophils which release the green-pigmented enzyme, verdoperoxidase.
4. Rusty sputum- in early pneumococcal pneumonia sputum may be rusty, red colour, as pneumonic inflammation causes lysis of red cells.
5. Serous/frothy/pink-occurs in pulmonary edema.
6. Blood stained-occurs in bronchial carcinoma, pulmonary tuberculosis, bronchiectasis, pulmonary embolism.

Scanned with CamScanner

'Red flag' symptoms associated with cough that should prompt a chest X-ray:

1. Haemoptysis
2. Breathlessness
3. Fever
4. Chest pain
5. Weight loss

Haemoptysis- is the coughing of blood originating from the respiratory tract below the level of the larynx.

Causes of haemoptysis

A) Bronchial disease

1) Bronchial carcinoma
2) Bronchiectasis
3) Acute bronchitis
4) Bronchial adenoma
5) Foreign body

B) Parenchymal disease

1. Pulmonary tuberculosis
2. Suppurative pneumonia
3. Lung abscess
4. Parasites (e.g. hydatid disease, flukes)
5. Trauma
6. Actinomycosis
7. Mycetoma

C) Lung vascular disease

1. Pulmonary infarction
2. Goodpasture's syndrome
3. Polyarteritis nodosa
4. Idiopathic pulmonary haemosiderosis

D) Cardiovascular disease

1. Mitral stenosis with pulmonary hypertension
2. Acute left ventricular failure
3. Aortic aneurysm

Scanned with CamScanner

E) Blood disorders

1. Leukaemia
2. Aplastic anaemia
3. Anticoagulant therapy

Common causes of haemoptysis

1. Bronchial carcinoma
2. Pulmonary tuberculosis
3. Bronchiectasis
4. Acute bronchitis
5. Mitral stenosis with pulmonary hypertension

What is massive haemoptysis?

Precise threshold that constitute massive hemoptysis are controversial. In clinical practice, massive hemoptysis is defined as either 500 ml or more of expectorated blood over a 24 hour period or bleeding at a rate of 100 ml/hour or more, regardless of whether abnormal gas exchange or hemodynamic instability exists.

Causes of massive haemoptysis are:

1. Bronchiectasis
2. Bronchial adenoma
3. Aspergillosis
4. Pulmonary tuberculosis
5. Mitral stenosis with pulmonary hypertension

How will you differentiate haemoptysis from haematemesis?

Haemoptysis	Haematemesis
1. Coughing out of blood	1. Vomiting out of blood
2. Bright red	2. Dark-red/coffee-colored blood
3. Mixed with mucous	3. Mixed with food
4. Alkaline pH	4. Acidic pH
5. Chest pain, fever, cough usually associated symptoms	5. History of abdominal pain, nausea, melaena, history of NSAID use usually present.

Wheezing- Wheezing is a high-pitched whistling sound during breathing due to narrowing of the small airways. Wheezing usually occurs in asthma exacerbation. Ask whether the patient hear any noise coming from chest. Sometimes bed partner can hear the noises. Wheeze occurs when asthma worses.

Scanned with CamScanner

Stridor- stridor is a physical sign which is produced by narrowed or obstructed large airway. It can be inspiratory, expiratory or biphasic. Inspiratory stridor is common. Causes of stridor is laryngeal tumour, laryngeal edema etc.

Hyperventilation- hyperventilation is rapid or deep breathing that can occur in anxiety or panic attack.

Apnoea-temporary cessation of breathing is called apnoea.

Chest pain

Causes

A) Cardiac

1. Myocardial ischaemia (angina)
2. MI (myocardial infarction)
3. Myocarditis
4. Pericarditis
5. Mitral valve prolapse

B) Lungs/pleura

1. Pneumonia
2. Brochial carcinoma
3. Pneumothorax
4. Tuberculosis
5. Pulmonary embolism
6. Tracheitis
7. Bronchospasm
8. Pulmonary infarction
9. Connective tissue disorders (rare)

C) Musculoskeletal

1. Musculoskeletal chest pain due to trauma, RTA etc
2. Osteoarthritis
3. Rib fracture/injury
4. Costochondritis (Tietze's syndrome)
5. Intercostal muscle injury
6. Epidemic myalgia (Bornholm disease)

Scanned with CamScanner

D) Oesophageal

1. GERD (Gastroesophageal reflux disease)
2. Oesophagitis
3. Oesophageal spasm
4. Mallory-Weiss syndrome

E) Aortic

1. Aortic dissection
2. Aortic aneurysm

F) Neurological

1. Prolapsed intervertebral disc
2. Herpes zoster
3. Thoracic outlet syndrome

G) Anxiety or emotion

Figure 1: Examination of nasal cavity

Characteristics of pleural pain

Pleural pain is localized, sharp, aggravated on cough, deep breathing and movements.

Clinical examination of the respiratory system

Examination of respiratory system consists of

1. Upper respiratory tract examination and
2. Chest examination

Examination of upper respiratory tract includes examination of the following:

1. Nose and nasal cavity
2. Nasal septum
3. Turbinate
4. Nasal polyp
5. Oro-pharynx

Steps of examination of upper respiratory tract

1. Greetings and consent.
2. Patient should be in sitting position.
3. Inspection of the both nasal cavity by torch light (figure 1)-look for DNS (deviated nasal septum), nasal polyp, hypertrophied turbinate etc.

Scanned with CamScanner

4. Ask the patient to open the mouth widely and inspect the oral cavity with torch light-look for tonsillar enlargement, oro-pharyngeal congestion etc.

5. Thank the patient.

Importance of examination of upper respiratory tract

One of the important causes of cough is pharyngitis, which is easily missed during clinical examination, besides tonsillar enlargement, DNS, nasal polyp, rhinosporiodiosis etc usually diagnose by examining upper respiratory tract.

Examination of the chest includes

1. Inspection
2. Palpation
3. Percussion and
4. Auscultation

Inspection

Points to be noted during inspection

1. Shape of the chest
2. Respiratory movement
3. Respiratory rate and rhythm
4. Deformity
5. Intercostal spaces
6. Intercostal recession
7. Supra sternal recession
8. Use of accessory muscle of respiration
9. Engorged vein
10. Any swelling
11. Scar mark
12. Others-intercostal drainage tube (given in pneumothorax, hydropneumothorax or empyema thoracics), gauze piece covered by micropore (indicating pleural fluid aspiration) should be mentioned.

Shape of the chest

Normally transverse diameter of the chest is more than the anterior-posterior diameter (elliptical on cross section). Barrel shape chest is called when anterior-posterior diameter is more than that of the transverse diameter. Barrel shape chest occurs in advanced stage of COPD (emphysema). Any flattening of the chest (occurs in fibrosis) should be noted during inspection.

Scanned with CamScanner

Interpretation of shape of the chest: (normal finding) shape of the chest is normal. Abnormal findings-chest is barrel shape, there is flattening of the upper part of the chest.

Respiratory movement

Movement of the chest with respiration should be carefully noted during inspection. Normally respiratory movement is symmetrical, abdomino-thoracic in male and thoraco-abdominal in female. Purely abdominal respiration is probably due to bilateral pleurisy and purely thoracic respiration is probably due to generalized peritonitis. Any localized diminishe movement with respiration indicating pathology on that side. Example-reduce movement of the chest on the left side is probably due to left sided pleural effusion, consolidation, pneumothorax etc.

Figure 2: Examination of respiratory rate

Interpretation: Normal findings-respiratory movement is abdomino-thoracic and normal/equal on both sides of the chest. Abnormal findings (as in left sided pleural effusion) - respiratory movement is abdomino-thoracic and reduced in left side.

Respiratory rate and rhythm

Respiratory rate should be counted over 30 seconds, start to count when patient's attention is directed elsewhere. It is convenient to do this when the patient thinks you are still counting the pulse (figure 2). Normal respiratory rate is 14-18 respirations/ minute in adult. Respiratory rhythm is normally regular. Irregular rhythm of respiration is seen in Cheyne-Stokes respiration (which is cyclically increasing rate and depth of breathing, followed by diminishing respiratory effort and rate, ending in a period of apnoea or hypopnoea, the cycle is then being repeated). Cheyne-Stokes respiration occurs in severely ill patient, acute left ventricular failure, diffuse cerebral atherosclerosis, head injury, stroke, narcotic drug poisoning etc. This pattern of respiration occurs due to impaire responsiveness of the respiratory centre to carbon dioxide.

What is tachypnea? What are the causes of tachypnea?

An abnormal increase in respiratory rate of more than 18 breaths/minute is called tachypnea. Causes are

1. Physiological-fever, exercise, anxiety.
2. Breathlessness due to any causes e.g. asthma, COPD, heart failure, pleural effusion etc.

Scanned with CamScanner

Deformity

During inspection any deformity of the chest likes kyphosis (forward bending), scoliosis (lateral bending), pectus excavatum (in which lower end of the sternum is pushed downwards), pectus carinatum (in which lower end of the sternum is pushed upwards) should be noted. Normally there is no deformity of the chest.

Intercostal space and recesssion

Intercostal spaces should be looked carefully in inspection. Normally intercostal spaces are not full. Fullness of the spaces occurs in pleural effusion, pneumot. orax. Intercostal recesssion- a drawing in of the intercostal spaces with inspiration indicate severe upper airways obstruction, as in laryngeal diseases, or tumour of the trachea. In COPD, the lower ribs often move paradoxically inwards on inspiration instead of normal outward movement.

Interpretation: (normal findings) intercostal spaces are normal. Abnormal findings-there is fullness of the lower intercostal spaces of the left side (in mild to morderate left sided pleural effusion/pneumothorax).

Supra sternal recession

Supra sternal recession is indrawing of suprasternal spaces in inspiration. Occurs in exacerbation of COPD, asthma etc.

Interpretation: Normal finding-there is no supra sternal recession. Abnormal finding- Supra sternal recession is present.

Use of accessory muscle of respiration

Among the accessory muscles of respiration sternocleidomastoid becomes prominent in chronic breathlessness due to any cause (figure 3) e.g. COPD, chronic asthma etc.

Interpretation: Normal finding-there is no use of accessory muscles of respiration. Abnormal finding- accessory muscles of respiration are prominent.

Figure 3: Prominence of sternocleidomastoid muscle in a patient with chronic dysponea.

Engorged vein

During inspection any engorged vein should be noted. Engorged vein usually present in the lateral wall of the chest in superior vena caval obstruction (in this case direction of the blood flow is above downwards).

Interpretation: Normal finding-there is no engorgement of the vein; abnormal finding-there is engorgement of the vein of the neck/upper part of the right side of the chest.

Scanned with CamScanner

Any swelling

Any swelling & its location on the chest should be noted.

Interpretation: Normally there is no swelling on the chest. Abnormal finding-there is a swelling over the right side of the chest.

Scar mark

Any scar mark in the chest should be noted, this indicates mark of previous surgery e.g. lobectomy, pleurodectomy, resection of whole lung etc.

Interpretation: Normal finding-there is no scar mark over the chest. Abnormal finding-There is a scar mark on the upper part of the right side of the chest.

Steps of inspection of the chest

1. Greetings and consent.
2. Proper exposure of the chest.

Figure 4 Inspection of the chest from side (right) and foot end of the patient (left).

3. Patient should be in supine position with one pillow under the head.
4. Carefully look over the chest from the side of the patient (figure 4 right).
5. Go to the foot end of the patient and inspect the chest. Look for any depression in any part of the chest (figure 4 left).
6. Ask the patient to seat and look over the back of the chest.
7. Re-clothing and thank the patient.

Presentation of inspection: Normal findings: On inspection shape of the chest is normal, respiratory movement is abdomino-thoracic & normal on both sides, respiratory rate is 14 breaths/minute, regular; there is no deformity, swelling, scar mark, engorged vein, intercostal spaces are normal and there is no suprasternal recession and intercostal indrawing.

Scanned with CamScanner

Palpation-during palpation of the chest following points to be noted:

1. Position of the trachea
2. Position of the apex beat
3. Symmetry of the movement of the chest
4. Vocal fremitus/tactile vocal fremitus
5. Total chest expansibility

Position of the trachea

Normally trachea is centrally placed (slight displacement to the right is common in healthy people).

Causes of tracheal displacement

Displacement to the same side of the lesion

1. Upper lobe or lung collapse
2. Upper lobe fibrosis
3. Pneumonectomy

Displacement to the opposite side of the lesion

1. Massive pleural effusion
2. Tension pneumothorax

Sequence of examination of position of the trachea

1. Greetings and consent.
2. Patient should be in supine position without pillow, looking forwards.
3. Place the index and ring finger of right hand to the right and left sternoclavicular joint respectively (figure 5).
4. Gently place the middle finger in the suprasternal notch and ask the patient to swallow to confirm the position of the trachea, then feel for the space between trachea and sternoclidomastoid muscle. Smaller spaces indicate trachea shifted to that side.
5. Thank the patient.

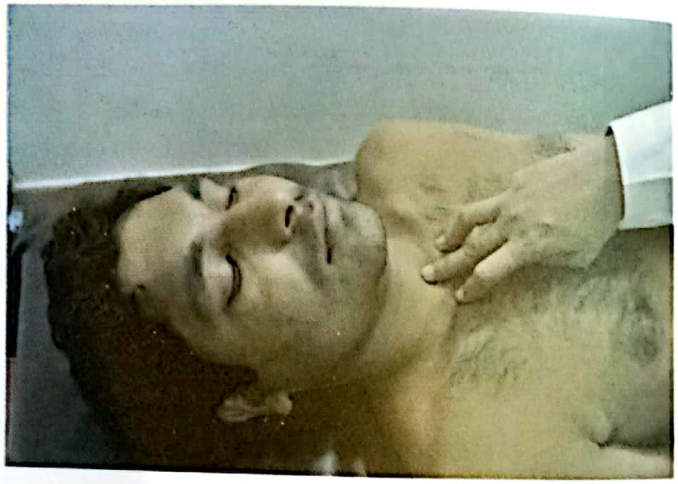

Figure 5: Examination of position of the trachea (Note pillow removed and index and ring finger placed in right and left sternoclavicular joint)

Scanned with CamScanner

Position of the apex beat

Apex beat is the lowermost and outermost point of the definite cardiac pulsation. Normally apex beat is situated in the left 5th intercostal space, 9 cm from midline, just medial to the left midclavicular line.

What are the causes of shifting apex beat?

1. Cardiac enlargement commonly due to valvular heart diseases, heart failure etc
2. Displacement of the apex due to mediastinal shifting, resulting from pleural effusion, pneumothorax, collapse, fibrosis etc.

What are the causes of absent apex beat?

1. Left sided pleural effusion
2. Left sided pneumothorax
3. Pericardial effusion
4. Thick chest wall (obese)
5. Apex beat under the rib etc.

Sequence of examination of position of the apex beat

1. Greetings and consent.
2. Patient should be in supine position, looking forwards and proper exposure of the precordium.
3. Place the right hand over the precordium where fingers should be in the left 4th, 5th & 6th intercostal space (Figure 6).
4. Feel the pulsation by the pulp of the finger.
5. Identify the location of the apex beat by counting the intercostal space from the sternal angle (left 2nd intercostal space) (Figure 7).
6. If apex beat is not palpable then turn the patient to the left side and feel for apex beat. If still not palpable then exercise (walking) the patient and feel for apex beat, if apex beat is not palpable then palpate on the right side (for dextrocardia). If apex beat is not palpable on the right side then declare that apex beat in not palpable/absent.
7. Re-clothing and thank the patient.

Figure 6: Examination of position of the apex beat



Figure 7: Counting of the intercostals space.

Scanned with CamScanner

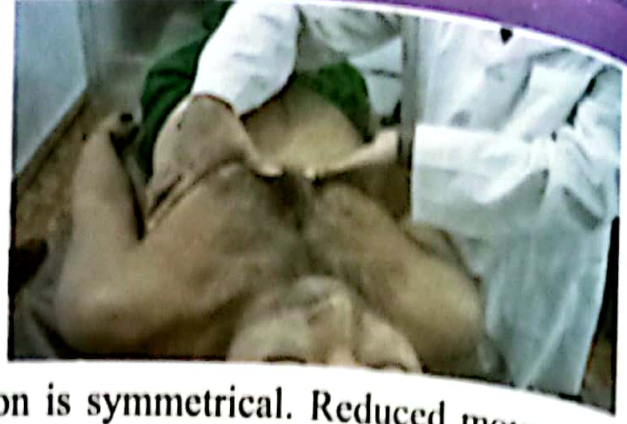

Figure 8: Examination of symmetry of movement of the chest at the level of the nipple. Note the thumbs meet in the midline and not touch the chest so that they can move freely.

Symmetry of the movement of the chest

Normally movement of the chest with respiration is symmetrical. Reduced movement on one side indicates abnormality on that side. For example, in right sided pleural effusion respiratory movement reduces in right side. Bilateral reduction in chest wall movement is common in advance stage of COPD and diffuse pulmonary fibrosis.

During examination from front of the chest, symmetry of the movement should be examined at the level of the clavicle, at the level of the nipple and at the level of the xiphisternum. During examination from back of the chest no need of examination of symmetry of the movement, but when ask to examine only back of the chest then symmetry of the movement should be examined at the level of the superior border of the scapula and at the level of the inferior angle of the scapula.

Sequence of examination of the symmetry of movement of the chest

1. Greetings and consent.
2. Patient should be in lying position, looking forwards and proper exposure of the chest.
3. Place both hands firmly on the chest wall and extend the fingers around the sides of the patient's chest along the intercostal spaces, both thumbs should almost meet in the midline and however not touch the chest (figure 8), so that they move with respiration.
4. Ask the patient to take deep breath. Carefully look for movement of the thumbs. Normally both thumbs should move symmetrically, at least 5 cm apart.
5. The thumb which moves less with respiration indicates chest expansion is reduced on that side.
6. Re-clothing and thank the patient.

Vocal fremitus

Sound produce in the vocal cord when perceive by palm of the hand over the chest is called vocal fremitus. Normally the hand perceive equal intensity sound in both sides of the chest. If the sound perception reduce in one side or increased in any side or part of the chest, probably problem is in that side or area. Vocal fremitus should be examined in the front of the chest along the midclavicular & mid axillary line; and in back of the chest along paravertebral line and dorsal scapular line.

Note: In chest examination, vocal fremitus, percussion, auscultation and vocal resonance should be examined along the midclavicular, mid axillary (front of the chest) and in back of the chest along the paravertebral and dorsal scapular line.

Scanned with CamScanner

During examination of front of the chest start from the supraclavicular fossa and continued downwards up to getting liver dullness (usually right 5th intercostal space) in right side and in left side up to getting cardiac dullness (usually left 5th intercostal space).

During examination along the midaxillary line start from the axilla (4th intercostal space) to 7th intercostal space. In back of the chest first examine 3 sites along the anterior border of the trapezius (for apex of the lung), then along the paravertebral line up to 6th intercostal space (up to inferior angel of the scapula) then along the dorsal scapular line up to 11th intercostal space. Every intercostal space should be examined; otherwise any lesion under that space may be missed.

Sequence of examination of vocal fremitus

1. Greetings and consent.
2. Patient should be in lying position, looking forwards and proper exposure of the chest.
3. Vocal fremitus can be examined by the ulnar border of the right hand or palm of the hand.

Figure 9: Examination of vocal fremitus in back of the chest.

4. Check for vocal fremitus-place the ulnar border of the hand or palm of the hand on the chest and ask the patient to say "99", compare sound perception in both sides. Examine vocal fremitus along the midclavicular, midaxillary, paravertebral and dorsal scapular line.
5. Re-clothing and thank the patient.

Vocal fremitus increases in

1. Consolidation
2. Fibrosis
3. Collapse with patent bronchus

Scanned with CamScanner

Vocal fremitus reduced in

1. Pleural effusion
2. Pneumothorax
3. Mass lesion (bronchial carcinoma)
4. Pleural thickening
5. Emphysema
6. Haemothorax
7. Pyothorax

Total chest expansibility

This should be measured in sitting position of the patient by measuring tape. Normal chest expansibility is 5-8 cm. Total chest expansibility reduce in COPD and ILD.

Figure 10: Examination of total chest expansibility.

Sequence of examination of total chest expansibility

1. Greetings and consent.
2. Patient should be in sitting position and the chest should be properly exposed.
3. Asked the patient to hold his breath after full inspiration then measure the diameter of the chest at the level of the nipple (figure 10).
4. Asked the patient to hold the breath after full expiration then measure the diameter of the chest at the same level.
5. The difference of the diameter of the chest between inspiration and expiration is total chest expansibility.
6. Re-clothing and thank the patient.

Percussion

1. Normal- resonant in both sides.
2. Dull
   a) Woody dull-occurs in consolidation.
   b) Stony dull- occurs in pleural effusion.
   c) Crack pot sound- occurs in lung abscess.
3. Hyperresonant –occurs in pneumothorax, emphysema.

Scanned with CamScanner

How to percuss?

1. Greetings and consent.
2. Position and exposure of the patient-patient should be in lying position when examination from front and patient should be in sitting position when examine from back. Chest should be properly exposed.
3. Palm of the hand should be placed over the chest (area to be purcussed) with the fingers slightly separated and press the middle finger of the left hand firmly against the chest in the intercostal space to be percussed.
4. Strike the centre of the middle phalanx of left middle finger with the tip of your right middle finger, using a loose swinging movement of the wrist and not from the forearm.
5. Remove the percussing finger quickly so that the percussion note generated is not dampened.
6. The same procedure should be repeated in other areas to be purcussed.

Steps of percussion of the chest

1. Greetings and consent.
2. Patient should be in lying position, looking forwards and proper exposure.
3. Start from supraclavicular fossa place the left hand in supraclavicular fossa with ring finger above the clavicle and middle finger below the clavicle (figure 11), intervening the clavicle between ring and middle finger. Then percuss over the ring finger, clavicle (directly) and middle finger, then gradually percuss downwards up to the 5th intercostal space (liver dullness) in right side and up to cardiac dullness in left side.
4. Then start from the 4th intercostal space along the midaxillary line (figure 12). Semiflex the both elbow joints so that there is enough space along the midaxillary line.
5. For examination of back of the chest-ask the patient to be seated and to fold their arms across the front of their chest (right hand in left shoulder and vice versa), thereby moving the scapulae laterally and provide wide area to be examined in back of the chest.

Figure 11: Percussion of the chest along the midclavicular.

Figure 12: Percussion along the midaxillary line (left).

Scanned with CamScanner

6. Percuss the lung apices by placing the palmar surface of left middle finger across the anterior border of the trapezius muscle in 3 sites (figure 13).
7. Percussion should be continued downwards along the paravertebral line first then along dorsal scapular line up to the last intercostal space.
8. Do not percuss near the midline, as this produces a dull note from the solid structures of the thoracic spine and paravertebral musculature. Map out abnormal areas by percussing from resonant to dull.
9. Percuss and compare both sides.
10. Re-clothing and thank the patient.

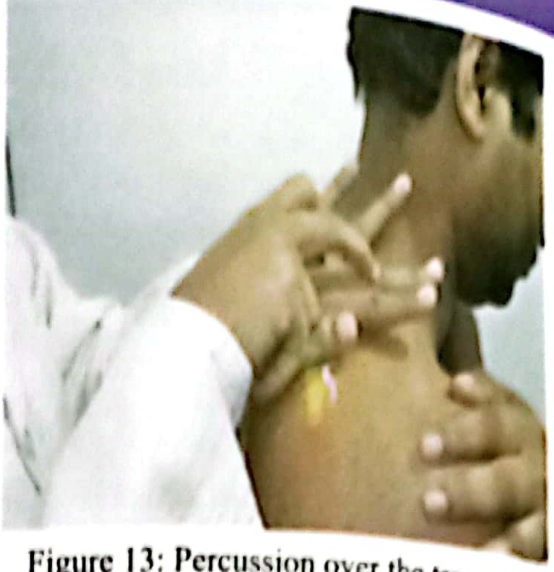

Figure 13: Percussion over the trapezius

Auscultation

Following points to be noted during auscultation of the chest:

1. Breath sound
2. Added sound-rhonchi (wheeze), crepitation, pleural rub.
3. Vocal resonance.

Breath sound-breath sound has two component-inspiration and expiration. Quality and intensity of the breath sound should be assessed.

There are 3 types of quality of the breath sound (figure 14):

1. Vesicular breath sound: In this pattern of respiration inspiration is longer than expiration and there is no gap between inspiration and expiration. Normal breath sound is vesicular.
2. Bronchial breath sound: Here inspiration and expiration is equal and there is a gap between them. Example-consolidation, fibrosis, collapse with patent bronchus, above the pleural effusion and normally present over the trachea.

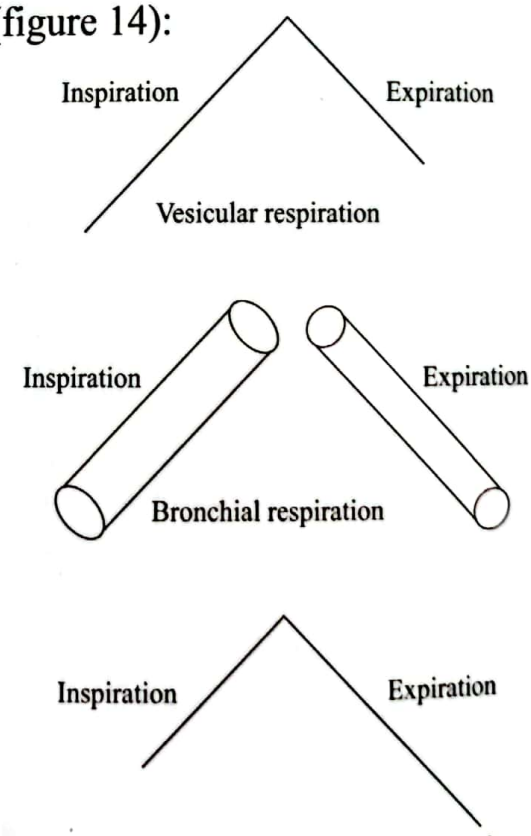

Figure 14: Vesicular with prolonged respiration

Scanned with CamScanner

3. Vesicular with prolonged expiration: Here expiration phase is prolonged than inspiration and there is no gap. Example-COPD.

Breath sound has 3 types of intensity

1. Normal intensity
2. Increased intensity (occurs in consolidation, fibrosis, collapse with patent bronchus).
3. Reduced intensity (occurs in pleural effusion, emphysema, mass lesion etc).

Rhonchi (wheeze)

These are the musical sounds produce due to small airway narrowing. Widespread polyphonic ronchi (wheeze), particularly heard in expiration occur in diffuse airway obstruction like asthma, COPD. A fixed monophonic ronchi (wheeze) can be generated by localized narrowing of a single bronchus, as may occur in the presence of a tumour or foreign body. Ronchi may be inspiratory or expiratory or both and may change its intensity in different positions.

Crepitation

Crepitation or crackles are short, explosive sounds often described as bubbling or clicking. These sounds produce due to sudden opening of the previously closed small airways.

Causes of crepitation

1. Acute LVF (bilateral fine basal crepitation)
2. Bronchiectasis (coarse crepitations)
3. COPD (crepitation at the beginning of the inspiration)
4. Diffuse interstitial fibrosis (crackles are characteristically fine in character and late inspiratory in timing)
5. Pulmonary tuberculosis (crepitation which persists after coughing- posttussive crepitation).

Pleural rub

Pleural rub is creaking or rubbing in character and in some instances can be felt with the palpating hands as well as being audible with the stethoscope. Pleural rub occurs due to pleurisy (pleural inflammation) and usually associates with pleuritic chest pain.

Vocal resonance

Sound produce in the vocal cords when perceive from the chest by stethoscope is called vocal resonance. This should be examined in the same way as vocal fremitus. Here instead of hand stethoscope is used to detect the sound.

Scanned with CamScanner

Steps of auscultation of the chest

1. Greetings and consent.
2. Proper exposure and patient should be in lying position, looking forwards.
3. Ask the patient breathing in and out deeply.
4. Place the bell of the stethoscope (because diaphragm of the stethoscope cannot be placed properly in supraclavicular fossa) (figure 15 right) on the supraclavicular fossa then move downwards along the midclavicular line. Use diaphragm of the stethoscope to auscult other part of the chest. Compare both sides.
5. In the midaxillary line starts from the 4th intercostal space. Compare both sides.

Figure 15: Auscultation of the chest in right supraclavicular fossa and along the left midaxillary line.

6. Ask the patient to seat, start auscultation from the apex of the lung, and compare both sides.
7. Finally examinaing vocal resonance by placing the diaphragm of the stethoscope and asking to pronounce '99'. (Same as vocal fremitus).
8. Re-clothing and thank the patient.

Putting it together

Pleural effusion (suppose right side)

Inspection-on inspection shape of the chest is normal, respiratory movement of the right side is reduced, middle and lower intercostal spaces of the right side are full, respiratory rate is 18 breaths per minute (may be increased in huge effusion), there is no deformity, swelling, engorged vein and scar mark.

Scanned with CamScanner

Palpation- on palpation trachea is shifted to the left side (remember in mild to moderate pleural effusion trachea is usually central, it only shifted in massive pleural effusion), apex beat is in left 5th intercostal space 9 cm from the midline, chest movement is reduced in right side, total chest expansibility is 3 cm, vocal fremitus is reduced on the right side from 3rd intercostal space to downwards along the right midclavicular line, from 5th intercostal space to downwards along the right mid axillary line and 6th intercostal space to downwards along the right paravertebral and dorsal scapular line and vocal fremitus is normal on the other parts of both lungs.

Percussion- percussion note is dull in the above mentioned areas and normal in other sites.

Auscultation-on auscultation breath sound is vesicular but reduced in intensity in the above mentioned areas. There are no rhonchi, crepitation and pleural rub. Vocal resonance reduced in the above mentioned areas.

So, my diagnosis is right sided pleural effusion.

Consolidation (suppose right side)

Inspection-on inspection shape of the chest is normal, respiratory movement of the right side is reduced, intercostal spaces are not full, respiratory rate is 18 breaths per minute (may be increased), there is no deformity, swelling, engorged vein and scar mark.

Palpation- on palpation trachea is central in position, apex beat is in left 5th intercostal space 9 cm from the midline, chest movement is reduced in right side, total chest expansibility is 3 cm, vocal fremitus is increased on the right side from 3rd to 4th intercostal space along the right midclavicular line, from 5th to 7th intercostal space along the right mid axillary line and 6th to 9th intercostal space to downwards along the right paravertebral and dorsal scapular line, and vocal fremitus is normal on the other parts of both lungs.

Percussion-percussion note is dull in the above mentioned areas and normal in other sites.

Auscultation-on auscultation breath sound is bronchial in the above mentioned areas. There is no rhonchi, crepitation and pleural rub. Vocal resonance is increased in the above mentioned areas.

So, my diagnosis is right sided consolidation.

Scanned with CamScanner

Collapse (suppose right side)

Inspection-on inspection shape of the chest is normal, respiratory movement is reduced on the right side, intercostal spaces are not full, respiratory rate is 18 breaths per minute (may be increased), there is no deformity, swelling, engorged vein and scar mark.

Palpation- on palpation trachea is shifted to the right side, apex beat is in left 5th intercostal space 9 cm from midline, chest movement is reduced in right side, total chest expansibility is 3 cm, vocal fremitus is reduced on the right side from supraclavicular fossa to 3rd intercostal space along the right midclavicular line, from 4th intercostal space to 6th intercostal space along the right mid axillary line and 3rd to 6th intercostal space to downwards along the right paravertebral and dorsal scapular line and vocal fremitus is normal on the other sides of the both lungs.

Percussion-percussion note is dull in the above mentioned areas and normal in other sites of the both lungs.

Auscultation-on auscultation breath sound is vesicular but reduced in intensity in the above mentioned areas and normal in other areas. There is no rhonchi, crepitation and pleural rub. Vocal resonance reduced in the above mentioned areas and normal in other areas.

So, my diagnosis is right sided collapse (upper lobe).

Fibrosis (suppose right side)

Inspection-on inspection upper part of the right sided chest is depressed, respiratory movement of the right side is reduced, intercostal spaces are normal, respiratory rate is 18 breaths per minute (may be increased), there is no deformity, swelling, engorged vein and scar mark.

Palpation- on palpation trachea is shifted to the right side, apex beat is in left 5th intercostal space 9 cm from midline, chest movement is reduced in right side, total chest expansibility is 3 cm, vocal fremitus is increased on the right side from the supraclavicular fossa to 3rd intercostal space along the right midclavicular line, from 4th intercostal space to 6th intercostal space along the right mid axillary line and 3rd to 6th intercostal space to downwards along the right paravertebral and dorsal scapular line and vocal fremitus is normal on the other sites of both lungs.

Percussion-percussion note is impaired in the above mentioned areas and normal in other sites.

Auscultation-on auscultation breath sound is bronchial in the above mentioned areas and normal in other areas. Crepitaion present in the above mentioned areas. There is no ronchi and pleural rub. Vocal resonance increased in the above mentioned areas and normal in other areas.

So, my diagnosis is right sided fibrosis.

Scanned with CamScanner

Asthma

Inspection-on inspection shape of the chest is normal, respiratory movement, intercostal spaces are normal, respiratory rate is 18 breaths per minute (may be increased), there is no deformity, swelling, engorged vein, suprasternal reccession and scar mark.

Palpation- on palpation trachea is central in position, apex beat is in left 5th intercostal space 9 cm from the midline, chest movement is symmetrical, total chest expansibility is 3 cm, vocal fremitus is normal in both sides.

Percussion-percussion note is resonant in both sides.

Auscultation-on auscultation breath sound is vesicular with prolonged expiration, polyphonic ronchi is present in all over the both lung fields. There is no crepitation and pleural rub. Vocal resonance is normal in both sides.

So, my diagnosis is asthma.

COPD

Inspection-on inspection shape of the chest is normal (may be barrel shape-in emphysema variety), respiratory movement and intercostal spaces are normal, there is prominence of accessory muscles of respiration, respiratory rate is 18 breaths per minute (may be increased), there is no deformity, swelling, engorged vein, suprasternal reccession and scar mark.

Palpation- on palpation trachea is central in position, apex beat is in left 5th intercostal space 9 cm from the midline, chest movement is symmetrical, total chest expansibility is 3 cm, vocal fremitus is normal in both sides.

Percussion-percussion note is resonant in both sides.

Auscultation-on auscultation breath sound is vesicular with prolonged expiration, there are inspiratory crepitation and expiratory ronchi present in both lungs field, but pleural rub is absent. Vocal resonance is normal in both sides.

So, my diagnosis is COPD.

Note: If the patient having acute exacerbation of asthma or COPD then respiratory rate may be increased. Crepitation may be present in asthma, if there is associated lower respiratory tract infection. In COPD breath sound may be diminished bilaterally if it is emphysema variety.

Scanned with CamScanner

The CVS is composed of 3 major components: the heart, the arteries and the veins. The main function of the CVS system is to deliver O2, nutrients, picking up and distributing metabolic products and carrying away waste for elimination from the body. The heart consists of four chambers-two atria and two ventricles, the two atria separated by interatrial septum and the ventricles separated by interventricular septum. Congenital defect of the interatrial and interventricular septum is known as ASD (atrial septal defect) and VSD (ventricular septal defect) respectively. The right atrium (RA) receives blood from the superior and inferior vena cava and the coronary sinus. The LA receives blood from four pulmonary veins, two from each of the left and right lungs. The ventricles are thick-walled structures, adapted to circulating blood through large vascular beds (arterial tree) under pressure. The atria and ventricles are separated by the annulus fibrosus, which forms the skeleton for the atrioventricular (AV) valves and which electrically insulates the atria from the ventricles. There are four valves in the heart. The two atrioventricular (AV) valves, the mitral valve (bicuspid valve), and the tricuspid valve, which are between the atrium and the ventricles. Two semilunar (SL) valves aortic and pulmonary valve; aortic valve lies in between the left ventricle and aorta and pulmonary valve in between the right ventricle and pulmonary artery.

Heart is supplied by the left main and right coronary artery arise from the left and right coronary sinuse of the aortic root (figure 1). The left main coronary artery divides into the left anterior descending artery (LAD), which runs in the anterior interventricular groove and the left circumflex artery (CX), which runs posteriorly in the atrioventricular groove. The LAD gives branches to supply the anterior part of the septum (septal perforators) and the anterior, lateral and apical walls of the LV. The CX gives marginal branches that supply the lateral, posterior and inferior segments of the LV. The right coronary artery (RCA) runs in the right atrioventricular groove, giving branches that supply the RA, RV and inferoposterior aspects of the LV.

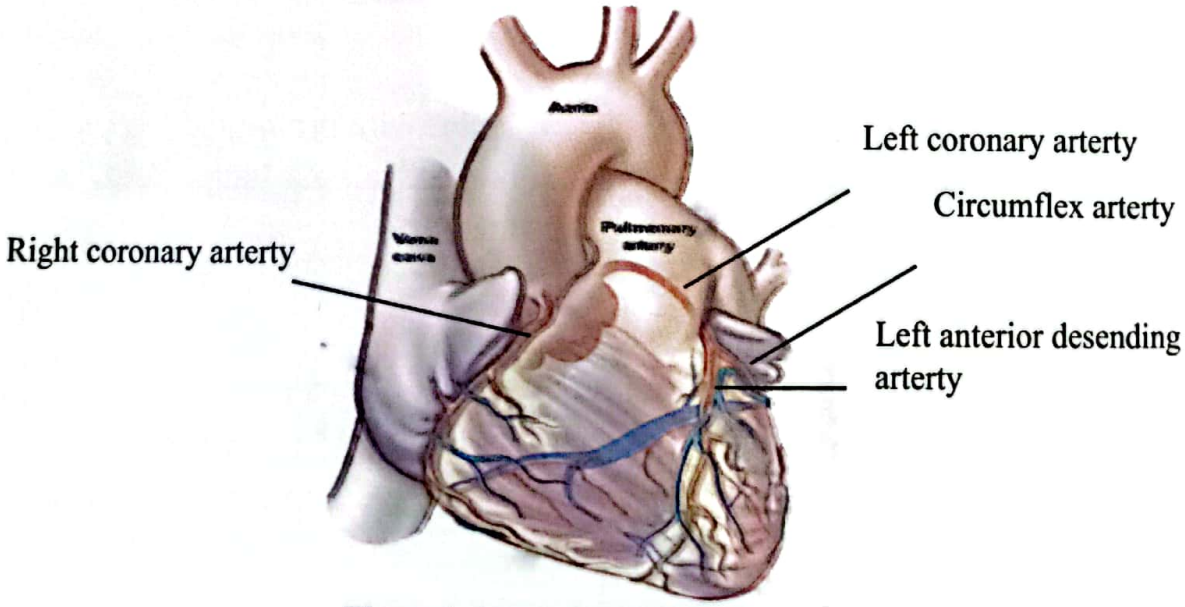

Figure 1: Artery supply of the heart

Scanned with CamScanner

The posterior descending artery runs in the posterior interventricular groove and supplies the inferior part of the interventricular septum. This vessel is a branch of the RCA in approximately 90% of people (dominant right system) and is supplied by the CX in the remainder (dominant left system). The RCA supplies the sinoatrial (SA) node in about 60% of individuals and the AV node in about 90%. Proximal occlusion of the RCA (which occurs in inferior MI) therefore often results in sinus bradycardia and may also cause AV nodal block.

Abrupt occlusions in the RCA, due to coronary thrombosis, result in infarction of the inferior part of the LV and often the RV. Abrupt occlusion of the LAD or CX causes infarction in the corresponding territory of the LV and occlusion of the left main coronary artery is usually fatal.

Conducting system of the heart

The SA node is situated at the junction of the superior vena cava and right atrium. The first electrical event in the cardiac cycle is the initiation of a spontaneous action potential in the SA node after that it stimulate the right atrium and through Bachmann's bundle enter into the left atrium and stimulate the atrial muscles, at the same time the impulse reach AV node via anterior, middle and posterior internodal tract. From the AV node the impulse travel to the ventricular muscles via bundle of His and its branches (purkinje fibres). The whole pathway (from SA node to the purkinje fibres) is conducting system of the heart (figure 2).

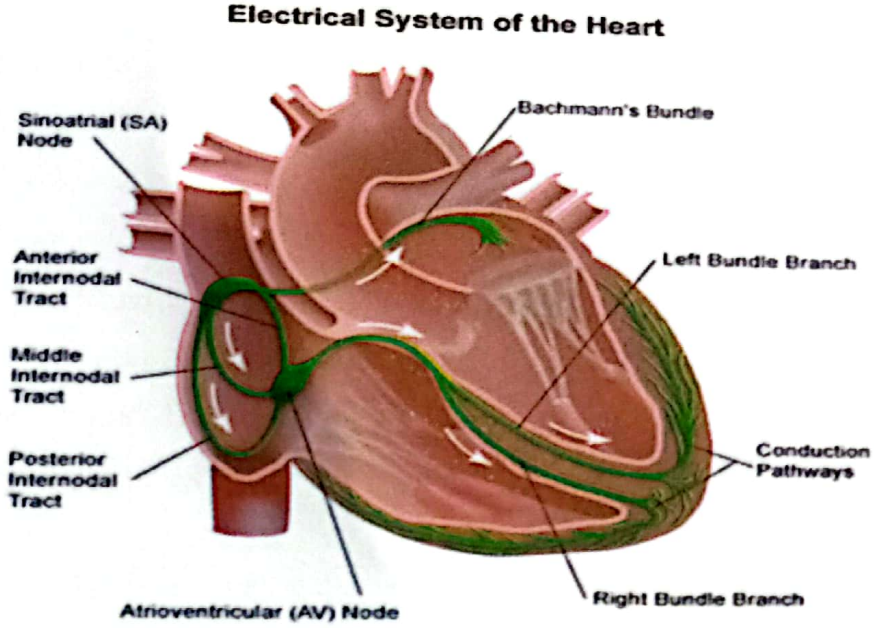

Figure 2: Conducting system of the heart

Presenting complaints of CVS

1. Chest pain
2. Breathlessness see respiratory system for details
3. Peripheral edema
4. Palpitation
5. Syncope
6. Fatigue

Scanned with CamScanner

Chest pain- here only cardiovascular causes of chest pain will be discussed. Please see respiratory system for other causes of chest pain.

1. Ischaemic heart disease
   a) Angina pectoris
      -Stable angina
      -Unstable angina
   b) Myocardial infarction
2. Pericarditis
3. Myocarditis
4. Aortic dissection

Angina pectoris

Angina pectoris is the symptom complex caused by transient myocardial ischaemia, it occur whenever there is an imbalance between myocardial oxygen supply and demand. Patient usually experience central chest pain, discomfort or breathlessness that is brought on by exertion or other forms of stress and is promptly relieved by rest. Coronary atheroma is by far the most common cause of angina, although the symptoms may be a manifestation of other forms of heart disease, particularly aortic valve disease (aortic stenosis) and hypertrophic cardiomyopathy.

Characteristics of pain of angina pectoris

1. Site-anginal pain is characteristically felt in the center of the chest. It is poorly localized and usually indicated using the open hand or a fist rather than finger tip.
2. Duration-anginal pain is short lived and usually lasting for less than 30 minutes.
3. Severity-severity of angina relates to the degree of functional limitation and frequency of symptoms rather than the intensity of pain. Usually mild to moderate.
4. Character-patient describes angina as tightness, heaviness, squeezing, crushing, constricting and usually a discomfort rather than pain. Angina is commonly accompanied by a feeling of breathlessness and sometimes this is the primary complaint.
5. Radiation-anginal pain may radiate to either or both arms, to the throat or jaw, less commonly to the back or epigastrium. Occassionally anginal pain may be experienced only at the sites of radiation or in the back.
6. Aggravating factor-pain of angina is aggravated by exertion, emotional excitement, cold weather, after meal etc.
7. Relieving factor-anginal pain is rapidly relieved by taking rest and after use of gleceryl trinitrate (oral or sublingual).

Scanned with CamScanner

Stable angina

Occurs due to fixed stenosis of the coronary artery and symptoms occurs in exertion and rapidly relieved by taking rest.

Unstable angina

Unstable angina is characterised by new-onset or rapidly worsening angina (crescendo angina), angina on minimal exertion or angina at rest, in the absence of myocardial damage. Evidence of myocardial damage is the elevation of cardiac troponin or creatine kinase-MB isoenzyme.

Myocardial infarction

Symptoms of myocardial infarction are similar to, but more severe and prolonged than, those of angina pectoris. Other features includes restlessness, breathlessness and a feeling of impending death (angor animi). Autonomic stimulation produces sweating, pallor, nausea, vomiting and diarrhoea, particularly in inferior infarction. Pain is absent in up to 30% of patients with myocardial infarction, especially in the elderly and those with diabetes mellitus.

What is acute coronary syndrome (ACS)?

Acute coronary syndrome is the term that encompasses both unstable angina and MI.

Differences between stable angina and myocardial infarction

Stable angina	Myocardial infarction
Onset of pain-gradual.	Onset of pain-sudden, over minutes.
Duration- short lived and usually lasting for less than 30 minutes.	Duration-prolonged episode, persists for more than 30 minutes.
Severity-mild to moderate.	Severity-severe.
Precipitant-pain usually brought on exertion and stressful condition.	Precipitant-none, pain occurs in resting condition.
Relieving factors-taking rest and nitrates.	Relieving factors -not relieve/partially relieve by taking rest and nitrates.
Signs of sympathetic stimulation like nausea, vomiting, sweating-usually absent.	Signs of sympathetic stimulation activity like nausea, vomiting, sweating-usually present.

Differences between ischemic cardiac chest pain and non-cardiac chest pain

Points	Ischemic cardiac chest pain	Non-cardiac chest pain
Location	Central, diffuse.	Peripheral, localized.
Radiation	Jaw, neck, shoulder, arm, back.	Other or no radiation.
Character	Squeezing, choking, tightening.	Sharp, stabbing, catching.
Precipitation	Exertion and/or emotion.	Spontaneous, not related to exertion, provoked by posture, respiration or palpation.
Relieving factors	Rest, nitrates.	Not relieved by rest, slow or no response to nitrates.
Associated features	Breathlessness, palpitation.	Respiratory, gastrointestinal, locomotor or psychological symptoms.

Scanned with CamScanner

Pericarditis

The pain of pericarditis is sharp in character, aggravated by deep inspiration, cough, posture changes, lying position and reduced by sitting forewards. Pericarditis is usually associated with pericardial rub. Pericarditis is usually idiopathic, but may occur due to coxsackie B infection and as a complication of MI.

How to differentiate between pericardial rub and pleural rub?

Pericardial rub	Pleural rub
Occurs due to pericarditis.	Occurs due to pleurisy.
Rate of pericardial rub is same as heart rate.	Rate of pleural rub is same as respiratory rate.
Pericardial rub persists after breath holding.	Pleural rub become absent after breath holding.

Aortic dissection

This produces severe tearing pain in either the front or back of the chest. The onset is abrupt, unlike the crescendo quality of ischaemic cardiac pain.

Fatigue- exertional fatigue is an important symptom of heart failure. It is caused partly by deconditioning and muscular atrophy but also by inadequate oxygen delivery to the exercising muscles, reflecting impaired cardiac output.

Palpitation-an abnormal awareness of the heart beat is called palpitation.

Causes of palpitation

Physiological

1. Anxiety, tension, fear
2. Exercise
3. Hearing of breaking news

Pathological causes

A) Cardiac

1. Premature atrial contraction (PAC)
2. Premature ventricular contraction (PVC)
3. Supraventricular tachycardia (SVT)
4. Atrial fibrillation and flutter
5. Ventricular tachycardia and fibrillation

B) Non-cardiac

1. Thyrotoxicosis
2. Severe anaemia
3. Fever
4. Drugs-salbutamol, theophylline, dihydropyridine calcium channel blockers (nifedipine, amlodipine).

Scanned with CamScanner

What history should be taken if a patient present with palpitation?

1. Duration-recurrent, short lived palpitation of long duration is usually benign in origin..
2. Frequency-frequent, recurrent palpitation is usually due to underlying heart disease.
3. Mode of onset and termination-exertion related palpitation is usually due to cardiac in origin. Palpitation particularly occurring in stressful condition and relieved spontaneously is usually benign.
4. Specific triggers e.g. exercise, alcohol, caffeine. Palpitation usually triggers by or occurs due to intake of caffeine or alcohol.
5. History of rheumatic fever in past-palpitation in a patient with past history of rheumatic fever may indicate underlying valvular heart disease.
6. Drug history-salbutamol, theophylline, dihydropyridine calcium channel blockers (nifedipine, amlodipine).
7. Are there any associated symptoms e.g. polyuria (a feature of supraventricular tachycardia), insomnia and weight loss (features of thyrotoxicosis) etc.

A simple approach to the diagnosis of palpitation

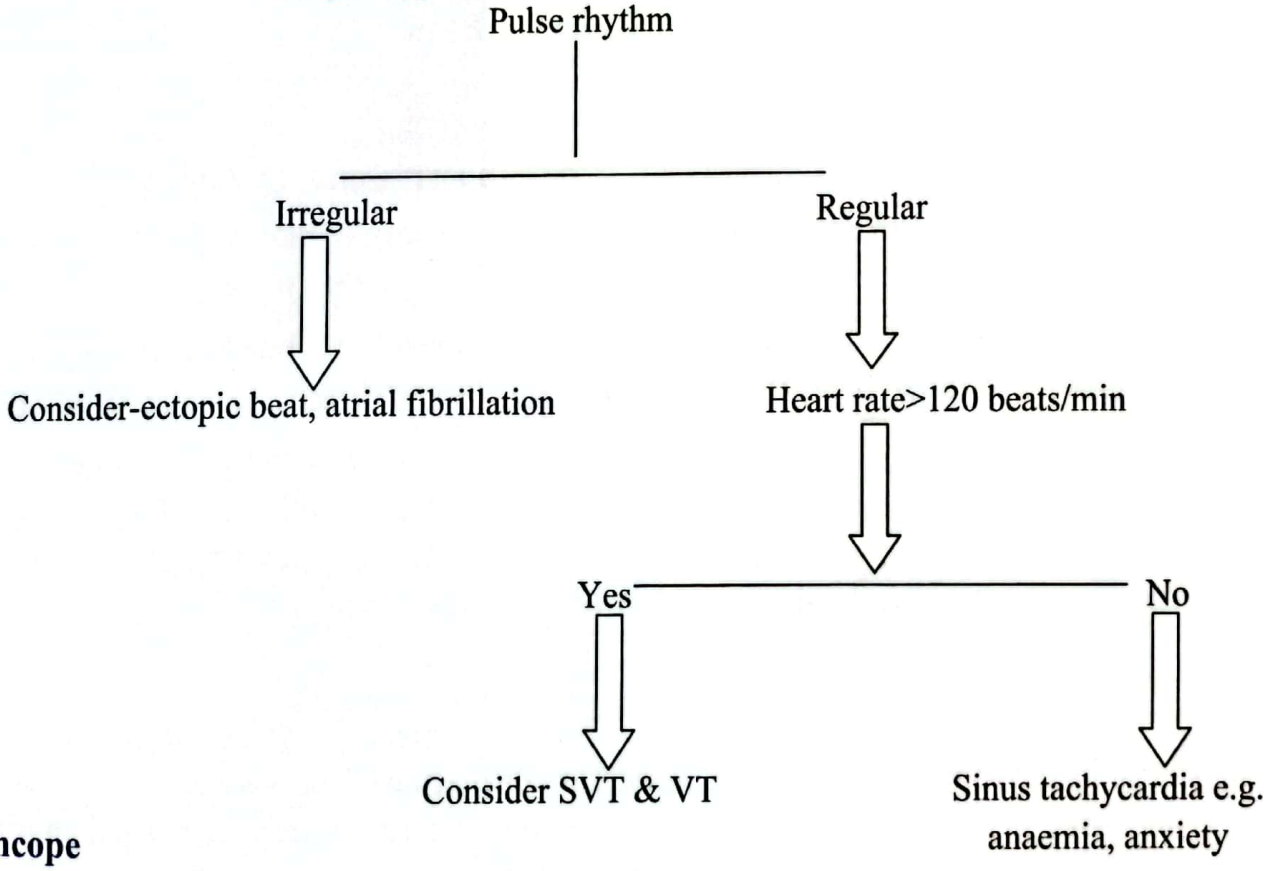

Syncope

Transient loss of consciousness due to reduced cerebral circulation, usually associated with hypotension is called syncope.

Presyncope

Symptoms of dizziness or lightheadedness, without loss of consciousness is called presyncope.

Scanned with CamScanner

Dizziness

Dizziness is a term used to describe everything from feeling faint or lightheaded to feel weak or unsteady. Dizziness that creates the sense that you or your surroundings are spinning or moving is called vertigo.

Causes of syncope

A number of medical conditions can cause syncope. Some of the most common are listed here.

1. Vasovagal syncope
2. Heart rhythm problems
   - -Sinus bradycardia
   - -Heart block (complete heart block)
   - -Ventricular tachycardia
   - -Supraventricular tachycardia
3. Blockage of blood flow from the heart
   - -Aortic stenosis
   - -Hypertrophic cardiomyopathy
4. Orthostatic hypotension
   - -Blood or fluid loss.
   - -Medications e.g. diuretics, ACEi, some antidepressants, morphine etc.
   - -Illnesses that affect the nervous system. Examples are Parkinson disease, diabetes mellitus, Shy-Drager syndrome and amyloidosis.
   - -Alcohol-drinking alcohol can cause blood vessels to expand, causing blood pressure to fall and syncope to occur.
   - -Carotid sinus hypersensitivity-carotid sinus hypersensitivity is a condition in which reflexes lead to a slow heart rate and/or enlargement of blood vessels. This may be triggered by pressure on the carotid arteries (the main artery in the neck), and can lead to low blood pressure and syncope.
5. Stokes-Adams attacks

   This condition caused by self-limiting episodes of asystole or rapid tachyarrythmias (including ventricular fibrillation). The loss of cardiac output causes syncope and striking pallor. Following restoration of normal rhythm, recovery is rapid and associated with flushing of the skin as flow through the dilated cutaneous bed is re-established.
6. Other causes-less common causes of syncope include a heart attack, atrial myxoma, or blood clot in the arteries supplying the lungs (pulmonary embolism).

Scanned with CamScanner

Peripheral edema

Accumulation of excessive fluid in the interstitial spaces and/or serous cavities is called edema. Edema can be a symptom as well as a sign. In cardiac disease (heart failure) edema first appears in leg or over the sacrum in bedridden patient (this occurs due to the effects of gravity on capillary hydrostatic pressure).

Causes of peripheral edema

Unilateral

1. DVT (deep venous thrombosis)
2. Lymph edema due to filariasis
3. Cellulitis
4. Immobility (hemiplegia)

Bilateral peripheral edema

1. CCF
2. Cirrhosis of liver with portal hypertension
3. Nephrotic syndrome, CKD
4. Malabsorption/protein energy malnutrition
5. Inferior venacaval obstruction
6. Hypothyroidism
7. Drugs-NSAIDs, steroid, CCB etc.
8. Preeclampsia
9. Idiopathic fluid retention syndrome

Clinical examination of the cardiovascular system

Examination of cardiovascular system consists of

1. Examination of arterial pulse
2. Measurement of blood pressure
3. Examination of JVP
4. Examination of the precordium
5. Percussion and auscultation of the lung base

Examination of arterial pulse

Definition: Pulse may be defined as expansion and elongation of the arterial wall produced due to left ventricular systole and diastole.

Sites of examination of pulse in our body

1. Radial artery (near the wrist joint)
2. Brachial artery (near the elbow joint)
3. Carotid artery (neck, at the level of angel of the mandible)
4. Femoral artery (at the inguinal region)
5. Popliteal artery (at the popliteal fossa)
6. Posterior tibial artery (at the ankle joint)
7. Arteria dorsalis pedis (over the dorsum of the foot)
8. Temporal artery

Scanned with CamScanner

Points to be noted during examination of the pulse

1. Rate
2. Rhythm
3. Volume
4. Character
5. Symmetry
6. Radio-radial and radio-femoral delay
7. Condition of the vessel wall

Rate- if the rhythm of the pulse is regular, then pulse should be counted at the radial artery over a period of 15 seconds and for 1 minute if the rhythm is irregular. Normal pulse rate is 60-90 beats/minute.

Tachycardia- when pulse rate is >100 beats/minute.

Causes of tachycardia

Physiological causes

1. Anxiety
2. Exercise
3. Fear
4. Pregnancy
5. Emotional excitement

Pathological causes of tachycardia

1. Hyperdynamic circulation due to any cause e.g. fever, anaemia, thyrotoxicosis etc
2. Heart failure
3. Anterior MI
4. Supra ventricular tachycardia
5. Ventricular tachycardia
6. Thyrotoxicosis
7. Pheochromocytoma
8. Drugs e.g. Salbutamol, theophylline, atropine, amlodipine, dopamine.

Bradycardia-when pulse rate is <60 beats/minute.

Pathological causes of bradycardia

a) Inferior myocardial infarction
b) Sick sinus syndrome
c) Complete heart block
d) Hypothyroidism
e) Hypothermia
f) Raised intracranial pressure due to any cause
g) Obstructive/cholestatic jaundice
h) Drugs e.g. beta blockers, rate limiting calcium channel blockers (verapamil, deltiazem), digoxin etc.

Physiological causes of bradycardia

1. Sleep
2. Athlet

Rhythm-this should be assessed while examining the radial artery. Normally rhythm is regular. Irregular rhythms are of two types

a) Regularly irregular e.g. ventricular ectopics, sinus arrhythmia, 2nd degree heart block.

b) Irregularly irregular e.g. atrial fibrillation, multiple ventricular ectopics, atrial flutter with variable block.

Scanned with CamScanner

Volume –this should be assessed in carotid artery.

Volume increase in

a) Pregnancy

b) Severe anaemia

c) Mitral regurgitation

d) Aortic regurgitation

Volume decrease in

a) Hypovolumia (shock)

b) Severe dehydration

c) Aortic stenosis

d) Mitral stenosis

Character-this is assessed at carotid artery. Normal pulse is catacrotic.

Symmetry-both side of the pulse present or present only in one side. As for example-radial pulse present in right side and absent in left side (which may indicate thrombo-embolic occlusion of the left radial artery).

Radio-radial and radio-femoral delay-normally there is no radio-radial and radio-femoral delay. Radio-radial delay occurs in cervical rib and radio-femoral delay occurs in coarctation of the aorta.

Condition of the vessel wall-in old age and atherosclerosis arterial wall become thickened and feel like a cord. This should be assessed while examining the radial pulse.

Some abnormalities of the pulse

1. Slow rising or anacrotic pulse-here pulse volume rises gradually, example aortic stenosis.
2. Water hammer pulse or collapsing pulse-after ejection of blood from the left ventricle to the aorta, blood come back to the left ventricle due to the incompetence of the aortic valve, so the aorta seems to be collapse. This pulse occurs in aortic regurgitation.
3. Pulsus bisferiens occurs in combined aortic stenosis and aortic regurgitation.
4. Pulsus alternans–alternative low and high volume pulse, occurs in acute left ventricular failure. Low volume pulse due to inadequate contraction of the left ventricle, after that blood volume of the left ventricle increase that stimulate the cardiac muscle as in Frank–Starling law, results in increased cardiac output and high volume pulse.
5. Pulsus paradoxsus–normally during inspiration systolic pressure fall up to 10 mm of Hg. When systolic pressure falls more than 10 mm of Hg this is called pulsus paradoxsus. Causes of pulsus paradoxsus are:

    a) Constrictive pericarditis

    b) Cardiac tamponade

Scanned with CamScanner

c) Obstructive pulmonary disease

d) Tension pneumothorax

e) Pulmonary embolism

6. Pulse deficit- in atrial fibrillation there is a substantial difference of heart rate detected by auscultation of precordium and from radial pulse. Because in atrial fibrillation all the ventricular contraction is not enough to produce a peripheral pulse. The difference of heart rate counted from auscultation and palpation of radial artery is pulse deficit. Pulse deficit occurs in atrial fibrillation, multiple ventricular ectopics, atrial flutter with variable block.

   How to examine for pulse deficit?

   Patient should be in supine position. One helping person should count the heart rate by auscultation and one should count heart rate from radial pulse simultaneously. e.g. If the heart rate by auscultation is 110 beats/minute and in radial artery 60 beats/minute, then pulse deficit is 110-60=50.

Steps of examination of pulse.

1. Greetings and consent.
2. Position-patient should be in supine position.
3. First examine the radio-radial and radio-femoral delay. Ask the patient to keep the both hands on both sides of the abdomen. Palpate the radial artery with both hands (right radial artery with left hand, left radial artery with right hand) (figure 3a). Feel whether the both radial pulsation feel simultaneously or not.

   For radio-femoral delay palpate the right radial artery of the patient with left hand and right femoral artery with right hand and feel whether both the pulsation feel simultaneously or not (figure 3b).

Figure 3a: Radio-radial delay

Figure 3b: Radio-femoral delay

Figure 3: Examination of radio-radial delay and radio-femoral delay.

Scanned with CamScanner

Figure 4: Examination of radial pulse.

4. Hold the patient's right hand with the right hand (like hand shake, slightly flex the patient's wrist joint) (figure 4), first examine the rhythm of the pulse, if the rhythm of the pulse is regular, then pulse should be counted over a period of 15 seconds and if the rhythm is irregular then for 1 minute.
5. Gently rub the artery to see the condition of the vessel wall.
6. Then proceed to examine the other pulses.



Figure 5a: Brachial artery (right) Figure 5b: Brachial artery (left)

Figure 5: Palpation of brachial artery.

7. Brachial artery-semiflexed the elbow joint, use the thumb to palpate the brachial artery (right for the right brachial artery and vice versa), while the fingers will cupped round the back of the elbow joint (figure 5).
8. Carotid artery- gently place the tip of your thumb obliquely at the level of the angel of the mandible. Use left thumb for right carotid artery and vice versa (figure 6).

Scanned with CamScanner

Figure 6a: Carotid artery (right) Figure 6b: Carotid artery (left)

Figure 6: Palpation of the carotid artery.

9. Femoral artery-place the pads of your index and middle fingers over the femoral artery in inguinal region at the level of the midpoint between anterior superior iliac spine and pubic tubercle.

10. Popliteal artery-semiflexed the knee joint, place tip of the fingers of the both hand at the back of the popliteal fossa and feel the artery (figure 7).

Figure 7a: Popliteal artery (right) Figure 7b: Popliteal artery (left)

Figure 7: Examination of popliteal artery.

11. Posterior tibial artery-place the tip of the fingers just below and behind the medial malleolus (figure 8).

Figure 8a: Posteriot tibial artery (right) Figure 8b: Posteriot tibial artery (left)

Figure 8: Examination of posterior tibial artery.

Scanned with CamScanner

12. Arteria dorsalis pedis-place the fingers on the dorsum of the foot, lateral to the extensor tendon of the great toe (1st inter metatarsal space) (figure 9).

Figure 9a: Figure 9b:

Figure 9: Examination of arteria dorsalis pedis 9a (left) and 9b (right).

13. Thank the patient.

How to examine for collapsing pulse?

Ask the patient "do you have any pain in your right shoulder joint?" if answer is no, then feel the radial pulse with the base of your fingers, then raise the patient's hand above his head (figure 10). Normally there will be no change of the pulse. If collapsing pulse is present then the pulse will be absent for a moment followed by high volume pulse will feel.

Note: If the patient has pain in right shoulder joint then examine in left side. If patient have pain in both shoulder joints then it is better not to examine the water hammer pulse.

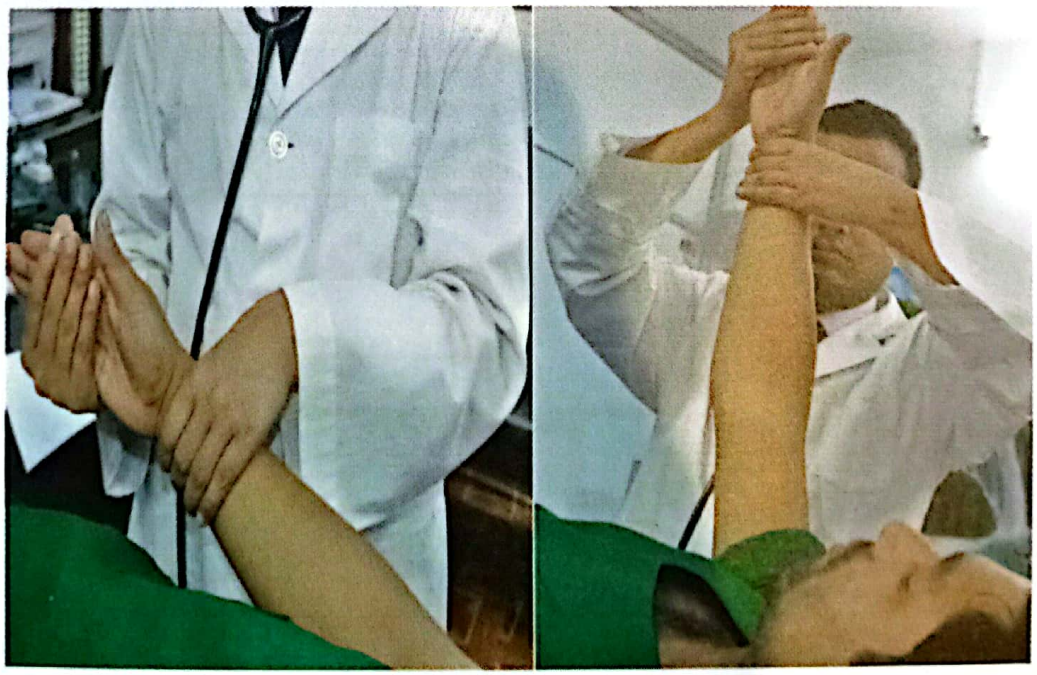

Figure 10: Examination of collapsing pulse.

Scanned with CamScanner

Blood pressure

Blood pressure (BP), sometimes referred to as arterial blood pressure, is the pressure exerted by circulating blood upon the wall of blood vessel and is one of the principal vital signs. Blood pressure should be measured at the arm (brachial artery) in sitting position by a sphygmomanometer. Both auscultatory and palpatory method should be used.

Blood pressure measurement devices- three types of devices usually use to measure blood pressure:

1. Mercury sphygmomanometer is the gold standard if properly maintained.
2. Aneroid devices are used widely.
3. Automated device- record blood pressure automatically. This is to monitor blood pressure at home but the device need to be a valid and well calibrated one.

Procedure of measurement of blood pressure

- ✓ Measurement should be started after at least 5 minutes of rest.
- ✓ Measure sitting blood pressure routinely.
- ✓ Lying and standing blood pressure should be recorded in elderly or in diabetic patients to determine presence of postural hypotension.
- ✓ Remove tight clothing from arm, thin cloth like blouse, shirt may be allowed. But folding of the shirt sleeve should be avoided, because this may compress the arm and may record false blood pressure.
- ✓ Patients should refrain from smoking, ingesting caffeine, heavy meal, exercise 30 minutes prior to measurement of blood pressure.
- ✓ Use cuff of appropriate size, the cuff (the bladder) should cover at least 2/3rd of the arm circumference.

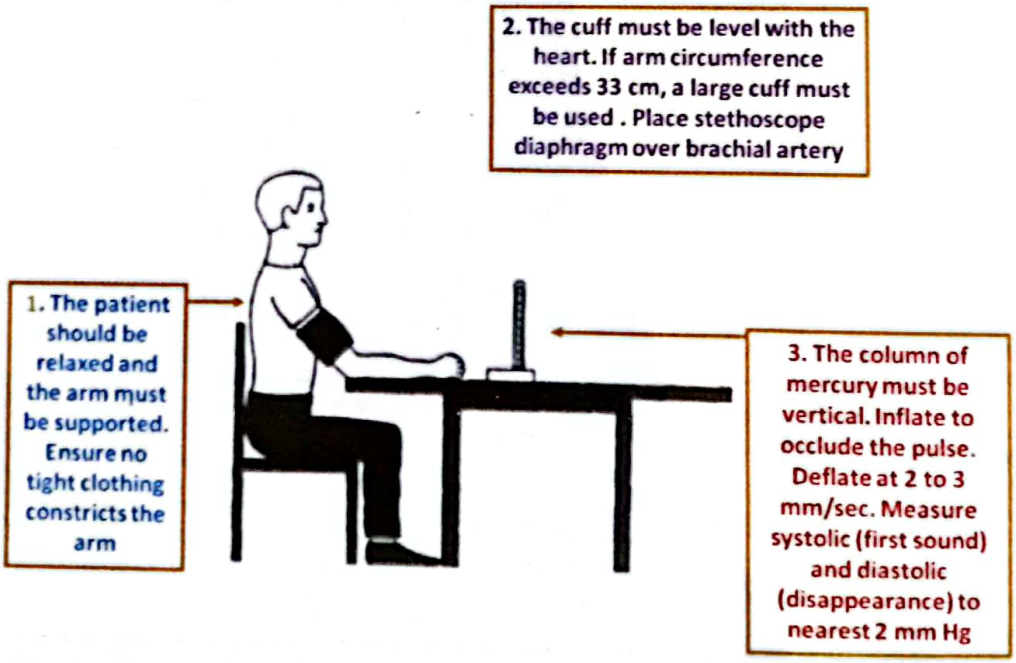

Figure 11: Position of the patient during measurement of blood pressure.

Scanned with CamScanner

- ✓ Patient must be in relax position.
- ✓ Avoid talking during the measurement procedure.
- ✓ Measure in both arms at 1st visit. In the subsequent visit measure BP in the arm which record high BP than other arm.
- ✓ At least 2 measurements should be taken in each visit (1-2 minutes apart). More measurement should be taken if >10mmHg difference in systolic or >5mmHg difference in diastolic blood pressure is found.
- ✓ Lower mercury column slowly (2mm/sec).
- ✓ Measurement should be made to the nearest 2 mm Hg.
- ✓ Measure systolic blood pressure as the appearance of korotkoff sound (phase I, see below).
- ✓ Measure diastolic blood pressure as the disappearance of korotkoff sound (phase V).
- ✓ Nevertheless, in those condition where korotkoff sounds remain audible despite complete deflation of the cuff (aortic regurgitation, arteriovenous fistula, pregnancy) phase 4 (muffling of the sound) must be used for the diastolic blood pressure.
- ✓ Clinicians should provide to the patient the measured blood pressure verbally and in writing the specific blood pressure number and blood pressure goal.
- ✓ Do not diagnose and treat hypertension on the basis of single blood pressure recording.

Korotkoff sound – during measurement of blood pressure while deflating the bladder cuff a sound appear on auscultation over the brachial artery this sound is called Korotkoff sound. Auscultation over the brachial artery reveals five phases of Korotkoff sounds as the cuff is deflated:

Phases of Korotkoff sounds

Phase 1: The first appearance of the sound.
Phase 2 and 3: Increasingly loud sound.
Phase 4: Abrupt muffling of the sound.
Phase 5: Disappearance of the sound.

Scanned with CamScanner

Classification of blood pressure level

BP Classification	Systolic blood pressure (mm of Hg)		Diastolic blood pressure (mm of Hg)
Normal	<120	and	<80
Prehypertension	120 - 139	and/or	80-89
Hypertension	≥140	and/or	≥ 90
Stage 1 Hypertension	140 - 159	and/or	90 - 99
Stage 2 hypertension	≥160	and/or	100 -109
Severe hypertension	≥180	and/or	≥ 110
Isolated systolic hypertension			
Grade 1	140 - 159	and	<90
Grade 2	≥160	and	<90
Severe hypertension	≥180	and	<90

JVP (Jugular venous pulse)

Please see general physical examination section.

Examination of precordium

Portion of the chest overlying the heart is called precordium. Examination of precordium consist of

1. Inspection
2. Palpation
3. Percussion
4. Auscultation

Inspection

Following points should be noted during inspection of the precordium-

1. Shape of the precordium
2. Visible pulsation
3. Deformity
4. Scar mark
5. Engorged vein
6. Any swelling

Scanned with CamScanner

Visible pulsation

Visible pulsation may be present in any part of the precordium, but may be also present in epigastrium and in neck. Site of the visible pulsation usually indicate disease in the underlying valves. Example- visible pulsation present over the mitral area indicates disease in the mitral valve. Visible pulsation in neck present in aortic regurgitation.

Position of different valves on the precordium

Name of the valve	Location
Mitral valve	Position of the apex beat (apical area)
Tricuspid valve	Left parasternal area in left 3rd & 4th intercostal space
Pulmonary valve	Left 2nd intercostal space
Aortic valve	Right 2nd intercostal space

Causes of epigastric pulsation

1. Normally in lean-thin person
2. Right ventricular hypertrophy
3. Abdominal aortic aneurysm
4. Pulsatile liver in tricuspid regurgitation

Deformity

During inspection any deformity of the chest likes kyphosis (forward bending), scoliosis (lateral bending), pectus excavatum (in which lower end of the sternum is pushed downwards), pectus carinatum (in which lower end of the sternum is pushed upwards) should be noted. In pectus excavatum apex beat may be normally shifted without having cardiomegally.

Scar mark

Any scar mark over the precordium should be noted, because it can provide important information e.g. midsternal scar mark indicate past bypass surgery, left submammary scar mark indicate history of mitral valve surgery. Infraclavicular scar may be present after pace maker implantation.

Engorged vein

During inspection any engorged vein should be noted. Engorged vein usually present in lateral chest wall in superior vena caval obstruction (in this case direction of blood flow is above downwards).

Scanned with CamScanner

Any swelling

Any swelling over the precordium should be noted.

Sequence of inspection of the precordium

1. Greetings and consent
2. Proper exposure of the precordium
3. Patient should be in lying position with one pillow under the head.
4. Carefully look over the precordium (mitral area, suprasternal area, neck) (figure 12a).

Figure 12a: Inspection from side of the patient Figure 12b: Inspection for epigastric pulsation

Figure 12: Inspection of the precordium.

5. Sit down beside the bed and asked the patient to hold the breath and carefully look for epigastric pulsation (figure 12b).
6. Re-clothing and thank the patient.

Presentation of inspection findings of precordium

(Normal findings)- on inspection shape of the precordium is normal; there is no visible pulsation, scar mark, deformity, engorged vein and swelling.

(Abnormal findings, suppose visible pulsation present in the apical area, midsternal scar mark present)-on inspection shape of the precordium is normal, visible pulsation present over the mitral area, midsternal scar mark present; there is no deformity, engorged vein and swelling.

Palpation

Following points should be noted during palpation of the precordium:

1. Position and character of the apex beat
2. Left parasternal heave
3. Palpable P2
4. Thrill

Scanned with CamScanner

Position and character of the apex beat

Definition -this is the lowermost and outermost point of the definite cardiac pulsation. Normally apex beat is situated in the left 5th intercostal space, 9 cm from the midline, just medial to the left midclavicular line. Character of the apex beat-normally normal in character.

What are the causes of shifting apex beat?

1. Cardiac enlargement commonly due to valvular heart diseases, heart failure etc
2. Displacement of the apex due to mediastinal shifting resulting from pleural effusion, pneumothorax, collapse, fibrosis etc.

What are the causes of absent apex beat?

1. Left sided pleural effusion
2. Left sided pneumothorax
3. Pericardial effusion
4. Thick chest wall (obese)
5. Apex beat under the rib etc.

Abnormal character of the apex beat: Tapping apex beat occurs in mitral stenosis. Thursting apex beat occurs in aortic regurgitation and mitral regurgitation (volume overload). Heaving apex beat occurs in left ventricular hypertrophy (pressure overload) due to hypertension, aortic stenosis etc.

Left parasternal heave

This should be examined by placing the ulnar border of the right hand along the left parasternal area, feeling of thrust on the hand indicate left parasternal heave is present.

Left parasternal heave present in right ventricular hypertrophy due to any cause (commonly pulmonary hypertension, pulmonary stenosis, chronic pulmonary embolism etc).

Palpable P2

This should be examined while placing the tips of the middle and ring fingers of the right hand over the pulmonary area. P2 will be palpable in pulmonary hypertension.

Thrill

Turbulance flow of blood that produce palpable vibration on the chest wall is called thrill. (Palpable murmur is called thrill). This should be examined by placing palm of the hand (especially area overlying the metacarpophalangeal joints) over the mitral, tricuspid, pulmonary and aortic area. If thrill present following points should be noted-

Scanned with CamScanner

1. Site –the site of the thrill indicate disease of the underlying valve or structures, e.g. thrill present on aortic area is usually due to aortic stenosis.
2. Timing-timing of the thrill is determined by placing the thumb of the left hand on carotid artery while examining for thrill, if the thrill coincides with the carotid pulse it is systolic, if does not coincide it is diastolic.

Causes of thrill

Any murmur can produce thrill, but common causes are:

1. VSD (ventricular septal defect)
2. Aortic stenosis
3. PDA (persistent ductus arteriosus)

Sequence of palpation of the precordium

1. Greetings and consent.
2. Position of the patient –supine position and proper exposure.
3. Place the fingers of the right hand over the precordium with middle and ring finger around the 4th, 5th, 6th intercostal spaces along the left midclavicular line (figure 11a). Try to feel the pulsation, if pulsation present, locate it (this is the position of apex beat). Count the location from left 2nd intercostal space (figure 11b) and measure from the midline by measuring tape. If pulsation not present move the fingers alongside. If still not palpable, then turn the patient to the left side and feel for apex beat. If still not palpable then exercise (walking or lying and sitting, but avoid heavy exercise) the patient and feel for apex beat, if apex beat is not palpable then palpate on the right side (for dextrocardia). If apex beat is not palpable on the right side then declare that apex beat is not palpable/absent.

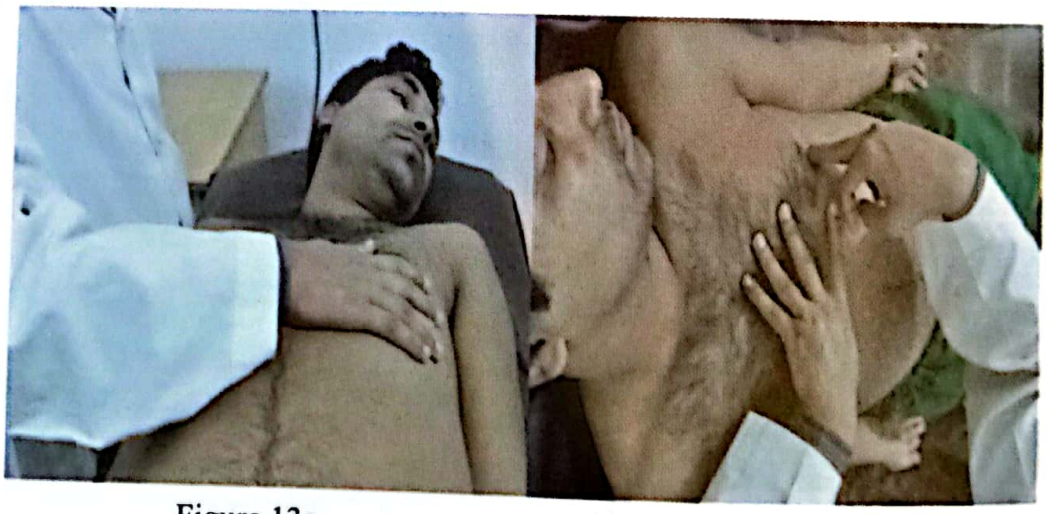

Figure 13a Figure 13b

Figure 13: Examination of position of the apex beat

Scanned with CamScanner

4. Place the ulnar border of the right hand along the left sternal edge (figure 14a), feeling of thurst on the hand indicates left parasternal heave is present.

5. Place the tips of the middle and ring fingers of the right hand over the pulmonary area (figure 14b) and feel for P2 (pulmonary component of the second heart sound).

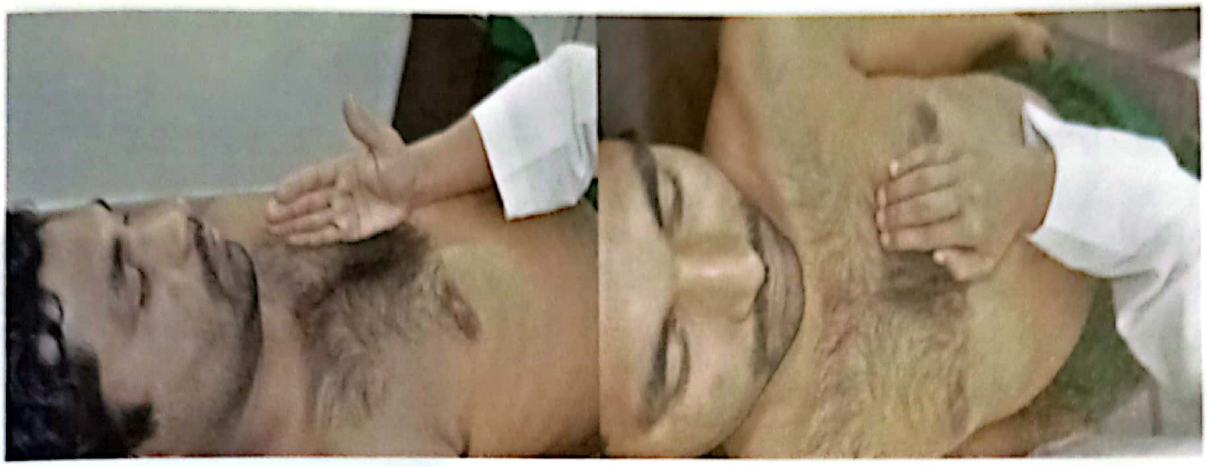

Figure 14a: Left parasternal heave Figure 14b: Palpable P2

Figure 14: Examination of left parasternal heave and palpable P2.

6. Place the palm of the hand (especially area overlying the metacarpophalangeal joints) over the mitral, tricuspid, pulmonary and aortic area (figure 15). If thrill present following points should be noted-

   a) Site of the thrill

   b) Timing of the thrill

Figure 15: Examination of thrill in mitral and aortic area

Scanned with CamScanner

7. Re-clothing and thank the patient.

Presentation of palpation findings

(Normal findings)-on palpation apex beat is situated in left 5th intercostal space, 9 cm from the midline, normal in character; left parasternal heave, thrill and P2 is absent.

(Abnormal findings as in mitral stenosis with pulmonary hypertension)-on palpation apex beat is in left 5th intercostal space, 9 cm from midline, tapping in character, left parasternal heave is present, thrill is absent and P2 is palpable.

Percussion

Percussion has very minimum importance and usually not done during routine examination of precordium. Percussion is done to map out superficial cardiac dullness. Area of superficial cardiac dullness increase in pericardial effusion and decrease in emphysema.

Auscultation

Following points should be noted during auscultation of the precordium:

1. Heart sounds
2. Murmur
3. Added sound-pericardial rub, opening snap, metallic sound of metallic heart valve etc.

Heart sounds

There are four heart sounds

1. First heart sound (S1)-produce due to closure of the AV valve (mitral and tricuspid). First heart sound normally present in healthy subjects.

   First heart sound (S1) loud in

   a) Mitral stenosis

   b) Tricuspid stenosis

   c) Tachycardia due to any cause.

   First heart sound (S1) soft in

   a) Mitral regurgitation

   b) Tricuspid regurgitation

   c) Severe calcified mitral stenosis

   d) Infective endocarditis

   e) After acute MI

Scanned with CamScanner

2. Second heart sound (S2)-produce due to closure of the aortic and pulmonary valve. S2 has two component aortic (A2) and pulmonary (P2). Second heart sound normally present in healthy subjects and single in expiration, physiological splitting (A2 followed by P2) occurs during inspiration.

Exaggerated splitting (A2 followet by P2 but the gap between them more than normal) occurs in RBBB (right bundle branch block), reverse splitting occurs (P2 followed by A2) occurs in LBBB and aortic stenosis. Fixed splitting of 2nd heart sound occurs in ASD.

In ASD fixed and wide splitting of the 2nd heart sound occurs, fixed due to equalization of pressure in both sides of the heart (oxygenated blood comes to the right side of the heart through atrial septal defect) and wide due to delayed right ventricular emptying.

A2 loud in

a) Systemic hypertension

A2 soft in

a) Aortic stenosis

b) Aortic regurgitation

c) Infective endocarditis

P2 loud in

a) Pulmonary hypertension

P2 soft in

a) Pulmonary stenosis

b) Pulmonary regurgitation

3. Third heart sound (S3)-produce due to rapid flow of blood from the left atrium to left ventricle in first rapid filling phase. Presence of 3rd heart sound always pathological but may be present normally in young adult.

Causes of presence of third heart sound

a) Young adult (<40 years)

b) Heart failure

c) Mitral regurgitation

d) Pregnancy

e) Fever

What is triple rhythm?

Presence of third heart sound along with 1st and second heart sound is called triple rhythm.

What is gallop rhythm?

Triple rhythm + tachycardia=gallop rhythm. Or presence of third heart sound along with tachycardia is called gallop rhythm. Gallop rhythm usually present in heart failure.

Scanned with CamScanner

4. Fourth heart sound (S4)-produce due to last filling phase.

Causes of fourth heart sound (S4)

a) Normally in elderly

b) Systemic hypertension

c) Aortic stenosis

d) Hypertrophic cardiomyopathy

Murmur

Murmur is an abnormal sound produce in the heart or great vessels due to normal blood flow through abnormal valve (as in stenosed valve), increase blood flow through normal valve (as in severe anaemia, thyrotoxicosis) or abnormal blood flow through abnormal openings between two sides of the heart (as in ASD, VSD).

Types of murmur

1. Systolic murmur
2. Diastolic murmur
3. Continuous murmur

Systolic murmur-3 types

1. Ejection (mid) systolic murmur: Ejection systolic murmur is a high frequency murmur separate from S1 and S2. It is usually due to turbulent forward flow across the right and left ventricular outflow tract e.g. aortic or pulmonary valve, or through the aorta or pulmonary artery. Causes are-aortic stenosis, pulmonary stenosis, hypertrophic cardiomyopathy.
2. Pansystolic murmur: Pansystolic murmur starts immediately with the first heart sound and continued through the second heart sound. (In pansystolic murmur second heart sound is obscured by the murmur) e.g. VSD, mitral regurgitation, tricuspid regurgitation.
3. Late systolic: The murmur begins in mid-systole, increases in intensity during late systole e.g. found in mitral valve prolapse, papillary muscle dysfunction.

Diastolic murmur-3 types

1. Early diastolic murmur (EDM): EDM is a high pitch murmur that begins with S2. Causes-aortic and pulmonary regurgitation.
2. Mid diastolic murmur: low pitch murmur occurs in mitral and tricuspid stenosis.
3. Presystolic murmur.

Scanned with CamScanner

Continuous murmur

This murmur can be heard in both systolic and diastolic phase of the cardiac cycle. e.g. PDA (persistent ductus arteriosus), A-V fistula.

Points to be noted if a murmur is present:

1. Site of the maximum intensity-murmur can be heard in several sites of the precordium, but the area of maximum intensity indicate the murmur originates from the underlying valve.
2. Timing-whether the murmur is systolic or diastolic? This should be done by palpating the carotid artery while auscultating for murmur. If the murmur coincides with the carotid pulse then it is systolic murmur, if not then it is diastolic murmur.
3. Radiation-radiation of the murmur means the murmur is heard in site other than the precordium. In this case intensity of the murmur is same in the radiant area like that of the site of origin of the murmur. e.g. murmur of aortic stenosis radiates to neck (along the direction of blood flow-carotid artery); murmur of mitral regurgitation radiates to left axilla.

Pericardial rub

This friction sound occur in pericarditis.

How to differentiate pericardial rub from pleural rub?

Pericardial rub	Pleural rub
1. Rate-same as heart rate.	1. Same as respiratory rate.
2. If voluntarily breath is hold- pericardial rub persist.	2. If voluntarily breath is hold-pleural rub disappear.

Sequence of auscultation of the precordium

1. Greetings and consent.
2. Position and proper exposure-patient should be in supine position and proper exposure of the precordium and neck.
3. First locate the position of the apex beat.
4. Place the left thumb over the left carotid artery to identify the heart sounds, 1st heart sound coincide with the carotid pulse and 2nd heart sound does not (figure 14).
5. Place the diaphragm of the stethoscope first in mitral area (figure 16) (where position of the apex beat is felt), then left parasternal area (tricuspid area), then pulmonary area (left 2nd intercostal space), then aortic area (right 2nd intercostal space).

Scanned with CamScanner

Figure 16: Auscultation of the precordium.

6. Turn the patient to the left side and re-locate the apex beat (as apex beat shift at left lateral position), ask the patient to hold the breath after expiration and auscult with the bell of the stethoscope for presence of mid diastolic murmur (this is to see mitral stenosis).

7. Ask the patient to sit and lean forwards and hold the breath after expiration and auscult the aortic area for ejection systolic murmur (aortic stenosis) and left parasternal area for early diastolic murmur (aortic regurgitation) with the diaphragm of the stethoscope. If ejection systolic murmur present then see radiation at right side of the neck by placing the diaphragm over the right carotid artery in neck. (if radiation present similar intensity murmur will be heard in neck)

8. Reclothing and thank the patient.

Note: During auscultation of the precordium, maneuver of mitral stenosis, aortic stenosis and aortic regurgitation should be done routinely.

Presentation of auscultatory finding (normal findings)

On auscultation 1st and 2nd heart sound are audible in all the 4 areas of the preccordium and normal in intensity, there is no murmur and pericardial rub.

Presentation of auscultatory finding (abnormal findings-mitral stenosis with pulmonary hypertension)

On auscultation 1st heart sound is loud, pulmonary component (P2) of the 2nd heart sound is loud, there is a middiastolic murmur in mitral area best heard with the bell of the stethoscope in left lateral position of the patient with breath hold after expiration, there is no pericardial rub. (Mention if opening snup is present).

Scanned with CamScanner

Procedure of auscultation of mitral stenosis(when ask to do the maneuver of mitral stenosis, proceed as follows)

1. Greetings and consent from the patient.
2. Position-supine position and proper exposure of the precordium.
3. Patient should be in left lateral position.
4. Locate the position of the apex beat (because apex beat will be shifted after change of position from supine to left lateral position).

Figure 17: Procedure of auscultation of mitral stenosis.

5. Place the bell of the stethoscope over the mitral area, while asking the patient to hold his breath at the end of the expiration (figure 17).
6. Re-clothing and thank the patient.

Why lateral position should be done during maneuver of mitral stenosis?

Mid diastolic murmur of mitral steenosis is low pitch. In lateral position the mitral area (apex of the heart) come closure to the chest and murmur will hear clearly/louder.

Why breath hold after expiration done during maneuver of mitral stenosis?

During expiration blood flow through left sided heart increases so the murmur will be louder as blood flow increase through stenosed mitral valve.

Auscultatory findings of mitral stenosis

On auscultation first heart sound is loud, pulmonary component (P2) of the 2nd heart sound is loud (in case of pulmonary hypertension), 2nd heart sound is followed by opening snap which is followed by a localized, low pitch, rough, rumbling, mid diastolic murmur best heard with the bell of the stethoscope, in the left lateral position of the patient, with breath hold after expiration.

Scanned with CamScanner

Procedure of auscultation of aortic stenosis and regurgitation (when ask to do the maneuver of aortic stenosis and regurgitation, proceed as follows)

1. Greetings and consent from the patient.
2. Position- Patient should be in sitting position with leaning forward and proper exposure of the precordium (figure 18a).

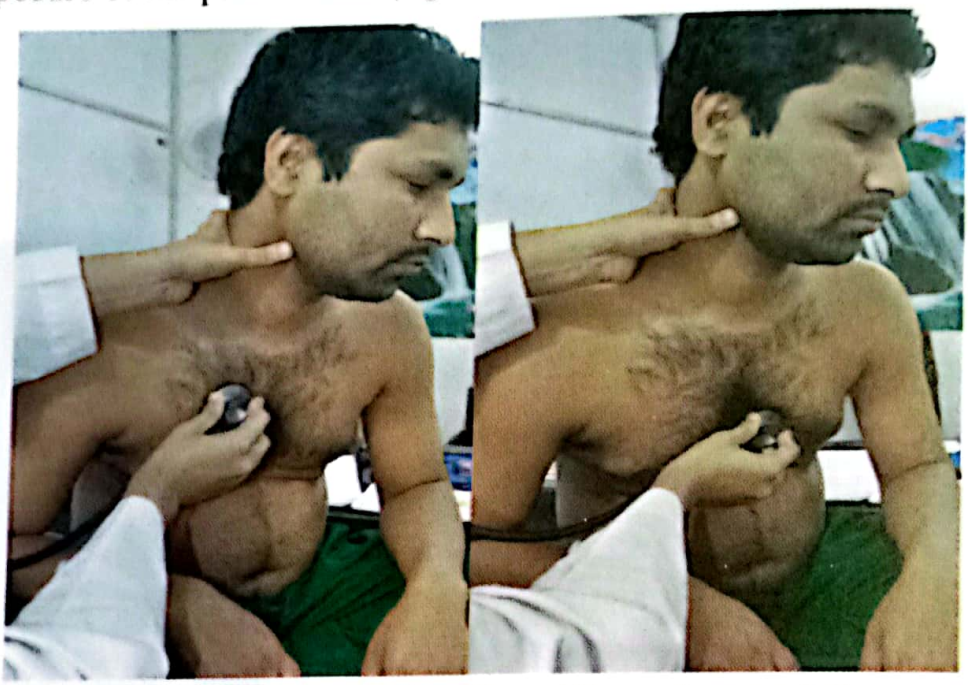

Figure 18a: Aortic stenosis Figure 18b: Aortic regurgitation

Figure 18: Procedure of ausculatation of aortic stenosis and regurgitation.

3. Place the diaphragm of the stethoscope over the aortic (figure 18a) (right 2nd intercostal space) area then in left parasternal area (3rd, 4th intercostal space), while asking the patient to hold his breath after expiration. (if ask to auscultate only aortic stenosis then don not auscult in the left parasternal area, if asked to auscult aortic regurgitation then auscult in both aortic and left parasternal area, figure 18b).
4. Place the diaphragm of the stethoscope over the right carotid artery if ejection systolic murmur present in aortic area to see the radiation of the murmur.
5. Reclothing and thank the patient.

(Remember if there is no ejection systolic murmur there is no need to see radiation in neck)

Percussion and auscultation of the lung base

Percussion and auscultation of the lung base should be done routinely to determine dullness and presence of fine crepitations. In acute left ventricular failure there is bilateral fine basal crepitation present.

Scanned with CamScanner

Sequence of examination of lung base

1. Greetings and consent from the patient.
2. Position- patient should be in sitting position and proper exposure of the back of the chest.
3. Percuss the base of the lung (from inferior angle of the scapula to below up to the last intercostal space on both sides).

Figure 19: Auscultation of the lung base.

4. Auscultate the base of the lung (for crepitation) (figure 19).
5. Re-clothing and thank the patient.

Putting it together

Mitral stenosis

1. Pulse-usually low volume, normal rhythm, irregular rhythm if atrial fibrillation present.
2. Blood pressure-usually normal.
3. JVP-usually not raised but may be raised if right heart failure present.
4. Precordium
   a) Inspection-normal but pulsation may be present in mitral area or apical area.

Scanned with CamScanner

b) Palpation

-Apex beat is situated in the left 5th intercostal space, 9 cm from the midline, just medial to the left midclavicular line, tapping in character. (apex beat may be shifted when mitral stenosis associated with mitral regurgitation)

-Left parasternal heave-usually absent, may be present if there is right ventricular hypertrophy (RVH due to mitral stenosis with pulmonary hypertension)

-P2-usually not palpable but palpable in pulmonary hypertension.

-Thrill-uaually absent but diastolic thrill may be present in mitral area.

c) Auscultation-on auscultation first and second heart sounds are audible, first heart sound is loud in intensity, pulmonary component of the second heart sound will be loud if there is pulmonary hypertension, second heart sound is followed by an opening snap, which is followed by a low pitch, localized, rough, rumbling, middiastolic murmur best heard with the bell of the stethoscope, during breath hold in expiration with the left lateral position of the patient.

5. Percussion and auscultation of the lung base-usually normal. But bilateral basal crepitation may be present if there is pulmonary edema.

Mitral regurgitation

1. Pulse-usually high volume, normal rhythm. But occasionally atrial fibrillation may be present.
2. Blood pressure-usually high systolic and low diastolic.
3. JVP-usually not raised but may be raised if right heart failure present.
4. Precordium

   a) Inspection-normal but visible pulsation may be present at the mitral or apical area.

   b) Palpation-apex beat is shifted, thrusting in character.

   -Left parasternal heave-usually absent, may be present if there is right ventricular hypertophy.

   -P2-usually not palpable but may be palpable if pulmonary hypertension present.

   -Thrill-usually absent but systolic thrill may be present in mitral area.

5. Auscultation-on auscultation first and second heart sounds are audible, first heart sound is soft in intensity, pulmonary component of the second heart sound will be loud if there is pulmonary hypertension, there is a pansystolic murmur in apical area which radiates to left axilla.

Scanned with CamScanner

6. Percussion and auscultation of the lung base-usually normal. But bilateral basal crepitation may be present if there is pulmonary edema.

Aortic stenosis

1. Pulse-usually low volume, normal rhythm.
2. Blood pressure-narrow pulse pressure (low systolic and normal diastolic).
3. JVP-usually not raised.
4. Precordium
   a) Inspection-normal.
   b) Palpation-apex beat is situated in the left 5th intercostal space, 9 cm from the midline, just medial to the left midclavicular line, heaving in character. (apex beat may be shifted when aortic stenosis associated with aortic regurgitation).
      -Left parasternal heave-usually absent.
      -P2-usually not palpable.
      -Thrill-systolic thrill may be present in aortic area.
   c) Auscultation-on auscultation first and second heart sounds are audible, first heart sound is normal in intensity, aortic component of the second heart sound is soft, there is a ejection (mid) systolic murmur present in aortic area best heard in sitting and leaning forward position of the patient, breath hold in expiration and the murmur radiates to right side of the neck.
5. Percussion and auscultation of the lung base-usually normal.

Aortic regurgitation

1. Pulse-usually high volume, normal rhythm, collapsing pulse may be present.
2. Blood pressure-usually high systolic and low diastolic (wide pulse pressure).
3. JVP-usually not raised.
4. Precordium
   a) Inspection-normal but pulsation may be present in neck.
   b) Palpation-apex beat is shifted, thrusting in character.
      -Left parasternal heave-usually absent.
      -P2-usually not palpable.
      -Thrill-usually absent.

Scanned with CamScanner

c) Auscultation-on auscultation first and second heart sounds are audible, first heart sound is normal in intensity, aortic component of the second heart sound is soft, there is a early diastolic murmur in left parasternal area best heard in sitting and leaning forward position of the patient, breath hold in expiration, there may be a ejection (mid) systolic murmur present in aortic area (due to increase blood flow through aortic valve, it is functional murmur).

5. Percussion and auscultation of the lung base-usually normal.

Q. What are the murmurs of aortic regurgitation?

In aortic regurgitation 3 murmurs are present:

1. Early diastolic murmur (due to aortic incompetence) (present in left parasternal area).
2. Ejection systolic (due to increase stroke volume) (present in aortic area).
3. Middiastolic murmur (in severe aortic regurgitation regurgitant flow of blood provides pressure on anterior leaflet of mitral valve, causing inappropriate opening of mitral valve producing middiastolic murmur, this murmur is also called Austin Flint murmur) (present in apical area).

Ventricular septal defect (VSD)

1. Pulse-usually low volume, normal rhythm.
2. Blood pressure-usually normal.
3. JVP-usually not raised.
4. Precordium

a) Inspection-normal.

b) Palpation-apex beat is situated in the left 5th intercostal space, 9 cm from the midline, just medial to the left midclavicular line, (may be shifted if patient develops LVH), heaving in character.

Left parasternal heave- present if RVH.

P2-usually not palpable.

Thrill-usually systolic thrill present in left parasternal area.

c) Auscultation-on auscultation first and second heart sounds are audible and normal in intensity, there is a pansystolic murmur present in left parasternal area.

5. Percussion and auscultation of the lung base-usually normal.

Scanned with CamScanner

Atrial septal defect (ASD)

1. Pulse-usually low volume, normal rhythm.
2. Blood pressure-usually normal.
3. JVP-usually not raised.
4. Precordium
   a) Inspection-normal.
   b) Palpation-apex beat is situated in the left 5th intercostal space, 9 cm from the midline, just medial to the left midclavicular line and normal in character.

      Left parasternal heave- present if there is RVH.

      P2-not palpable.

      Thrill-absent.

   c) Auscultation-on auscultation first heart sound is audible, there is fixed and wide splitting of the second heart sound, there is a ejection systolic murmur in pulmonary area.
5. Percussion and auscultation of lung base-usually normal.

Why there is fixed and wide splitting of second heart sound in ASD?

Fixed-normally during inspiration blood flow increases in right heart (because during this period intrathoracic pressure decrease so venous drainage increases) and decreases in left heart and vice versa. In ASD blood flow through the right and left ventricular outflow tract is equal in both phase of the respiration, so the splitting of A2 and P2 is fixed.

Wide-normally A2 valve close first then close the P2 (normal splitting), in ASD due to increase blood flow through the right side of the heart, right ventricular emptying is delayed, so wide splitting of second heart sound.

Scanned with CamScanner

The alimentary system includes the mouth, pharynx, esophagus, stomach, small intestine, large intestine and anus. GI tract (gastrointestinal tract) consists of the stomach and intestine, but commonly alimentary tract and GI tract used synonymously. Upper GI tract extent from the mouth to ileum; and lower GI tract extent from caecum to anus. GI tract is approximately 8 meter in length. Function of the GI system is to process, absorption, passage and elimination of food. Upper GI tract digest and absorb the carbohydrate, protein and fat; lower GI tract absorbs water and electrolytes. Besides the GI tract liver, billiary system, pancreas, kidneys, genitalia will be discussed in this chapter.

Anatomically abdomen is divided into 9 regions (figure 1) by two horizontal lines (transpyloric and transtubercular line) and two vertical lines (right and left midclavicular lines). These 9 regions are very important during clinical examination, because many examinations are done according to region of the abdomen.

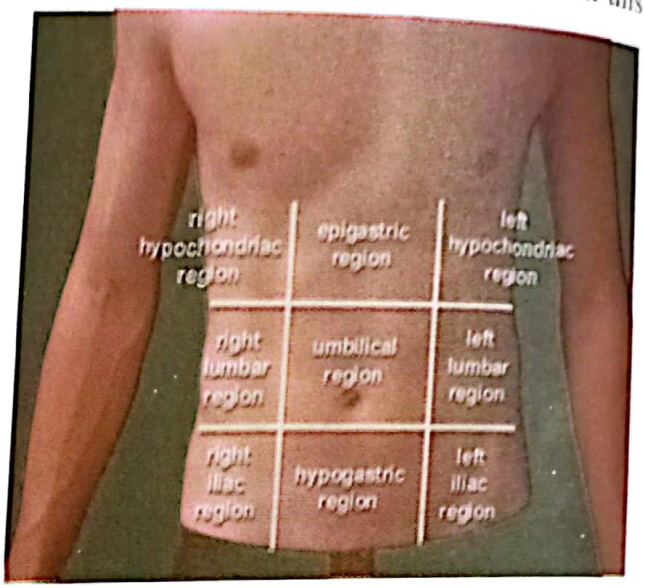

Figure 1: Anatomical region of the abdomen

Presenting complaints of the alimentary system:

1. Abdominal pain
2. Vomiting
3. Diarrhoea
4. Heart burn
5. Dyspepsia
6. Haematemesis and melaena
7. Flatulence
8. Constipation
9. Abdominal distension
10. Dysphagia
11. Weight loss

Scanned with CamScanner

Abdominal pain

There are four types of abdominal pain:

Visceral pain: Gut organs are insensitive to stimuli such as burning and cutting but are sensitive to distension, contraction, twisting and stretching. Pain from unpaired structures is usually felt in the midline.

Parietal pain: The parietal peritoneum is innervated by somatic nerves, and its involvement by inflammation, infection or neoplasia causes sharp, well-localized and lateralised pain.

Referred pain: Patient experience pain at the site of origin as well as to the referred area. For example, gallbladder pain is referred to the back or tip of the shoulder.

Psychogenic pain: Cultural, emotional and psychosocial factors influence everyone's experience of pain. In some patients, no organic cause can be found despite investigation, and psychogenic causes (depression or somatisation disorder) may be responsible.

Causes of acute abdominal pain:

A) Inflammation

1. Acute appendicitis
2. Acute cholecystitis
3. Acute pancreatitis
4. Pelvic inflammatory disease
5. Pyelonephritis
6. Intra-abdominal abscess
7. Diverticulitis

B) Perforation/rupture

1. Peptic ulcer
2. Ovarian cyst
3. Diverticular disease
4. Aortic aneurysm

C) Obustruction

1. Intestinal obstruction
2. Biliary colic
3. Ureteric colic

Scanned with CamScanner

D) Extraintestinal causes

1) Retroperitoneal-malignancy, lymphadenopathy, abscess, aortic aneurysm
2) Psychogenic- depression, anxiety, hypochondriasis, somatisation
3) Locomotor-vertebral compression, abdominal muscle strain
4) Metabolic/endocrine-diabetes mellitus, addison's disease, acute intermittent porphyria, hypercalcaemia.
5) AQDrugs/toxins-corticosteroids, lead, azathioprine, alcohol
6) Haematological–sickle cell disease, haemolytic disorders
7) Neurological-spinal cord lesion, tabes dorsalis, radiculopathy
8) Cardiovascular-inferior myocardial infarction

Common causes of acute abdominal pain:

1. Acute cholecystitis
2. Acute appendicitis
3. Perforation of hollow viscus
4. Intestinal obstruction
5. Acute pancreatitis
6. Acute pyelonephritis
7. Choledocholithiasis
8. Ureterolithiasis
9. Acute myocardial infarction (inferior MI)
10. Basal pneumonia

Common causes of chronic abdominal pain:

1. PUD (peptic ulcer disease)
2. IBS (irritable bowel syndrome)
3. IBD (inflammatory bowel disease)
4. Chronic pancreatitis
5. NUD (non-ulcer dyspepsia)
6. Psychogenic

Scanned with CamScanner

Vomiting-vomiting is the expulsion of the gastric contents via the mouth.

Nature of vomiting in intestinal obstruction at different sites of GI tract:

1. Gastric outlet obstruction-projectile vomiting of large volumes of gastric content immediately after meal that is not bile stained.
2. Obstruction distal to pylorus-produce bile stained vomiting.
3. Obstruction more distal to GI tract-more marked accompanying symptoms of abdominal distention and intestinal colic.

Causes of vomiting

A) Infections

1) Hepatitis

2) Gastroenteritis

3) UTI

B) Gastroduodenal

1) PUD

2) GOO (gastric outlet obstruction)

3) Carcinoma stomach

4) Gastroparesis (due to DM)

C) Acute abdomen

1) Acute appendicitis

2) Acute cholecystitis

3) Acute pancreatitis

4) Intestinal obstruction

D) Uraemia/ Renal failure-acute renal failure, chronic renal failure.

E) CNS disorders

1) Migraine

2) Raised intracranial pressure due to any cause

3) Meningitis

4) Vasovagal syncope, shock, fear and severe pain due to any cause e.g. renal colic, MI etc.

5) Vestibular neuritis

Scanned with CamScanner

F) Alcoholism

G) Drugs

1) NSAIDs

2) Tramadol hydrochloride

3) Pregabalin

4) Opioids-morphine, pethidine

5) Antibiotics-nitrofurantoin

6) Cytotoxic drugs-anticancer drugs

7) Digoxin

H) Metabolic/Endocrine

1) Diabetic ketoacidosis

2) Addison's disease

I) Psychogenic

1) Anorexia nervosa

2) Bulimia nervosa

J) Others

1. Pregnancy

2. Cyclical vomiting syndrome

What is rumination?

Rumination is the habitual, involuntary, subconscious regurgitation of gastric contents which are chewed and swallowed.

Scanned with CamScanner

What history should be taken in patient present with vomiting?

1. Duration of vomiting-vomiting for long duration usually during stressful condition like exam is usually normal without any underlying cause.
2. Diurnal variation-early morning vomiting occurs in pregnancy and raised intracranial pressure.
3. Vomiting preceded by nausea or not- in raised ICP and in intestinal obstruction, vomiting occur without nausea, in hepatitis vomiting occur after significant nausea.
4. Content of vomitus e.g. bile stained, blood stained or faeculant.
5. Associated symptoms-abdominal pain, abdominal distension, dyspepsia, headache etc.
6. Whether abdominal pain, abdominal distension relieved after vomiting.
7. Drug history-to determine drug cause of vomiting e.g. NSAID, tramadol, pregabalin, cytotoxic drugs etc.

Anorexia

Anorexia is loss of appetite and/or lack of interest in food. It may arise due to any infection, inflammatory condition (e.g. RA, SLE etc), malignancy, drugs (aspirin, cytotoxic drug), electrolyte imbalance (hyponatraemia) etc. However commonest cause in practice is infection e.g. UTI, RTI, TB etc.

Diarrhoea

Frequent passage of loose stool more than three times per day is called diarrhoea. Gastroenterologist define diarrhoea as the passage of more than 200 gm of stool/day.

Types of diarrhoea

1. Acute diarrhoea is defined as an episode that has an acute onset and lasts no longer than 14 days.
2. Chronic or persistent diarrhoea is defined as an episode that lasts longer than 14 days.

Causes of diarrhoea

Acute diarrhoea

A) Infectious causes

1. Infective gastroenteritis (viral, bacterial, protozoal)
2. Meningococcaemia
3. Pneumonia (especially 'atypical disease')
4. Malaria

Scanned with CamScanner

5. Pelvic inflammatory disease
6. Sepsis
7. Cl. difficile infection
8. Acute diverticulitis

B) Non-infectious causes (drugs)

1. NSAIDs
2. Antibiotics (amoxicillin)
3. PPI
4. Cytotoxic drugs
5. Heavy metals

Causes of chronic diarrhoea

1. IBS
2. Intestinal TB
3. IBD (inflammatory bowel disease)
4. Thyrotoxicosis
5. Tropical sprue
6. Parasitic infestations (e.g. Giardiasis)
7. Colorectal cancer
8. Malabsorption due to any cause
9. Laxative abuse
10. Small bowel or right sided colonic resection

Heartburn

Heart burn is a hot, burning retrosternal discomfort which radiates upwards. This occurs due to acid reflux from the stomach to oesophagus. Heart burn commonly resulting from gastro-oesophageal reflux disease (GERD).

How to differentiate heartburn from cardiac chest pain (ischaemic heart disease)?

Heart burn	Cardiac pain
Burning in character	Compressive, tightening in character
Radiates to upwards, along the position of the oesophagus	Radiates to neck, jaw, arm, back etc
Occurs in lying flat or bending forwards or stooping forwards when abdominal pressure increases	Occurs in exertion or stressful condition

Scanned with CamScanner

Reflux

Regurgitating gastric acid producing a sour taste in the mouth is called reflux.

Dyspepsia

Dyspepsia is the term used to describe symptoms such as bloating and nausea which are thought to originate from upper GIT.

Causes of dyspepsia:

A) Upper GI disorders
   1. PUD
   2. Gall stone
   3. IBS

B) Other GI disorders
   1. Pancreatic disease- chronic pancreatitis
   2. Hepatic disease- hepatitis, metastasis in liver
   3. Colonic carcinoma

C) Systemic disease
   1. Renal failure
   2. Hypercalcaemia

D) Drugs
   1. NSAIDs
   2. Iron tablet and potassium supplements
   3. Corticosteroids
   4. Digoxin

E) Others
   1. Alcohol
   2. Psychological e.g. anxiety, depression

Alarm features of dyspepsia

1. Haematemesis and/or melaena
2. Dysphagia
3. Palpable abdominal mass
4. Weight loss
5. Anaemia
6. Vomiting

Scanned with CamScanner

Haematemesis

Vomiting of blood is called haematemesis. It results from bleeding in the upper GIT (above duodenojejunal flexure).

Causes of haematemesis:

1. PUD
2. Drug induced (NSAID) gastric erosions
3. Variceal bleeding in CLD with portal hypertension
4. Carcinoma of the stomach
5. Oesophagitis
6. Vascular malformations
7. Mallory-Weiss tear
8. Bleeding diathesis e.g. anticoagulant therapy, leukaemia etc.

Melaena

Passage of altered blood (black tarry) per rectum is called melaena. It indicate bleeding above the ileocaecal valve. Melaena looks jet black, tarry and with a particularly characteristic smell. All causes of upper GI bleeding (haematemesis) cause melaena. The most common cause of melaena is peptic ulcer disease. Sometimes bleeding from the ascending colon can also cause melaena.

How to differentiate melaena from black stool?

Melaena	*Black stool*
Black and tarry	Black and hard
When water is given turned in to red colour	Not such
History of haematemesis, NSAID intake, CLD may be present	History of intake of iron tablet or iron containing food may be present
Offensive	Not offensive

Lower gastrointestinal bleeding

This may be due to haemorrhage from the colon, anal canal or small bowel.

Causes of lower gastrointestinal bleeding:

Severe acute

1. Diverticular disease
2. Angiodysplasia
3. Intestinal ischaemia
4. Meckel's diverticulum
5. Inflammatory bowel disease (rarely)

Scanned with CamScanner

Moderate, chronic/subacute

1. Anal disease, e.g. haemorrhoids, fissure
2. Inflammatory bowel disease
3. Rectal carcinoma
4. Rectal polyps
5. Angiodysplasia
6. Radiation enteritis
7. Solitary rectal ulcer

Occult gastrointestinal bleeding

Occult means that blood or its breakdown products are present in the stool but cannot be seen by the naked eye. Occult bleeding may reach 200 ml per day and may cause iron deficiency anaemia and signify serious gastrointestinal disease. Occult GI bleeding detected by occult blood testing (OBT).

Rectal bleeding

Common causes of fresh bleeding per rectum

1. Haemorrhoids
2. Rectal carcinoma
3. Rectal polyps

Flatulence

Belching, excessive or offensive flatus, abdominal distension and borborygmi (audible bowel sounds) are often called 'wind' or 'flatulence'. Between 200 ml to 2000 ml of flatus is normally passed per day. It is rarely associated with any organic GI disease but usually represents functional disturbances of the GI tract. In some patients it is clearly associated with some kinds of foods intake like vegetables. Loud borborygmi, particularly if associated with colicky discomfort, suggest small bowel obstruction or dysmotility.

Constipation

Constipation is the infrequent passage of hard stool. In clinical practice, the passage of formed stool less frequently than three times per week is taken as abnormal bowel frequency.

Scanned with CamScanner

Causes of constipation

Gastrointestinal disorders

A) Dietary-lack of fibre and/or fluid intake

B) Motility disorders

1. Slow-transit constipation
2. Irritable bowel syndrome
3. Drugs (see below)
4. Chronic intestinal pseudo-obstruction

C) Structural disorders

1. Colonic carcinoma
2. Diverticular disease
3. Hirschsprung's disease

Non-gastrointestinal disorders

A) Drugs

1. Iron supplements
2. Aluminium containing antacids
3. Anticholinergics (e.g. TCA-amitriptyline)
4. Calcium antagonists (e.g. verapamil)
5. Opioids

B) Neurological

1. Multiple sclerosis
2. Spinal cord lesions
3. Stroke patient
4. Parkinsonism

C) Metabolic/endocrine

1. Diabetes mellitus
2. Hypothyroidism
3. Hypercalcaemia
4. Pregnancy

Scanned with CamScanner

D) Others

1. Any serious illness with immobility, especially in the elderly
2. Depression

Common causes of constipation

1. Low fluid and fiber containing diet
2. Immobility (bed ridden patient like stroke patient)
3. Drugs-iron, amitriptyline
4. Intestinal obstruction
5. Hypothyroidism

What history should be taken in patient present with constipation?

1. Onset-neonatal onset suggests Hirschsprung's disease, while a recent change in bowel activity in middle age should raise the suspicion of organic disorders such as colonic carcinoma.
2. Duration-constipation of recent onset is much more important than long standing constipation, the later may be due to dietary habits, (lack of intake of fiber containing diet).
3. Frequency of bowel movement.
4. Associated features-abdominal pain, anal pain on defecation or rectal bleeding, neurological problems (stroke, spinal cord compression), features of intestinal obstruction etc.
5. Any drug history e.g. opiates, iron, anticholinergic drugs, aluminium containing antacids.

Tenesmus

Tenesmus is the sensation of needing to defecate, although the rectum is empty and suggests rectal inflammation or tumour.

Abdominal distension

Abdominal distension gradually occurs over months to years is usually due to obesity. Fluctuating abdominal distension that develops over the day and resolves over night is usually due to functional bowel disorders (commonly irritable bowel syndrome). Abdominal distension associtaed with weight loss, fever usually indicate underlying abdominal diseases.

Causes of abdominal distension

Factor	Consider
Fat	Obesity
Flatus	Pseudo-obstruction, obstruction.
Faeces	Subacute obstruction, constipation
Fluid	Ascites, tumour (usually ovarian), distended bladder
Fetus	Check date of the last menstrual period
Functional	Bloating often associated with irritable bowel syndrome (IBS)

Scanned with CamScanner

Dysphagia-dysphagia is defined as difficulty in swallowing. Whereas painful swallowing is called odynophagia, which occurs in GERD or esophageal candidiasis. Sometimes anxious people feel a lump in the throat without any organic cause, this is called globus sensation.

Dysphagia is of two types:

1. Oropharyngeal dysphagia-dysphagia occurs at the initiation of swallowing at the pharynx and upper esophageal sphincter. Oropharyngeal dysphagia is usually due to neurological diseases, in which there is greater difficulty in swallowing liquids than solids.
2. Esophageal dysphagia occurs due to obstructing the lumen or by affecting the motility. Patients with esophageal dysphagia complain of food sticking after swallowing.

Causes of dysphagia:

A) Oral

-Painful mouth ulcer

-Tonsillitis, pharyngitis, peritonsillar abscess.

B) Neurological

-Stroke

-Bulbar palsy, pseudobulbar palsy

C) Neuromuscular

-Achalasia cardia

-Myasthenia gravis

-Oesophageal dysmotility

D) Mechanical

-Oesophageal cancer

-Peptic oesophagitis

-Systemic sclerosis

-Other benign stricture e.g. after prolonged nasogastric intubation, following ingestion of corrosives poison etc.

-Extrinsic compression e.g. lung cancer

Scanned with CamScanner

What history should be taken in a patient present with dysphagia?

1. Duration-long duration of dysphagia may be due to benign causes e.g. motility disorder like achalasia, peptic oesophagitis etc. Short duration of progressive dysphagia is usually from carcinoma of the oesophagus.
2. Types- whether dysphagia occurs at the initiation of swallowing or after swallowing. Dysphagia at the initiation of swallowing is oropharyngeal (neurological), dysphagia after swallowing is oesophageal dysphagia.
3. Is the dysphagia is for solid or liquid or both? Liquid dysphagia usually occur in neurological diseases.
4. Whether the dysphagia is painful or painless? Painful dysphagia occurs in GERD, oesophageal candidiasis.
5. Is the dysphagia intermittent or progressive? Progressive dysphagia occurs in carcinoma oesophagus.
6. Whether there is any history of heart burn? Commonly found in GERD.
7. Associated symptoms like cough and regurgitation occurs in oro-pharyngeal (neurological) dysphagia, tightening of the skin, history of raynaud's phenomenon (systemic sclerosis).

Weight loss

Weight loss may be 'physiological' due to dieting, exercise, starvation, or decrease nutritional intake which usually accompanies in old age. Alternatively, weight loss may signify disease and in this case a loss of more than 3 kg over 6 months or loss of 10% of body weight in 6 months is significant.

Causes of weight loss:

Gastrointestinal

1. Poor dentition
2. Any cause of oral pain
3. Dysphagia
4. Malabsorption
5. IBD
6. Cirrhosis of liver
7. Malignancy at any site
8. Chronic infection e.g. tuberculosis

Scanned with CamScanner

Respiratory

1. Pulmonary tuberculosis
2. Bronchial carcinoma
3. COPD
4. Bronchiectassis
5. Empyema thoracics

Cardiovascular

1. CCF
2. Infective endocarditis

Rheumatological

1. Rheumatoid arthritis
2. SLE (Systemic lupus erythematosus)
3. MCTD (Mixed connective tissue disorder)
4. JIA (Juvenile idiopathic arthritis)
5. Vasculitis due to any cause

Chronic infection

1. Tuberculosis
2. HIV infection
3. Brucellosis
4. Gut infection

Endocrine

1. Diabetes mellitus
2. Thyrotoxicosis
3. Addison's disease
4. Diabetes incipidus
5. Hypopituitarism

Renal

1. Chronic renal failure
2. Renal malignancy

Neurodegenerative

1. Parkinsonism
2. Motor Neuron disease
3. Dementia

Scanned with CamScanner

Psychosocial

1. Deprivation
2. Starvation
3. Eating disorder
4. Depression
5. Chronic pain or sleep deprivation

Common causes of extreme weight loss:

1. Thyrotoxicosis
2. Type I DM
3. Pulmonary tuberculosis
4. Malignancy
5. Malabsorption syndrome

Some easily overlooked causes of unexplained weight loss

1. Diabetes mellitus/hyperthyroidism
2. Existing conditions (severe chronic obstructive pulmonary disease, cardiac failure)
3. Occult malignancy (e.g. proximal colon, renal, lymphoma)
4. Chronic pain or sleep deprivation
5. Depression/anxiety
6. Psychosocial deprivation/malnutrition in the elderly
7. Anorexia nervosa in atypical groups, e.g. young men
8. Rare endocrine disorders, e.g. Addison's disease, panhypopituitarism

Clinical examination of alimentary system

Examination of alimentary system consists of

1. Examination of mouth and oral cavity and
2. Abdomen

Examination of mouth and oral cavity-following points to be noted during examination of mouth and oral cavity

Scanned with CamScanner

1. Lips-in lips we usually look for angular stomatitis, presence of herpes labialis etc. Angular stomatitis is inflammatory condition affecting the corners of the mouth or oral commissures (figure 2). Angular stomatitis are usually multifactorial, it may occur due to

   i) Candidal infection

   ii) Bacterial infection (staphylococcus, streptococcus etc)

   iii) Vitamin B complex and iron deficiency etc.

   (However presence of angular stomatitis may need to search underlying malabsorption syndrome.)

2. Gum-presence of gum hypertrophy, gingivitis, gum abscess should be noted carefully. Gum hypertrophy may be present in poor oral hygiene, dental carries and acute leukaemia.

3. Teeth-number, alignment and discoloration of teeth should be noted. Discoloration of teeth may occur after tetracycline intake. Large, malaligned teeth may be seen in acromegaly.

4. Tonsil-may be enlarged, congested and pus point present in case of acute tonsillitis.

5. Tongue-this may provide many information like anaemia, jaundice, cyanosis, dehydration, vitamin deficiency; coated tongue occurs in enteric fever, whitish coated tongue occurs in fungal infection (candidiasis).

-Macroglossia-enlargement of tongue. Causes are- acromegaly, hypothyroidism, down's syndrome and amyloidosis.

-Microglossia-small tongue. Occurs in MND (motor neuron disease), bulbar and pseudobulbar palsy.

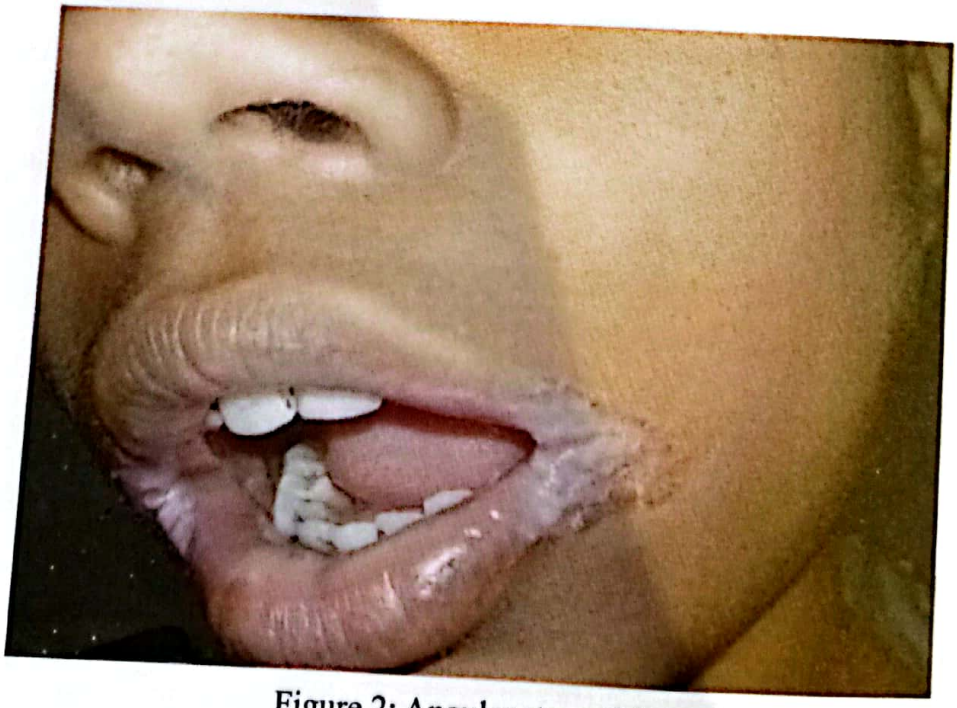

Figure 2: Angular stomatitis

Scanned with CamScanner

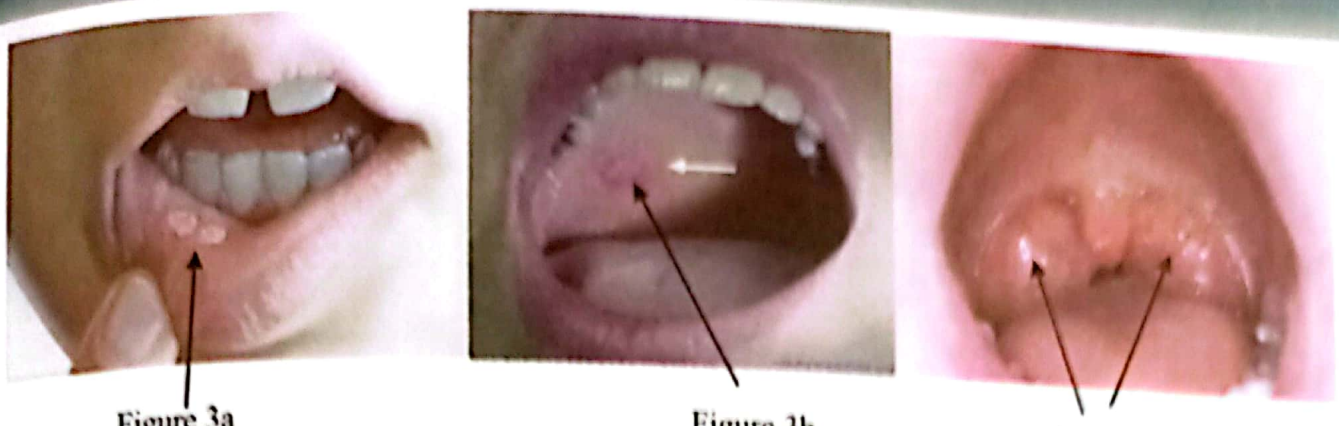

Figure 3a Figure 3b Figure 3c

Figure 3: showing apthous ulcer (1a), ulcer in hard palate in SLE patient (1b) and bilateral enlargement of the tonsils (1c).

6. Oral mucosa-ulcer may be present in any sites of the mouth. Ulcer may be apthous, viral, SLE or due to malignancy. Black pigmentation may indicate adrenal insufficiency.
7. Palate –any ulceration should be noted. Ulcer or erosion in hard palate usually occurs in SLE.

Steps of examination of mouth and oral cavity

1. Greetings and consent.
2. Patient should be in sitting position.
3. First look at and around the mouth for presence of angular stomatitis.
4. Open the mouth, look at the teeth, its colour & alignment.
5. Carefully hold and evert the lips (to see gum and any hidden aphthous ulcer).
6. Ask the patient-please open your mouth widely, then carefully look inside the oral cavity with torch light, it is better to use a tongue depressor during examination to see the oro-pharynx and tonsils (figure 4).
7. Thanks the patient.

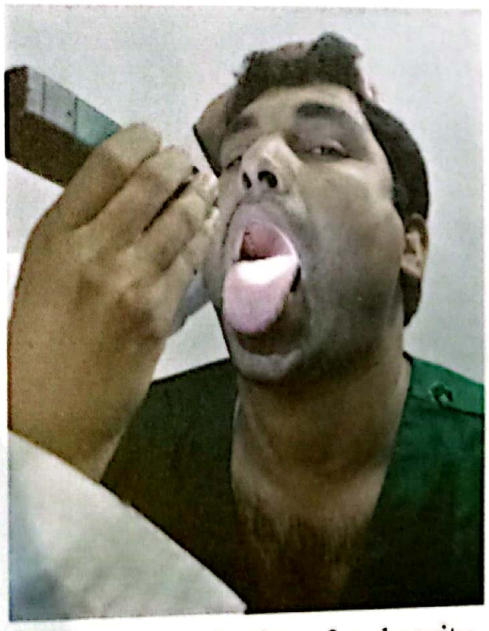

Figure 4: Examination of oral cavity

Scanned with CamScanner

Normal findings of oral cavity examination- there is no angular stomatitis, gum hypertrophy, no ulcer, no pigmentation, teeth are normal in number, colour & alignment, tonsils are normal, there is no congestion and pus point.

Presentation-examination of oral cavity is normal.

Examination of the abdomen includes

1. Inspection
2. Palpation
3. Percussion and
4. Auscultation.

Inspection-during inspection following points to be noted:

1. Shape of the abdomen
2. Flanks
3. Umbilicus-position, slit (inverted or everted).
4. Visible peristalsis
5. Visible epigastric pulsation
6. Movement on respiration
7. Visible lump/swelling
8. Engorged vein
9. Visible cough impulse
10. Scar mark
11. Skin condition
12. Others-striae, pigmentation etc.

Figure 5: Ascites, noted flanks full, umbilicus everted, engorged vein in upper abdomen

Shape of the abdomen

During inspection- shape of the abdomen provide important information. Shape of the abdomen is usually normal. But there may be generalized or localized swelling of the abdomen.

Causes of generalized swelling of the abdomen:

1. Fluid (ascites)
2. Intestinal obstruction
3. Large ovarian tumour
4. Fetus (pregnancy)
5. Gross hydronephrosis of the both kidneys

Scanned with CamScanner

Causes of localized swelling of the abdomen

Site of the localized swelling should be noted. Localized swelling usually implies swelling from the underlying structure. Examples are given below-

Causes of swelling of epigastric region

1. Carcinoma of stomach
2. Enlarged left lobe of the liver (due to HCC, liver abscess etc)
3. Carcinoma head of the pancreas
4. Pancreatic pseudocyst
5. Carcinoma of transverse colon

Causes of swelling in right iliac fossa

1. Appendicular lump
2. Ileo-caecal tuberculosis
3. Carcinoma of caecum
4. Ovarian tumour
5. Crohn's disease

Flanks

The side of the body between the pelvis or hip and the last rib is called flank. Normally flanks are not full. Fullness of the flank occurs in ascites because it is the dependant part of the abdomen.

Umbilicus-followings points to be noted while examining umbilicus

1. Position of the umbilicus (normally centrally placed).
2. Inverted or everted (normally umbilicus is inverted, in umbilical hernia, ascites and large ovarian tumour umbilicus may be everted).
3. Slit (in ascites umbilicus is everted with transverse slit, vertical slit occurs in pregnancy and large ovarian tumour).

Presentation (normal findings)-umbilicus is centrally placed, inverted with normal slit.

Visible peristalsis

Peristalsis is the muscular contractions of the digestive tract that moves the bolus of food down to the stomach. Normally peristalsis is not visible. But in some condition like gastric outlet obstruction this may be visible. It should be examined by sitting beside the patient's bed and looking at the abdomen in profile view for 10 seconds, while asking the patient to hold the breath. When visible peristalsis will be present-look the direction. If the visible peristalsis moves from left to right side of the abdomen then this is due to small intestine obstruction. If the visible peristalsis is from right to left side of the abdomen then this is due to large intestine obstruction.

Scanned with CamScanner

Visible pulsation

Any visible pulsation in the abdomen particularly in upper abdomen should be noted. This should be examined by sitting beside the patient's bed while the patient hold his breath for few seconds and looking at the epigastric region.

Causes of visible pulsation in upper abdomen

1. Right ventricular hypertrophy
2. Abdominal aortic aneurysm
3. Normally in lean thin person.

Movement on respiration

Normal respiratory movement is abdomino- thoracic in case of male and thoraco-abdominal in female. Look carefully while examining the abdomen. Purely thoracic respiratory movement resulting from generalized peritonitis, on the other hand purely abdominal respiratory movement occurs in bilateral pleurisy.

Figure 6: Inspection of the abdomen for visible peristalsis and visible pulsation.

Steps of examination of visible peristalsis, visible pulsation and respiratory movement

1. Greetings and consent.
2. Patient should be in supine position with a single pillow under the head.
3. Proper exposure of the abdomen from mid chest to the symphysis pubis.
4. Sit besides the patient's bed and carefully look over the upper part of the abdomen and chest (see respiratory movement) (figure 6).
5. Ask the patient to hold the breath and look over the epigastric region for visible pulsation and visible peristalsis. If visible peristalsis is present then identify its direction (from left to right or right to left).
6. Re-clothing and thank the patient.

Visible lump

Any visible lump and its location should be noted during inspection. Location of the lump usually indicates it is originated from the underlying structures. Example-visible lump in right upper abdomen usually indicates it may be from liver, gall bladder or right sided colon.

Scanned with CamScanner

Engorged vein

Normally engorged vein is not present in the abdomen. Carefully look for any engorged vein in the abdomen and if present direction of blood flow should be noted. Normal direction of blood flow is away from the umbilicus. In portal hypertension, exacerbation of the normal flow occurs. In IVC obstruction, direction of blood flow is below upwards.

How to determine direction of blood flow in engorged vein?

1. Place index finger of both hands side by side over a vein and move the fingers away from each other.

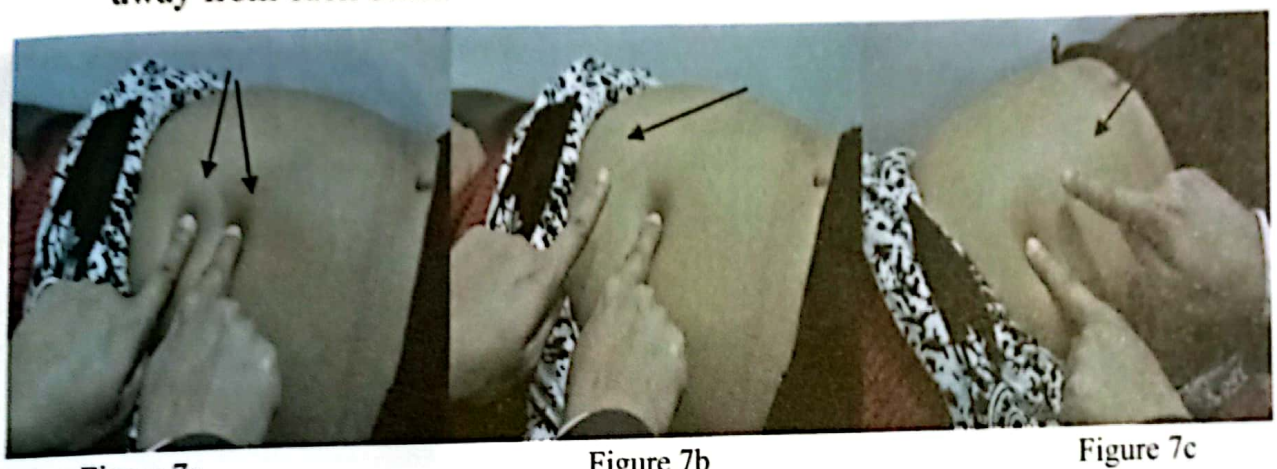

Figure 7a Figure 7b Figure 7c

Figure 7: Examination of direction of blood flow in engorged vein.

2. Release one finger (Figure 7b) and see time of refill, repeat with other finger (figure 7c). Venous return is in the direction of faster filling.

Scar mark

Any scar mark in the abdomen should be noted. Scar mark will indicate any previous surgery. Example-right subcostal incision usually indicates cholecystectomy.



Figure 8: Showing right paramedian scar (indicates cholecystectomy).

Skin condition

Any abdominal discoloration should be noted.

Striae

Striae atropica or gravidarum are white or pink wrinkled linear marks on the abdominal skin. White striae usually occurs following pregnancy, obesity and pink striae usually occurs in Cushing syndrome. They are produced by gross stretching of the skin with ruptures of the elastic fibres and indicates a recent change in size of the abdomen that occurs in pregnancy, ascites, wasting disease and severe dieting.

Scanned with CamScanner

Steps of inspection of the abdomen

1. Greetings and consent.
2. Position and exposure- patient should be in supine position; head should be supported by single comfortable pillow. Proper exposure of the abdomen from mid chest to the symphysis pubis.
3. Stand besides the bed and look carefully the umbilicus, flanks, engorged vein, visible lump, scar mark etc.

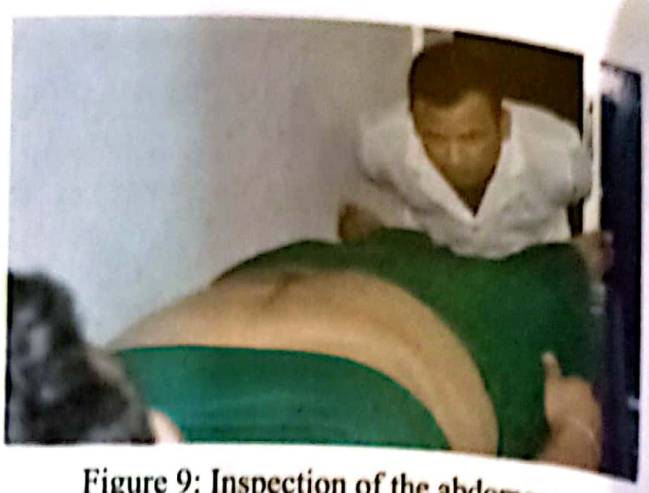

Figure 9: Inspection of the abdomen from foot end of the patient.

4. Sit besides the patient's bed and carefully look over the upper part of the abdomen and chest (see respiratory movement). Ask the patient to hold his breath and look over the epigastric region for visible pulsation and visible peristalsis. If visible peristalsis is present then identify its direction (from left to right or right to left).
5. Go to the foot end of the patient then again inspect the abdomen (figure 9).
6. Re-clothing and thank the patient.

Presentation of the inspection findings (normal finding)-On inspection shape of the abdomen is normal, flanks are not full, umbilicus is central in position, inverted and normal slit, there is no visible lump, engorged vein, scar mark, visible pulsation, visible peristalsis and striae, respiratory movement is abdominothoracic.

Palpation of the abdomen

1. Superficial palpation
2. Deep palpation

Superficial palpation

In which abdominal wall is depressed approximately 1 cm. Points to be noted in superficial palpation are:

1. Temperature
2. Superficial tenderness
3. Superficial lump
4. Muscle rigidity
5. Direction of blood flow in engorged vein (if any).

Scanned with CamScanner

Superficial palpation should be performed according to the anatomical region (9 regions) of the abdomen.

Steps of superficial palpation

1. Greetings and consent.
2. Position - patient should be in supine position; head should be supported by a single comfortable pillow.
3. Proper exposure of the abdomen from mid chest to the symphysis pubis.
4. Ask the patient to relax the abdomen.
5. Ask the patient-do you have pain in abdomen? if yes, what is the location of the pain? The site of the pain should be examined last (otherwise patient will not co-operate to examine due to pain).

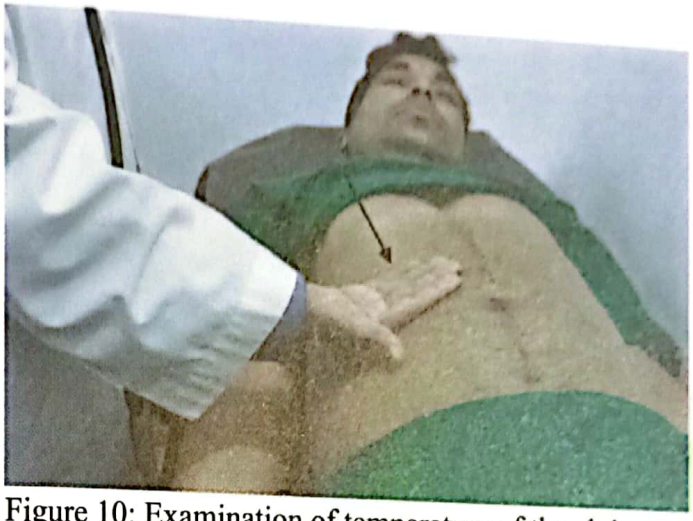

Figure 10: Examination of temperature of the abdomen.

6. First feel for the temperature of the abdomen (figure 10) by the dorsum of the palm and compare with forehead. Temperature should be examined in all the anatomical regions of the abdomen rather than in one site, because in case of localized infections only local temperature will be raised (e.g. in acute appendicitis temperature will be raised in right iliac fossa). In generalized peritonitis temperature will be raised in whole abdomen.

Figure 10a Figure 10b

Figure 10: Supeficial palpation of the abdomen (figure 10a left iliac fossa and figure 10b right iliac fossa)

Scanned with CamScanner

7. If patient do not have any abdominal pain then start from the left iliac fossa (figure 8a) and move anticlock wise to cover all the anatomical regions. During palpation the wrist and forearm should be in the same horizontal plane, make movement of the MCP joint to palpate the abdomen (don't poke the abdomen), look at the patient's face to see any change of facial expression due to pain. Carefully feel for any tenderness, superficial lump and rigidity.
8. Check direction of blood flow in engorged vein, if any.
9. Re-clothing and thank the patient.

Deep palpation

Points to be noted in deep palpation

1. Deep tenderness
2. Deep seated mass
3. Organ palpation

Similar to superficial palpation, start in the left iliac fossa of the abdomen, using slightly deeper palpation and repeat for each anatomical region of the abdomen for tenderness and deep seated mass. Then palpate the abdominal organs, in the following order

1. Palpation of the left kidney
2. Palpation of the spleen
3. Palpation of the right kidney
4. Palpation of the liver
5. Palpation of the urinary bladder
6. Palpation of the para-aortic lymph nodes
7. Palpate if there is any abdominal lump
8. Examine the external genitalia

Most of the senior clinicians prefer to examine the liver first, then spleen, kidneys and others. (Due to liver and spleen are more important clinically than other abdominal organs).

In case of ascites organ palpation should be done by deepening method but ascites detected by shifting dullness and fluid thrill, these are done later to palpation of abdominal organs. How this should be co-related during clinical examination?

Answer-organ palpation should be done by deepening method in case of huge ascites and huge ascites usually can be diagnosed by inspection of the abdomen. Organ palpation can be done normally in mild/minimal ascites.

Scanned with CamScanner

Kidney

The kidneys are located in the abdominal cavity, retroperitoneally. There are two kidneys. The right kidney is slightly lower than the left kidney due to larger right lobe of the liver. Each kidney is approximately about 9-12 cm in length. Left kidney may be palpable normally in lean thin person.

Steps of palpation of left kidney

1. Greetings and consent.
2. Position - patient should be in supine position; head should be supported by a single comfortable pillow.
3. Proper exposure of the abdomen from mid chest to the symphysis pubis.
4. Ask the patient to relax the abdomen, turn the patient's face to the left side and ask to take deep breath.

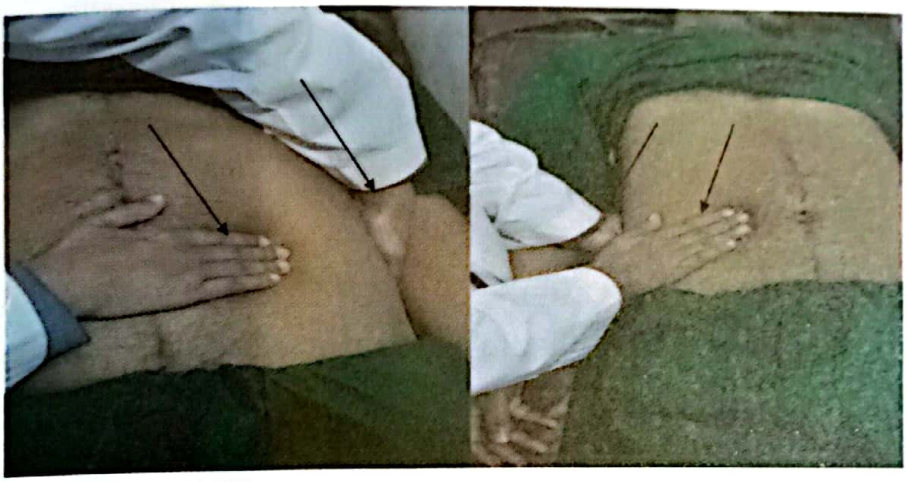

Figure 11a Figure 11b

Figure 11: Palpation of the kidney, note the position of the left and right hand during palpation of left (figure 11a) and right (figure 11b) kidney.

5. Place the palm of the left hand posteriorly in the left loin and right hand anteriorly in the left lumbar region (usually 2.5 cm above and lateral to the umbilicus) (figure 11a & 11b).
6. Ask the patient to take deep inspiration, press the left hand forwards and right hand backward, upwards, and inwards.
7. If kidney is palpable, it is felt as a rounded firm swelling between right and left hand.
8. Re-clothing and thank the patient.

Steps of palpation of right kidney

Repeat the same procedure of palpation of left kidney.

Scanned with CamScanner

What is balloting of the kidney?

When kidney is palpable, if it can be pushed from one hand to other, then it is called balloting.

What are the causes of enlargement of kidney?

Unilateral

1. Unilateral hydronephrosis due to ureteric obstruction
2. RCC (renal cell carcinoma)

Bilateral

1. PKD (polycystic kidney disease)
2. Bilateral hydronephrosis due to any cause (commonly bladder outflow obstruction due to BPH & stricture urethera in male and genital prolapse in female).

Presentation of normal finding- on palpation both kidneys are not palpable.

Presentation of abnormal finding- on palpation left kidney is palpable but it is not ballotable.

Spleen

Spleen is the largest lymphatic organ in the human body, lies under the diaphragm in the left upper part of the abdomen at the level between 9th and 11th ribs. The spleen typically weighs 150 grams in a typical adult and spans about 11 cm vertically in its longest dimension. Moderate splenomegaly if spleen size in between 11-20 cm and severe or huge splenomegaly if it is more than 20 cm. Like the left kidney, the spleen is not normally palpable. It has to be enlarged two to three times its usual size before becoming palpable and then is felt beneath the left costal margin. Enlargement takes place in superior and posterior directions first, and then the direction of further enlargement is downwards and towards the right iliac fossa.

Steps of palpation of spleen

1. Greetings and consent.
1. Position - patient should be in supine position; head should be supported by a single comfortable pillow.
2. Proper exposure of the abdomen from mid chest to the symphysis pubis.
3. Ask the patient to relax the abdomen, turn the patient's face to the left side and to ask to take deep breath.
4. Place the flat of the left hand over the left lowermost ribcage postero-laterally and push forwards (figure 12a).

Scanned with CamScanner

Figure 12a Figure 12b

Figure 12: Palpation of the spleen, note the placement of the hands (figure 12a) and right lateral position of the patient (12b) with straight right lower limb and left knee joint flexed.

5. Place the right hand in right iliac fossa and ask the patient to take deep breath in and out; press gently during inspiration and proceed towards the left costal margin in expiration.
6. If spleen is not palpable after reaching left costal margin, turn the patient in right lateral position, keep patient's left hand in his right shoulder, right leg should be straight and left leg should be flexed (figure 12b). Palpate for the spleen below the left costal margin. (If spleen is still not palpable then we can say spleen is not enlarged/palpable).
7. Re-clothing and thank the patient.

If spleen is palpable then following points to be noted

1. Size-locate the margin of the spleen, then measure from the left costal margin, along the anterior axillary line towards the right iliac fossa.
2. Spleenic notch-this differentiates spleen from left kidney or other abdominal mass.
3. Insinuation test-done by placing fingers under the left costal margin. If insinuation test is not possible (that is finger cannot be introduced under the left costal margin) then spleen is palpable and vice versa. This test differentiate spleen from the left kidney.
4. Percussion over the spleen- dull.
5. Splenic rub-it is a scratchy to-and-fro sound heard with respiration i.e. during movement of the spleen. if the patient hold his breath, the rub stops. It usually present in splenic infarction. For splenic rub-place the diaphragm of stethoscope over the spleen, if rub present, then ask the patient to hold his breath. If it is splenic rub then it disappear when patient hold his breath.

Scanned with CamScanner

Presentation of normal finding- on palpation spleen is not palpable.

Presentation of abnormal finding- on palpation spleen is palpable, 5 cm from left costal margin along the left anterior axillary line, there is not splenic bruit or rub.

How to differentiates palpable spleen from left kidney?

Points	Spleen	Left kidney
1. Direction of enlargement	1. Towards right iliac fossa	1. Downwards
2. Notch	2. Present	2. Absent
3. Get above the swelling	3. Not possible	3. Possible
4. Insinuation	4. Not Possible	4. Possible
5. Percussion	5. Dull	5. Resonant

Causes of splenomegaly:

1. Hereditary haemolytic anaemia (thalassemia)
2. Malaria
3. Kala-azar
4. Acute leukaemia
5. Lymphoma
6. Portal hypertension due to any causes
7. Typhoid fever
8. Infectious mononucleosis
9. Infective endocarditis
10. Disseminated tuberculosis
11. Acute viral hepatitis (hepatitis B)

Scanned with CamScanner

Causes of just palpable spleen:

1. Typhoid fever
2. Infectious mononecleosis
3. SLE
4. Disseminated tuberculosis
5. Infective endocarditis
6. Sarcoidosis
7. Polycythaemia rubra vera

Causes of huge splenomegaly

1. CML (chronic myeloid leukaemia)
2. Chronic malaria
3. Chronic kala-azar
4. Myelofibrosis

Liver

Liver is located in the right upper quadrant of the abdominal cavity. It is both the largest internal organ (the skin being the largest organ overall) and the largest gland in the human body. Liver palpation can be done by preferred method and conventional or alternative method (less accurate that preferred method).

Preferred method

Steps of examination

1. Sit on the couch beside the patient.

2. Place both hands side-by-side flat on the abdomen in the right subcostal region lateral to the rectus with the fingers pointing towards the ribs.

3. If resistance is encountered, move the hands further down until this resistance disappears.

4. Exert gentle pressure and ask the patient to breathe in deeply. Concentrate on whether the edge of the liver can be felt moving downwards and under the examining hand.

5. Repeat this manoeuvre working from lateral to medial regions to trace the liver edge as it passes upwards to cross from right hypochondrium to epigastrium.

Scanned with CamScanner

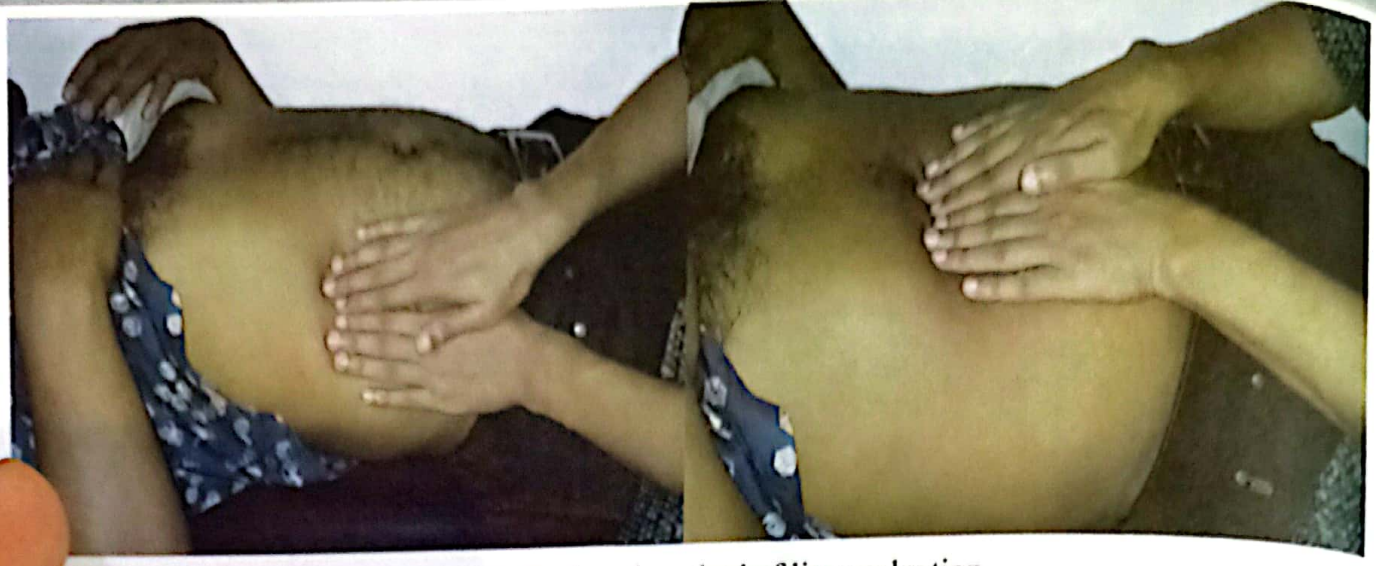

Figure 13: Preferred method of liver palpation

Conventional method of liver palpation

Steps of examination

1. Greetings and consent.

1. Position - patient should be in supine position, head should be supported by a single comfortable pillow.

2. Proper exposure of the abdomen from mid chest to the symphysis pubis.

3. Ask the patient to relax the abdomen, turn the patient's face to the left side and ask to take deep breath.

4. Sit on the toll beside the patients bed (figure 14a), (if unavailable kneel down beside the patient's bed)

5. Place your right hand in the right iliac fossa, parallel to the right costal margin, and ask the patient to take deep breath (figure 14b). Press the abdomen during inspiration by slightly flexing the MCP joint (avoid poking of the fingers) and proceed forward during expiration.

Figure 14a Figure 14b Figure 14c

Figure 14: Palpation of the liver by sitting in a toll (14a), by sitting beside the patient (14b), percussion of the upper border of the liver dullness (14c).

Scanned with CamScanner

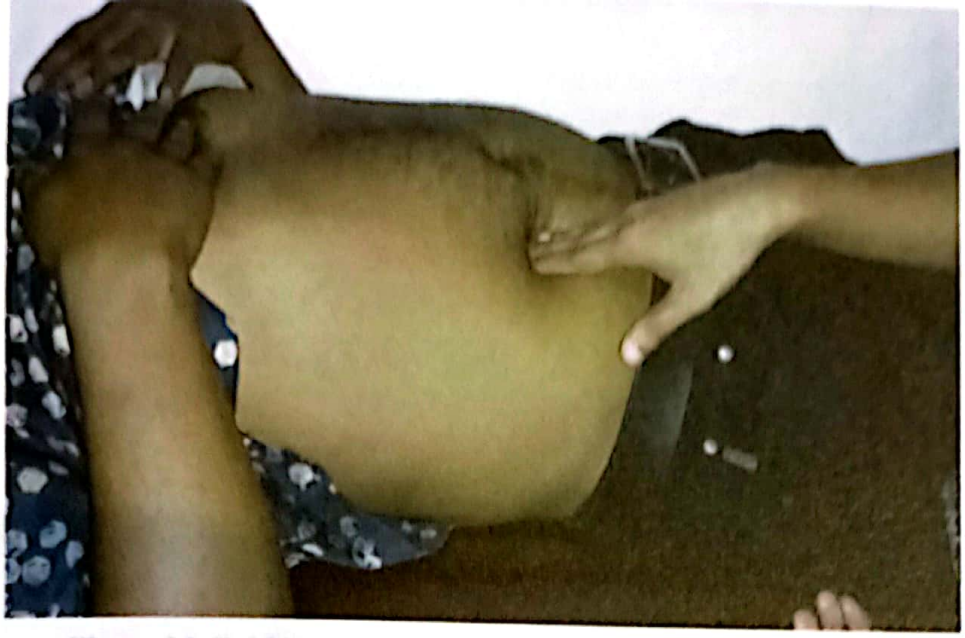

Figure 15: Poking of fingers (must be avoided during palpation)

6. Continued the above procedure up to palpate the lower border of the right lobe of the liver.
7. Put your hand in the midline and repeat the above steps till you palpate the lower border of the left lobe of the liver.
8. Percuss from the right 2nd intercostal space to downwards to find the upper border of the liver dullness (figure 11c).
9. Re-clothing and thank the patient.

Points to be noted if liver is palpable

1. Size-measure the lower border of the liver from the right costal margin along the right mid clavicular line.
2. Margin-sharp or rounded.
3. Surface- smooth or rough. Smooth surface of liver found in acute viral hepatitis, CCF. Rough surface found in malignancy of liver (primary or secondary).
4. Consistency- soft, firm or hard. Soft consistency occurs in acute viral hepatitis, liver abscess, CCF; hard consistency of liver occurs in malignancy of the liver (primary or secondary), firm liver occurs in other cases like leukemia, lymphoma, malaria, kala-azar.
5. Tenderness- present or not. Tenderness present in acute hepatitis (viral or drug induced), CCF, liver abscess, hepatocellular carcinoma (HCC).

Scanned with CamScanner

6. Upper border of the liver dullness- start percussion from the right 2nd intercostal space to downwards to determine the upper border of the liver. This will help to diagnose the pneumoperitoneum (liver dullness will be absent) and determination of liver span.

7. Liver span- liver span is the distance between the lower border of the liver in the mid-clavicular line obtained by palpation, and the upper border of the liver in the mid-clavicular line detected by percussion. Normal liver span is 6–12 cm.

8. Bruit or rub-bruit is an audible vascular sound associated with turbulent blood flow. The liver should be auscultated using moderately firm pressure with either the bell or the diaphragm of the stethoscope. An arterial bruit may be confined to systole or systolic with extension into diastole or be continuous.

Causes of hepatic bruit:

1. Hepatoma/HCC: commonest cause due to increased vascularity
2. Acute alcoholic hepatitis
3. Arterio-venous fistula in liver(due to trauma or iatorgenic in liver biopsy)
4. Haemangioma

Causes of hepatic rub:

1. Secondary deposit in the liver
2. Trauma
3. Hepatic infarction
4. Perihepatitis in pelvic inflammatory disease (Gonococcal or chlamydial in female called Fitz-Hugh-Curtis syndrome)

Why percussion to be done to find out upper border of the liver dullness if liver is not palpable?

Liver dullness will be absent in case of perforation of hollow viscus (pneumoperitoneum), so upper border of the liver dullness to be examined routinely.

Presentation of normal finding- on palpation liver is not palpable.

Presentation of abnormal finding- on palpation liver is palpable, 5 cm from right costal margin along the right midclavicular line, margin is sharp, surface is smooth, non-tender, firm in consistency, upper border of the liver dullness is in right fifth intercostal space, liver span is 17 cm and there is no hepatic bruit or rub.

Scanned with CamScanner

Causes of hepatomegaly

Enlarged tender liver:

1. Acute viral hepatitis
2. CCF
3. Liver abscess
4. Hepatocellular carcinoma

Enlarged non-tender liver:

1. Acute leukaemia
2. Lymphoma
3. Malaria
4. Kala-azar
5. Heriditary haemolytic anaemia (thalassemia)

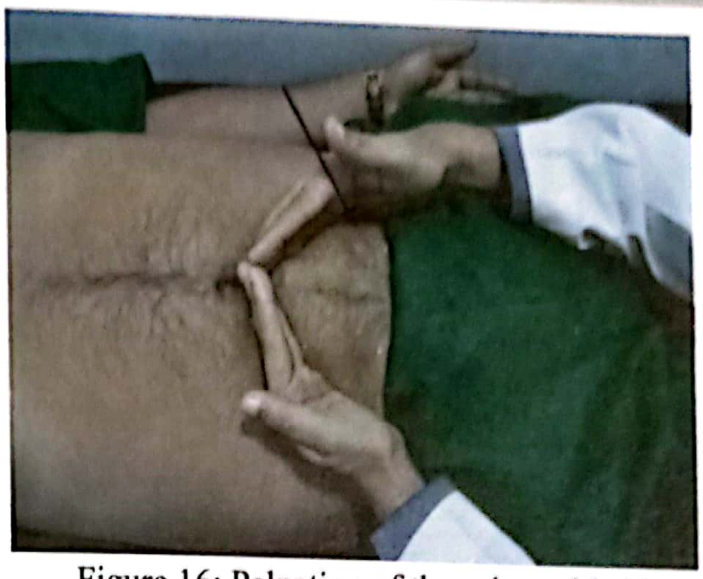

Figure 16: Palpation of the urinary bladder.

Steps of examination of urinary bladder-normally urinary bladder is not palpable, it is palpable when it is full (commonly due to urinary retention)

1. Greetings and consent.
2. Position and exposure- patient should be in supine position; head should be supported by a single comfortable pillow.
3. Place the ulnar border of the both hand in the suprapubic region along the lateral border of the urinary bladder and move downwards (figure 16). Give firm pressure if it is palpable, while asking the patient whether there is any urge of micturition.
4. If urinary bladder is palpable then percuss over it (dull in percussion).
5. Reclothing and thank the patient.

Palpable urinary bladder should be differentiated from fibroid uterus, gravid uterus and ovarian cyst in case of female.

Urinary bladder	Fibroid uterus	Gravid uterus	Ovarian cyst
Symmetrically placed in the suprapubic region beneath the umbilicus.	Place in supra pubic region, centrally.	Place in supra pubic region, centrally.	Place ecentrically right or left side.
Don't move side to side.	Move side to side.	Move side to side.	May be mobile.
Urge of micturition on pressure.	No urge of micturition on pressure.	No urge of micturition on pressure.	No urge of micturition on pressure.

Scanned with CamScanner

Steps of examination of para aortic lymph nodes-paraaortic lymph nodes are not normally palpable, palpable only when significantly enlarged.

1. Greetings and consent
2. Position and exposure-patient should be in supine position; head should be supported by a single comfortable pillow.
3. Place the pulp of the fingers of the both hands in the epigastric region along the lateral border of the aorta (figure 17). Paraaortic lymph nodes felt as rounded, firm, often confluent, fixed masses in the umbilical region and epigastrium along the lateral border of the aorta.
4. Re-clothing and thank the patient.

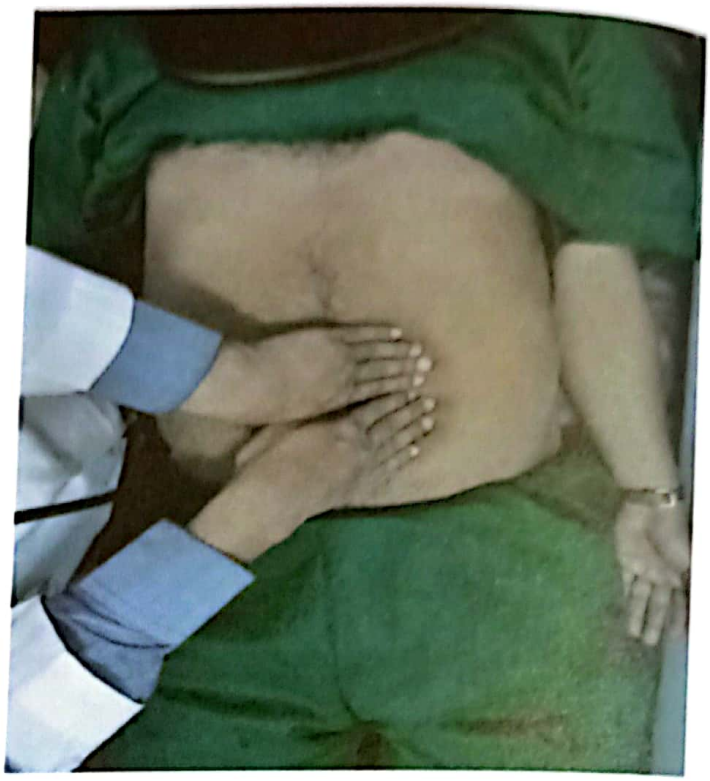

Figure 17: Palpation of paraaortic lymph nodes

Causes of enlargement of paraaortic lymphnode:

1. Abdominal TB
2. Lymphoma
3. Abdominal malignancy with metastasis

How to examine a lump of the abdomen?

When an abdominal mass is present, first determine whether it is normal abdominal structure or the swelling is originated from liver, spleen, kidney, urinary blader, aorta, intestine or para aortic lymph nodes. The purpose of examination of an abdominal lump is to determine its site of origin and pathological nature. When an abdominal mass is present proceed as follows-

Inspection

During inspection site of the lump, overlying skin and shape of the lump should be noted.

Site-first locate the site of the swelling. Probably the swelling originated from its underlying structure. As for example-

Scanned with CamScanner

Right upper abdominal swelling is probably due to

a) Enlargement of liver
b) Gall bladder mass
c) Swelling from right kidney
d) Swelling from right hepatic flexure
e) Swelling from colon

Palpation

1. If the swelling is present in the upper abdomen then try to determine whether get above the swelling is possible or not. When get above, the swelling is not possible in upper abdomen then the swelling may be due to

a) Enlargement of liver
b) Swelling from spleen
c) Swelling from stomach

When get below, the swelling is not possible in lower abdomen then the swelling may be due to

a) Swelling of the urinary bladder
b) Swelling of the uterus
c) Swelling of the ovary
d) Swelling of upper rectum (occasionally)

2. Size-size (length and breadth) of the lump should be measured.
3. Intra abdominal or extra abdominal mass- feel the lump, while ask the patient to lift the head and shoulders from pillow against resistance (figure 18). If the lump disappears then it is intra abdominal. If the lump becomes prominent then it is extra abdominal (arising from the abdominal wall).
4. Temperature-raised temperature over an abdominal mass usually indicates an underlying inflammatory lesion like appendicular abscess, liver abscess etc

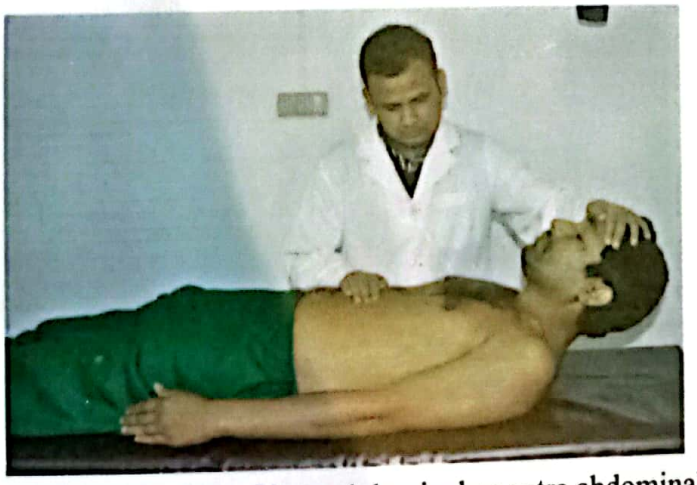

Figure 18: Examination of intra abdominal or extra abdominal mass (patient tries to raise the head from the pillow against resistence).

Scanned with CamScanner

5. Margin-mass having irregular margin is usually malignant, while mass having regular margin is usually benign.

6. Surface-nodular, uneven surface usually occurs in malignant lump. Smooth surface lump is usually benign.

7. Consistency-hard mass usually occurs in malignancy, soft consistency usually occurs in cystic lesion.

8. Tenderness-tender mass usually indicates underlying inflammatory leison as in crohn's disease of ileocaecal region.

9. Movement-with respiration-swellings arising in liver, spleen, kidneys, gallbladder and distal stomach show downward movement during inspiration due to normal diaphragmatic movement and such structures cannot be moved with the examining hand (manually).

   -With manually- tumours of the small bowel and transverse colon, cysts in the mesentary and large secondary deposits in the greater omentum are not usually influenced by respiratory movements, but may easily move on manually.

10. Fixity - fixed swelling usually signifies one of the three things

    a) A mass of retroperitoneal origin (e.g. pancreas).

    b) Part of an advanced tumour with extensive spread to the anterior or posterior abdominal walls or abdominal organs.

    c) A swelling resulting from severe chronic inflammation involving other organs (e.g. diverticulitis of the sigmoid colon or a tuberculous ileocaecal mass.

11. Percussion over the lump-mass originated from luminal structure is resonant on percussion.

12. Auscultation-bruit may be present in lump originated from the artery.

13. Re-clothing and thank the patient.

Palpation of the external genitalia

Prerequisite of examination of genitalia

1. Ask for screen.
2. Special permission from the patient.
3. Attendant (female nurse for female patient).

Scanned with CamScanner

In male (following points to be noted during examination of genitalia)

1. Pubic hair (loss of pubic hair usually occurs in hypogonadism due to any causes)
2. Penile length (small penile length in primary hypogonadism)
3. Scrotal swelling
4. Testicular swelling
5. Testicular atrophy

Digital rectal examination-abdomen examination will be not complete unless DRE done. This examination may reveal anal and rectal diseases like haemorrhoids, anal fissure, fistula, rectal polyp, tumour etc.

Percussion of the abdomen

A. Shifting dullness: (this is the cardinal sign to detect ascites)

1. Start percussion from the region of the umbilicus (figure 15 right) to the left side of the abdomen up to the flank till you elicit a dull note.
2. If there is no dullness of the left flank then continued the percussion from the left flank to the right flank. If there is no dullness in the right flank also, then there is no ascites.

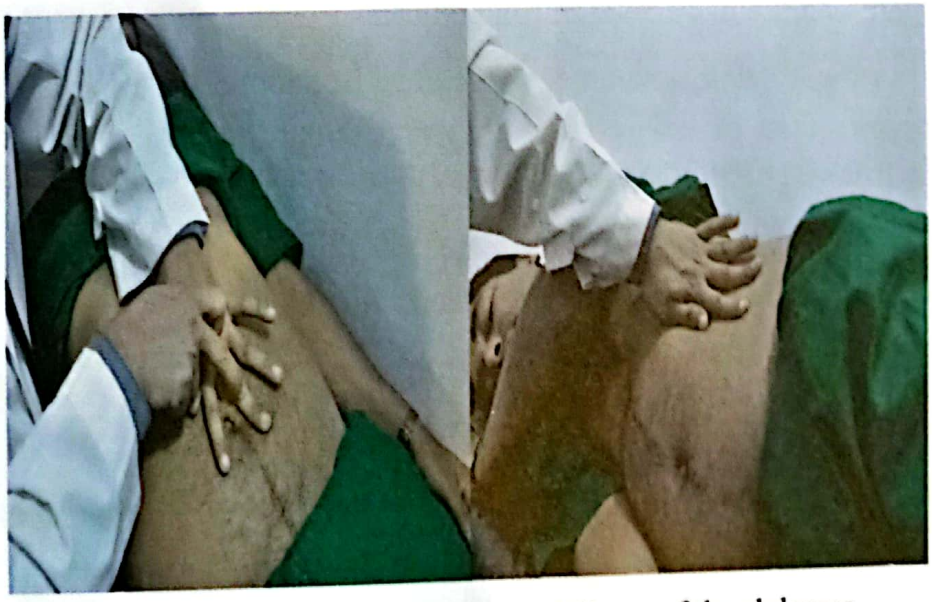

Figure 19: Examination of shifting dullness of the abdomen

3. On detecting dullness in the left flank, ask the patient to turn to the right side (figure 19 left), while keeping the examining hand over the exact site of dullness.

Scanned with CamScanner

4. Keep your hand in position for few seconds (up to 30 seconds) till the patient rests on the right side (this allows to redistribute the ascites fluid to the other side (downward side). Now again percuss in the area, if percussion returns a resonant note (from dull to resonant) continued percussion towards the other flank, if ascites is present, this flank will be dull. (This is shifting of the dullness from one flank to other).

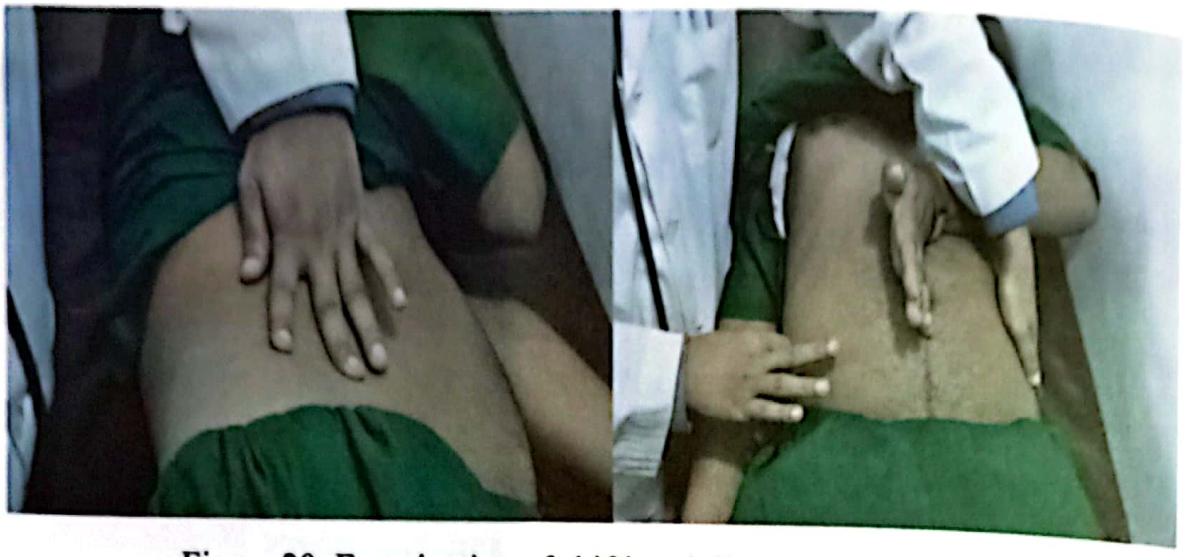

Figure 20: Examination of shifting dullness and fluid thrill.

5. Again turn the patient to the left side and keep the left hand in dull area and wait for few seconds, then percuss the area (figure 20 right), this will now reveal resonant, now continued percussion to the left side, in the left flank percussion will be dull (shifting dullness from one side to other side).

Note: In case of huge splenomegaly or huge hepatomegaly, first percuss towards the opposite area of enlargement. As for example if huge splenomegaly then percuss from the umbilicus to the right side of the abdomen then turn the patient to the left side and vice versa in case of huge hepatomegaly.

B. Fluid thrill: Positive in huge ascites and ovarian cyst.

1. Instruct the patient to lie in supine position.
2. Place one hand flat over the lumbar region on one side.
3. Ask the patient to put his left hand in the midline of the abdomen.
4. Tap or flick the opposite lumbar region (figure 20 left).
5. A thrill will be felt in the other hand if ascites is present.

How to differentiate between gross ascites, large ovarian cyst and intestinal obstruction-these three conditions causes diffuse enlargement of abdomen

Scanned with CamScanner

Gross ascites	Large ovarian cyst	Intestinal obstruction
Percussion note-dull in flanks.	Percussion note -resonant in flanks.	Percussion note -resonant in whole abdomen.
Umblicus-everted and/or hernia present.	Umblicus-vertical slit.	Umblicus-no remarkable change.
Shifting dullness positive.	Shifting dullness negative.	Resonant in whole abdomen.
Normal bowel sounds.	Normal bowel sounds.	Increase and/or noisy bowel sounds.

Auscultation of the abdomen-following points to be noted during auscultation of the abdomen:

1. Bowel sound
2. Bruit-hepatic bruit, renal bruit, arterial bruit
3. Rub-hepatic rub, splenic rub
4. Fetal heart sound (in pregnant patient)
5. Position of the NG tube (if any) (to cheek whether the NG tube in the stomach or in trachea)

Bowel sound

Bowel sound are gurgling noises from the normal peristaltic activity of the gut. They normally occur every 5-10 seconds, but the frequency varies. Listen for up to 2 minutes before concluding that bowel sound is absent.

Causes of absent bowel sound:

1. Paralytic ileus 2. Generalized peritonitis.

Causes of increased bowel sound

1. Proximal to the intestinal obstruction bowel sounds occur with increase frequency, volume and pitch, and have a high-pitched, tinkling quality.

Steps of auscultation of abdomen

1. Greetings and consent.
2. Position - patient should be in supine position; head should be supported by a single comfortable pillow.
3. Proper exposure of the abdomen from mid chest to the symphysis pubis.

Figure 21: Auscultation of the bowel sound.

Scanned with CamScanner

4. Bowel sound-place the diaphragm of the stethoscope to the right of the umbilicus and do not move it (figure 21). If no bowel sound is audible wait for at least 2 minutes before concluding bowel sound is absent.

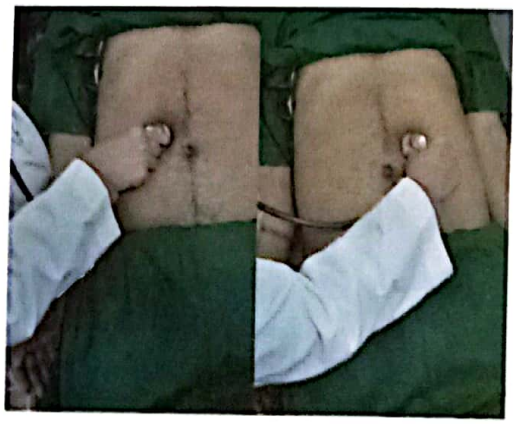

Figure 22: Auscultation of the renal bruit

5. Arterial bruit-listen above the umbilicus over the aorta for arterial bruits, which suggest an atheromatous or aneurysmal aorta or superior mesenteric artery stenosis.
6. Renal bruit-place the stethoscope 2-3 cm above and lateral to the umbilicus and listen for renal artery bruit from renal artery stenosis (figure 22).
7. Hepatic bruit/ rub-listen over the liver for bruit due to hepatoma or acute alcoholic hepatitis. A friction rub, which sound like rubbing your dry fingers together, may be heard over the liver (perihepatitis) or spleen (perisplenitis).
8. Foetal heart sound in case of pregnant patient.
9. Re-clothing and thank the patient.

How to examine for succussion splash?

A succussion splash sounds like a half-filled water bottle being shaken. Explain the procedure to the patient then shake the abdomen by lifting him with both hands under the pelvis and place one ear near to the upper part of the abdomen. An audible splash more than 4 hours after the patient has eaten or drunk anything indicates delayed gastric emptying, e.g. gastric outlet obstruction due to any cause commonly pyloric stenosis, carcinoma of stomach etc.

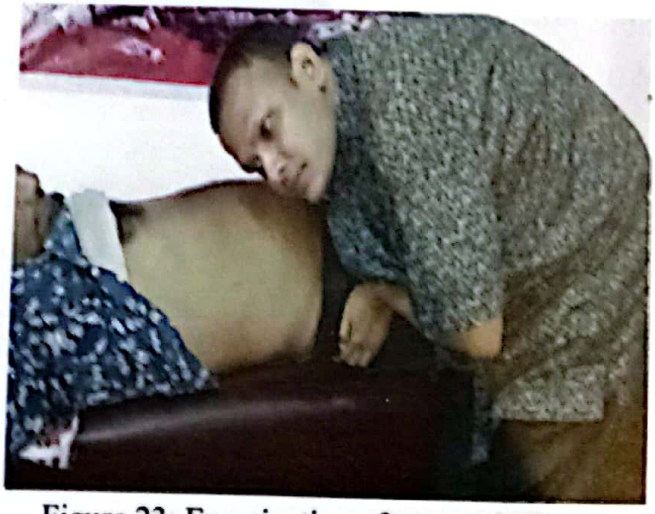

Figure 23: Examination of succussion splash

Scanned with CamScanner

The nervous system has two major parts: the central nervous system (CNS) and the peripheral nervous system (PNS). Central system is the primary control center for the body and is composed of the brain and spinal cord. The anterior part of the brain, including the cerebral hemispheres, the thalamus, and the hypothalamus is known as forebrain. The midbrain is the smallest region of the brain that acts as a sort of relay station for auditory and visual information. Portions of the midbrain called the red nucleus and the substantia nigra are involved in the control of the body movement. The darkly pigmented substantia nigra contains a large number of dopamine producing neurons. The degeneration of neurons in the substantia nigra is associated with Parkinson's disease. Cerebellum, pons, and medulla oblongata is known as hindbrain. The 3 major components of the brain are the cerebrum, cerebellum and brain stem. The cerebrum is divided into left and right hemispheres, each composed of a frontal, temporal, parietal and occipital lobe. The cerebellum is located near the base of the head. The cerebellum coordinates voluntary movements such as posture, balance, coordination, and speech, resulting in smooth, balanced muscular activity. The brain stem is made of the midbrain, pons and medulla oblongata. This structure is responsible for basic vital life functions such as breathing, heartbeat and blood pressure (respiratory and cardiac center located in brainstem).

Covering of the brain and spinal cord is meninges. Meninges consist of three layers: the dura mater, the arachnoid mater and the pia mater. Subarachnoid space is the anatomic space between the arachnoid and pia mater. CSF (cerebrospinal fluid) occupies the subarachnoid space. The primary function of the meninges and cerebrospinal fluid is to protect the central nervous system. The peripheral nervous system (PNS) has two components: the somatic nervous system and the autonomic nervous system. The PNS consists of all of the nerves that lie outside the brain and spinal cord. The somatic nervous system is responsible for all voluntary muscle contractions and carry information from the periphery to the central nervous system. 31 pairs spinal nerves and 12 pair of cranial nerves are the most important component of somatic nervous system.

Autonomic nervous system control involuntary processes of the body. The autonomic nervous system (ANS), also known as the visceral nervous system or involuntary nervous system that influences the function of internal organs. The autonomic nervous system is a control system that acts largely involuntarily and regulates the heart rate, digestion, respiratory rate, pupillary response, urination and sexual arousal. The autonomic nervous system has two branches: the sympathetic nervous system and the parasympathetic nervous system. The sympathetic nervous system is responsible for mounting responses to physical and psychological stimuli and the parasympathetic nervous system predominates during rest by slowing heart rate, lowering blood pressure and promoting digestion.

Scanned with CamScanner

Presenting complaints of the nervous system

1. Headache
2. Loss of consciousness/ unconsciousness
3. Hemiphlegia
4. Seizure
5. Vertigo
6. Delirium
7. Dizziness, blackout
8. Numbness and paraesthesia
9. Abnormal movements
10. Nystagmus

Headache

Headache is the most common neurological symptom. Primary headache syndromes are those in which no underlying cause is found. Common primary headaches include migraine, tension type headache and cluster headache. Secondary headache are those that results from underlying cause. Causes of secondary headache are meningitis, encephalitis, sinusitis, intracranial haemorrhage (ICH), ICSOL (intracranial space occupying lesion) etc.

Common causes of headache:

1. Chronic daily headache (tension headache)
2. Migraine
3. Infection (meningitis, encephalitis, brain abscess, sinusitis)
4. Intracranial haemorrhage (intracerebral haemorrhage, subdural haematoma, subarachnoid hemorrhage etc).
5. Raised intracranial pressure (ICSOL, idiopathic intracranial hypertension).
6. Referred pain from other structures (orbit, temporomandibular joint, neck)
7. Inflammatory disease (temporal arteritis, other vasculitis, arthritis).

What history should be taken in patient present with headache?

1. Duration-this is very important in terms of etiology of headache. Headache of longer duration usually due to benign cause. But headache of shorter duration is usually due to serious cause like ICSOL, ICH, subdural haematoma etc.
2. Onset-sudden onset of severe headache is usually suggest a serious underlying cause e.g. intracranial haemorrhage etc.

Scanned with CamScanner

3. Severity-severe headache usually due to migraine, encephalitis, ICH, SAH. Tension headache are usually mild to moderate in severity.
4. Site of headache-sudden, severe occipital headache is usually due to SAH, frontal headache may be due to sinusitis. Headache that can be located with tip of the finger is usually benign in origin.
5. Diurnal variation-headache severe at morning (awakening) gradually improve as the day progress is usually due to raised intracranial pressure (from ICSOL or benign intracranial hypertension), headache increase in severity as the day progress, highest at evening or night is usually due to tension headache. (Tension headache usually associated with sleep disturbance).
6. Presence of vomiting- migraine attack is usually associated with vomiting. Headache associated with early morning vomiting usually due to raised intracranial pressure (from ICSOL or benign intracranial hypertension).
7. Aggravating factor-migraine headache is usually aggravated on exposure to sound, light, noise etc.
8. Relieving factor-headache of raised ICP relieves with NSAIDs.
9. Periodicity of headache-in migraine usually there is periodicity of headache and in between attack the patient is usually normal.

Facial pain

What are the causes of facial pain?

1. Acute sinusitis
2. Dental pain
3. Pain of temporomandibular joint problem
4. Migraine
5. Trigeminal neuralgia
6. Herpes zoster affecting trigeminal nerve.

Dizziness, blackout, funny turns

Dizziness is defined as feelings of unsteadiness, wooziness and lightheadedness. A blackout is a transient loss of consciousness.

Consciousness

Consciousness may be defined as an awareness of the environment and ability to respond to it.

Scanned with CamScanner

Unconsciousness

Unconsciousness is a state in which a person unable to respond to any stimuli.

Disorientation

Means the patient is conscious but muddled in time, place and person.

Confusion

It implies disorientation.

What is stupor and coma?

Stupor is a state in which the person is unconscious but can be aroused by painful stimuli.

Coma is a condition in which a person unable to respond to external (pain, touch stimuli) and internal stimuli (feeling of hunger, micturition, defecation etc).

What are the common causes of unconsciousness?

1. Acute stroke (intracranial haemorrhage, SAH, large cerebral infarction)
2. Encephalitis/meningoencephalitis
3. Electrolyte imbalance (hyponatraemia)
4. Encephalopathy (hepatic/uraemic)
5. Diabetic ketoacidosis/Hyperosmolar non-ketotic diabetic coma (HONK)
6. Hypoglycaemia
7. Acute poisoning (OPC poisoning)

Seizure/convulsion

A seizure is any clinical event (commonly abnormal, excessive movement of one or more limbs or whole body) caused by an abnormal electrical discharge in the brain. Recurrent seizure is called epilepsy.

Common causes of seizure/convulsion in medicine ward

1. Idiopathic (primary epilepsy)
2. Encephalitis
3. Stroke (intracranial hemorrhage)
4. Electrolyte imbalance (hyponatraemia)
5. ICSOL (Intracranial space occupying lesion)

Scanned with CamScanner

Delirium

Delirium is an acute or subacute brain failure in which impairment of attention is accompanied by abnormalities of perception and mood. It is reversible. Individuals living with dementia (flail patient) are highly susceptible to delirium.

Causes of delirium

1. An acute medical illness, such as a urinary tract infection or RTI particularly in old age
2. Acute stroke
3. CNS infection (meningitis, encephalitis)
4. Withdrawal of drugs particularly alcohol.
5. An adverse reaction to a medication, mixing of medications or to alcohol

Dementia-is the clinical syndrome characterized by loss of previous acquired intellectual function in the absence of impairment of consciousness.

Parasthesia is abnormal sensation on the skin.

Numbness is decreased or lost sensation in the skin.

Tingling is an unusual sensation in the skin. It is often described as feeling of pins and needles, tickling, pricking, creeping, insect crawling etc.

Vertigo

Vertigo is defined as an abnormal perception of movement of the environment or self.

Common causes of vertigo

Central

1. Brainstem or cerebellar disorders (ischemia or infarction)
2. Migraine
3. Multiple sclerosis

Peripheral

1. Benign paroxysmal positional vertigo
2. Vestibular neuritis
3. Ménière's disease
4. Trauma
5. Drugs e.g. gentamicin, anticonvulsants, tramadol, pregabalin.

Scanned with CamScanner

Abnormal movements

Abnormal movements are mainly two types- hyperkinetic disorders and hypokinetic disorders. In both the cases, the lesion often localizes to the basal ganglia, although some tremors are related to the cerebellar or brainstem disturbance.

Hypokinetic disorders

In this disorder there is slow or less movements of the body parts. Classical example of this disorder is parkinsonism disease, in which there is combination of tremor, bradykinesia and rigidity.

Hyperkinetic disorders

In this disorder there is extra, unwanted movement of the body parts occur. Here are some examples

Tremor: Rhythmical oscillation of body part.

Causes of tremor

1. Essential tremor
2. Parkinson's disease (resting tremor)
3. Intention tremor in cerebeller lesion
3. Drug induced e.g. salbutamol, theophylline etc.

Chorea

Jerky, small amplitude, purposeless involuntary movements are termed 'chorea'.

Causes of chorea

1. Huntington's disease
2. Drug-induced
3. Sydenham's chorea

Tics-stereotyped, repetitive movements, briefly and voluntarily suppressible.

Myoclonus-shock like muscle jerks.

Dystonia-sustained muscle contraction causing abnormal postures.

Nystagmus

Nystagmus can be defined as a repetitive, involuntary, to-and-fro oscillation of the eyes. It may be physiological or pathological and may be congenital or acquired. It can be described according to:

1. The direction of movements: this may be horizontal, vertical, torsional or nonspecific.

Scanned with CamScanner

2. Amplitude - how far the eyes move, this can be fine or coarse.
3. Frequency - how often the eyes oscillate, this is said to be high, moderate or low.

Nystagmus is said to be one of the three forms:

1. Jerk nystagmus: This is characterised by a slow drifting movement followed by a fast corrective jerking movement. The direction of nystagmus is described according to the fast component.
2. Pendular nystagmus: The drifting and corrective movements occur slowly.
3. Mixed nystagmus: There is a pendular movement in the primary position of gaze (e.g. looking ahead) but a jerk nystagmus on lateral gaze.

Furthermore, nystagmus is said to be symmetrical, asymmetrical, bilateral or unilateral. It may be conjugate (both eyes move together) or disconjugate (the eyes appear to move independently of each other).

What are the causes of nystagmus?

1. Congenital (pendular nystagmus)
2. Acquired

   a) Brainstem or cerebellar ischaemia or infarction

   b) Certain medications or drugs, including sedatives and antiseizure medications like phenytoin

   c) Excessive alcohol consumption

   d) Head injury or trauma

   e) Vitamin deficiency (specifically B12 or thiamine)

Clinical examination of the nervous system

Examination of nervous system-usually nervous system examination is done under following headlines

1. Assessment of higher psychic function/ mental function
2. Examination of the cranial nerves
3. Examination of the motor system
4. Examination of the sensory system
5. Examination of signs of meningeal irritation

Scanned with CamScanner

Higher psychic function/ mental function

Following points to be noted during assessment of higher psychic function

1. Appearance, behavior and communication
2. Emotional state
3. Delusion and hallucination
4. Orientation in time, place and person
5. State of consciousness
6. Memory-short term and long-term
7. Speech and language

Appearance, behavior, communication and emotional state

Appearance is very important in term of diagnosis of neurological diseases. In parkinsonism, face is usually expressionless, in 3rd cranial nerve palsy there is complete ptosis, in 7th cranial nerve palsy face is deviated to the opposite side; these can be diagnosed only by appearance of the patient.

Behavior and communication (how the patient behaves with the physician) is also very important during evaluation of a patient with neurological disease. A patient who communicates with the physician with writing or by moving his body parts may have motor aphasia. Multiple sclerosis and paralyzed, disable stroke patient may be emotionally labile.

How to assess appearance, behavior, communication and emotional state?

Appearance can be assessed when the patient first enter into the consultation room to throughout the consultation period by carefully looking at the patient. For behavior and communication-give Salam (greetings) to the patient and asked may I examine you? Assess the emotional state of the patient while he/she talks. If he/she replies the Salam verbally and give consent of examination (yes, you can examine me) then his behavior is normal (co-operative), he communicates via speech and his emotional state is also normal.

Delusion-This is the false belief of something which is continued to be held even after evidence to the contrary. e.g Rahim is thinking that Karim has stolen his book. But Karim showed to Rahim that the book is still in Rahim's table, even though Rahim blaming Karim about stealing the book. Here Rahim is suffering from delusion.

How to assess delusion?

Do you think that somebody is trying to harm you?

Hallucination- it is the false perception of the senses in the absence of real stimulation (particularly related to the special senses).

Scanned with CamScanner

Types of hallucination:

1. Auditory hallucination- auditory hallucination is false perception of hearing sounds (voices, music etc.) without any real existence of source. The most common condition associated with auditory hallucinations is schizophrenia, with a reported 70% of schizophrenic patients experiencing them.

2. Visual hallucination- visual hallucination is false perception of seeing objects without any real existence of that particular object. Visual hallucination occurs in parkinson's disease, delirium tremens, schizophrenia etc.

3. Gustatory hallucination-gustatory hallucination is the perception of taste without a stimulus. Gustatory hallucination is common in temporal lobe epilepsy.

4. Olfactory hallucination- olfactory hallucination are perception of a smell in the complete absence of any physical odor. Temporal lobe seizure is often the cause of such damage, but olfactory hallucinations may also be present with neurological disorders such as schizophrenia, alzheimer's disease and parkinson's disease.

5. Tactile hallucinations-tactile hallucination involve the feeling of touch or movement in your body. Example: feeling of bugs crawling on skin, feeling imagined touch of someone's hands or body.

How to assess hallucination?

Ask the patient-do you hear, see, taste, smell, feel anything when you are alone?

Orientation in time, place and person

Orientation is a person's awareness of his location and the date and time. Orientation of time, place and person is lost in Alzheimer's disease and other types of dementia.

This is assessed by

1. What is the approximate time of the day? (orientation of time)
2. Where are you now? (orientation of place)
3. Who is he/she? (Show a known person of the patient and ask to identify him) (Orientation of person).

(Normal finding-a normal individual can answer the location and approximate time of the day and identify the person).

Scanned with CamScanner

Memory is the process by which information is encoded, stored and retrieved.

Types

1. Short term memory-short-term memory is the memory pertaining to the immediate past. Short term memorry loss can sometimes be normal; however, persistent short-term memory loss is associated with Alzheimer's dementia and other serious mental conditions.

2. Long term memory-long term memory is obviously enough, intended for storage of information over a long period of time. Despite our everyday impressions of forgetting, it seems likely that long-term memory actually decays very little over time, and can store a seemingly unlimited amount of information almost indefinitely. Indeed, there is some debate as to whether we actually ever "forget" anything at all, or whether it just becomes increasingly difficult to access or retrieve certain items from memory. Long term memory usually not affected by the neurological diseases.

Assessment of memory

1. Short term

   What did you eat at your last meal?

2. Long term

   What is the name of your primary school?

Consciousness

Consciousness is the state of being awake and aware of one's surroundings. The Glasgow Coma Scale or GCS is a neurological scale that aims to give a reliable, objective way of recording the conscious state of a person for initial as well as subsequent assessment. It is composed of three parameters: Best Eye Response, Best Verbal Response, Best Motor Response. The GCS score is between 3 and 15; 3 being the worst and 15 is the best. A GCS score of 13 or higher correlates with a mild brain injury; 9 to 12 is a moderate injury and 8 or less indicates a severe brain injury.

Best Eye Response	
Response	Grading
No eye opening	1
Eye opening to pain	2
Eye opening to verbal command	3
Eyes open spontaneously	4

Scanned with CamScanner

Best Verbal Response	
Response	Grading
No verbal response	1
Incomprehensible sounds	2
Inappropriate words	3
Confused	4
Orientated	5

Best Motor Response	
Response	Grading
No motor response	1
Extension to pain	2
Flexion to pain	3
Withdrawal from pain	4
Localizing pain	5
Obeys commands	6

What is speech?

Speech refers to the sounds that come out of mouth and take shape in the form of words.

What is language?

Language is what we speak, write, read and understand. Communication through gestures is also considered as language (body language or sign language). There are two distinct areas of language: receptive (what we hear and understand from others' speech or gestures) and expressive (the words we use to create messages that understand by others).

What is aphasia?

Aphasia (or dysphasia) is a disorder of the language content of speech. It can occur with lesions over a wide area of the dominant hemisphere.

Types of aphasia

1. Motor/expressive aphasia- expressive aphasia involves difficulty in conveying thoughts through speech. The patient can understand everything but cannot speak. In motor aphasia site of lesion is Broca's area of the dominant hemisphere.
2. Sensory/ receptive aphasia- receptive aphasia involves difficulty in understanding spoken or written language. The patient cannot understand but talks fluently and irrelevantly. Site of the lesion is Wernicke's area of the dominant hemisphere.

Scanned with CamScanner

3. Nominal aphasia-it is a type of motor aphasia in which there is difficulty in naming the familiar object, patient usually talk less, answer is either 'yes' or 'no' and comprehension is good.
4. Global aphasia- patients lose almost all language function, both comprehesive and expressive. They cannot speak or understand speech, nor can read or write. Global aphasia results from severe and extensive damage to the language areas of the brain. (Along the territory of dominant middle cerebral artery).

What is dysarthria?

Dysarthria is a disorder of speech in which there is difficult or unclear articulation of speech.

There are four main types of dysarthria

1. Cerebellar (scanning) dysarthria- in this disorder patient speaks syllable by syllable. Example- if patient is asked to pronounce 'Lalmonirhat', patient will speak like 'Lal-Mo-Nir-Hat'. Cerebellar (scanning) dysarthria occurs in cerebellar lesion.
2. Bulbar dysarthria-here pronounciation of consonant is difficult. Occurs in bulbar palsy. Here if patient is asked to pronounce 'egg' then he will pronounce like 'eng'; which is nasal voice.
3. Pseudobulbar dysarthria-speech is strangled and spastic. Rapid changes in speech sound, as required for tongue-twisters are particularly difficult. 'British constitution' is pronounced as 'Brizh Conshishushon'.
4. Extrapyramidal dysarthria-usually occurs in parkinsonism.

How you will approach to a patient with dysarthria?

1. Ask the patient to say 'lalmonirhat', if the patient pronounces syllable by syllable like 'lal-mo-nir-hat'then it is cerebellar dysarthria.
2. Ask the patient to pronounce 'egg' if the patient pronounces like 'eng' which is nasal voice then it is bulbar dysarthria.

What is dysphonia?

Dysphonia describes hoarse or whispered speech. The most common cause is laryngitis, but dysphonia can also result from a lesion of the 10th cranial nerve or disease of the vocal cords, including laryngeal dystonia.

Scanned with CamScanner

How to assess speech and language?

Speech and language can be assessed when testing "behavior and communication"-give Salam (greetings) to the patient and ask may I examine you? Carefully hear the answer of the patient. (listens to the character of the speech, the fluency (smoothness of speech), and the patient's ability to understand and carry out simple or complex commands and to read and write). If dysarthria present, confirm type of dysarthria by asking to utter different words.

How to approach a patient with aphasia?

1. Give Salam (greetings) to the patient, and seek consent of examination.
2. Wait for the answer.
3. If patient give irrelevant answer then-sensory aphasia.
4. If patient do not give any answer or try to answer with body parts/limb movement, then ask the patient to protrude the tongue/raise the leg/grapes examiner hand etc, if the patient can do this, then the patient have motor aphasia.
5. If patient do not give any answer and cannot follow any above mentioned command then-global aphasia.
6. Ask the patient 'any question'? if he answer with either 'yes' or 'no' then this is nominal aphasia.

Sequence of examination of higher psychic function

1. Greetings and consent (give Salam and ask may I examine you). Answer of this question will provide information about-appearance, behavior, communication, emotional state, state of consciousness, speech and language.
2. Ask the patient-do you hear anything, see anything, taste anything, smell, feel anything, when you are alone? (for hallucination).
3. Ask-do you think that somebody is trying to harm you? (for delusion)
4. Ask-what is the approximate time of the day? (Orientation of time)
5. Ask-where are you now? (orientation of place)
6. Do you know him? (orientation of person)
7. Ask –what have you eaten at your last meal? (short term memory)
8. If patient is unconscious assess by GCS
9. Thank the patient

Scanned with CamScanner

Cranial nerves

There are 12 pairs of cranial nerves; among them 3rd, 4th, 6th, 11th & 12th are purely motor, 1st, 2nd & 8th cranial nerves are purely sensory and others are mixed nerve (have both motor and sensory component).

1st and 2nd cranial nerve truely is an extension of the brain parenchyma.

Nucleus of 3rd and 4th cranial nerve located at the midbrain.

Nucleus of 5th, 6th, 7th & 8th cranial nerve to the pons.

The remaining cranial nerves (9th, 10th, 11th & 12th) nuclei located in medulla (figure 1).

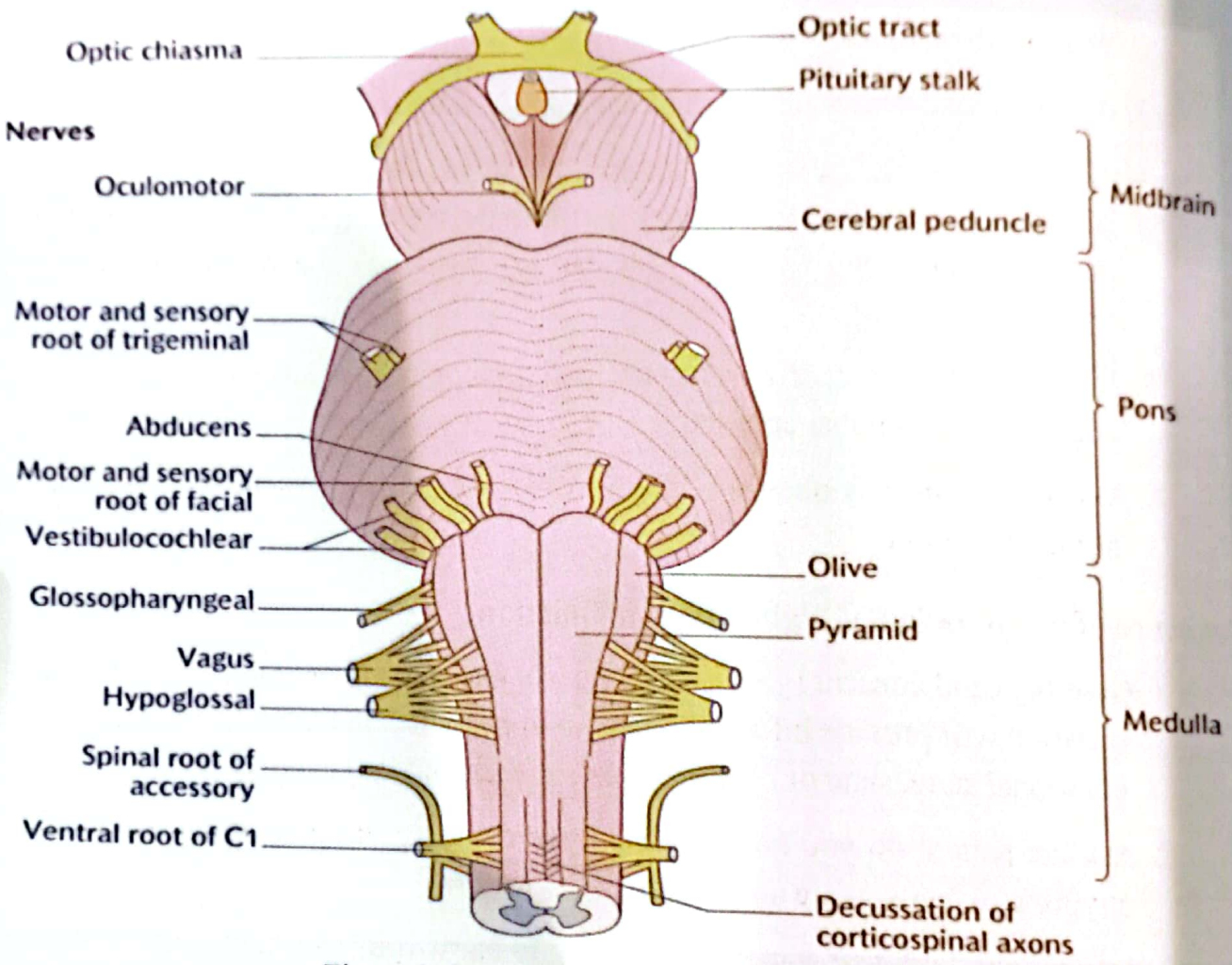

Figure 1: Location of cranial nerve nucleus

Scanned with CamScanner

1st cranial nerve or olfactory nerve

This is the shortest cranial nerve, concerned with olfaction (carry the smell sensation).

Sequence of examination

1. Greetings and consent (give Salam and ask may I examine you?)
2. Patient should be in sitting position.
3. Ask the patient-do you feel all types of smell?
4. Inspect the nasal cavities for any blockage, polyp, DNS etc. by torch light.
5. Ask the patient-close your eyes and shut one nostril with a finger (figure 2).

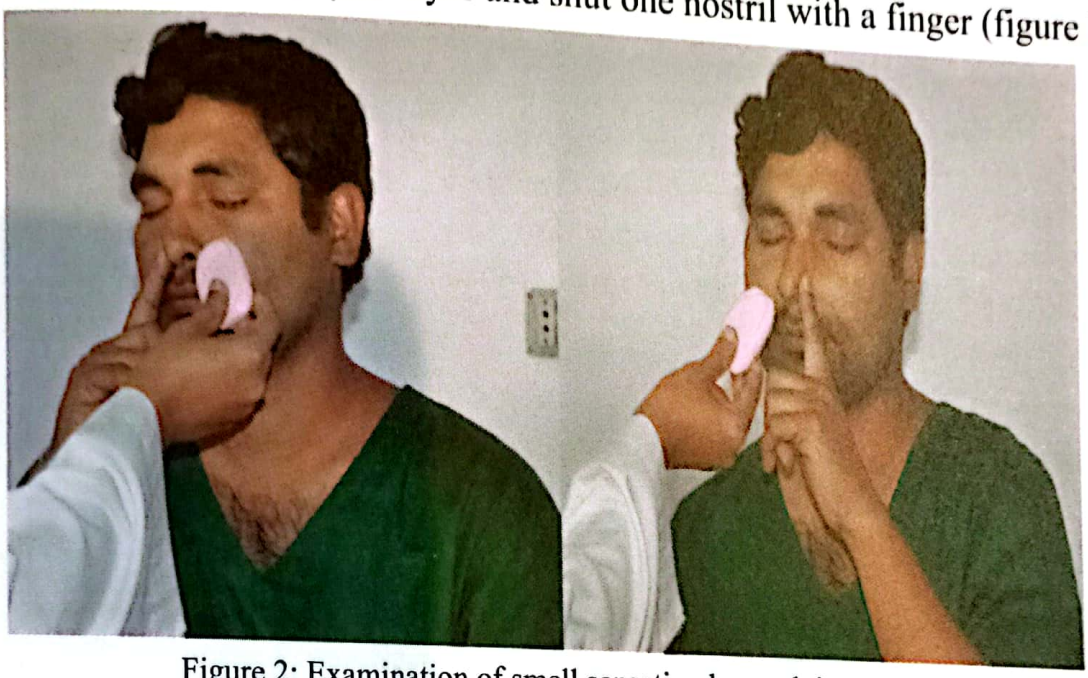

Figure 2: Examination of smell sensation by applying soap.

6. Apply different smells (commonly used-fruit, scent, soap) in open nostril one by one and ask whether he could identify the smell (figure 1). Repeat this in other nostril.
7. Thank the patient.

Normal findings- 1st cranial nerve is intact (patient gets all modalities of smell).

Abnormalities of smell perception

Anosmia-absence of smell perception is called anosmia.

Causes:

1. Rhinitis (common cold)
2. Sinusitis
3. Previous bacterial meningitis
4. Closed head injury
5. Sub frontal meningioma

Parosmia- in this condition pleasant smell seems offensive. This occurs in sinusitis.

Scanned with CamScanner

2nd cranial nerve or optic nerve

Examination of the optic or 2nd cranial nerve includes the following-

a) Visual acuity
b) Color vision
c) Field of vision
d) Opthalmoscopic examination
e) Pupillary light reflex (commonly this is tested under 3rd cranial nerve examination but afferent pathway of the pupillary light reflex is formed by the 2nd cranial nerve. When somebody will ask to do examination of only 2nd cranial nerve then pupillary light reflex should be examined under 2nd cranial nerve otherwise this should be examined under 3rd cranial nerve).

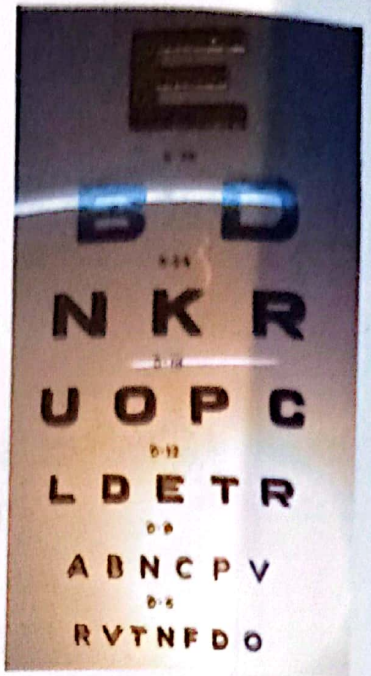

Figure 3: Snellen's distant vision chart

Visual acuity

It is the ability of the eye by which one thing can be differentiated from another.

It is of two types

1. Visual acuity for distant vision- tested by Snellen's distant vision chart (figure 3).
2. Visual acuity for near vision-tested by Snellen's near vision chart..

Here are some features of Snellen's distant vision chart

- ✓ Distance from the patient to the Snellen's distant vision chart is 6 meter or 20 feet.
- ✓ This chart has 7 rows.
- ✓ Visual acuity of the patient who can see the uppermost row (largest 'letter' line) is 6/60.
- ✓ Visual acuity of the patient who can see the lowermost row (smallest 'letter' line) is 6/6 (normal vision).

What is meant by visual acuity 6/60?

Visual acuity 6/60 means a normal eye can see the object from 60 meter distance and the diseased eye can see that object only from 6 meter distance.

Bedside test for visual acuity for distant vision

1. Ask the patient to close his one eye with palm of the hand.

Figure 4: Testing visual acuity at bed side.

Scanned with CamScanner

2. Ask him to count the fingers placed 2/3 feets in front of the eye (figure 4). If can count the finger then take the fingers more away and again ask to count. The last distance in which the patient can count the fingers, is his visual acuity. Example if a patient can count finger from 10 feet distance. So his visual acuity of that eye is 10 feet counting finger.

3. If the patient cannot count the fingers then reduce the distance and ask to count again, if still cannot count then take the hand of you up to 1 feet distance and move the hand, ask the patient whether he can see the hand movements, if yes then visual acuity is hand movement, if no then put light into eye and ask whether he/she can see the light, if the patient can see the light then visual acuity is perception of light. If cannot see the light then he/she is blind.

4. Test visual acuity of the other eye by the same way described above.

Visual acuity for near vision

This should be tested by Snellen's near vision chart. At bedside visual acuity for near vision tested by asking the patient to read newspaper/any books/any picture or objects.

Color vision

Acquired unilateral loss of colour vision is a characteristic feature of optic neuropathy and loss of colour vision can occur when visual acuity is well preserved. Thus, testing colour vision may be a sensitive bedside test for mild optic neuropathy. Ideally it should be tested by Ishihara color vision chart. Clinically it should be tested by showing three basic colors (red, sky blue and green) to the patient.

Field of vision

Ideally it should be tested by Goldman Perimeter (figure 5 right). Visual field defects in one eye indicate a retinal or optic nerve disorder. In the clinic or in the ward, neurologists and general physicians test visual field by simple confrontation field testing, comparing the patient's field with their own, assuming their own to be normal.

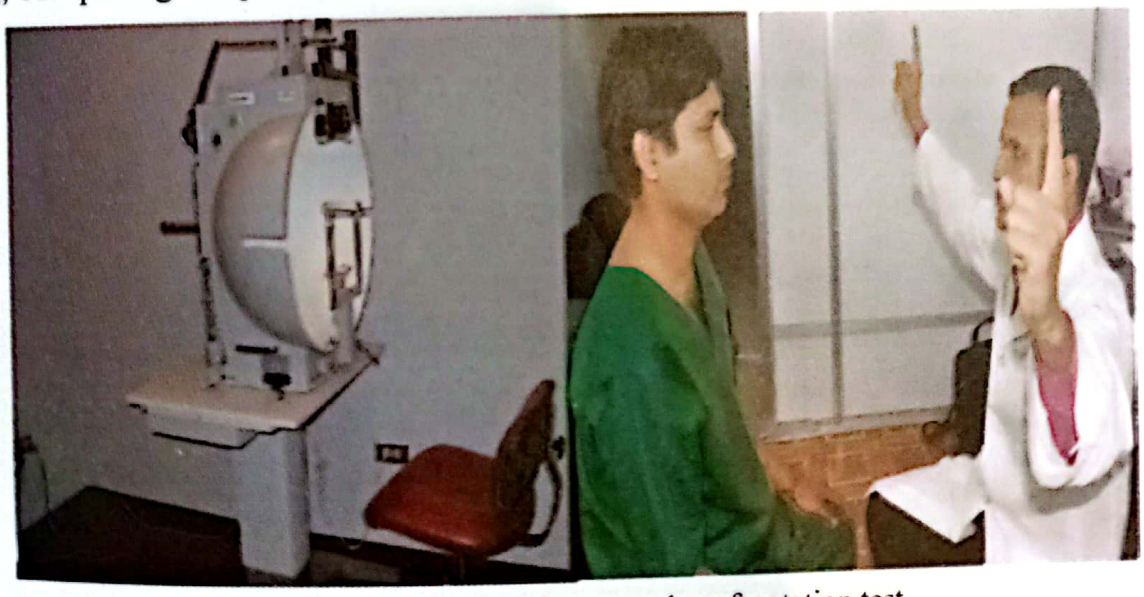

Figure 5: Goldman Perimeter and confrontation test.

Scanned with CamScanner

How to perform confrontation test

1. Greetings and consent from the patient.
2. Sit in front of the patient with 1 meter distance.
3. Ask the patient to fix the eye to the examiner's eye and not to move the head.
4. Hold your hands up one on each side at the face level, about 1 meter apart and ask the patient whether he can see both hands (figure 4).
5. Switch from hands held up to index fingers held up and move them up so that they are situated in the right and left superior quadrant of vision (figure 4 left).
6. Gradually place the moving finger in the visual field from four corners (horizontally right and left side, vertically right and left side).
7. Ask the patient to report, whether he/she can see the moving finger while examiner can see it.
8. If the patient can see the moving finger while examiner can see it in four corners then visual field is normal.
9. Thank the patient.

Opthalmoscopic examination

This should be tested by ophthalmoscope. Ophthalmoscopic examination should be done to see

1. Papilloedema
2. Hypertensive retinopathy
3. Diabetic retinopathy
4. Optic atrophy etc.

Procedure of opthalmoscopic examination

1. Greetings and consent-the procedure should be described to the patient
2. Patinet should be in sitting position and the room should be dimmed.
3. Ask the patient to fix stare at object placed at distant.
4. Turn on ophthalmoscope and set dial to 0.
5. Approach from 15cm, "O" magnification.
6. Remember examiner's right hand & right eye for patient's right eye and examiner's left hand & left eye for patient's left eye (figure 6).
7. Rest hand on patients forehead (figure 6).
8. Begin at arm's length away to see the red reflex (figure 6).
9. Move closer until optic disc visible (approximately 3-5cms) (figure 6).

Scanned with CamScanner

Figure 6: Procedure of opthalmoscopic examination (note the room is dimmed).

10. If examiner is hyperopic – turn disc of ophthalmoscope for plus numbers (green).
11. If examiner is myopic – turn disc of ophthalmoscope for minus numbers (red).
12. First examined the optic disc, then periphery and finally macula (because when light will fall in macula, there will be irritation in eye and patient will not co-operate for further examination). To examine the macula ask the patient to look at the light, when he/she will look at the light macula will be visible.
13. Repeat the same procedure for the other eye.
14. Thank the patient.

Pupillary light reflex

(Why pupillary light reflex should be examined in 2nd cranial nerve examination? Because the afferent pathway of the light reflex is formed by 2nd nerve).

It is of two types

1. Direct light reflex- normally when light is directed in one eye, it produces constriction of pupil in both eyes. The direct response is the constriction of pupil in the eye to which the light is directed (e.g. if the light is shown in the right eye, the right pupil constricts).
2. Indirect light reflex/consensual light reflex-when light is directed in one eye, this causes constriction of pupil of opposite eye, this is indirect/consensual light reflex.

   Light reflex pathway: Light fall in eyes-retina-optic nerve-optic tract-pretectal nucleus of mid brain-Edinger-Westphal nucleus-oculomotor nerve-ciliary ganglion-ciliary nerve-pupillary sphincter.

Scanned with CamScanner

In severe optic neuritis or an ischaemic optic neuropathy there will be an afferent pupillary defect e.g. a failure of constriction of either pupil to light shown into the affected eye. (Both direct and indirect reflexes are absent).

What is efferent pupillary defect?

A lesion of the pupilloconstrictor nerve fibres in the oculomotor nerve will lead to dilatation of the ipsilateral pupil (due to the unrestrained effect of the intact sympathetic supply). Direct light reflex will be absent in the affected eye and consensual reflex to the other eye is normal and in the other eye direct light reflex is normal but consensual reflex to the affected eye is lost.

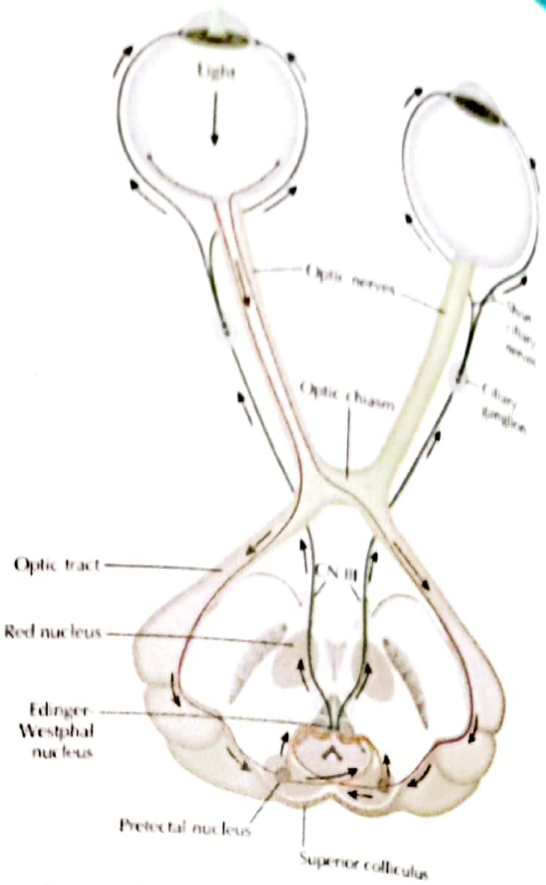

Figure 7: Pathway of pupillary light reflex

Sequence of examination of light reflex

1. Greetings and consent.
2. Patient should be in sitting position and looking forwards.
3. Direct light reflex of the left eye-place the light on the lateral part of the head (above the ear) and gradually fall it in to the left eye, simultaneously look for the changes of the pupil of the left eye (normally pupil gradually constrict) (figure 8 right).

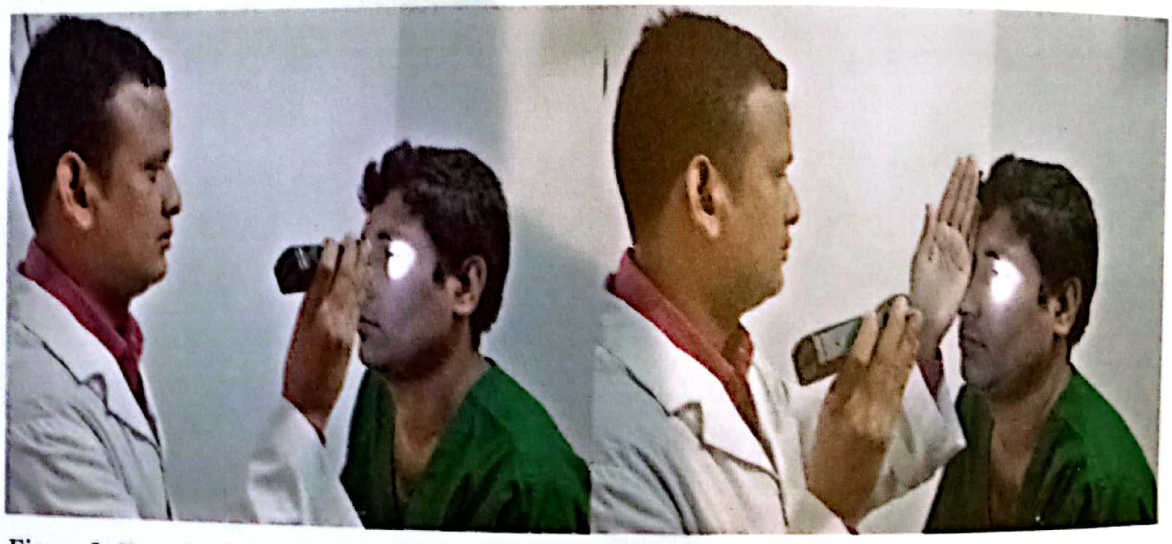

Figure 8: Examination of light reflex; direct light reflex (right) and consensual light reflex (left).

Scanned with CamScanner

4. Consensual light reflex of the left eye- place the left hand of the examiner over the nose to make a wall in between two eyes, (to prevent fall of light to the right eye which will cause an direct light reflex to the right eye) then gradually fall light in to the left eye, simultaneously look for the changes of the pupil of the right eye (normally pupil gradually constrict) (figure 6 left).

5. For right eye repeat the above procedure.

6. Thank the patient.

Normal findings-on examination of 2nd cranial nerve is intact (visual acuity, colour vision, field of vision is normal and opthalmoscopic examination, direct and consensual light reflex is normal).

3rd, 4th & 6th cranial nerve (oculomotor, trochlear & abducent nerve)

3rd cranial nerve involves two separate components, each of which has a distinct function. The somatic motor component supplies four extraocular muscles in the eyes and the upper eyelid muscle levator palpebrae superioris. It controls the muscles that allow visual tracking and fixation by the eyes. The visceral motor component control parasympathetic innervation of the ciliary muscles and constrictor pupillae, aiding in accommodation and pupillary light reflexe.

Trochlear nerve (4th cranial nerve) supply superior oblique muscle. The function of the fourth nerve is to turn the eyes down and medially (towards the nose) as well as inward rotation of the eye.

Abducent (6th cranial nerve) nerve supply lateral rectus muscle, which move the eyes laterally (away from the nose).

Sequences of examination of 3rd, 4th and 6th cranial nerve

1. Greetings and consent, patient should be in sitting position.
2. Ask the patient for diplopia-do you see one thing as double?
3. Inspect the eyes for-ptosis (dropping of the eyelid), squint (figure 9) (eyes look in different directions) and nystagmus.
4. Examination for ocular movements-
   a) Sit in front of the patient with 1 metre distance.
   b) Ask the patient please fix your eye to the examiner's eye and not to move the head.



Figure 9: Squint of right eye.

Scanned with CamScanner

c) Place the right index finger in front of the patient and ask the patient please follow the finger only by moving the eye (not moving the head). Move the finger into four quadrants as like of 'H' shap (figure 10). Look for the movement of the eye ball,

Figure 10: Examination of ocular movements.

presence of nystagmus. Ask the patient whether he/she sees double fingers (to confirm diplopia). (Look carefully while the eyeball moves. If the eyeball does not move to any side, the responsible muscle/innervating nerve is paralysed. Example if 6th nerve becomes paralysed then eyeball will not move to the lateral side).

Figure 11: Examination of accommodation reflex.

4. Accommodation reflex-place the index finger in front of the patient and ask him to look on distant, and then ask the patient to see the finger and observe the changes of the eye (figure 11). Changes of accommodation are-

   I. Pupillary constriction.

   II. Convergence of the eye ball (it goes medially)

   III. Increase convexity of the lens.

Scanned with CamScanner

5. Pupillary light reflex-described above.
6. Thank the patient.

Features of 3rd nerve palsy

1. Complete ptosis .
2. Eye ball directed downwards and outwards.
3. Pupil dilated & not reacting to light.
4. Absence of movement of the eye ball.

Causes of 3rd nerve palsy- diabetes mellitus, brain tumour, head injury etc.

Features of 4th nerve palsy- absence of movement of the eyeball in downwards & medially.

Causes of 4th nerve palsy- common causes are congenital and trauma, rare causes are stroke, tumor etc.

Features of 6th nerve palsy- absence of movement of the eyeball laterally.

Causes of 6th nerve palsy

The most common causes of 6th cranial nerve palsy are brain tumour, stroke, trauma and elevated pressure inside the brain due to any cause.

5th or trigeminal nerve

Trigeminal nerve is a mixed nerve, it has both motor and sensory component. Motor part supply to the muscles of mastication- temporalis, masseter, lateral pterygoid and anterior belly of digastrics muscle.

It has three divisions (figure 12)

a) Opthalmic division b) Maxillary division c) Mandibular division

The ophthalmic and maxillary nerves are purely sensory and the mandibular nerve has cutaneous and motor function.

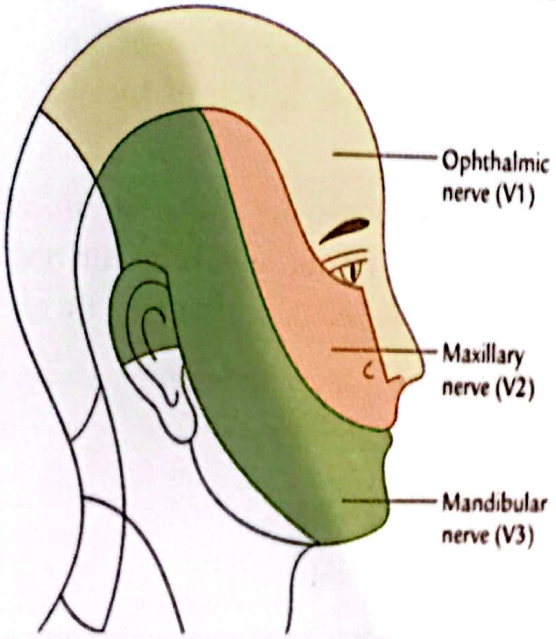

Figure 12: Dermatome of trigeminal nerve

Scanned with CamScanner

Sequences of examination of 5th cranial nerve

1. Greetings and consent.
2. Ask the patient-clench the teeth and feel the temporalis & masseter muscle.(normally the muscles will be taut) (figure 13a).

13a 13b 13c

Figure 13: Examination of 5th cranial nerve; examination of muscle of mastication (13a, 13b) and jaw jerk (13c).

3. Ask the patient-please try to open your mouth (examiner will prevent to open the mouth) (Open the mouth against resistance) (figure 13b).
4. Jaw jerk-ask the patient to make the mouth half open, place the thumb of the left hand below the lower lip in the midline then strike with the hammer and observe while the mouth become close or not. Normally there will be no change, in upper motor neuron lesion of the nerve the mouth will be closed (figure 13c).
5. Corneal reflex-place a pointed end of the sterile cotton on the sclero-corneal junction and observe whether the eye blink or not; normally blinking occurs. (Remember don't do the procedure with unsterile cotton).
6. Sensory examination-pain, touch and temperature sensation should be tested along the 3 divisions of the trigeminal nerve. (See sensory examination).
7. Thank the patient.

Scanned with CamScanner

Facial or 7th cranial nerve

Facial nerve is a mixed nerve, has both motor and sensory component. Motor portion controls the muscles of facial expression, the principal muscles are the frontal belly of occipitofrontalis muscle (concerned with wrinkling of forehead), orbicularis oculi (concerned with closure of the eyes), buccinator, orbicularis oris (this muscle closes the mouth and puckers the lips when it contracts), platysma, the posterior belly of the digastric and the stapedius muscle (It prevents excess movement of the stapes, helping to control the amplitude of sound waves from the general external environment to the inner ear. The stapedius muscle dampens the ability of the stapes vibration and protects the inner ear from high noise level). Sensory portion carries taste sensations from the anterior two-thirds of the tongue via the chorda tympani branch.

Course of facial nerve

From its motor nucleus in the lower pons, fibres of the VII nerve pass back to loop around the VI nucleus before emerging from the lateral pontomedullary junction in close association with the VIII nerve; together they enter the internal acoustic meatus. At the lateral end of the meatus the VII nerve continues in the facial canal within the temporal bone, exiting the skull via the stylomastoid foramen. Passing through the parotid gland, it gives off its terminal branches. In its course in the facial canal it gives off branches to the stapedius muscle and its parasympathetic fibres, as well as being joined by the taste fibres of the chordae tympani.

Sequences of examination of 7th cranial nerve

1. Greetings and consent, patient should be in sitting position.
2. Ask the patient
   a) Do you have any hearing problem (hyperacusis will occur if the lesion of facial nerve is proximal to the nerve to the stapedius).
   b) Does food accumulate in any cheek during eating?
   c) Does water come out along the angle of the mouth during drinking?
   d) Do you get the taste of different foods like salt, sweet, sour etc?
3. Examination

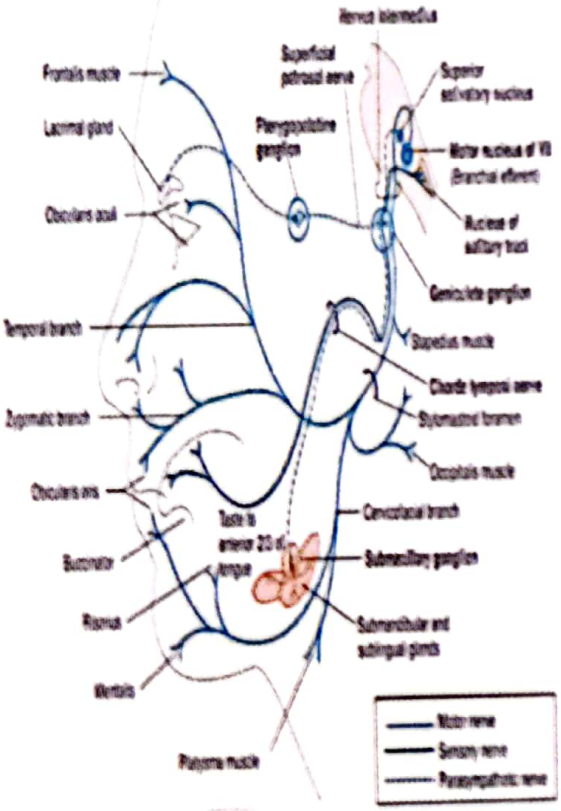

Figure 14: Course of 7th cranial nerve

Scanned with CamScanner

a) Instruct the patient-please look upwards without moving your head (hand can be placed over the patient's head so that the patient can not move the head). Look wrinkling of forehead (normally wrinkling present in both side of the forehead) (figure 15a).

15a 15b 15c

Figure 15: Examination of facial nerve

b) Instruct the patient - close your eyes tightly and not let me to open it. (Normally the patient can close both eyes tightly) (Figure 15b).

c) Ask the patient to blow his cheek and examiner should feel the cheek whether he can retain the air within the mouth. (Normally the patient can blow the check and air cannot pass out after pressing the cheek) (figure 15c).

Figure 16: Examination of facial nerve

Scanned with CamScanner

d) Ask the patient-please show me your teeth and look for any deviation of the angle of the mouth. (Normally there is no deviation of angle of the mouth to any side) (Figure 16 right).

e) Ask the patient-give whistle by mouth (patients of facial nerve lesion cannot make whistle) (Figure 16 left).

3. Taste sensation-

a) Instruct the patient not to speak during the test.

b) Ask the patient to put out his tongue.

c) Use cotton buds dipped in sugar (sweet), salt and quinine (bitter) solutions. Apply them one at a time to the anterior two-third of the tongue.

d) Ask the patient to point to sweet, salt, sour and bitter on a card to indicate his response.

e) The patient should rinse out his mouth with water between each test.

4. Thank the patient.

What are the normal and abnormal findings in facial nerve examination?

Normal findings	Abnormal findings
Hearing of the patient is normal	Hyperacusis may be present
Food does not accumulate in the cheek	Food accumulates in the cheek
Water does not come out along the angle of the mouth while drinking	Water comes out along the angle of the mouth while drinking. (due to weakness of orbicularis oris)
Taste sensation intact	Taste sensation impaired
Wrinkling present in both side of the forehead.	Wrinkling absent in affected side of the forehead
The patient can close both eyes tightly	The patient cannot close his eye or cannot close the eye tightly in affected side
The patient can blow the check and air cannot pass out after pressing the cheek	The patient cannot blow the check and air pass out after pressing the cheek
Normally there is no deviation of angel of the mouth to any side	Deviation of angel of the mouth to opposite side
Patient can make whistle	Patient of facial nerve lesion cannot make whistle

Scanned with CamScanner

How you will differentiate between upper motor and lower motor type neuron lesion of facial nerve?

17a 17b

Figure 17: LMN type right sided facial nerve palsy (right) and UMN type right sided facial nerve palsy (left).

LMN type lesion of 7th cranial nerve	UMN type lesion of 7th cranial nerve
Wrinkling absent on the affected side of the forehead (figure 17a).	Wrinkling present in both side of the forehead (figure 17b).
The patient cannot close his eye or cannot close the eye tightly on the affected side (figure 17a).	The patient can close both eyes tightly (figure 17b).
Weakness affect both upper and lower part of the face.	Weakness (facial paresis) is marked in the lower facial muscles with relative sparing of the upper face (there is bilateral cortical innervations of the upper facial muscles.)

Why upper part of the face not affected in upper motor neuron lesion of 7th cranial nerve?
Because upper part of the face (frontalis muscle and orbicularis oculi) get innervation from both cerebral cortex. So if right sided upper motor type 7th nerve palsy due to cortical problem (e.g. stroke) then it get innervation from left cortex, so upper part of the face is not involved.

How to find out the site of lesion in case of LMN lesion of 7th cranial nerve?

Features	Site of lesion of facial nerve
Hyperacusis.	Proximal to the nerve to the stapedius.
Hypogeusia (partial loss of taste) or ageusia (complete loss of taste sensation).	Facial canal or proximally.
Taste and lacrimation are preserved.	Distal to the stylomastoid foramen.

Scanned with CamScanner

What is Bell's palsy?

Idiopathic lower motor neuron lesion of VII nerve is called Bell's palsy.

Causes

1. Idiopathic
2. Viral infection-Herpes simplex virus infection, Varicella zoster virus infection
3. Sarcoidosis

What is Bell's phenomenon?

During attempt closure of the eyes, the eyeball rotate upward, this is a normal phenomenon but can not see due to closure of the eye with eyelid, but in Bell's palsy eye remain open, so the upward rotation of the eye can be seen, this is called Bell's phenomenon.

What is Ramsay Hunt syndrome?

Ramsay Hunt syndrome occurs in herpes zoster infection of the geniculate (facial) ganglion.

Features

1. Painful vesicular eruption within the external auditory meatus.
2. Ipsilateral lower motor neuron facial nerve palsy.
3. Ipsilateral loss of taste sensation and buccal ulceration.

Vestibulocochlear nerve (8th cranial nerve)

This nerve has two components cochlear part and vestibular part. Cochlear part carrying information about hearing and the vestibular nerve carrying information about balance. Only cochlear part is tested clinically by

1. Rinne's test.
2. Weber's test

(Tuning fork 512 Hz should be used for both the tests).

The Weber and the Rinne test are typically performed together with the results of each combined to determine the location and nature of any hearing loss. The Rinne's test should be done first.

Scanned with CamScanner

Normal or postive Rinne's test

A normal or positive Rinne's test is when the sound heard outside of the ear (air conduction or AC) is louder than the sound over the skin on top of the mastoid process behind the ear (bone conduction or BC). Therefore AC > BC; which is reported clinically for a normal or positive Rinne's test.

Negative Rinne's test

When bone conduction is better than air conduction or BC > AC. Negative Rinne's test occurs in conductive hearing loss. A patient with a profound sensorineural deafness may have a false Rinne's negative.

False negative Rinne's test occurs because with complete loss of innervation to that ear the patient shouldn't be able to hear anything whether the tuning fork is presented to the external acoustic canal or to the bone of the mastoid. However, patient may hear the sound being transmitted through his skull to their remaining good ear on the other side and he may not be able to recognize which ear is hearing the sound. This may give the appearance of bone conduction being better than air conduction when in fact the ear is completely "dead". False negative Rinne's test can be confirmed by Weber's test.

Normal Weber's test

Weber's test in which tuning fork sound is heard equally loud in both ears.

In a patient with hearing loss, the tuning fork sound heard louder in one ear (lateralization). If the sound is heard louder in one ear then this can be caused by a conductive hearing loss on that side or a sensorineural hearing loss on the other side.

A simple way to demonstrate and understand (Weber's test on yourself is to place a finger occluding one ear (mimicking a conductive deafness) and with a tuning fork sounded over the vertex of the skull, sound will be conducted to the occluded ear. If both ears are affected by a conductive hearing loss the tuning fork will be heard in the ear which is the more affected. In a sensorineural hearing loss then the sound is transmitted to the better functioning ear.

Scanned with CamScanner

Sequences of examination of Rinne's test

1. Greetings and consent.
2. Patient should be in sitting position.
3. Hit the prongs of the tuning fork against a hard surface (commonly forearm) to make it vibrate.
4. Place the vibrating base of the tuning fork against the patient's mastoid bone and asking the patient to tell you when the sound is no longer heard (figure 18a). This is BC.

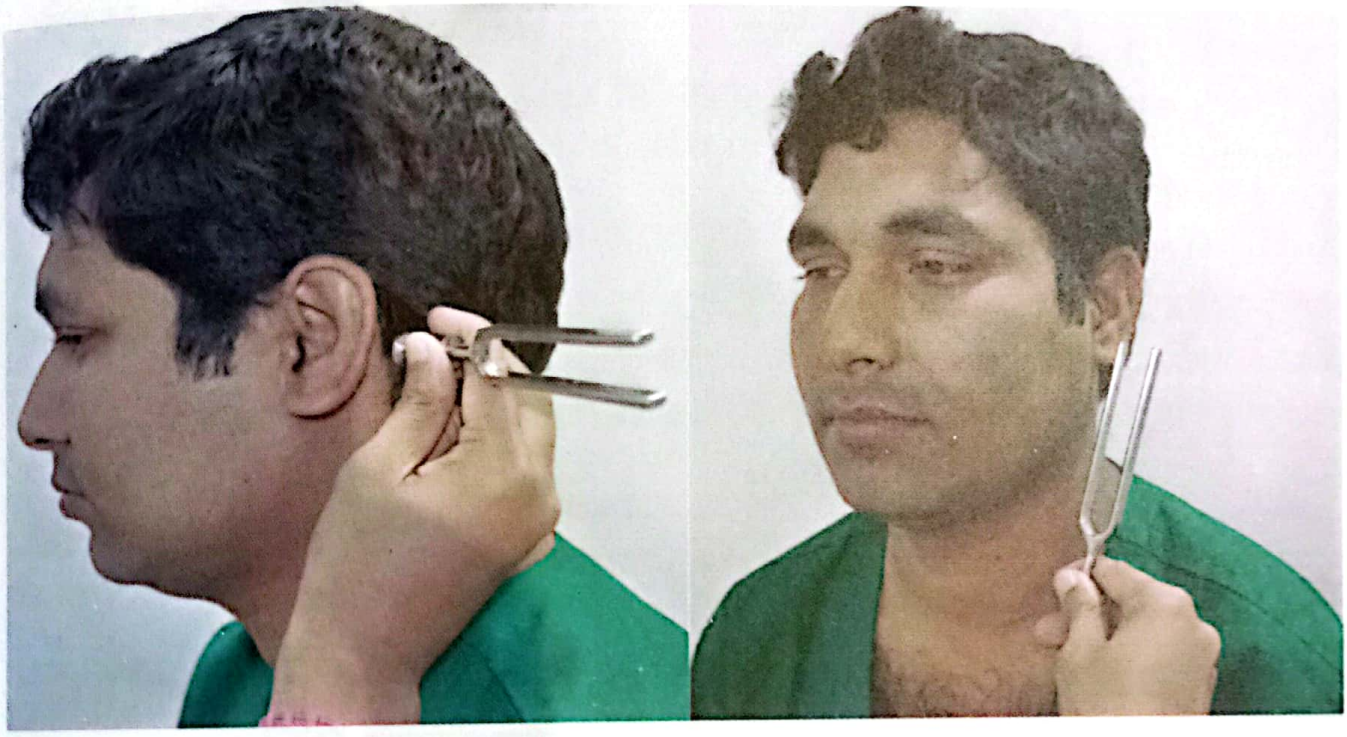

18a 18b

Figure 18: Showing Rinne's test.

5. Once the patient can't hear it, quickly place the still vibrating prongs of tuning fork 1–2 cm from the auditory canal, and again ask the patient to tell you if they are able to hear the tuning fork (figure 18b). This is AC.
6. Thank the patient.

Interpretation: Normal hearing: AC>BC. In abnormal hearing as in conductive deafness.: BC>AC

Scanned with CamScanner

Sequences of examination of Weber's test

1. Greetings and consent.
2. Patient should be in sitting position.
3. Hit the prongs of the fork against a hard surface (forearm) to make it vibrate.
4. Place the base of the vibrating tuning fork on top of the patient's head or in the middle of the forehead (figure 19).
5. Ask the patient where he hears the sound; normally this is in the middle or equally in both ears.
6. Note to which side the sound lateralizes.
7. Thank the patient.

Figure 19: Weber's test.

Normal findings:

In Weber's test the tuning fork sound should be heard equally in both ears. The patient may have difficulty saying where the noise is coming from and just say all over the head. However, it should be symmetrical.

Abnormal findings:

Conductive deafness-loudest in the affected ear.

Sensorineural deafness- the sound is loudest in the normal ear.

How you will interpretate Rinne's and Weber's test in conductive and sensorineural deafness?

	Rinne's test	**Weber's test**
Conductive deafness	BC>AC in affected ear.	Lateralized to the affected ear.
Sensorineural deafness	False negative Rinne in affected ear.	The sound is loudest in the normal ear.

Glossopharyngeal, vagus and cranial part of the accessory nerve (9th, 10th and cranial part of the 11th nerve)

The IX and X nerves have an intimate anatomical relationship. Both contains sensory, motor and autonomic components.

The IX nerve passes down and forward to supply the stylopharyngeus muscle, the mucosa of the pharynx, the tonsillar area and the posterior third of the tongue, and sends parasympathetic fibres to the parotid gland.

The X nerve courses down in the carotid sheath and into the thorax, giving off several branches, including pharyngeal and recurrent laryngeal branches, which provide motor supply to the pharyngeal, soft palate and laryngeal muscles. The main nuclei of these nerves in the medulla are the nucleus ambigus (motor), the dorsal motor vagal nucleus (parasympathetic) and the solitary nucleus (visceral sensation).

The accessory nerve has two components-cranial part and spinal part. Cranial part is closely related to the vagus nerve. Commonly 9th, 10th and cranial part of the 11th nerve is tested together.

Scanned with CamScanner

Sequence of examination

1. Greetings and consent.
2. Ask the patient-do you have any problem of swallowing? Do you have any nasal regurgitation of the food or water?
3. Ask the patient to cough, assess the strength of the cough.
4. Ask the patient to pronounce 'EGG' and observe whether there is nasal voice. (if nasal voice it will pronounce like 'ENG'.
5. Ask the patient to open the mouth widely and to tell 'aah' and observe movement of the soft palate. (Damage of X nerve on one side leads to the deviation of the uvula when the soft palate is elevated after saying 'Aaah').
6. Ask the patient to puff out the cheeks with the lips tightly closed. Look and feel for air escaping from the nose. Normally, both sides of the palate elevate symmetrically and the uvula remains in the midline. In order for the cheeks to puff out, the palate must elevate and occlude the nasopharynx. If palatal movement is weak, air will escape audibly through the nose.
7. Testing pharyngeal sensation and the gag reflex (gag reflex unpleasant for the patient). Place a spatula on the posterior wall of the oro-pharynx and observe is there any contraction of the pharyngeal muscles (a vomiting response will be seen). Use the more reliable water swallow test instead, in fully conscious patients only. Administer 3 teaspoons of water and observe for absent swallow, cough or delayed cough, or change in voice quality after each teaspoon. If there are no problems, watch for the same reactions as above while the patient swallows a glass of water.
8. Thank the patient.

Normal findings: Normally the patient will not have any problem of swallowing, nasal regurgitation of the food or water, coughing, pronunciation and movement of the uvula is normal.

Abnormal findings: Isolated unilateral IX nerve lesion is rare. Damage to the X nerve on one side leads to deviation of the uvula when the soft palate is elevated after saying 'Aaah'. Damage to the recurrent laryngeal branch of the X nerve causes dysphonia and 'bovine' cough.

What is bovine cough?

Bovine cough is non-explosive cough due to inadequate closure of the glottis due to the damage of the recurrent laryngeal branch of the X nerve and associated with dysphonia.

Causes of recurrent laryngeal nerve damage

1. Lung cancer (Common cause)
2. Thyroid surgery
3. Mediastinal tumours and
4. Aortic arch aneurysm

Scanned with CamScanner

What is bulbar palsy?

Bilateral lower motor neuron lesion of IX, X, XI and XII cranial nerves are called bulbar palsy.

Causes of bulbar palsy

1. Genetic- acute intermittent porphyria
2. Stroke-medullary infarction
3. MND (Motor neuron disease)
4. GBS (Guillain-Barre syndrome)
5. Poliomyelitis

What is pseudobulbar palsy?

Bilateral upper motor neuron lesion of IX, X, XI and XII cranial nerves are called pseudobulbar palsy.

Causes of pseudobulbar palsy

1. Bilateral cerebral infarction
2. Multiple sclerosis
3. Progressive supranuclear palsy

Spinal part of the 11th cranial nerve

This part of the nerve supplies the trapizeus and sternocleidomastoid muscle. Normal function of sternocleidomastoid muscles are rotation of the head to right and left side and trapezius causes elevation of the scapula (shurg the shoulder).

Sequence of examination

1. Greetings and consent.
2. Patient should be in sitting position.
3. Stand behind the patient and put the both hand over the patient's shoulder and ask the patient to shrug the shoulder (test of trapezius) (figure 20 right). Weakness of trapezius will result in winging of the scapula.

Figure 20: Examination of spinal part of 11th cranial nerve; test of trapezius (right) and sternocleidomastoid (left).

Scanned with CamScanner

4. Stand in front of the patient and ask the patient to turn the patient's head to the right side against resistance (place left hand over the rigth side of the patient's face and exert gentle pressure) and feel the left sternocleidomastoid muscle. Repeat the procedure in left side (figure 20 left).
5. Place the palm of the right hand to the patient's cheek and ask him to give pressure to the palm, the both sternocleidomastoid muscles will be taut.
6. Thank the patient.

12th cranial nerve

The XII nerve innervates the muscles of the tongue; the nucleus lies in the dorsal medulla beneath the floor of the fourth ventricle.

Sequences of examination

1. Greetings and consent.
2. Inspect the tongue while the tongue is within the mouth for fasciculation, wasting etc. (figure 21a)

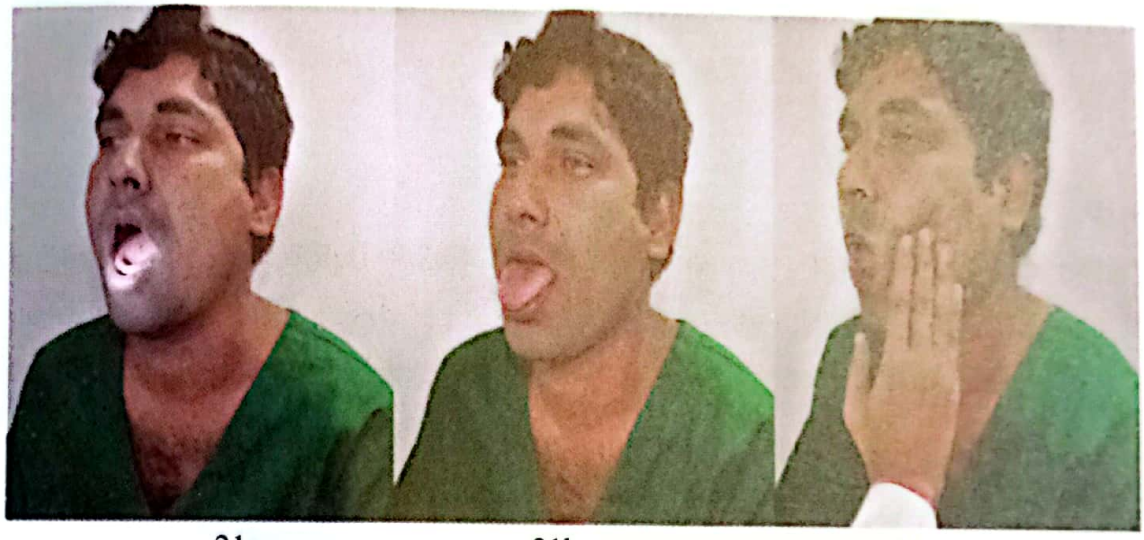

21a 21b 21c

Figure 21: Examination of 12th cranial nerve.

3. Ask the patient to protrude the tongue and look for deviation or involuntary movement (tremor) (figure 21b).
4. Ask the patient to move the tongue from side to side.
5. Test power by asking the patient to press the tongue against the inner side of each cheek in turn while you press from the outside with your finger (figure 21c).
6. Assess speech by asking the patient to say 'yellow lorry'.
7. Assess swallowing with a water swallow test.
8. Thank the patient.

Scanned with CamScanner

Abnormal findings: Unilateral lower motor XII nerve lesions lead to wasting of the tongue on the affected side and deviation to that side on protrusion. Bilateral lower motor neuron damage results in global wasting - the tongue lies thin and shrunken like an autumn leaf and involuntary twitching (fasciculation) may be evident. When associated with lesions of IX, X and XI nerves, typically in motor neuron disease, these features are called bulbar palsy.

Motor system

Following points to be noted during motor system examination

1. Bulk of the muscle
2. Fasciculation
3. Tone of the muscle
4. Power of the muscle
5. Reflexes and clonus
6. Co-ordination of movement
7. Involuntary movement
8. Gait

Bulk of the muscle

Bulk of the muscle is usually normal in acute onset neurological disease. But the muscle bulk reduced (wasting) in chronic neurological disease like lower motor neuron lesion. In upper motor neuron lesion muscle bulk may be reduced later due to disuse atrophy.

Causes of muscle wasting

1. Lower motor neuron lesion (peripheral neuropathy due to any cause)
2. Disuse atrophy due to any cause (e.g. paralysed patient)
3. Cachexia due to any case

How to assess bulk of the muscle?

1. Inspection-by looking the muscle and compare with the opposite side. e.g. for upper limb inspect the muscles of arm and forearm and for lower limb inspect the muscles of thigh and leg and compare with the other side.
2. Palpation- wasted muscle are softer and flabby on palpation.

Scanned with CamScanner

Figure 22: Assessment of the bulk of the muscle by measurement of the muscle from definite bony point.

3. Measurement- measuring the muscle bulk from a definite bony prominence and compare with the other side. e.g. measure the thigh muscle 10 cm from medial epicondyle of both sides and compare (figure 22).

Fasciculation

Contraction of group of muscle fibres is called fasciculation. It is visible, looks like irregular ripples or twitches under the skin overlying the muscles. (fibrillation is contraction of single muscle fibre, it is not visible, diagnosed by EMG).

Causes of fasciculation

1. Lower motor neuron lesion due to any cause e.g. Motor neuron disease (MND), poliomyelitis etc.

How to examine for fasciculation?

Carefully look over the muscles e.g. arm and forearm in upper limb and thigh and leg for lower limb. If no fasciculation is seen then flick the skin over the wasted muscle. After flickering if there is no fasciculation, then fasciculation is absent.

Tone of the muscle

This refers to the state of muscle tension or contraction in resting muscle. Tone of the muscles may be normal, hypotonia or hypertonia.

Hypertonia

Increase tone of the muscle is called hypertonia.

Causes

1. Upper motor neuron lesion due to any cause (e.g. stroke, transverse myelitis, spinal cord compression etc).
2. Parkinsonism
3. Muscles surrounding a painful joint.

Scanned with CamScanner

Two form of hypertonia is usually seen

a) Spasticity- spasticity is found with upper motor neuron lesion and manifest as a marked resistance to the initiation of rapid passive movement. This initial resistance gives way and then there is less resistance over the remaining range of motion (clasp-knife phenomenon).

b) Rigidity- rigidity is an increase in tone that persists throughout the passive range of movement. This has been termed "lead pipe" rigidity and is common with extrapyramidal disease, especially Parkinson's disease.

Hypotonia

Decrease tone of the muscle is called hypotonia.

Causes

1. Lower motor neuron lesion due to any cause (e.g. poliomyelitis, peripheral neuropathy etc).
2. Cerebellar lesion
3. UMN lesion with spinal shock.

Tone of the muscle should be examined by

1. Greeting and consent.
2. Patient should be in supine position.
3. Passively move all the joints of the upper and lower limbs. (In hypertonia resitance will feel during movement, in hypotonia there will be no resistance during movement) (Figure 23).

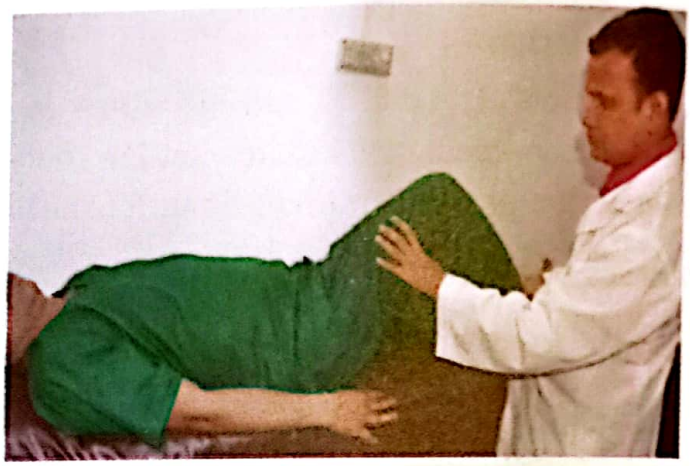

Figure 23 : Examination of tone of the muscle by passive movement of the joint

Figure 24: Examination of tone of the muscle by lifting the leg and allow it to fall freely.

Scanned with CamScanner

4. Lift the leg with knee in extension position and allow it to fall freely. In case of increased tone, the leg will be lifted off the bed briefly before falling back down (figure 20).

Power of the muscle

MRC (Medical Research Council) scale for assessment of muscle power. This is a reliable and validated scale for assessing and grading of muscle weakness. Each muscle group is graded as follows:

Grading	Muscle status
0	Complete paralysis.
1	Flickering of contraction is present.
2	Only side to side movement is possible but movement against the gravity is not possible.
3	Movement against the gravity is possible.
4	Can move against gravity & some resistance exerted by examiner.
5	Normal power.

Some definitions

Paresis	Partial paralysis.
Plegia	Complete paralysis.
Monoplegia	Paralysis of a single limb.
Hemiplegia	Paralysis of one half of the body.
Paraplegia	Paralysis of both legs.

How to assess muscle power?

1. By MRC grading.
2. For individual muscle test- the action of the muscle against resistance.

Scanned with CamScanner

Reflexes

A reflex is an involuntary and spontaneous movement in response to a stimulus.

Reflex arc or reflex circuit consists of:

1. Sensory receptor
2. Sensory neuron
3. Integration centre (spinal cord or brain stem)
4. Motor neuron
5. Effector (muscle)

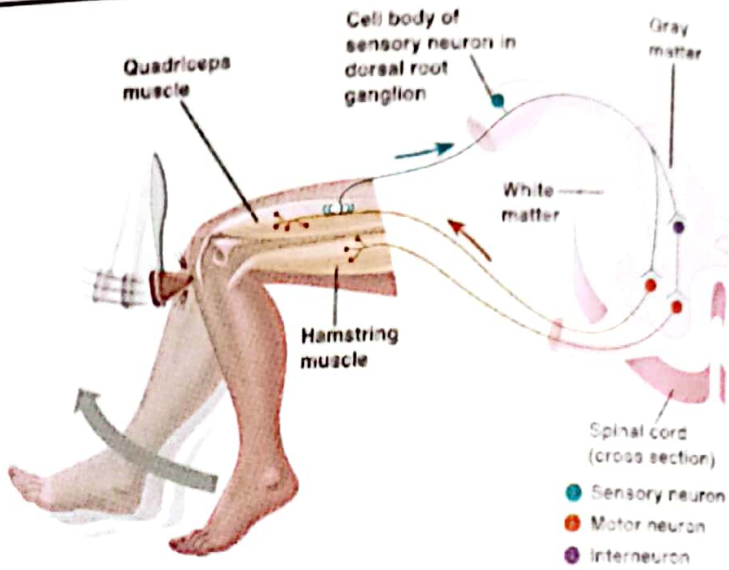

Figure 25: Pathway of deep reflex

Two types of reflex in our body-superficial reflex and deep reflex.

Superficial reflex

These are elicited by stimulation of a structure on the surface of the body. Their reflex arc consists of more than one synapse, thus they are considered as polysynaptic reflex. Following are the examples of superficial reflex.

Abdominal reflex (T8-12): Scratching the abdomen around the umbilicus will lead to contraction of the abdominal wall muscles. Abdominal reflex is absent in upper motor neuron lesion.

How to elicit abdominal reflex:

1. The patient should be supine and relaxed.
2. Use the reverse end of the tendon hammer and stroke briskly but lightly in a medial direction across the upper and lower quadrant of both sides of the abdomen (figure 26 right).

Scanned with CamScanner

3. The normal response is contraction of the underlying muscle, with the umbilicus moving laterally and up or down depending upon the quadrant tested.

Cremasteric reflex (in males L1-L2): Scratching the inner thigh, will lead to elevation of the scrotum.

Corneal reflex: Touching the cornea will lead to a blinking response, or closure of the eye.

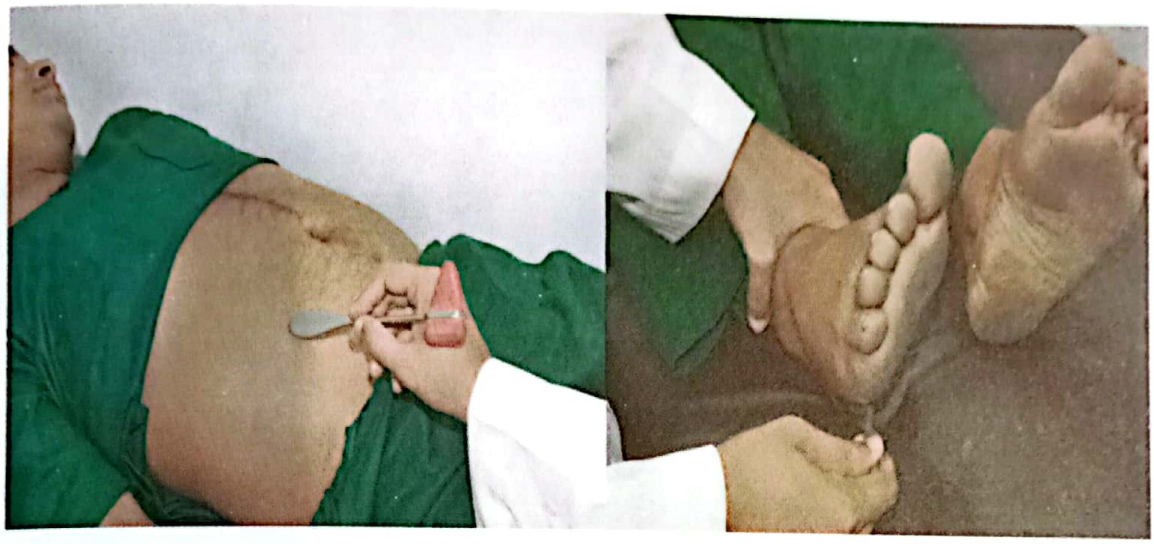

Figure 26: Examination of abdominal reflex (right) and planter reflex (left).

Plantar reflex (S1,2): Run a blunt object (usually key) along the lateral border of the sole of the foot towards the little toe (figure 26 left).

The normal response is flexion of the great toe and flexion of the other toes too. This is a normal negative Babinski response (plantar flexion).

An abnormal positive Babinski response (plantar extension) is when the patient responds to the stimuli by dorsiflexion and abduction of the toes (fanning of the toes). Positive Babinski (plantar extension) reflex is considered normal in children below first year, while in adult it is considered as damage to the pyramidal tract fibres.

Interpretation of planter reflex

Normally planter reflex is flexor but extensor response is highly indicative of presence of upper motor neuron lesion.

When planter reflex will be not extensor in spite of having upper motor neuron lesion?

1. A patient with lower motor neurone paralysis of toe extension cannot have a conventional extensor response regardless of the severity of any upper motor neurone disorder.

2. If patient is in spinal shock.

Scanned with CamScanner

Causes of extensor planter reflex

Bilateral extensor (commonly occur in bilateral cerebral or spinal cord disease)

1. Meningo-encephalitis
2. Encephalitis
3. Spinal cord compression due to any cause
4. Transverse myelitis
5. Multiple sclerosis
6. Hepatic encephalopathy
7. Raised ICP due to any cause
8. Hypoglycaemia

Spinal shock

Spinal shock is a combination of areflexia/hyporeflexia and autonomic dysfunction that accompanies spinal cord injury. Here below the level of lesion there will be loss of both superficial and deep tendon reflexes though patient has upper motor neuron lesion. Reflexes will usually return within a few days.

Unilateral extensor (commonly occur in unilateral cerebral leison)

1. Acute stroke

Deep reflex

Here we excite deep structures in the body. Also called the "tendon jerk", because we are striking the tendon. In this reflex there is direct contact between motor and sensory neurons (monosynaptic reflex).

Deep reflexes of our body

Upper limb
1. Biceps jerk (C5,6)
2. Triceps jerk (C6,7)
3. Supinator jerk (C5,6)

Lower limb
1. Knee jerk (L2,3,4)
2. Ankle jerk (L5,S1)

Grading of deep jerk

Grade	Response
0	Absent
1	Present (as a normal ankle jerk)
2	Brisk (as a normal knee jerk)
3	Very brisk
4	Clonus

What is clonus?

Clonus is a series of involuntary, rhythmic, muscular contractions and relaxations. Normally clonus is absent but present in upper motor neuron lesion due to any cause. Two types of clonus commonly tested during clinical examination-patellar and ankle clonus.

Scanned with CamScanner

How to examine patellar and ankle clonus?

1. Greetings and consent.
2. Expose both lower limbs.
3. Patient should be in supine position with the knee and hip joint in extension position.
4. Hold the base of the patella with the left hand and pull towards the thigh then rapidly push the patella towards the toes (figure 27 left). When patellar clonus present this will be followed by involuntary movement of the knee joint.

Figure 27: Examination of ankle (right) and patellar clonus (left).

5. Ankle clonus-hip and knee should be kept in semiflexed position. Hold the leg of the patient with the left hand and hold the foot with the right hand, rapidly dorsiflex (upward) the foot (figure 27 right). Subsequent beating of the foot will result if ankle clonus present. However only a sustained clonus (5 beats or more) is considered abnormal.

When to declare deep jerks is absent?

1. If the deep jerks are absent, then do the 'Jendrassik maneuver' and repeat elicit of the jerk. If still no response, then declare deep jerks are absent.

Jendrassik maneuver

When deep reflexes are absent, we use a mechanism of exaggeration called the "Jendrassik maneuver" e.g. for lower limb ask the patient-please clasp your hand and interlock your fingers and try to pull them apart strongly and during this time again elicit the jerk. This will increase the lower limb reflexes. For upper limb ask the patient to clench the teeth.

Scanned with CamScanner

Reflex demonstration

Demonstrating the reflexes by striking the tendon of the muscle, which leads to stretching of the muscle. Before elicite the deep jerk examiner should expose the tested muscle to see its contraction; like for biceps and triceps jerks arm should be exposed; for knee jerk thigh should be exposed and for ankle jerks leg should be exposed.

1. Knee jerk: Proper exposure of the thigh to see the contraction of the quadriceps muscle. Flex the knee joint and hang it by placing palm of the left hand in popliteal fossa, then locate the patellar tendon and strike the quadriceps tendon directly with the hammer (figure 28). A positive response will be contraction of quadriceps muscle that leads to flexion of the knee joint).

Figure 28: Examination of knee jerk.

2. Ankle jerk: Expose the calf muscles, then slightly dorsiflex the ankle so as to stretch the achiles tendon and with your other hand, strike the tendon on its posterior surface (figure 20), a quick contraction of the calf muscles (figure 29) will occur normally.

Figure 29: Examination of ankle jerk.

Scanned with CamScanner

3. Biceps jerk: Semiflex the patient's elbow joint and then place your thumb on the biceps tendon (figure 30), and elicit the reflex by indirectly striking your thumb with the hammer. Normal respose is contraction of biceps muscle causing flexion of the elbow joint.

Figure 30: Examination of biceps jerk.

4. Triceps jerk: Strike the triceps tendon directly (figure 31). Normal respose is contraction of triceps muscle causing extension of the arm.

Figure 31: Examination of triceps jerk.

5. Supinator jerk- The supinator reflex is tested by striking the lower end of the radius just above the wrist joint with a tendon hammer (figure 32). This normally causes contraction of the brachioradialis and hence flexion of the elbow.

Scanned with CamScanner

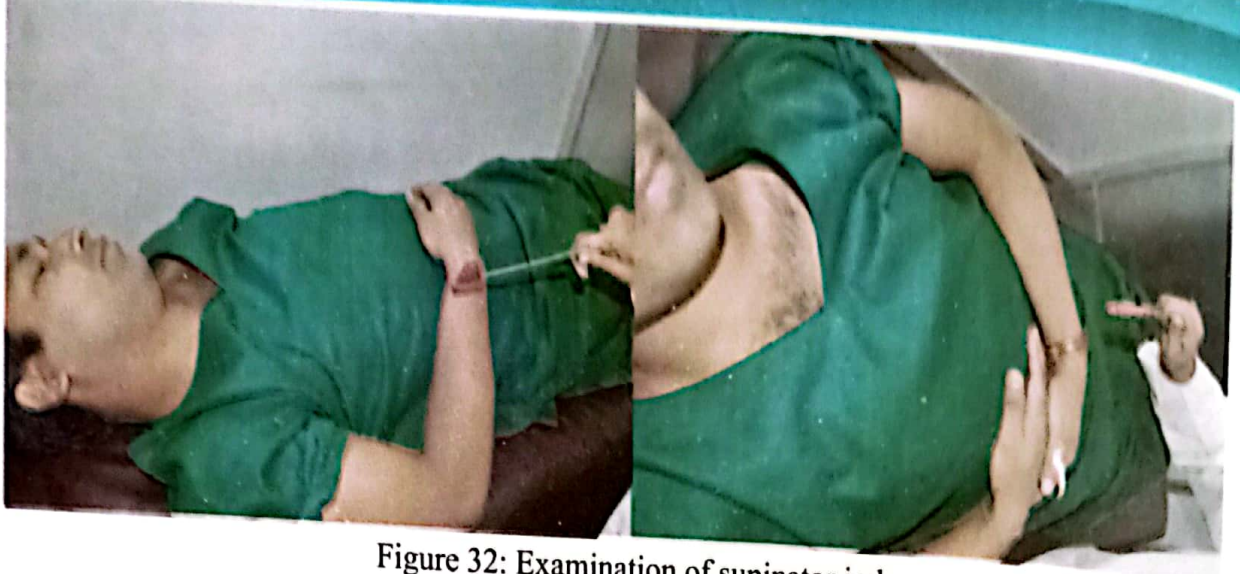

Figure 32: Examination of supinator jerk.

Interpretation of deep jerk: Normally deep jerks are present. Exaggerated deep jerk occurs in upper motor neuron lesion and absent deep jerk occurs in lower motor neuron lesion.

Hoffmann's reflex

The test involves tapping the nail or flicking the terminal phalanx of the middle finger. A positive response is seen with flexion of the terminal phalanx of the thumb (figure 33). Positive sign usually indicates upper motor abnormalities.

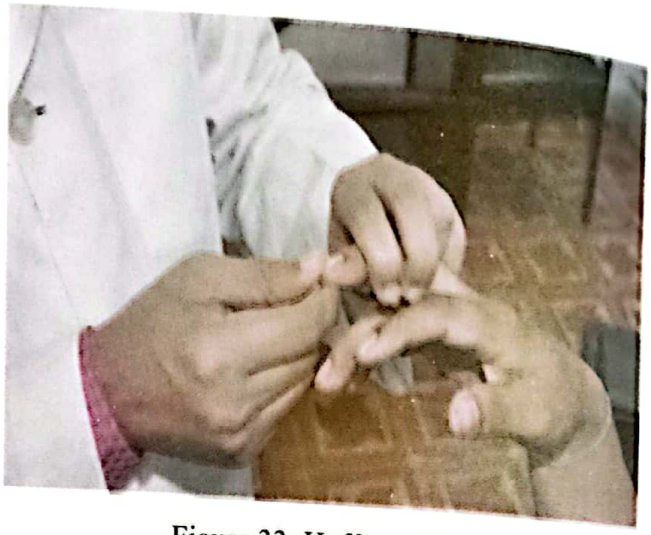

Figure 33: Hoffmann's sign.

Co-ordination of movement

Testing co-ordination of upper limbs

1. Finger-nose test

   I. Place the tip of your index finger in front of the patient's face held at arm's length distance.

   II. Ask the patient to touch his nose and then tip of your finger (figure 34).

   III. Repeat the procedure while changing position of your finger.

   IV. Repeat the procedure with left hand.

Figure 34: Finger-nose test.

2. Dysdiadochokinesis

   I. Place your palm of the hand in front of the patient (commonly patient's own palm is used).

Scanned with CamScanner

Figure 35: Dysdiadochokinesis

II. Ask the patient to tap your palm with the tips of the fingers of one hand, with alternately supination and pronation movement (figure 35).

III. Repeat the procedure with the opposite hand. (Normally the patient can do this very rapidly, but slightly less rapidly with the non-dominant hand).

3. Fine movements

I. Watch the patients dressing or undressing.

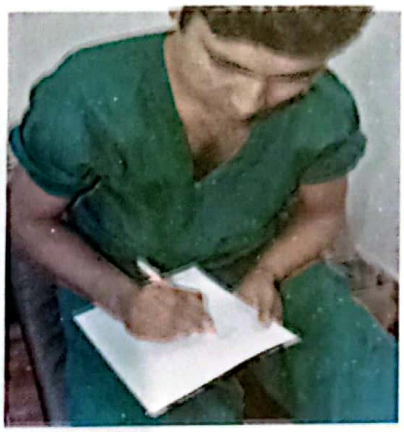

Figure 36: Examination of fine movements (writing).

II. Ask the patient to write, handle a book or picking up pins.

Testing co-ordination of lower limb

1. Heel-shin test

I. Patient should be in supine position.

II. Ask the patient to place the heel of the one foot to the upper part of the shin of the opposite leg and slide the heel down the shin towards the ankle and again return the heel to same way to the upper part of the shin (figure 37).

III. Repeat the same procedure to the other side.

Figure 37: Heel-shin test

Scanned with CamScanner

(In cerebellar ataxia, characteristics, irregular, side to side series of errors in the speed and direction of the movements occurs).

Figure 38: Heel-toe test.

2. Heel-toe test
   I. Ask the patient to stand with bare foot.
   II. Ask the patient to walk in a straight line by placing heel of the foot to the front of the toes (Heel-toe) (figure 38).

Involuntary movement

Any involuntary movements of the limb or face should be noted. Here are few examples of involuntary movements.

Tremor: It is an involuntary, rhythmic movement of one or more parts of the body. Example: Resting tremor occurs in parkinsonism, action tremor in cerebellar lesion etc.

For details please see presenting complaints.

Gait

Ask the patient to stand with bare foot and walk in a straight line. Assess, is there any difficulty in walking and characteristic gait.

Here is few example of gait.

1. Antalgic gait: Also called painful gait, patient walk by giving less pressure on the painful leg.
2. Parkinson's gait-occurs in parkinsonism. Patient walk on small amplitude, with flexion attitude.
3. High stepping gait-occurs in dorsal column lesion.
4. Hemiplegic gait- occurs in stroke with hemiplegia patient.

Scanned with CamScanner

Sensory system

For sensory system examination detail knowledge of the dermatome of the peripheral nerve is necessary. Pain, touch, temperature, joint position and vibration sense usually tested during clinical examination. These sensations are tested according to the dermatome of the peripheral nerve and compared with corresponding dermatome of the other side. Joint position (proprioception) and vibration sense are carried out by the posterior (dorsal) columns and pain and temperature sensation are carried by spinothalamic tract.

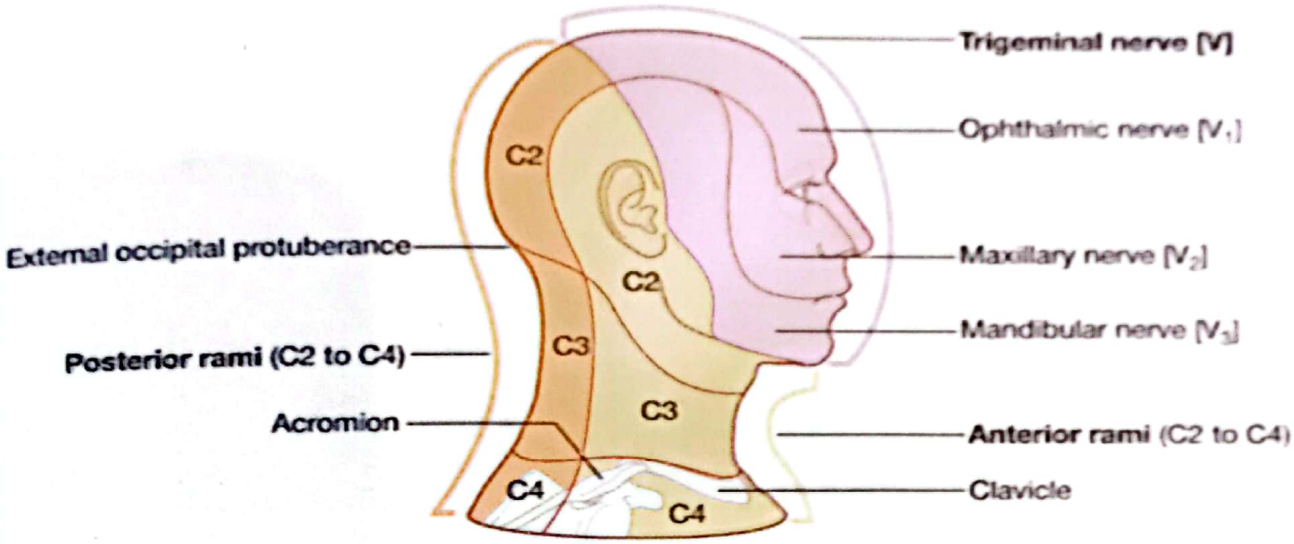

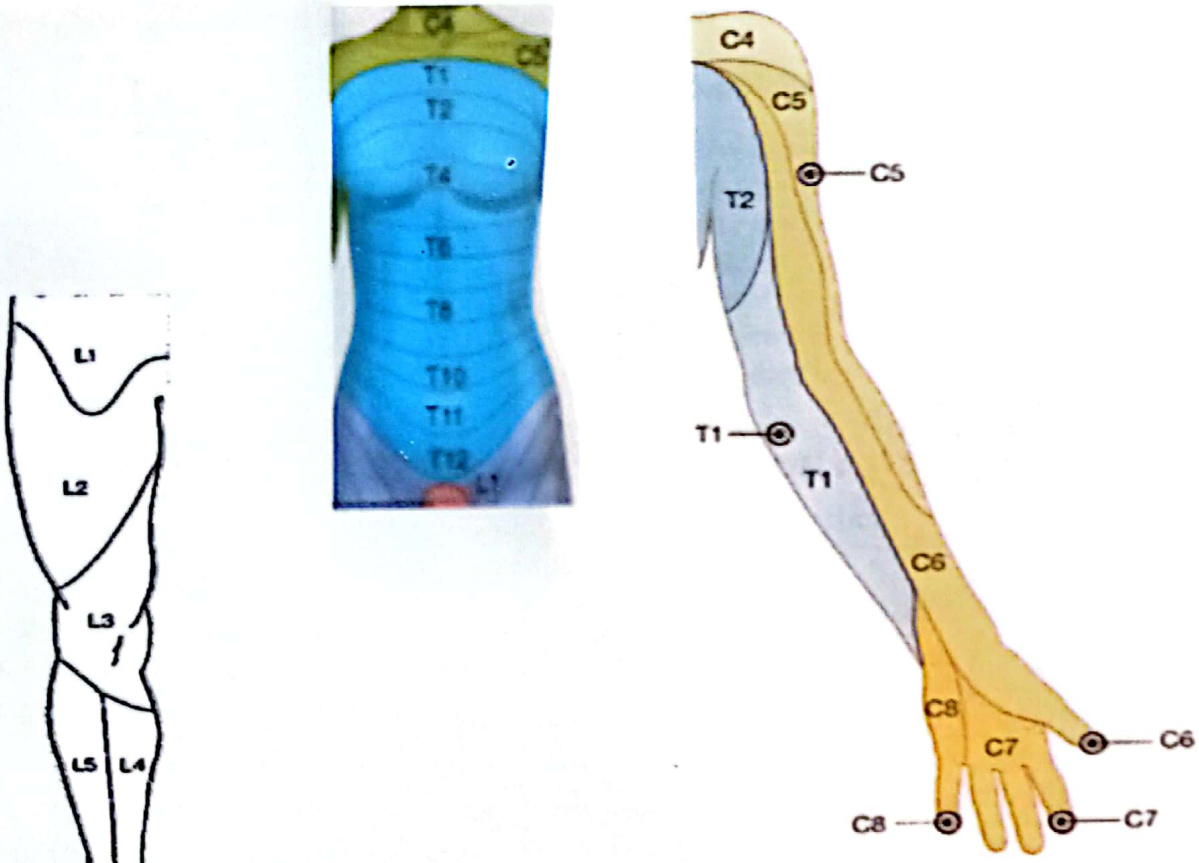

Figure 39: Dermatome of whole body

Scanned with CamScanner

For testing pain sensation use disposable pin, for touch use pointed end of rolled cotton, for temperature use the end of the tuning fork, for vibration sense use tuning fork of 128 Hz.

Sequence of examination of sensory system

1. Greeting and consent.
2. Patient should be in supine position.
3. Place a pointed end of the cotton in forehead and ask whether he/she feel the sensation, if the patient can feel the sensation then tell him that this will be applied in different parts of the body (according to the dermatome), if he feels the sensation then he will tell yes, if not then he will say no (figure 40).

Figure 40: Examination of touch sensation with cotton.

4. Repeat the procedure with pin and basal part of the tuning fork (figure 41).

Figure 41: Examination of pain sensation with pin.

5. Locate the areas where sensory is impaired or absent.
6. For joint position of lower limb-demonstrate the patient with eye open "dorsiflexon of the great toe is 'above' (figure 42 right) and plantar flexion is 'below'." Repeat this procedure with closing of eye of the patient and see whether patient can tell correctly. For upper limb repeat the above procedure with movement of the thumb. If the patient failed to detect the movement of the joint, then move to the proximal joint.

Scanned with CamScanner

Figure 42: Examination of joint position and vibration sense.

7. For vibration sense-use a 128 Hz tuning fork and ensure the tuning fork is vibrating. Place it on the sternum to start with so that the patient can feel the vibration. Then place it on the big toe (figure 36 left). If no vibration is sensed, move backwards to the bony medial malleolus of the ankle, then the tibial shaft then tibial tuberosity and then anterior iliac crest. If in doubt as to the accuracy of the response, ask the patient to close his eyes and to report when you stop the fork vibrating with your fingers.

Signs of meningeal irritation

1. Neck rigidity
2. Kernig's sign
3. Brudzinski sign

Neck rigidity

Passively but gently flex the patient's neck (figure 37). The chin should normally touch the chest without pain.

Causes of neck rigidity

1. Meningitis
2. SAH (Subarachonoid haemorrhage)

Figure 43: Examination of neck rigidity.

Note: In old age and cervical spondylosis neck rigidity may be present, in those condition movements of the neck (cervical spine) particularly restricted to the lateral bending but in neck rigidity of meningitis/SAH neck movements restricted to flexion movement.

Scanned with CamScanner

Kernig's sign

With the flexion of the hip and knee joint gradual extension of the knee joint causing spasm of the hamstring muscles, this respond by changes of facial expression of the patient due to pain. Kernig's sign positive in meningitis and subarachnoid hemorrhage.

Steps of examination of Kernig's sign

1. Greetings and consent.
2. The patient should be in supine position, with the hip and knee joint in flexion.
3. Examiner's left hand should be placed in patient's right thigh and with the right hand grasp the right leg (figure 44), gradually extent the knee joint, patient will wince due to pain result from spasm of the hamstring muscles.
4. Thank the patient. (if patient is unconscious thank need not to give)

Figure 44: Examination of Kernig's sign.

Brudzinski sign

Passive flexon of the neck will cause flexion of the hip and knee joint.

Steps of examination

1. Greetings and consent.
2. The patient should be in supine position.
3. The physician should place one hand behind the patient's head and place the other hand on the patient's chest. The physician then raises the patient's head (with the hand behind the head) while the hand on the chest restrains the patient and prevents the patient from rising. Flexion of the patient's lower extremities (hips and knees) constitute a positive sign. Brudzinski's neck sign has more sensitivity than Kernig's sign.
4. Thank the patient. (if patient is unconscious thank need not to give)

Scanned with CamScanner

When you will suspect the patient has cerebellar lesion?

Cerebellar lesion usually causes inco-ordination of movements in spite of normal muscle power. Clinically when patient present with the complaints of vertigo, intention tremor, unsteadiness of gait or unable to walk then he/she should be suspected as a case of cerebellar lesion.

How you will examine a suspected case of cerebellar lesion patient?

1. Greetings and consent.
2. Patient should be seated first.
3. Look at the eyes of the patient-whether nystagmus present or not. If nystagmus is absent then examine for nystagmus (do ocular movements and check for nystagmus).
4. Ask the patient to pronounce 'Lalmonirhat', if he pronounce like 'lal-mo-nir-hat' then cerebellar lesion present.
5. Do finger-nose test (patient will be unable to do this test accurately).
6. Do the dysdiadochokinesis (patient will be unable to do the finger-nose test accurately).
7. Ask the patient to hold the pen (placed in front of the patient), patient will have tremor of the hand as he reaches the target.
8. Rebound phenomenon-ask the patient to stretch his arms out in front and maintain this position. Push the patient's wrist quickly downward and observe the returning movement. In cerebellar lesion after release your hand, their arm shoots up above the position it originally was and bounces up.
9. Now ask the patient to lie on the bed.
10. Do heel-shin test (patient will be unable to do the heel-shin test accurately).
11. Examination for pendular knee jerk-ask the patient to sit at the corner of the bed with the legs hangs from the bed, then elicit the knee jerk, if cerebellar lesion present the leg will swing like pendulum.
12. Thank the patient.

Note: In cerebellar lesion sign are ipsilateral (same side of the lesion e.g. if lesion in left cerebellar hemisphere then signs will be in left side of the body) but in cerebral lesion signs are contralateral (opposite side of the lesion e.g. if lesion in left cerebral hemisphere then signs will be in right side of the body).

What is Romberg's sign?

Romberg's sign is a test for the position sense. Romberg's sign is said to be positive in patients with sensory ataxia (dorsal column lesion) and negative in cerebellar ataxia. In cerebellar lesion, the patient is often unsteady with the eyes open or closed.

Sequence of examination of Romberg's sign

1. Greetings and consent.
2. The patient is asked to stand with the feet together.
3. Ask the patient to close his eyes (caution should be taken before ask to close the eyes, because patient may fall after closing the eyes). If the patient is steady with eyes open but unsteady with eyes closed then Romberg's sign positive.
4. Thank the patient.

Scanned with CamScanner

The human musculoskeletal system (also known as the locomotor system) is an organ system that gives human the ability to move by using their muscular and skeletal system. The musculoskeletal system provides form, support, stability and movement to the body. Major components of this system are bones, joints, ligaments, tendons etc. Among these, joints are frequently affected by different problems and among the joints, synovial joints are affected more frequently due to their large degree of movements.

Common presenting complaints of the locomotor/musculoskeletal system disorders are:

1. Arthritis
2. Stiffness
3. Synovitis
4. Back and neck pain
5. Oral ulcer
6. Alopecia
7. Raynaud's syndrome
8. Scleroderma/skin tightening
9. Muscle pain and weakness
10. Extra-articular manifestations

Arthritis-inflammation of the joint is called arthritis. Patient usually complains of pain and swelling of the the joint.

Arthralgia- arthralgia means joint pain without inflammation.Patient usually complains of joint pain without any joint swelling.

Depending on number of joint involvement arthritis can be

1. Monoarthritis
2. Oligoarthritis
3. Polyarthritis

Monoarthritis-arthritis of single joint is called monoarthritis. Monoarthritis can be acute when persist for less than 6weeks and chronic when persist for more than 6 weeks. In most of the cases monoarthritis is acute. Chronic monoarthritis may be due to chronic infection with mycobacteria (tuberculosis), fungi or monoarticular presentation of inflammatory arthritis.

Scanned with CamScanner

Causes of acute monoarthritis

1. Septic arthritis
2. OA (knee OA)
3. Crystal synovitis like gout, pseudogout
4. Monoarticular presentation of oligo or polyarthritis
   a. Reactive, psoriatic or other seronegative spondyloarthritis
   b. Erythema nodosum
   c. Rheumatoid arthritis
   d. Juvenile idiopathic arthritis
5. Trauma: especially if associated with haemarthrosis
6. Haemarthrosis associated with clotting abnormality (haemophillia)

Oligoarthritis-arthritis of 2-4 joints is called oligoarthritis.

Causes of oligoarthritis

1. OA (commonest cause)
2. Seronegative spondyloarthritis like ankylosing spondylitis, reactive arthritis, psoriatic arthritis etc.
3. Juvenile idiopathic arthritis
4. Oligoarticular presentation of polyarthritis
5. Erythema nodosum
6. Infection including mycobacteria, infective endocarditis, Neisseria etc.

Polyarthritis-arthritis of five or more joints is called polyarthritis.

Causes of polyarthritis

1. Viral arthritis e.g. rubella, mumps, hepatitis B, Chikungunya virus etc (usually self limiting by 6 weeks)
2. Rheumatoid arthritis
3. SLE
4. JIA
5. Seronegative spondyloarthritis (psoriasis, reactive, ankylosing spondylitis, enteropathic arthropathy)
6. Systemic sclerosis and polymyositis
7. Chronic gout
8. Noninflammatory causes are- generalized osteoarthritis, haemochromatosis, acromegaly.

What is flitting or migratory arthritis/joint pains?

This term is used to describe inflammation beginning in one joint and then involving others, usually one at a time for about 3 days each. Occurs in acute rheumatic fever and gonococcal arthritis.

Scanned with CamScanner

What is palindromic rheumatism?

Acute attack of joint pain associated with redness around the joint, with the attacks lasting about 48 hours (occasionally up to 1 week) and migrating to other joints. This is called palindromic rheumatism, which may progress to rheumatoid arthritis.

Stiffness

Stiffness means difficulty or pain on movement of the joint but also means restriction of range of joint movement. Morning stiffness is a cardinal sign of inflammatory arthritis that can appear even before pain. Early morning joint stiffness that persists for more than 30 minutes is an important symptom of active inflammatory joint disease. A similar "gel" phenomenon can occur if a person is inactive (sleep or taking rest) during the day (inactivity stiffness). In non-inflammatory arthritis (mechanical) stiffness lasts only for few minutes.

Why morning stiffness occur in inflammatory arthritis?

Morning stiffness occurs due to the accumulation of edema fluid within inflamed tissues during sleep, because as there is no movements during sleep or resting condition, edema fluid can not absorb properly. Morning stiffness disappears as edema and products of inflammation are absorbed by lymphatics and venules and returned to the circulation by motion accompanying the use of muscles and joints.

Synovitis (swelling of the joint)

Synovitis is the inflammation of a synovial (joint-lining) membrane, usually painful, particularly on motion and characterized by swelling, due to effusion (fluid collection) in synovial sac. Morning or inactivity stiffness is more marked in synovitis.

Causes of synovitis

1. Inflammatory arthritis e.g. rheumatoid arthritis, seronegative arthritis.
2. Infection of the joint (septic arthritis) e.g. with mycobacteria, staphylococcus etc
3. Acute rheumatic fever.

Back pain

Causes of low back pain

1. Mechanical low back pain
2. Osteoarthritis
3. Seronegative arthritis (e.g. Ankylosing spondylosis, Reactive arthritis etc)
4. Prolapsed intervertebral disc (commonly prolapsed lumbar intervertebral disc, PLID)
5. Vertebral fracture
6. Bone metastasis
7. Spondylolisthesis

Features of mechanical low back pain

1. Pain increase with physical activity (improved with rest)

Scanned with CamScanner

2. Sudden onset, precipitated by lifting or bending
3. Recurrent episodes
4. Pain limited to back or upper leg
5. No clear-cut nerve root distribution
6. No systemic features
7. Prognosis good (90% recovery at 6 wks)

Red flags for possible spinal pathology

History

1. Age: presentation < 20 years or > 55 years.
2. Character: constant, progressive pain unrelieved by rest.
3. Location: thoracic pain.
4. Past medical history: carcinoma, tuberculosis, HIV, systemic corticosteroid use, osteoporosis.
5. Constitutional: systemic upset, sweats, weight loss.
6. Major trauma.

Examination

1. Painful spinal deformity.
2. Severe/symmetrical spinal deformity.
3. Saddle anaesthesia.
4. Progressive neurological signs/muscle-wasting.
5. Multiple levels of root signs.

Neck pain

Causes of neck pain

1. Postural
2. Cervical spondylosis
3. Prolapsed intervertebral disc
4. Spondilitis
5. Rheumatoid arthritis
6. JIA
7. Metastasis
8. Vertebral fracture
9. Referred pain from teeth, pharynx, cervical lymph node, angina pectoris etc.

Oral ulcer

Causes of oral ulceration

A) Aphthous-idiopathic, premenstrual.

B) Infection-fungal (candidal), viral (herpes simplex, HIV), bacteria (syphyllis, tuberculosis).

C) Gastrointestinal diseases-Crohn's disease, coeliac disease.

D) Dermatological conditions-Lichen planus, dermatitis herpetiformis, erythema multiforme.

Scanned with CamScanner

E) Drugs-nicorandil, NSAIDs, methotrexate, penicillamine, losartan, ACE inhibitors, cytotoxic drugs

F) Systemic diseases-SLE, Bechet's syndrome

G) Neoplasia-carcinoma, leukaemia, Kaposi's sarcoma.

Alopecia

There are many causes of alopecia. In connective tissue disease alopecia occur in SLE. Though alopecia is not a criterion of SLE, presence of diffuse, usually nonscarring alopecia occur with active disease.

Raynaud's phenomenon

Raynaud's phenomenon is the characteristic sequence of digital pallor due to vasospasm, cyanosis due to deoxygenated blood, and rubor due to reactive hyperaemia.

Primary Raynaud's phenomenon (or Raynaud's disease)

Raynaud's phenomenon without any underlying cause is called Primary Raynaud's phenomenon (or disease). This affects 5–10% of young women aged 15–30 years in temperate climates and may be familial. It does not progress to ulceration or infarction, and significant pain is unusual. No investigation is necessary. The patient should be reassured and advised to avoid exposure to cold. Long-acting nifedipine may be helpful but sympathectomy is not indicated.

Secondary Raynaud's phenomenon (or syndrome)

Raynaud's phenomenon with underlying specific cause is called secondary Raynaud's phenomenon (or syndrome). This commonly occur in connective tissue disease (most commonly systemic sclerosis or CREST syndrome, SLE, rheumatoid arthritis etc), vibration-induced injury (from the use of power tools) and thoracic outlet obstruction (e.g. cervical rib). It is often associated with fixed obstruction of the digital arteries, fingertip ulceration and necrosis and pain. The fingers must be protected from cold and trauma, infection requires treatment with antibiotic and surgery should be avoided if possible. Vasoactive drugs have no clear benefit. Sympathectomy helps for a year or two. Prostacyclin infusion are sometimes beneficial.

Scleroderma

Scleroderma refers to a group of rare chronic autoimmune diseases in which the skin and connective tissues tighten and harden. There are two types:

Localized scleroderma mainly affects the skin. There are two types of localized scleroderma: morphea and linear.

Systemic scleroderma, also called generalized scleroderma, can involve many body parts or systems. According to the site of involvement systemic sclerosis may be

a) Limited scleroderma: Skin involvement restricted to sites distal to the elbow or knee (apart from the face) is classified as'limited disease' or CREST syndrome.

Scanned with CamScanner

b) Diffuse scleroderma: Skin involvement proximal to the knee and elbow and on the trunk is classified as 'diffuse disease'.

Muscle pain and weakness

Muscle pain and weakness can arise from a variety of causes. It is important to distinguish between a subjective feeling of generalized weakness or fatigue and an objective weakness with loss of muscle power and function. The former is a nonspecific manifestation of many diseases, including depression, whereas the latter is often a sign of primary muscle disease.

Causes of proximal muscle pain or weakness

Inflammatory

Polymyositis, dermatomyositis, inclusion body myositis, polymyalgia rheumatica.

Endocrine

Hypothyroidism, hyperthyroidism, Cushing syndrome, addisson's disease.

Metabolic

Hypokalaemia, osteomalacia.

Drugs and toxins

Statins, fibrates, alcohol, penicillamine.

Infections

Viral (HIV, cytomegalovirus, Rubella, Epstein–barr, Echo), parasitic (schistosomiasis, cysticercosis, toxoplasmosis); bacterial (Clostridium perfringens, Staphylococci, tuberculosis, Mycoplasma).

Extra-articular manifestations

Patients may present with symptoms of extra-articular disease, rather than musculoskeletal features. Weight loss, low-grade fever and malaise are associated with rheumatoid arthritis, SLE. High-spiking fevers in the evening with a rash occur in adult-onset Still's disease. Headache, jaw pain on chewing (claudication) and scalp tenderness are features of temporal arteritis.

Seropositive arthritis: Indicates the presence of IgM rheumatoid factor (RF) in significant titre in the serum of patients with a polyarthritis.

Seronegative arthritis: Indicates the absence of RF in the serum of patients with inflammatory arthritis. Commonly ankylosing spondylitis, reactive arthritis and psoriatic arthritis are known as seronegative arthritis. They are more likely to be associated with HLA B27.

Scanned with CamScanner

Musculoskeletal system includes joints (mainly), bones, ligaments, muscles and tendons. Inflammatory arthritis can lead to irreversible joint damage and lead to disability if not properly treated. So early detection of the musculoskeletal problems is mandatory to prevent irreversible joint damage.

GALS screening

Elaboration of GALS screening is 'gait', 'arms', 'legs' and 'spine'screening, which is a rapid and sensitive screening method for detecting musculoskeletal disorders. A physician can easily detect any musculoskeletal disorders at his chamber within a short period of time by GALS screening.

Steps of GALS screening

GALS screening is a stepwise method, which includes history taking and examination.

GALS history -GALS screening starts with the following questions

1. Do you have any pain or stiffness in your muscles, joints or back?
2. Can you dress yourself completely without difficulty?
3. Can you walk up and down stairs without difficulty?
4. Have you ever had gout or arthritis?

If answers of these questions are negative, the patient is unlikely to have any significant musculoskeletal problem. If the patient answers positively, then further examination is recommended.

Scanned with CamScanner

Practically GALS examination start with gait examination, followed by spine and arm examination, and finally legs should be examined to avoid repeated lying and standing of the patient.

Gait –steps of examination of gait.

1. Greetings and consent
2. Ask the patient to stand with barefooted and walk along a straight line and turn back along the line (figure 1).
3. Thank the patient.

Figure 1: Examination of gait.

What to look during gait examination?

1. Symmetry of both sides of the body
2. Smoothness of the movement
3. Arm swinging during movement
4. Pelvic tilting
5. Stride length
6. Ability to turn quickly
7. Specific gait like painful gait (antalgic gait), waddling gait, hemiplegic gait etc.

Normal findings: Both sides of the body are symmetrical, movements are smooth, arm swing are normal, no pelvic tilt, stride length are normal, patient can turn quickly.

Spine: Steps of examination

1. Greetings and consent.
2. Position of the patient-standing position.
3. From back of the patient-following points to be observed-look for abnormal spinal and paraspinal anatomy, curvature of the spine, any deformity (gibbus) and look at the legs.

Scanned with CamScanner

Figure 2: Inspection of the spine from side of the patient (right) and movement of the thoracic and lumbar spine (left).

4. From side of the patient- look for abnormal spinal posture, and then ask the patient to bend down and to touch his toes (without bending the knee joints) and look movement of the thoracic and lumbar spine (figure 2).
5. From front- ask the patient to 'put your ear on your left then right shoulder' and watch the neck movements (figure 3). Then gently press the mid-point of each supraspinatus muscle to elicit tenderness of hyperalgesia of fibromyalgia.

Figure 3: Examination of neck movements.

Arms: Steps of examination

1. Greetings and consent.
2. Position of the patient-standing position.
3. Stand in front of the patient.
4. Ask the patient to put his both hands behind the head, with the elbows going back (figure 4). This test shows abduction and external rotation of the glenohumeral joint.
5. Ask the patient to place the elbows by the side of the body and bend them 90°. Turn the palms up and down. This tests supination (figure 5 right) and pronation (figure 5 left) of the wrist and elbow.

Figure 4: Abduction and external rotation of the glenohumeral joint

Scanned with CamScanner

Figure 5: Examination of supination and pronation.

Figure: Elbow flexion

6. Ask the patient to bend the arms up to touch the shoulders. This tests elbow flexion.
7. Ask the patient to make a 'prayer sign', bending the wrist back as far as possible. Put the back of the hands together in a similar fashion (figure 6). This tests wrist flexion and extension.



Figure 6: Prayer's sign.

8. Ask the patient to put his arms straight out in front of the body. This tests elbow extension.

Figure 7: Examination of movements of the hand joints.

9. The patient next make fist, and then opens the hands flat (figure 7). This tests both wrists and hands. Inspect the dorsum of the hands and check for full finger extension at the metacarpophalangeal (MCP), PIP and DIP joints.

Scanned with CamScanner

10. Ask him to squeeze your index and middle fingers (figure 8). This tests the strength of the power grip.

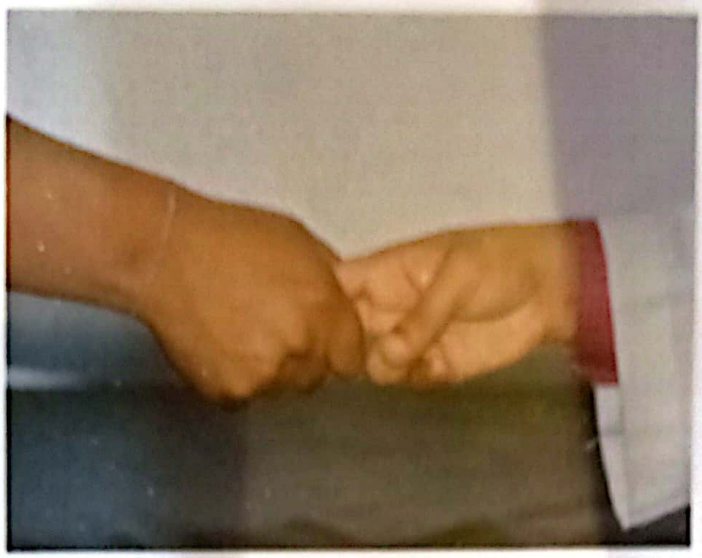

Figure 8: Test of griping.

11. Ask the patient to touch each finger tip with his thumb (figure 9). This tests precision grip and problems in co-ordination or concentration.

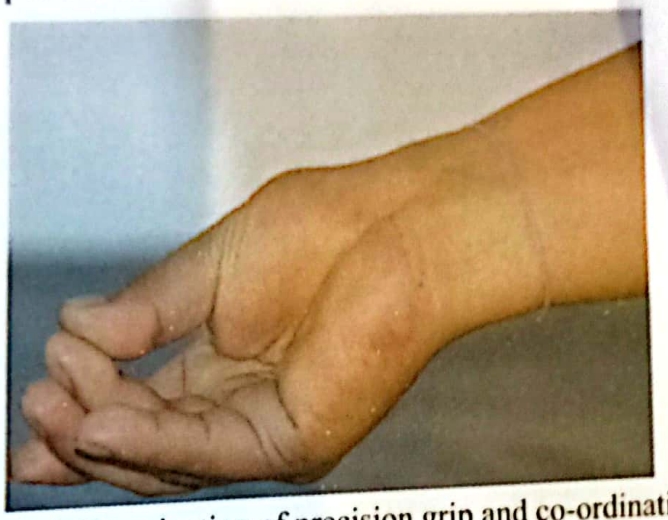

Figure 9: Examination of precision grip and co-ordination.

12. Gently squeeze the patient's metacarpal heads (figure 10). Tenderness suggests inflammation e.g. rheumatoid arthritis, involving the MCP and PIP joints.

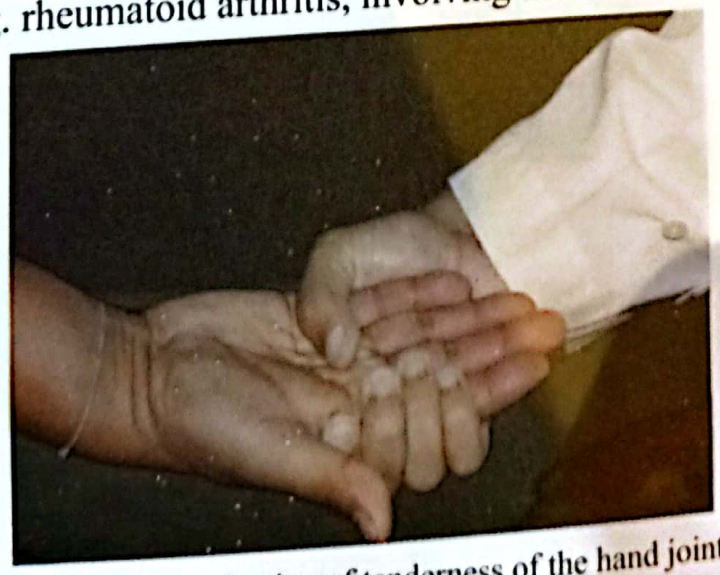

Figure 10: Examination of tenderness of the hand joints.

Scanned with CamScanner

Legs -steps of examination

1. Greetings and consent
2. Inspect the lower limbs for swelling, deformities or limb shortening in standing position.
3. Ask the patient lying on bed

-Flex each hip and knee joint with a hand on the knee to feel for crepitus (figure 11).

Figure 11: Flexion of hip and knee joint.

-Passively rotate each hip internally and look for pain or limitation of movement.

-Palpate each knee for warmth and swelling and press on patella feeling for an effusion (figure 12).

Figure 12: Patellar tap test.

-Squeeze gently across the metatarsals for tenderness.

-Finally inspect the soles of the feet for callosities, ulcer.

Interpretation of GALS screening

Any positive answer needs to elaborate.

Screening questions	
Pain	0
Gout or arthritis	0
Dressing	✓
Walking	✓

Scanned with CamScanner

Normal findings in GALS screening		
	Appearance	Examination
G	✓	✓
A	✓	✓
L	✓	✓
S	✓	✓

With abnormal findings indicated e.g. in rheumatoid arthritis		
	Appearance	Examination
G	×	×
A	×	×
L	×	×
S	✓	✓

Slow painful gait. Synovitis of MCP, MTP, wrists and knee joints.

How to examine a joint?

Examination of a joint can be simplified as 'Look', 'Feel' and 'Move' (move means range of movement, active and passive). These can be applied during examination of any joint.

Inspection

During inspection following points to be noted:

1. Joint swelling-usually occurs due to joint effusion, but may be also due to bony swelling.
2. Deformity –any deformity of the joint should be noted.
3. Joint involvement-symmetrical or asymmetrical, peripheral or axial or both. Symmetrical arthritis usually due to rheumatoid arthritis, asymmetrical arthritis usually due to seronegative arthritis.
4. Overlying skin-redness of the skin overlying the joint usually indicate underlying inflammation commonly due to septic arthritis.

Figure 13: Inspection of the knee joint.

Palpation

During palpation of the joint following points needs to be covered:

1. Temperature-overlying temperature is very important, raise overlying temperature of a joint usually result from underlying inflammation (rheumatoid arthritis, septic arthritis). Normal temperature is usually in non-inflammatory joint disease e.g. OA.

Scanned with CamScanner

Figure 14: Examination of temperature of the knee joint.

2. Tenderness-tenderness is important for assessing the severity of the joint disease. This graduation depending on the patient's reaction to firm pressure of the joint between finger and thumb. If tenderness is present first localize it as accurately as possible whether it arises in the joint or in neighboring structures, then assess grading of tenderness.

   Depending on patient's reaction there are 4 grades of joint tenderness.

Grade	Patients reaction
Grade 1	The patient says the joint is tender
Grade 2	The patient winces to pain
Grade 3	The patient winces to pain and withdraw the affected part
Grade 4	The patient will not allow the joint to be touched. Grade 4 tenderness occurs in septic arthritis, acute rheumatic fever, acute gout

3. Joint crepitus-this can be detected by feeling the joint with one hand while moving it passively with the other. This may indicate osteoarthritis or loose bodies (cartilaginous fragments) in the joint space, but should be differentiated from non-specific clicking of the joints.

4. Tendon sheath crepitus- this is a grating or creaking sensation defined by palpating the tendon while the patient is asked to contract the muscle tendon complex involved. It is particularly common in the hand and is seen in rheumatoid arthritis and systemic sclerosis.

5. Range of movement- required to estimate the degree of limitation based on comparison with the normal side or on the examiner's previous experience. Actual range of movement should be measured with a protractor (goniometer). Both active and passive movements should be assessed. Range of movement should be measured in degrees from neutral position and compare with the opposite side.

Scanned with CamScanner

Active movement, however, may give a poor estimation of true range of movement because of muscle spasm due to pain. In testing the range of passive movement, always be gentle, particularly when the joint is painful. Limitation of movement in a joint may be due to pain, muscle spasm, contracture, inflammation, increased thickness of the capsular or periarticular structures, effusion into the joint space, bony overgrowths, bony ankylosis etc.

Examination of individual joint

The spine

Inspection

During inspection of the spine following points to be noted

1. Curvature of the spine- normal thoracolumbar spine is 'S' shape curve. Abnormal curvature may be in an anterior, posterior or lateral direction.

   Lordosis-anterior curvature is termed lordosis, normal lordotic curve present in cervical and lumbar spine. Kyphosis-posterior curvature is termed kyphosis. Normally thoracic spine exhibits a slight smooth kyphosis, which increases in elderly and in osteoporosis. Scoliosis- lateral curvature is termed scoliosis. It is due to muscle spasm (e.g. with lumbosacral disc protrusion syndromes) and inequality of leg length.
2. Gibbus-localized angular deformity of the spine is called gibbus. Gibbus usually caused by pott's disease (spine tuberculosis), fracture, metastatic malignant deposit.
3. Any deformity, or any other abnormality.
4. Local projection.

Palpation

1. Temperature-temperature over the cervical spine should be examined. Local temperature may be increased in inflammation of the spine, though it is the less common site of infection.
2. Tenderness-tenderness over the spine should be examined and graded accordingly (grade 1, grade 2 etc).
3. Range of movement-following movements should be tested. Neutral position of the spine is must, before testing range of movement. The neutral position of the spine is an upright stance with head erect and chin drawn in.

   Cervical spine-following movements of the cervical spine should be examined-

   a) Flexion (ask the patient to touch the chin to the chest) (figure 15a).

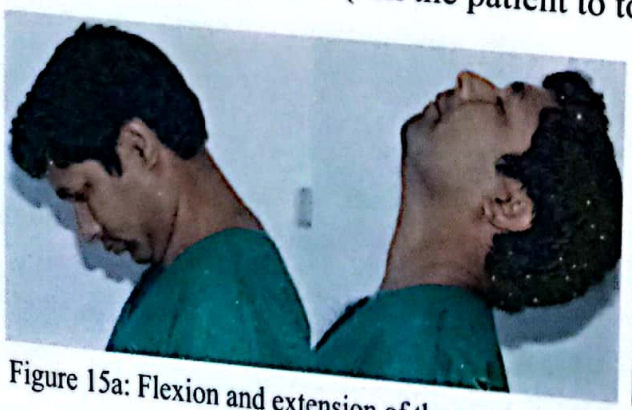

Figure 15a: Flexion and extension of the cervical spine



Figure 15b: Lateral bending of cervical spine

Scanned with CamScanner

b) Extension (ask the patient to look up to the ceiling) (figure 15a).

c) Lateral bending (ask the patient to bend the neck sideways and to try to touch the shoulder with the ear without raising the shoulder) (figure 15b).

d) Rotation (ask the patient to look over one then the other shoulder) (figure 15c).

In rheumatoid arthritis, particular care is necessary when examining the neck, as atlantoaxial instability may lead to damage to the spinal cord when the neck is flexed. In patients with cervical injury, never try to elicit range of movement of the neck. Instead, splint the neck and image the neck to detect any fracture or dislocation.

Thoracic spine-thoracic spine has very minimum movement. The main movement is rotation. Examination of movement of thoracic rotation- patient should be in sitting position, with arms crossed, twist round the trunk to the left and right as far as possible (figure 16).

Figure 15c: Rotation of cervical spine

Figure 16: Rotation of thoracic spine

Lumbar spine-lumbar spine has following movements

a) Flexion -ask the patient to try to touch his toes, without bending at the knees (17b).

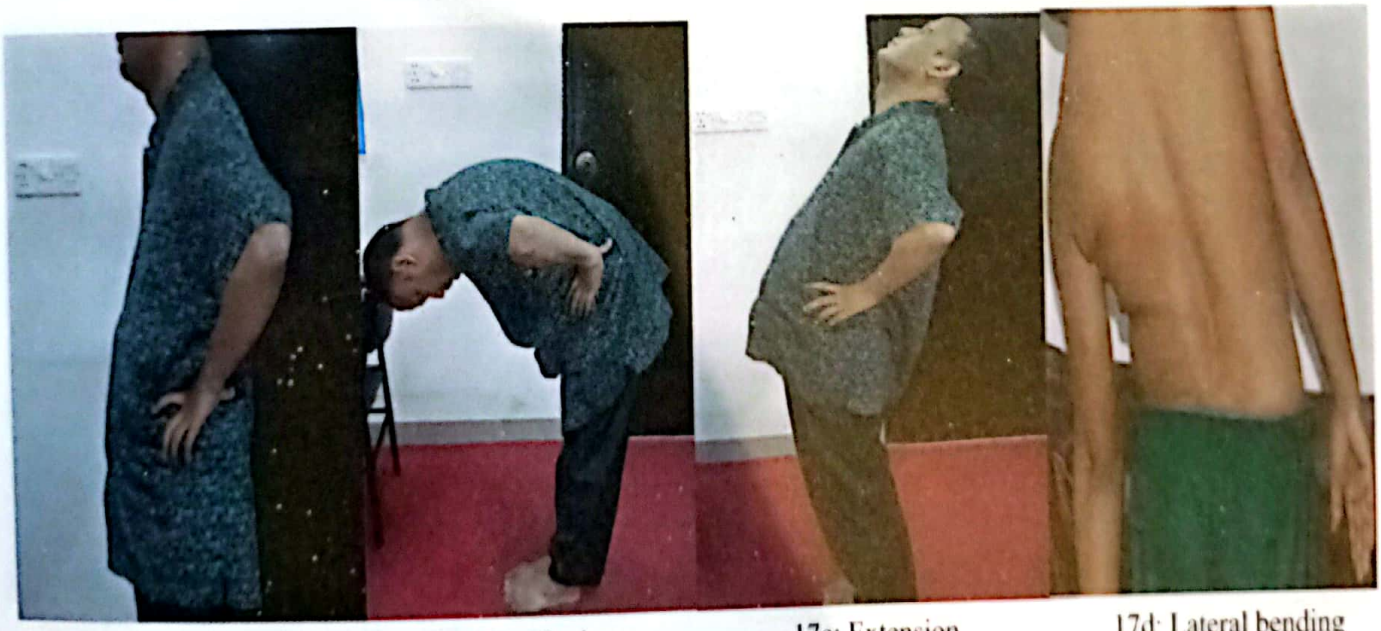

Figure: 17a: Neutral position 17b: Flexion 17c: Extension 17d: Lateral bending

Figure 17: Movements of lumbar spine

b) Extension -ask the patient to bend backwards (figure 17c).

c) Lateral bending-ask the patient to run the hand down the side of the thigh as far as possible (figure 17d).

Scanned with CamScanner

Additional/Special test for lumbar spine

1. Straight leg raising test (SLR)-straight leg can be raised normally 30 to 70 degrees SLR stretches L5 & S1 nerve root by 2-6 mm. Thus positive SLR test suggests lesion a L5 S1 usually due to herniated intervertebral disc.

Steps of examination of SLR test

1. Patient should be lying down on his or her back on an examinatio.ı table or exam floor.

2. Lift the patient's leg while the knee is straight, while lifting the leg look to the face of the patient (figure 18).

3. If patient experience pain is at an angle of between 30 and 70 degrees, then the test is positive.

4. This SLR test can be falsely positive in hamstring muscles spasm; this can be distinguished by Lasègue's sign.

Figure 18: Straight leg raising test (SLR).

Scanned with CamScanner

How to test Lasègue's sign?

Do the maneuver as of SLR test, when patient experience pain, slightly lower the leg to just below the limit of SLR (this will relieve pain of radiculopathy) and then do gentle passive dorsiflexion of the foot (figure 19), if the pain returns then it is due to radiculopathy (prolapsed disc), if pain do not return then due to hamstring muscles spasm.

Figure 19: Lasègue's sign

2. Reflex and sensory examination of lower limb. See nervous system chapter for details.
3. Schober's test: It is a physical examination used to measure the ability of a patient to flex the lumbar spine.

a) Patient should be in standing position

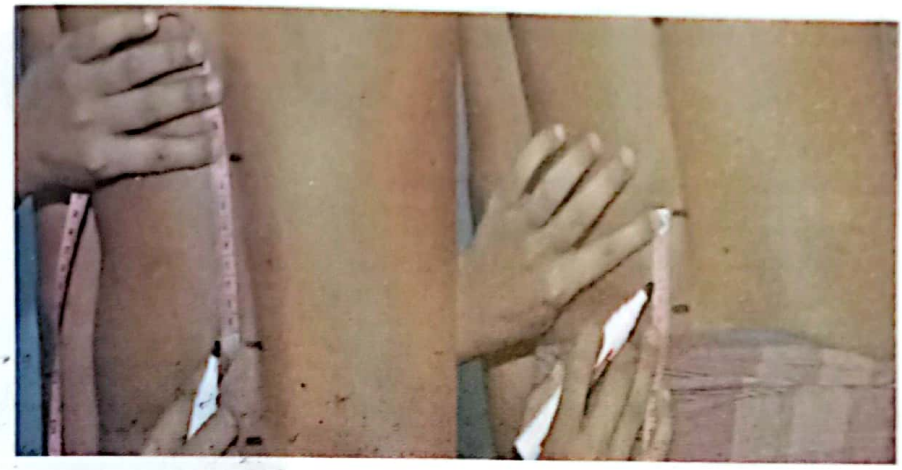

Figure 20: Examination of Sober's test, marking point 'A' (right) and 'B' (left).

b) Mark a point with skin marker over the lumbar spine at the level of the dimple. Mark another 2 points, one (A) 10 cm above this point (figure 20 right) and another (B) 5 cm below this point (figure 20 left). So total length between these points (A-B) is 15 cm.

c) Ask the patient to full flex the lumbar spine and measure the distance between 2 lines (A-B) (figure 21).

Figure 21: Examination of Sober's test, full flexion of lumbar spine and measurement of distance between 'A' and 'B'.

Scanned with CamScanner

d) Interpretation of Schober's test

a) Normal: distance between 2 lines (A-B) increases to >20 cm from 15 cm.

b) Abnormal: distance does not increase to >20 cm which suggests decreased range of movement of lumbar spine.

4. Modified Schober's test-it is the test to detect the extent of flexion of the lumbar spine accurately. With skin marker mark a vertical 10-cm line on the skin overlying the lumbar spinous processes and the sacral dimples. Measure the increase in the line length on flexion. Normally this should be 5 cm or more.

The sacroiliac joints

The surface markings of these joints are two dimples low in the lumbar region. Steps of examination

1. Direct pressure over each sacroiliac joint.
2. Firm pressure with the side of the hand over the sacrum.
3. Inward pressure over both iliac bones with the patient lying on one side, in an attempt to distort the pelvis.
4. Flex the hip to 90° and exert firm pressure at the knee through the femoral shaft (this should only be done if the hip and knee are not painful).

What are the causes of painful restriction of spinal movement?

1. Cervical and lumbar spondylosis.
2. Vertebral disc disease (commonly PLID).
3. Mechanical disorders of the back or neck.

What are the causes of a rigid lumbar spine?

1. Staphylococcal or tuberculous discitis
2. Ankylosing spondylitis
3. Secondaries in spine

In mechanical or osteoarthritic back problems, flexion and extension are reduced more than lateral movements. In prolapsed intervertebral disc lesions lateral bending of lumbar spine restricted, sustained gentle lumbar extension may reproduce the low back pain and sciatic radiation.

The shoulder joint-steps of examination

1. Greetings and consent.
2. Proper exposure of the shoulder joint including the axilla.

Scanned with CamScanner

3. Inspection-carefully inspect the shoulder joint for:

a) Any deformity of anterior glenohumeral and acromioclavicular joint dislocation.

b) Swelling of the joint- may occur in dislocations, proximal humeral fractures, haemarthrosis and inflammatory conditions.

c) Muscle wasting-wasting of supraspinatus or infraspinatus indicates a chronic tear of their tendons.

d) Size and position of the scapula-may be elevated, depressed or 'winged'. 'Winging' of the scapula due to paralysis of the nerve to the serratus anterior.

Figure 22: Neutral position of the shoulder joint.

4. Movement-before testing movement, neutral position is mandatory. The neutral position (figure 22) is with the arm to the side, elbow flexed to 90° and forearm pointing forwards. The following movements should be tested:

a) Flexion-from the neutral position move the arm forwards (figure 23a).

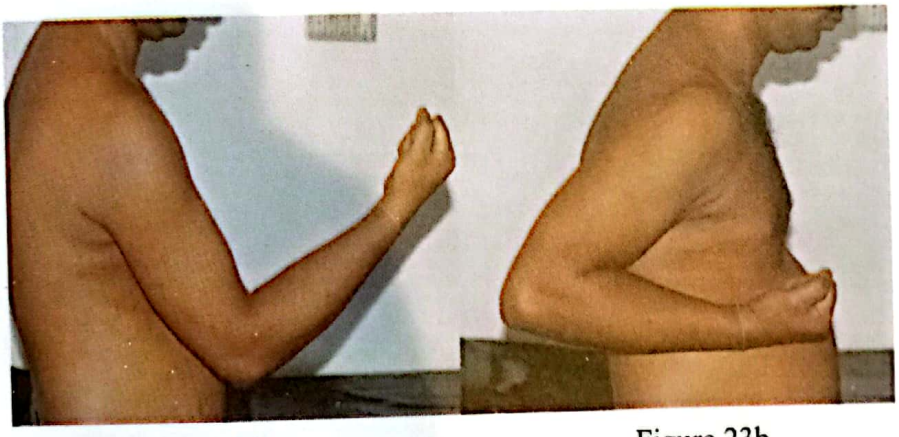

Figure 23a Figure 23b

Figure 23: Flexion (23a) and extension (23b) of the shoulder joint.

b) Extension- from the neutral position moves the arm backwards (figure 23b).

c) Abduction- from the neutral position move the arm outwards.

d) Rotation in abduction.

e) Rotation in neutral position.

Scanned with CamScanner

Figure 24: Elevation of the shoulder joint.

f) Elevation (also involving scapular movement)-with the extended elbow joint move the whole upper limb to outwards and upwards (figure 24).

The elbow joint-steps of examination

1. Greetings and consent
2. Proper exposure
3. Inspection-look for any deformity and swelling of the joint
4. Palpation-palpate the bony contour and feel for focal tenderness, over the lateral or medial epicondyle. When isolated to one site, this may indicate 'tennis' (lateral) or 'golfer's' (medial) elbow.



Figure 25: Neutral position of the elbow joint.

5. Movement-the neutral position is with the forearm in extension (figure 25). The following movements should be tested
   a) Flexion-ask the patient to touch his shoulder on that side with the pulp of the fingers and see the limit of flexion of the elbow joint (figure 26).
   b) Hyperextension-straighten the elbow from flexion position.
   c) Supaination and pronation-ask the patient to put his elbows by the side of the body and flex them to 90°. Now ask the patient to turn the hands upwards to face the ceiling (supination) and then downwards to face the floor (pronation) (figure 27).

Figure 26: Flexion of the elbow joint.

Scanned with CamScanner

Figure: Supination

Pronation

Figure 27: Supination and pronation

Special tests of elbow joint

Tennis elbow (lateral epicondylitis)

1. Greetings and consent
2. Ask the patient to flex the elbow to 90°.
3. Pronate and flex the hand/wrist fully (figure 28).
4. Support the patient's elbow. Ask him to extend the wrist against your resistance (figure 26).
5. Pain is produced at the lateral epicondyle and may be referred down the extensor aspect of the arm.

Figure 28: Examination of Tennis elbow.

Golfer's elbow (medial epicondylitis)

1. Greetings and consent
2. Ask the patient to flex the elbow to 90° and supinate the hand/wrist fully (figure 29).
3. Support the patient's elbow.
4. Ask him to flex the wrist against your resistance. Pain is produced at the medial epicondyle and may be referred down the flexor aspect of the arm.

Figure 29: Examination of Golfer's elbow.

Scanned with CamScanner

The wrist joint-steps of examination

1. Greetings and consent
2. Proper exposure of the joint
3. Inspection-look for swelling, deformity of the joint.
4. Movement-the neutral position is with the hand in line with the forearm, and palm down. The following movements should be tested (figure 30)
   a) Dorsiflexion (extension)
   b) Palmar flexion.
   c) Ulnar deviation.
   d) Radial deviation

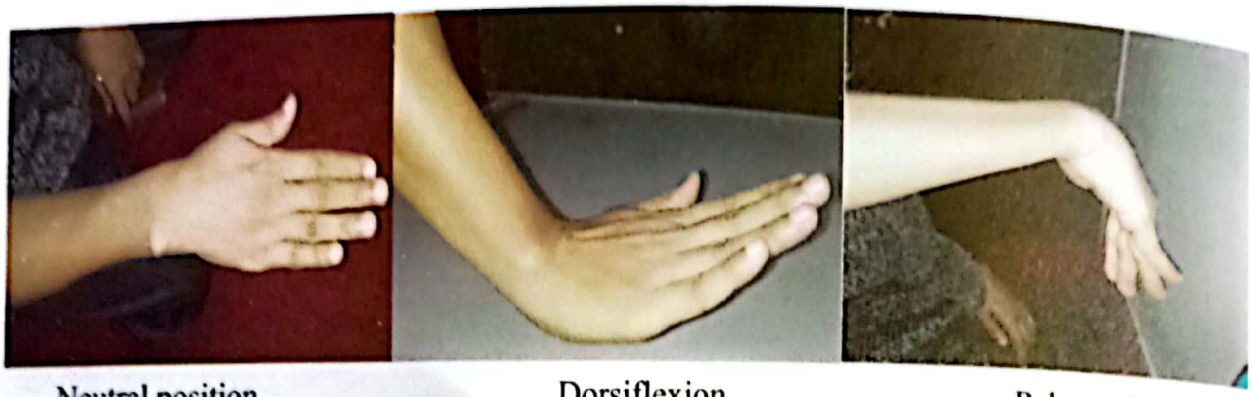

Neutral position Dorsiflexion Palmar flexion

Radial deviation Ulnar deviation

Figure 30: Movement of wrist joint

Examination of hands

This is particularly for postgraduate student and less practiced in under graduate level. Examination of hand may be for rheumatological disease and also for neurological disease. So, when ask to examine the hand first look for whether the patient have rheumatological disease or neurological disease, then consume more time in that particular disease related examination. If nothing can be predicted then do all the examinations serially.

1. Greetings and consent.
2. Patient should be in sitting position.
3. Ask the patient to place the both hand over a pillow placed in front of him (figure 31).

Scanned with CamScanner

Figure 31: Inspection of the hands.

4. Look for any joint swelling (swelling of PIP, DIP, MCP, wrist), deformity (swan neck, Boutonniere deformity, Z-deformity etc), ulcer, gangrene rheumatoid nodule etc.
5. Look for muscle wasting (generalized wasting of hand occur in C8 and T1 leison, wasting of the thenar eminence (occurs in median nerve lesion) or hypothenar eminence (occurs in ulnar nerve lesion), wasting of dorsum of the hand occurs in ulnar nerve leison etc).
6. Prayer's sign –ask the patient to make apposition of the both palm (figure 32). Look for the range of extension of the wrist joint and look for the deformity of fingers.

Figure 32: Prayer's sign.

7. Inverse prayer's sign- ask the patient to make apposition of the both dorsum of the hands. Look for range of flexion of the wrist joint and any swelling or deformity of the wrist joint.
8. Palpation of the joint-feel the temperature of hand joints and compare with the forehead. Then see tenderness of the joint. Every joint should feel for tenderness and graded accordingly.
9. Assess the functional activity of the hands-ask the patient to use a glass, open the button, write with a pen, grip strength (ask to squeeze your fingers) and key grip (give a key, ask the patient to move the hand with the key, as in unlocking).
10. Look and feel for any rheumatoid nodule.
11. Test of carpal tunnel syndrome-

Tinel's sign-ask the patient to take the hand infront, then taps over the median nerve in inner side of the wrist joint (figure 33). If the patient feel tingling, numbness, "pins and needles," or a mild "electrical shock" sensation in his hand (along the distribution of median nerve) then he/she has carpal tunnel syndrome.

Scanned with CamScanner

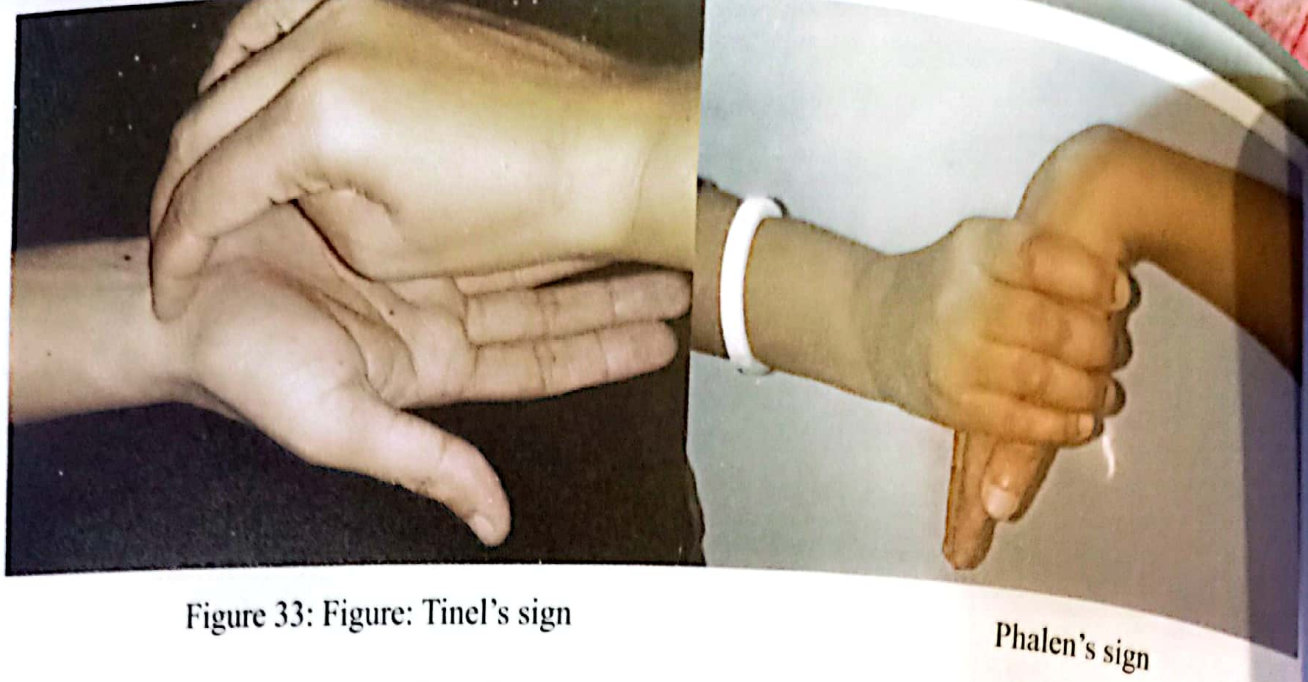

Figure 33: Figure: Tinel's sign

Phalen's sign

Phalen's sign-gently flex the wrist joint of the patient and letting hang down for about 60 seconds. If patient feel tingling, numbness, or pain in the hand (along the distribution of median nerve) within 60 seconds then he/she has carpal tunnel syndrome (figure 33).

12. Neurological examination- for motor function-

a) Ask the patient to 'open and close the hands' as quickly as possible (figure 34) (observe the weakness and evidence of myotonia dystropica).

Figure 34: Open and close the hands.

Scanned with CamScanner

b) Put your thumb towards the ceiling and stop me from bending it (test of abductor pollicis brevis) (figure 35).

Figure 35: Test of abductor pollicis brevis

c) Fix the tip of the little finger and thumb and stop me from aparting it (test of opponens pollicis) (figure 36).

Figure 36: Test of opponens pollicis.

d) Spread your fingers wide apart and stop me from pushing them together (test of dorsal interrossei, dorsal abduction, DAB) (figure 37).

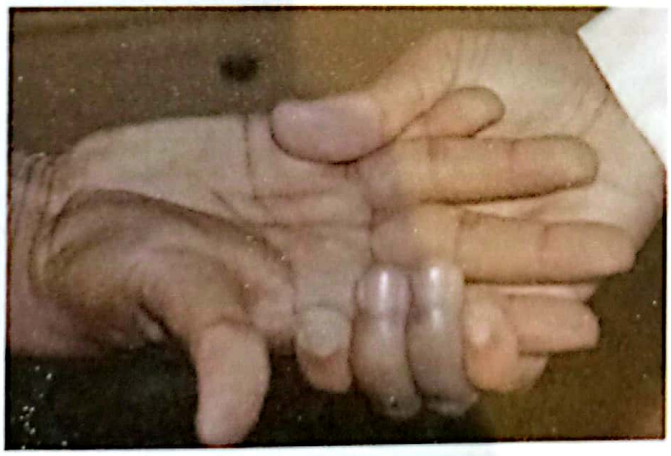

Figure 37: Test of dorsal interrossei.

e) Hold a piece of paper between thumb and index finger and stop me taking it out (test of adductor pollicis, if muscle is paralyzed patient can hold the paper by flexing the thumb: Froment's sign) (figure 38).

Scanned with CamScanner

Figure 38: Froment's sign.

f) Squeeze my fingers (test of C8 and T1 lesion), long and short flexors of the fingers.

g) Sensory examination-along the sensory distribution of the median and ulnar nerve.

13. Other examination-radial pulse should be examined to see any absence of pulse.

14. Thank the patient.

Examination of hip joint:

1. Greetings and consent
2. Inspection-Look for scars and wasting of the gluteal and the thigh muscles.
3. Palpation-The neutral position is with the hip in extension and the patella pointing forwards. Following movements should be tested (figure 39)

   a) Flexion: Extent of flexion usually measure with knee bent. Opposite thigh must remain in neutral position. Flex the knee as the hip flexes.

   b) Abduction: Measured from a line that forms an angle of 90° with a line joining the anterior superior iliac spines of both sides. Move the whole lower limb to outwards.

   c) Adduction (measured in the same manner) and move the whole lower limb to inwards.

   d) Extension: attempt to extend the hip with the patient lying in the lateral or prone position.

   e) Rotation in flexion.

   f) Rotation in extension.

Scanned with CamScanner

Neutral position Flexion

Abduction

Figure 39: Movements of hip joint

Additional examination of the hip joint

Thomas test: Test for flexion deformity. With one hand flat between the lumbar spine and the couch, flex the normal hip fully to the point of abolishing the lumbar lordosis. The spine will come down into the hand, pressing it into the couch. If there is a flexion deformity on the opposite side, the leg on that side will move into a flexed position.

Trendelenburg test: Observe the patient from behind and ask him to stand on one leg. In health, the pelvis tilts upwards on the side with the leg raised. When the weight bearing hip is abnormal, owing to pain or subluxation, the pelvis sags downwards due to weakness of the hip abductors on the affected side.

Examination of knee joint

1. Greetings and consent
2. Proper exposure of the knee joints

Scanned with CamScanner

3. Inspection- inspection should be done in both standing and supine position of the patient (figure 40 right). During inspection following points to be noted

a) Any joint swelling-swelling of the joint may be due to joint effusion resulting from inflammatory arthritis, septic arthritis, haemathrosis due to haemophillia or anticoagulant therapy.

b) Wasting of the thigh muscles-wasting of the thigh muscle usually due to chronic inflammation of the knee joint.

c) Inspection of the back of the knee joint (popliteal fossa)-Baker's cyst occurs in rheumatoid arthritis may be present in popliteal fossa.

d) Deformity of the joint-valgus (lateral angulation of the tibia) or varus (medial angulation) deformity of the knee joint should be inspect on the couch and on standing.

e) Overlying skin-redness of the skin overlying the knee joint usually indicate underlying septic arthritis.

Figure 40: Inspection of the knee joint (right)
and examination of temperature of the knee joint (left).

4. Palpation-during palpation following points to be noted

a) Temperature- first feel for the temperature of the knee joint by the dorsum of the palm (figure 40 left) and compare with forehead. Temperature usually raise in inflammatory arthritis of the knee joint.

b) Tenderness-grapes and gradually press the knee joint to elicite tenderness, express the tenderness in grading.

c) To detect joint effusion-

Scanned with CamScanner

Patellar tap test: With the patient's knee extended, empty the suprapatellar pouch by sliding your left hand down the thigh until you reach the upper edge of the patella. Keep your hand there and, with the finger tips of your right hand, press down briskly and firmly over the patella(figure 41). In a moderate-sized effusion you will feel a tapping sensation as the patella strikes the femur. You may feel a fluid impulse in your left hand.

Figure 41: Patellar tap test.

Bulge test (for small effusions): In which the medial parapatellar fossa is emptied by pressure of the flat of the hand sweeping proximally. The bulge is seen to refill as the suprapatellar area is emptied by pressure from the flat hand.

5. Movement-neutral position of the knee joint is with the extension of the knee joint. Two types of movements is possible in knee joints-flexon and extension. With the patient supine ask him to flex the knee up to the chest and then extend the leg back down to lie on the couch. Feel for crepitus between the patella and femoral condyles. Crepitus usually present in OA of knee joint.

Examination of ankle joint and foot

1. Greetings and consent.
2. Proper exposure of the ankle joints.
3. Inspection- during inspection following points to be noted.
   a) Any joint swelling-swelling of the joint may be due to joint effusion resulting from inflammatory arthritis, septic arthritis etc. Swelling of the 1st metatarso-phalangeal joint is usually due to gout.
   b) Deformity of the joint
   c) Overlying skin-redness of the skin overlying the joint usually indicate underlying septic arthritis.
   d) Wasting of the calf muscles-may occur in long standing ankle joint disorders.

Scanned with CamScanner

5. Palpation-during palpation following points to be noted

a) Temperature- first feels for the temperature of the ankle joint by the dorsum of the palm and compare with forehead. Temperature usually raised in inflammatory arthritis of the ankle joint.

b) Tenderness-grasp and gradually press the ankle joint to elicite tenderness, express the tenderness in grading.

6. Movement- following movements of ankle joint should be tested

a) Dorsiflexon-ask the patient to move the foot towards his body, while the examiner will put resistance (figure 42a).

b) Planterflexon- ask the patient to move the foot away from his body, while the examiner will put resistance (figure 42b).

Figure: 42a Figure: 42b

Figure 42: Planter flexion (42a) and dorsiflexion of the foot (42b).

For foot following movements should be tested

a) Inversion (figure 43a)

b) Eversion (figure 43b)

Figure: 43a Figure: 43b

Figure 43: Inversion (43a) and eversion of the foot (43b).

Scanned with CamScanner

Components of the renal system are kidneys, ureter, urinary bladder and urethra. The clinical examination of the kidneys and urinary bladder detailed in alimentary system. Here only the presenting complaints of the renal system will be discussed.

Common presenting complains of renal system disorders

1. Dysuria
2. Frequency of micturition
3. Haematuria
4. Oliguria
5. Anuria
6. Polyuria
7. Nocturia
8. Incontinence of urine

Dysuria

Dysuria is a symptom of pain, discomfort or burning sensation during micturition.

Causes of dysuria

1. UTI (urinary tract inection)-commonest cause.
2. Urethritis-urethritis is an inflammation of the urethra. It is usually caused by sexually transmitted diseases (such as chlamydia and gonorrhea).
3. Vaginitis-vaginitis is an inflammation of the vagina. It can be caused by an allergic reaction to an irritating chemical (spermicide, douche, bath soap), after menopause, infection like bacterial vaginosis, candidiasis, trichomoniasis etc.

Frequency

Frequency describes micturition more than a patient's expectations.

Causes

1. UTIs (urethritis, cystitis, prostatitis) or urethral syndrome
2. DM
3. Anxiety
4. Consequence of polyuria
5. Diuretic therapy
6. Diabetes insipidus

What is haematuria?

Haematuria means presence of blood in the urine. It may be macroscopic (visible) or microscopic (invisible). In case of microscopic haematuria in female first exclude menstruation, because in this period RBC may be found in urine even 3-4 days after cessation of menstruation.

Scanned with CamScanner

Causes of haematuria

Painless

1. Glomerulonephritis
2. UTI (urinary tract infection)
3. Tuberculosis of the urinary tract
4. Acute tubular necrosis
5. Renal ischaemia (renovascular disease)
6. Tumours of the kidney, ureter, bladder or prostate
7. After severe exercise
8. Coagulation disorders, anticoagulant therapy

Painful

1. Stone in any part of the urinary tract
2. Adult polycystic kidney disease

What are the common causes of haematuria?

1. Stone in any part of the urinary tract
2. UTI
3. AGN (acute glomerulonephritis)
4. Tumour in any part of the urinary tract
5. Bleeding disorder

Oliguria-is the passage of <500 ml of urine per day.

Causes

1. Dehydration due to any cause (vomiting and diarrhoea)
2. Acute renal failure
3. Less intake of water

Anuria-is the complete absence of urine flow.

Causes

1. Acute renal failure
2. Obustructive anuria is seen in case of acute rention of urine due to any cause.

Polyuria-passess of inappropriately high volume urine (> 3 L/day) is called polyuria. Polyuria usually associated with frequency and nocturia.

Causes of polyuria

1. Excess fluid intake
2. Osmotic, e.g. hyperglycaemia, hypercalcaemia

Scanned with CamScanner

3. Cranial diabetes insipidus (reduced ADH secretion). Causes are-
   Idiopathic (50%), mass lesion, trauma, infection.
4. Nephrogenic diabetes insipidus (tubular dysfunction)
   a) Genetic tubular defects
   b) Drugs/toxins, e.g. lithium, diuretics
   c) Interstitial renal disease
   d) Hypokalaemia, hypercalcaemia

Nocturia- waking up at night to void urine, which interrupting sleep, is called nocturia.

Causes

1. Nocturia may be a consequence of polyuria
2. Fluid intake or diuretic use in the late evening
3. CKD
4. Prostatic enlargement
5. Sleep disturbance

Urinary incontinence

Urinary incontinence is defined as any involuntary leakage of urine.

Stress incontinence-in stress incontinence leakage occurs because passive bladder pressure exceeds the urethral pressure, due to either poor pelvic floor support or a weak urethral sphincter. Most often there is an element of both. This is very common in women and most often seen following childbirth.

Urge incontinence- in urge incontinence leakage usually occurs because of detrusor over-activity producing an increased bladder pressure which overcomes the urethral sphincter (motor urgency). Occurs in UTI or bladder stone

Continual incontinence- this suggests the presence of a fistula, usually between the bladder and vagina (vesicovaginal) or the ureter and vagina (ureterovaginal).

Overflow incontinence- this occurs when the bladder becomes chronically over-distended. It is most commonly seen in men with benign prostatic hyperplasia or bladder neck obstruction. Other causes are

1. Neurological diseases e.g. multiple sclerosis
2. Bladder outlet obstruction
3. Pelvic floor weakness following childbirth
4. Urinary tract infection
5. Childbirth, pelvic surgery or radiotherapy
6. Detrusor instability

Scanned with CamScanner

What is urgency?

Urinary urgency is an immediate unstoppable urge to urinate. Commonly occur due to UTI.

What is hesitancy?

Hesitancy is trouble starting or maintaining a urine stream. Commonly occur due to enlarged prostate.

What is glomerulonephritis?

Inflammation of the glomerulus (detect on histology) describe as a glomerulonephritis.

What is glomerulopathy?

If inflammation is absent then it's called glomerulopathy.

Types of glomerular disease

1. Nephrotic syndrome: Podocyte malfunction or injury is often causative.
2. Glomerulonephritis (nephritic syndrome): Endothelial and mesangial cells primarily involved.
3. Rapidly progressive glomerulonephritis: acute nephritis, focal necrosis with or without crescents and rapidly progressive renal failure over weeks.
4. Mixed nephritic/nephrotic presentations: Usually result from systemic disease e.g. lupus nephritis, cryoglobulinaemia and Henoch-Schonlein purpura).

Acute nephritic syndrome (AGN)

Acute nephritic syndrome is a group of symptoms that occur with some disorders that cause swelling and inflammation of the glomeruli in the kidney, or glomerulonephritis.

Acute nephritic syndrome is often caused by an immune response triggered by an infection or other disease.

1. Post-steptococcal glumerulonephritis
2. IgA nephropathy
3. Henoch-Schonlein purpura
4. Hemolytic uremic syndrome.

Common causes of AGN in adults include

- Lupus nephritis (SLE)
- Vasculitis
- Hepatitis B, C
- Viral diseases such as infectious mononucleosis, measles, mumps
- Endocarditis
- Membranoproliferative glomerulonephritis
- Rapidly progressive (crescentic) glomerulonephritis
- Goodpasture syndrome

Scanned with CamScanner

Components of AGN

1. Haematuria (red or brown urine)
2. Oedema and generalized fluid retention
3. Hypertension
4. Oliguria
5. Reduced renal function

Nephrotic syndrome

Components of nephrotic syndrome

1. Hypoalbuminaemia -this can be partly explained by increased catabolism of reabsorbed protein, largely albumin, in the proximal tubules, even though the rate of albumin synthesis is increased.
2. Massive proteinuria (more than 3.5 g/day)- due to structural damage to the glomerular barrier (podocytes, basement membrane, fenestrated endothelium and endothelial charge) allows the passage of more and larger molecules.
3. Dyslipidaemia- this is a consequence of increased synthesis of lipoproteins as a direct consequence of a low plasma albumin.
4. Salt and water retention, leading to oedema.
5. Hypercoagulable states- the hypercoagulable state is due to loss of clotting factors (e.g. antithrombin) in the urine and an increase in hepatic production of fibrinogen.

Causes of nephrotic syndrome

Primary glomerular disease

1. Minimal-change nephropathy
2. Congenital nephrotic syndrome
3. Focal segmental glomerular sclerosis
4. Membranous nephropathy

Secondary glomerular disease

1. Amyloidosis
2. Diabetic nephropathy

How to differentiate AGN and NS?

AGN	NS
Usually affect the children	Affect any age
History of sore throat, skin lesion may be present	History of DM, connective tissue disease e.g. SLE may be present
Edema -less prominent	Edema -more prominent
History of haematuria (passes of high colour urine) -common	History of haematuria (passes of high colour urine) - absent
History of frothy urine -absent	History of frothy urine -present
Blood pressure - elevated	Blood pressure - usually normal
Urine R/M/E - haematuria, dysmorphic RBC present	Urine R/M/E - haematuria usually absent.
24 hours total urinary protein <3.5 gram/24 hours	24 hours total urinary protein >3.5 gram/24 hours

Scanned with CamScanner