Available online at www.sciencedirect.com

ScienceDirect

Procedia Computer Science 260 (2025) 32–39

Procedia Computer Science

www.elsevier.com/locate/procedia

7th International Conference on Recent Trends in Image Processing and Pattern Recognition (RTIP2R-2024)

Brain Tissue Segmentation from MRI Scans using Digital Image Processing

Sushmita Chauhan[a], Poonam Saini[a,*], Sanjeev Sofat[a]

[a] *Department of Computer Science and Engineering, Punjab Engineering College (Deemed to be university), Sector 12 Chandigarh, 160012.*

Abstract

The brain is one of the most unexplored parts of the human body and its complex and delicate structure has scientists worldwide looking for answers about its intricacies. Also, since the advent of deep learning techniques as well as imaging techniques like computed tomography (CT), magnetic resonance imaging (MRI), and positron emission tomography (PET), analysis of the brain has become the most intriguing and researched area in healthcare, as well as deep learning sectors of artificial intelligence. The extraction of the brain from the skull forms the basis and source of study for the prediction of age-related diseases like Alzheimer's disease. Nowadays With the increase in life expectancy and the extravagant use of technology, it is evident that neurological diseases are on the rise. Therefore, it becomes essential that such diseases can be diagnosed at an early stage of their occurrence. The proposed work presents brain extraction from the skull with the help of three basic steps, *data acquisition, pre-processing, and largest connected component extraction using contours*. The data acquired is using the ADNI data repository. The preprocessing step involves contrast enhancement using CLAHE, binarization of the scan using Otsu thresholding, and de-blurring so that the noise that might be there in the scans can be removed and a clear image of the brain is available for further processing and classification of Alzheimer's disease.

© 2025 The Authors. Published by Elsevier B.V.
This is an open access article under the CC BY-NC-ND license (https://creativecommons.org/licenses/by-nc-nd/4.0)
Peer-review under responsibility of the scientific committee of the Seventh International Conference on Recent Trends in Image Processing and Pattern Recognition.

Keywords: Alzheimer's Disease; Digital Image Processing; Magnetic Resonance Imaging; Brain Extraction.

1. Introduction

In this age of progress and innovation, the potential technological advancements, especially in the field of healthcare, have resulted in an increased life expectancy. However, the rate of age-related diseases has also accelerated with time. Alzheimer's disease is one such brain disorder that affects the elderly population. It is a progressive neurodegenerative disease that slowly destroys memory, the capability to think and reason out, and eventually to carry out

* Corresponding author. Tel.: +0-000-000-0000 ; fax: +0-000-000-0000.
E-mail address: poonamsaini@pec.edu.in

1877-0509 © 2025 The Authors. Published by Elsevier B.V.
This is an open access article under the CC BY-NC-ND license (https://creativecommons.org/licenses/by-nc-nd/4.0)
Peer-review under responsibility of the scientific committee of the Seventh International Conference on Recent Trends in Image Processing and Pattern Recognition.
10.1016/j.procs.2025.03.174

routine activities [1]. Currently, the occurrence of Alzheimer's disease is increasing at an alarming rate as is quite evident from the statistics published by the Alzheimer's and Related Disorders Society of India (ARDSI) [2]leading to the untimely demise of patients suffering from AD[3]. Nerve cell damage is the root cause of Alzheimer's Disease which ultimately impairs the communication, memory, and thinking process of the patient[4]. It is one of the deadliest and most expensive diseases of the twenty-first century, and the World Health Organization recognizes it as a global health priority. It commences with unnoticeable changes in the brain, over the years which convert into symptoms like memory loss as well as language problems. The name Alzheimer's disease has been adapted from the name of the doctor, Dr. Alois Alzheimer who was the first to examine his patient's brain who had died of a strange mental illness that had caused loss of memory and communication problems along with unpredictable behavior in her , in the year 1906 and had eventually caused her death[5]. He had examined her brain and reported abnormal clumps and tangled bundles of fibers in it, which are presently called amyloid plaques and neurofibrillary or tau tangles, respectively [6].

The onset of the first symptoms of this disease is at an early stage of 30 to 65 years of age. Mild Cognitive Impairment (MCI) is the predementia stage that is considered to affect 10%-15% of individuals who will eventually progress to Alzheimer's Disease every year [7]. It is not necessary that every MCI patient will progress to severe AD. Pathologically MCI is optimally the stage at which clinical treatments and intervention of a doctor can prevent and delay the decline to severe dementia.

Biomarkers are measurable indicators that overall indicate what is happening within the body. They are helpful in tracking healthy processes, diagnosing diseases, monitoring responses of medication and identifying health risks in a person [8]. Alzheimer's disease (AD) is developed due to the deposition of amyloid plaques extracellularly, and tau proteins intracellularly as neurofibrillary tangles which lead to malfunctioning of neuron connectivity ultimately resulting in loss of brain functions [9].

There are different types of biomarkers and tests that have evolved over the years: Brain imaging serves as biomarkers consisting of scans like MRI, CT, and PET, these serve as evidence for the diagnosis of AD and other brain disorders like Tumor detection, Epilepsy or Parkinson's disease [10] and the datasets for the study of the affect AD on the brain structure have been made available for studies by open source repositories ADNI [11] Cerebrospinal fluid (CSF) is a transparent fluid that surrounds the brain and spinal cord, providing protection, insulation, and cushioning. Beta-amyloid 42 and phosphotau present in amyloid plaques and tau tangles respectively act as biomarkers existing in CSF of the brain and are used for identifying Alzheimer's disease[12]. Blood tests involve proteins from the brain, and CSF eventually ends up in the bloodstream, in which they are then diluted. These proteins are detected in the blood, but very few of these blood biomarkers have demonstrated sufficient predictive value to be used in clinical practice for the detection and classification of AD [13]. Genes transmit genetic information from one generation to another and are also considered as biomarkers for the detection of AD at an early stage or in a person having a strong family history of Alzheimer's or frontotemporal dementia [14].

Brain imaging is a major tool to identify whether AD has caused brain damage in an individual[15].In order to diagnose and treat neurological disorders like Parkinson's disease, Alzheimer's disease, Schizophrenia, Epilepsy etc different modes of imaging technologies are in use viz magnetic resonance imaging (MRI), positron emission tomography (PET), Diffusion tensor imaging (DTI) and computerized tomography (CT) scans[16].

Atrophy or shrinkage of the brain's hippocampus area is one of the most important biomarkers. Structurally, MRI forms the basis of computer-aided diagnosis (CAD) for early detection of AD as well as MCI. sMRI-based CAD methods are one of the basic and the most commonly used tests in neuroscience and neurosurgery. It provides a detailed image of the brain in three dimensions i.e., axial (from top to down), sagittal (from side to side), and coronal (from front to back) as shown in Fig. 1.

The Dataset used for this study has been taken from Alzheimer's Disease Neuroimaging Initiative (ADNI)[17] which is an open-source repository maintained by USC.In order to track and detect the early stage of AD, the ADNI is a longitudinal cohort of clinical, imaging, genetic and biochemical biomarkers. This article has been organized in the following manner and Section 2, presents a brief review of the literature. Section 3, describes the proposed methodology used for the extraction of the brain area from the skull and other non-required parts of the scan. Also, metrics used to evaluate the proposed methodology have been discussed in detail. Section 4 involves the experimentation used for extracting the brain from the skull and finally, section 5 involves the Conclusion of our work.

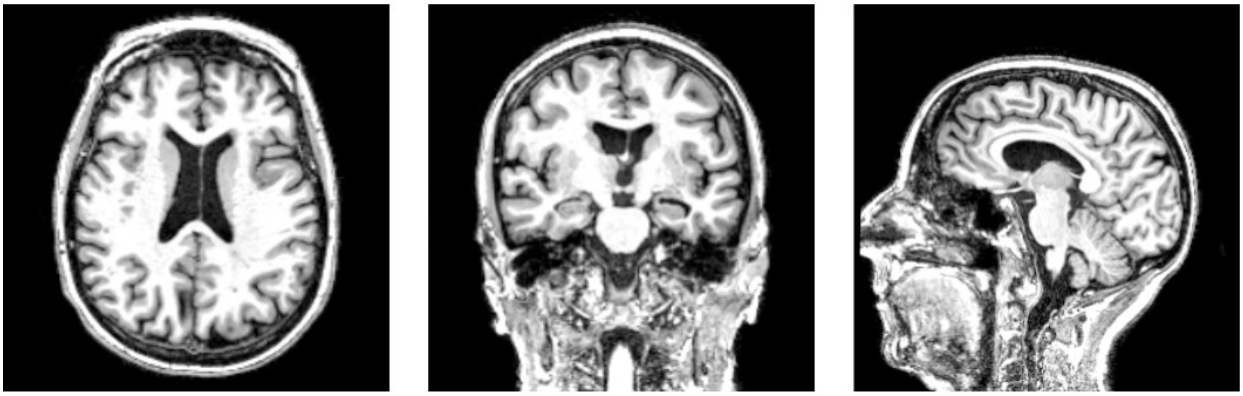

Fig. 1. Axial, Coronal and Sagittal dimensions of the brain

2. Motivation

The presented work is based on Alzheimer's Disease which is an incurable neurodegenerative disease that affects the elderly population and is increasing at an alarming rate due to the current lifestyle which is full of stress, anxiety, and other environmental factors. Hence, it becomes highly necessary that it is diagnosed at an early stage so that deterioration can be slowed down and complications can be avoided. Computer-aided diagnosis of the disease using imaging modalities like MRI and PET as well as deep learning techniques are more reliable as there is negligible scope of human error. The biggest hindrance in identifying AD is its overlap of symptoms with many other conditions like stress, anxiety, depression, and the natural aging process, and the doctors also have limited knowledge of the disease. However, deep learning techniques can address these issues that a conventional diagnosis system nearly misses. The presented study encompasses the pre-processing of sMRI scans which involves acquiring data, converting it into structured format, applying pre-processing steps, and preparing the data for further suitable classification process.

3. REVIEW OF RELATED WORK

In their attempt to address the issue of extracting the brain from the cranium in multiple T1-Weighted MRI imaging slices Duarte et al.[18] have used Digital image Processing techniques to strip the skull from the brain MRI scan as it is not affected from Alzheimer's Disease and is not required for this particular study. In their attempt to extract the brain from the skull, the authors have proposed an approach in which T1 weighted approach plays a key role which states that the dark intensity area refers to the skull and the bright intensity refers to the fat part of the brain which is affected by Alzheimer's disease. It is noteworthy to state that only the Axial plane also known as the horizontal plane has been incorporated in their study. The quantitative metrics used to evaluate their results included Specificity and Precision which was about 90 percent, F-Measure as well as Accuracy surpassed 80 % and Recall achieved in their experiments was better than 70%.

Convolutional Neural Networks are the most widespread deep learning techniques that have been applied on various fields like computer vision, speech recognition, facial recognition, etc. It consists of various convolutional layers also called kernels. The input is a n-dimensional matrix which convolves with filters to create a feature map as its output, comprising of the essential features to be fed to the next layers. The final output from the successive layers is a vector of class scores, which is used to classify the disease [19] .

An H-FCN framework has been explored by Lian et al.[20] which is a hierarchical-fully CNN for AD diagnosis using structural MRI obtained from two large cohorts of independent datasets namely ADNI-1 and ADNI-2. The discussed framework automatically identifies and discriminates between local patches and global brain patches which are fused together for study and feature representation in a data-driven manner. The H-FCN method creates sub-networks to perform joint atrophy localization and AD classification at every level be it patch, region, or subject level. The proposed method was evaluated in terms of AD classification and MCI conversion prediction. AD classification between AD vs NC reached an accuracy of 0.90 along with sensitivity and specificity of 0.82, and 0.97 respectively,

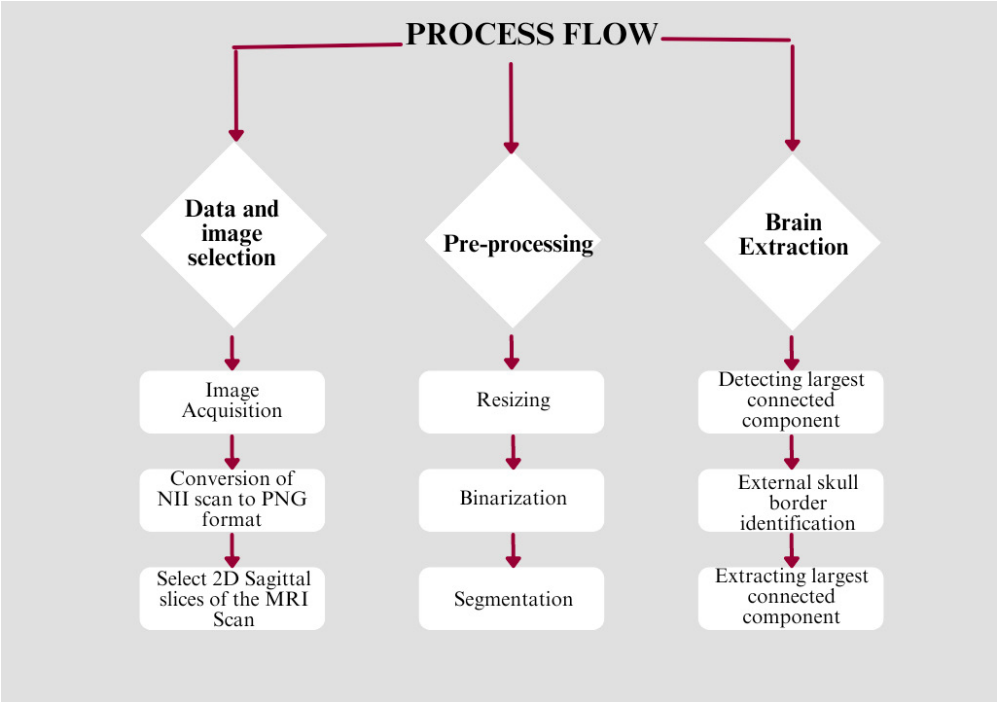

Fig. 2. Workflow

and AUC of 0.95, while MCI conversion between pMCI vs sMCI the model reached an accuracy of 0.81, sensitivity of 0.53, specificity of 0.85 and AUC of 0.78 was evaluated.

Fan et al. [21] have performed a Unet-based analysis of MRI data for AD diagnosis. The method so implemented by the authors is a combination of encoding and decoding along with skip connections. The skip connections combine the high-level semantics and the low-level fine-grained surface representation, which results in more information utilization from the images for further classification. The region of interest for the model is explored by the 3D Grad CAM method which is implemented after preprocessing steps like clipping and sampling of images, normalization of intensity, and finally brain extraction. The proposed Unet model is applied to 181 subjects of the ADNI dataset with an accuracy of 86.74%.

4. PROPOSED APPROACH

In this section the approach followed for the extraction of the brain from the skull in MRI scans has been discussed. The basis of this approach is the fact that brain MRI scans have different intensities of gray areas which differs from region to region. Also, there is variation in the T1 intensity in accordance with the water-filled areas of the brain which makes it difficult for using conventional thresholding techniques. The largest connected component which is considered in this work is the brain and the intensity differences between the skull (dark area) and bright intensity fat areas become the basis of this work. After identifying this idea, we proposed the step-by-step illustration of this work with the help of a flow diagram in (Fig 2.).

4.1. Image Acquisition

1)Acquiring dataset for analysis: MRI scans are obtained using ADNI which provides MRI scans in the nifty or nii format. These files initially are converted into 2D slices of 682 images each. These images are then selected

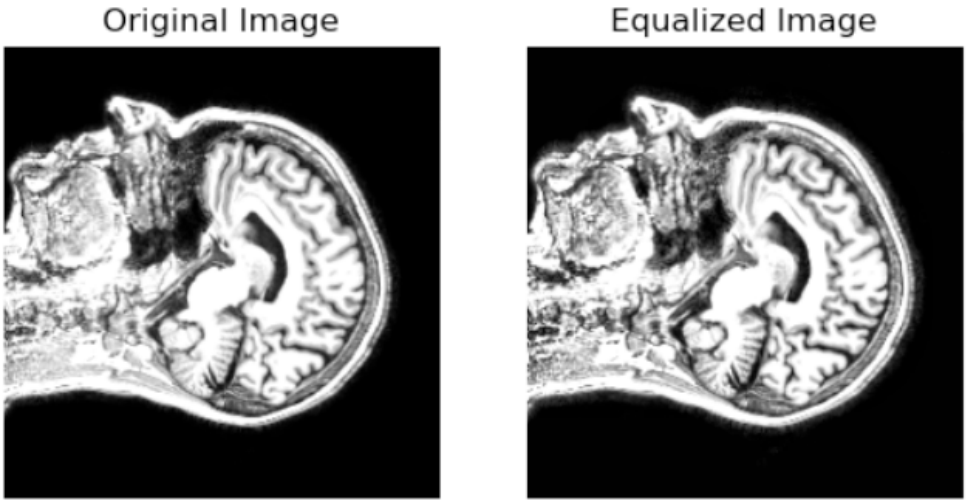

Fig. 3. CLAHE Equalized scan

randomly for further pre-processing and finally for brain extraction from the skull. The size of each of these images in 3 Dimensions is 256x256x170 pixels. A batch file is used to read and convert all of the MRI scans into 2D images.

4.2. Preprocessing

1) Selecting 2D slices for analysis : In this section, we discuss the random selection of 2D images in the three different planes for analysis i.e. Axial, Coronal and-Sagittal. The dataset is sliced into 3 Dimensions as mentioned above. Axial and Coronal images are 256 in number each and Sagittal are 170 in number.Our study focuses on the Sagittal and coronal dimensions of the scan. The sagittal dimension provides the side view of the brain as shown in Fig 1 and the coronal section provides a detailed cross-sectional view which is indicative of the hippocampus and the entorhinal cortex which are the parts of the brain that are mainly affected by Alzheimer's disease.

2) Contrast limited adaptive histogram equalization : This particular method deals with the dispersion of intensity values in order to produce an improved image in terms of contrast. This particular method is different from Histogram Equalization in terms of a number of histograms each belonging to a segment of a different segment of the image and utilizes them for redistribution of the lightness value of the image.CLAHE functions in a way that divides the entire image into tiles. Blending of the boundaries of these tiles is done using bilinear interpolation which removes the false boundaries and improves the overall contrast of the image. The apparent difference between a normal scan and a CLAHE equalized can be seen in Fig 3.

3) Blur and Noise Removal Firstly blurring mostly occurs in a grayscale image due to movement of the patient during the scan, imperfect hardware also due to the limitations of the scanning technique itself. Therefore, it becomes necessary to deblur and remove noise from the scans. Blurring is mostly seen in the image where the sharp edges and fine details get smeared, which make the identification of different regions of the brain, difficult. Intentional blurring is done by adjusting the kernel size of the Gaussian Filter.

4)Binarization: The original brain scans are subjected to a two-step process, the first being grayscale conversion and the second is Otsu thresholding which is a global binarization method in which the grayscale image is assumed to consist of only two types of pixels one foreground and the other background pixels. It is a variance-based binarization technique where the pixels are divided into two clusters which minimises the intra-cluster variation by increasing the inter-cluster variance. The representation of weighted variance within the class is represented in equation (1)

$$\sigma_w^2(t) = w_1(t)\sigma_1^2(t) + w_2\sigma_2^2(t) + ... \quad (1)$$

where w(t) is the probability of intensity classes divided by the threshold t within the range 0-255 and the weights can be calculated as mentioned in equation (2)

$$w_1(t) = \sum_{i=1}^{t} P(i) \tag{2}$$

$$w_2(t) = \sum_{i=t+1}^{I} P(i) \tag{3}$$

For deriving equation (1) the means of the two intensity classes are calculated according to the following equation (3) and variances of the two intensity classes are calculated by using the formula given in equation(4)

$$\mu_1(t) = \sum_{i=1}^{t} iP(i) \div w_1(t) \tag{4}$$

$$\mu_2(t) = \sum_{i=t+1}^{I} iP(i) \div w_2(t) \tag{5}$$

$$\sigma_{\mathbf{1}}^{\mathbf{2}}(\mathbf{t}) = \sum_{i=1}^{t} \left[i - \mu_1(t)\right]^2 P(i)/w_1(t) \tag{6}$$

$$and\ \sigma_{\mathbf{2}}^{\mathbf{2}}(\mathbf{t}) = \sum_{i=t+1}^{I} \left[i - \mu_2(t)\right]^2 P(i)/w_2(t) \tag{7}$$

The in-class variance is calculated by substituting the values of μ and σ in equation (1)

4.3. Brain Extraction

The brain is the fundamental seat of learning, thinking, and doing day-to-day jobs; therefore, it becomes vital that it is studied precisely without taking into consideration the outer cranial structure, which otherwise is present in all MRI scans. In the present study, the skull is separated from the brain structure which is necessary to further segment the brain tissues and identify the region of interest. Also, skull stripping plays an important role in detecting pathology and multi-modality brain image registration.

5. Discussion and Comparative Analysis

The previous section demonstrates the preprocessing of MRI scans so as to extract the Region of interest which in this case is the brain tissue. The preprocessing of sMRI is beneficial for further classification of the scans into three main classes. The Region of Interest is well-marked after the segmentation of the brain scan is done. The brain mask along with the segmented brain structure is shown in Fig 4. The segmentation method used in this study mainly depends on the Largest Connected component which is one of the most fundamental operations in Computer vision. Computationally this method is light as it does not require much resources as compared to 3D data. Also, it helps in boundary detection, shape analysis, Region isolation, and most important segmentation.A tabulated study on the comparative analysis of various methods used for Brain Extraction has been shown in Table 1.

Comparative Analysis according to Sensitivity and Specificity:

Method	Sensitivity	Specificity
3D Skull Strip[22]	90.6%	96.2%
BB [23]	80.6%	98.8%
GCUT [24]	95.2%	94.0%
FreeSurfer [25]	94.8%	94.0%
Contouring Method [26]	91.2%	96.9%

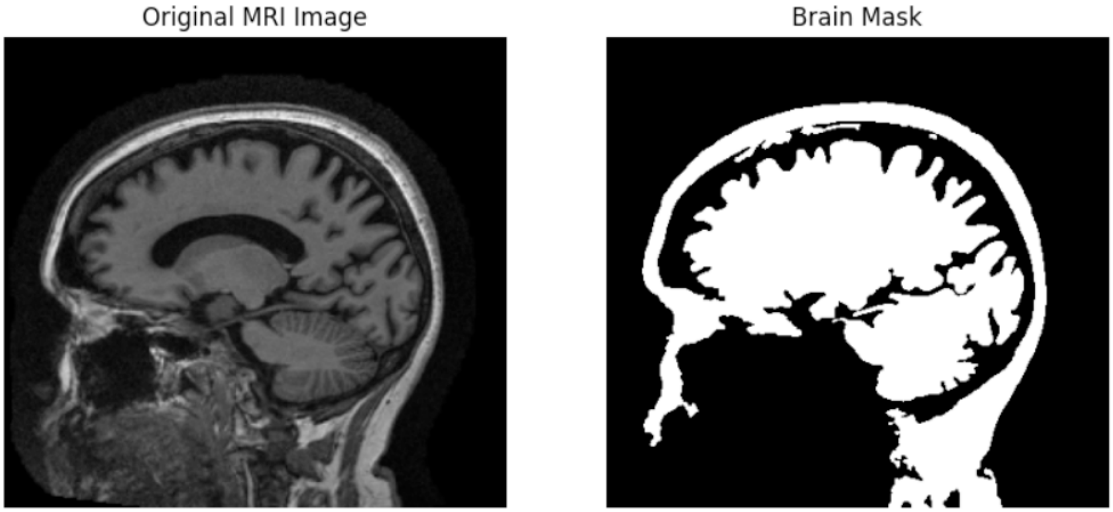

Fig. 4. Brain mask generation

6. Conclusion

With the alarming rate at which memory-related problems along with Alzheimer's Disease have increased over the years, it becomes all the more necessary to study and analyze the human brain and its complexities. The presented work becomes one of the most basic yet important steps for brain extraction from the skull. Additionally, efficient digital image processing techniques have been discussed so that any distortion that might have occurred during scanning can be removed. Further, image preprocessing helps in better and more effective analysis of scans so that the points or regions of interest can be projected and studied easily as well as extensively. The mask generated after segmentation of the brain MRI scan clearly is indicative of the volume of the brain which can be further studied for classifying whether the scan belongs to a patient suffering from AD or not.

References

[1] J. Ouyang, Q. Zhao, E. Adeli, G. Zaharchuk, and K. M. Pohl, "Disentangling Normal Aging From Severity of Disease via Weak Supervision on Longitudinal MRI," IEEE Trans. Med. Imaging, vol. 41, no. 10, pp. 2558–2569, 2022, doi: 10.1109/TMI.2022.3166131.
[2] "ARDSI." https://ardsi.org/
[3] "2023 Alzheimer's disease facts and figures," Alzheimer's Dement., vol. 19, no. 4, pp. 1598–1695, 2023, doi: 10.1002/alz.13016.
[4] W. Is, A. S. Disease, W. H. O. Gets, and A. S. Disease, "Alzheimer ' s Disease WHAT IS ALZHEIMER ' S DISEASE? WHO GETS ALZHEIMER ' S DISEASE?," no. March, pp. 1–22, 2002.
[5] R. A. Stelzmann, H. Norman Schnitzlein, and F. Reed Murtagh, "An english translation of alzheimer's 1907 paper, 'über eine eigenartige erkankung der hirnrinde,'" Clin. Anat., vol. 8, no. 6, pp. 429–431, 1995, doi: 10.1002/ca.980080612.
[6] U. States and A. Alzheimer, "Alzheimer ' s Disease Fact Sheet disease clinical trials Alzheimer ' s disease or Participants in Alzheimer ' s clinical research help brain changes in healthy," pp. 1–13, 2023.
[7] M. Torres-Velazquez, W. J. Chen, X. Li, and A. B. McMillan, "Application and Construction of Deep Learning Networks in Medical Imaging," IEEE Trans. Radiat. Plasma Med. Sci., vol. 5, no. 2, pp. 137–159, 2021, doi: 10.1109/TRPMS.2020.3030611.
[8] J. Kleesiek et al., "Deep MRI brain extraction: A 3D convolutional neural network for skull stripping," Neuroimage, vol. 129, pp. 460–469, 2016, doi: 10.1016/j.neuroimage.2016.01.024.
[9] M. Huang, X. Chen, Y. Yu, H. Lai, and Q. Feng, "Imaging Genetics Study Based on a Temporal Group Sparse Regression and Additive Model for Biomarker Detection of Alzheimer's Disease," IEEE Trans. Med. Imaging, vol. 40, no. 5, pp. 1461–1473, 2021, doi: 10.1109/TMI.2021.3057660.
[10] L. Brand, K. Nichols, H. Wang, L. Shen, and H. Huang, "Joint Multi-Modal Longitudinal Regression and Classification for Alzheimer's Disease Prediction," IEEE Trans. Med. Imaging, vol. 39, no. 6, pp. 1845–1855, 2020, doi: 10.1109/TMI.2019.2958943.
[11] National Institute on Aging, How Biomarkers Help Diagnose Dementia, National. Institute.of Aging, pp. 1–7, 2022.
[12] ADNI" https://adni.loni.usc.edu/

[13] C. Delaby, C. Hirtz, and S. Lehmann, "Overview of the blood biomarkers in Alzheimer's disease: Promises and challenges," Rev. Neurol. (Paris)., vol. 179, no. 3, pp. 161–172, 2023, doi: 10.1016/j.neurol.2022.09.003.

[14] W. Ko, W. Jung, E. Jeon, and H. Il Suk, "A Deep Generative-Discriminative Learning for Multimodal Representation in Imaging Genetics," IEEE Trans. Med. Imaging, vol. 41, no. 9, pp. 2348–2359, 2022, doi: 10.1109/TMI.2022.3162870.

[15] A. P. Porsteinsson, R. S. Isaacson, S. Knox, M. N. Sabbagh, and I. Rubino, "Diagnosis of Early Alzheimer's Disease: Clinical Practice in 2021," J. Prev. Alzheimer's Dis., vol. 8, no. 3, pp. 371–386, 2021, doi: 10.14283/jpad.2021.23.

[16] Z. Xia, T. Zhou, S. Mamoon, and J. Lu, "Recognition of Dementia Biomarkers with Deep Finer-DBN," IEEE Trans. Neural Syst. Rehabil. Eng., vol. 29, pp. 1926–1935, 2021, doi: 10.1109/TNSRE.2021.3111989.

[17] "Initiative, Alzheimer's Disease Neuroimaging." [Online]. Available: https://adni.loni.usc.edu/

[18] Duarte, K. T. N., Moura, M. A. N., Martins, P. S., and de arvalho, M. A. G. (2022). Brain Extraction in Multiple T1-weighted Magnetic Resonance Imaging slices using Digital Image Processing techniques. IEEE Latin America Transactions, 20(5), 831-838.

[19] L. Alzubaidi et al., Review of deep learning: concepts, CNN architectures, challenges, applications, future directions, vol. 8, no. 1. Springer International Publishing, 2021. doi: 10.1186/s40537-021-00444-8.

[20] C. Lian, M. Liu, J. Zhang, and D. Shen, "Hierarchical fully convolutional network for joint atrophy localization and Alzheimer's disease diagnosis using structural MRI," IEEE Trans. Pattern Anal. Mach. Intell., vol. 42, no. 4, pp. 880–893, 2020, doi: 10.1109/TPAMI.2018.2889096.

[21] Z. Fan et al., "U-net based analysis of MRI for Alzheimer's disease diagnosis," Neural Comput. Appl., vol. 33, no. 20, pp. 13587–13599, 2021, doi: 10.1007/s00521-021-05983-y.

[22] "Analysis of functional neuroimages." http://afni.nimh.nih.gov.

[23] A. Mikheev, G. Nevsky, S. Govindan, R. Grossman, and H. Rusinek, "Fully automatic segmentation of the brain from t1-weighted MRI using bridge burner algorithm," Journal of Magnetic Resonance Imaging, vol. 27, pp. 1235–1241, May 2008.

[24] S. A. Sadananthan, W. Zheng, M. W. Chee, and V. Zagorodnov, "Skull stripping using graph cuts," NeuroImage, vol. 49, pp. 225–239, Jan. 2010.

[25] F. Ségonne, A. Dale, E. Busa, M. Glessner, D. Salat, H. Hahn, and B. Fischl, "A hybrid approach to the skull stripping problem in mri," NeuroImage, vol. 22, no. 3, pp. 1060– 1075, 2004.

[26] K. Tartarotti Nepomuceno Duarte, M. Andrade Nascimento Moura, P. Sergio Martins and M. A. Garcia de Carvalho, "Brain Extraction in Multiple T1-weighted Magnetic Resonance Imaging slices using Digital Image Processing techniques," in IEEE Latin America Transactions, vol. 20, no. 5, pp. 831-838, May 2022, doi: 10.1109/TLA.2022.9693568. keywords: Brain;Magnetic resonance imaging;Histograms;Software algorithms;Data mining;Image edge detection;Diseases;Image Processing;Skull Stripping;Brain Extraction;Image Segmentation;Medical Imaging,