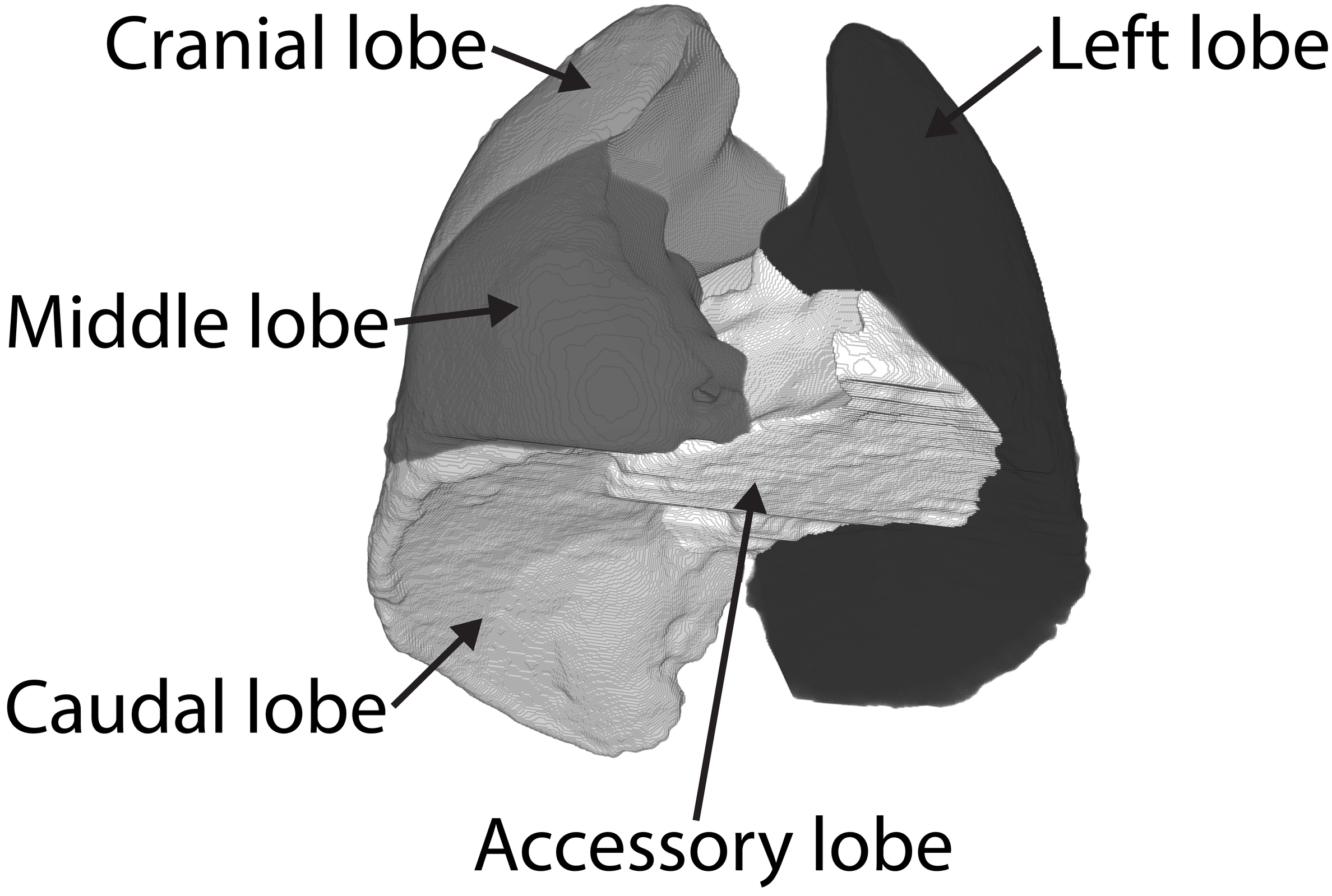
Cranial lobe
Left lobe
Middle lobe
Caudal lobe
Accessory lobe