OPEN

PRS GLOBAL OPEN

ORIGINAL ARTICLE

Cosmetic

Impact of Dorsal Preservation Rhinoplasty on the Internal Nasal Valve

Reyof Saeed Alharthi, MBBS, SB-ORL, HNS*
Mubarak Abdullah Alshahrani, MBBS, SB-ORL, HNS†
Rahaf Hatim Rajab, MBBS‡
Ahmed Mohammed Mogharbel, MBBS‡
Mohammed Abdullah Bahabri, MBBS§
Mohammed Hatim Rajab, MBBS§
Ahmed Zuhair Aytah, MBBS§
Mohammed Zuhair Aytah, MBBS§

Background: The internal nasal valve (INV) is the airway's narrowest segment and main regulator of nasal resistance. Dorsal preservation rhinoplasty (DPR)—push-down (PD), let-down (LD), and spare roof (SR)—preserves dorsal structures, but its effect on INV angle is unclear. This study systematically evaluated INV angle changes after DPR.

Methods: We searched PubMed and Google Scholar (through April 2025) for studies reporting pre- and postoperative INV angles in DPR. Data were synthesized in RevMan 5.4 following PRISMA guidelines. The primary outcome was a change in the INV angle.

Results: Nine studies met inclusion criteria; 4 clinical studies (N = 118) were pooled. Meta-analysis showed a significant postoperative INV angle increase (standardized mean difference [SMD] = 0.52; 95% confidence interval [CI]: 0.02–1.02; P = 0.04; I^2 = 63%). Removing 1 outlier reduced heterogeneity to 0% and preserved significance (SMD = 0.43; 95% CI: 0.16–0.69; P = 0.002). Cadaveric analysis (N = 46) demonstrated the greatest INV widening with SR (SMD = 1.42; P = 0.02); PD showed a nonsignificant decrease (SMD = −1.65; P = 0.15), and LD showed a positive, nonsignificant trend (SMD = 0.86). Technique-based subgroup differences were significant (P = 0.02).

Conclusions: SR and LD techniques provide modest but meaningful INV angle improvement, supporting DPR as a functional alternative to traditional dorsal hump reduction. PD appears less reliable for valve patency. Larger, long-term studies with standardized functional measures are needed to refine technique selection.
(Plast Reconstr Surg Glob Open 2026;14:e7577; doi: 10.1097/GOX.0000000000007577; Published online 27 March 2026.)

INTRODUCTION

The internal nasal valve (INV), described by Mink in the 1920s, is the airway's narrowest segment and a critical airflow regulator.[1] Located 1.3–1.5 cm posterior to the nostrils, it is bounded by the inferior turbinate, septum, upper lateral cartilage, and nasal floor. In White people, the INV angle measures 10–15 degrees, with variations across ethnic groups.[1–3]

Preservation rhinoplasty (PR) traces back to 1914 with Lothrop's "surface preservation techniques."[4] Later, Cottle formalized the push-down (PD) operation, earning recognition as the father of PR.[5] Despite refinements in the 1950s, PR fell out of favor by the 1960s due to technical imprecision and unpredictability, shifting practice toward structured rhinoplasty (SR).[6]

Recently, dorsal preservation rhinoplasty (DPR) has re-emerged due to advances in anatomy and instrumentation. DPR preserves the osseocartilaginous dorsum and INV function, minimizes grafting, and yields natural aesthetics.[7,8] Ferreira and Toriumi classified DPR into foundation techniques (FTs/type I) and surface techniques (STs/type II).[6] FTs (PD, LD) rely on dorsal impaction via osteotomies to reposition the nasal pyramid. STs focus on dorsal modulation, reshaping the middle vault without impaction while preserving cartilaginous integrity. FTs vary by the septal strip resection level and may include adjunctive maneuvers (Fig. 1).

*From the *Department of Otolaryngology – Head and Neck Surgery, King Faisal Specialist Hospital and Research Centre, Jeddah, Saudi Arabia; †Department of Otolaryngology – Head and Neck Surgery, King Abdulaziz Medical City NGH, Jeddah, Saudi Arabia; ‡Department of Otolaryngology – Head and Neck Surgery, King Fahad Armed Forces Hospital, Jeddah, Saudi Arabia; and §Department of Otolaryngology – Head and Neck Surgery, King Abdulaziz University, Jeddah, Saudi Arabia.*

Received for publication August 27, 2025; accepted February 3, 2026.

Copyright © 2026 The Authors. Published by Wolters Kluwer Health, Inc. on behalf of The American Society of Plastic Surgeons. This is an open-access article distributed under the terms of the Creative Commons Attribution-Non Commercial-No Derivatives License 4.0 (CCBY-NC-ND), where it is permissible to download and share the work provided it is properly cited. The work cannot be changed in any way or used commercially without permission from the journal.

DOI: 10.1097/GOX.0000000000007577

Disclosure statements are at the end of this article, following the correspondence information.

HOW DPR IMPACTS INV

DPR techniques affect the INV differently. In FTs, the dorsum shifts downward; cadaveric computed tomography analyses show that LD enlarges the INV, whereas PD may reduce it due to impaction within the pyriform aperture.[9,10] Conversely, STs maintain the cartilaginous middle vault, preserving INV stability and reducing postoperative collapse risk compared with reductive rhinoplasty[11] (Table 1).

Cone-beam computed tomography (CBCT) findings confirm postoperative INV widening and improved functional outcomes with preservation techniques.[12] However, objective data on parameters like minimum cross-sectional area (MCA), nasal resistance, and volume remain inconsistent. The main goal of this systematic review and meta-analysis was to determine DPR's influence on the INV angle via CT and cone-beam CT and, secondarily, to examine nasal resistance and volume.

Takeaways

Question: Does dorsal preservation rhinoplasty (DPR) affect the internal nasal valve angle and nasal function?

Findings: A review of nine studies found that DPR increases the INV angle. Let-down and spare roof techniques showed improvement, whereas push-down produced negative outcomes. Limited airflow data suggested increased nasal volume without resistance change.

Meaning: DPR's functional impact is technique dependent, making careful patient selection and individualized planning essential for preserving valve function. Further research is needed to clarify long-term effects and guide optimal surgical decision-making to ensure consistent functional and aesthetic outcomes in clinical practice.

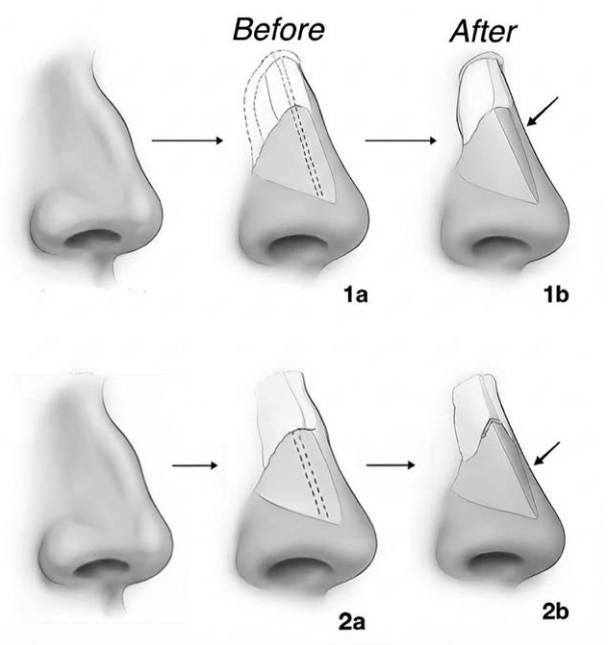

Fig. 1. Foundation and surface techniques. 1a, 1b, Foundation techniques (type 1) involve osteotomies and impaction (PD/LD) of the nasal pyramid into the face. 2a, 2b, Surface techniques (type II) involve treating the hump superficially without impaction. Dashed lines indicate the removed part. Adopted from 2021, Drs Ferreira and Toriumi.

METHODS AND MATERIALS

Literature Review

This review followed Cochrane methodology and PRISMA guidelines.[13,14] Registered with PROSPERO (CRD420251035398), the study adhered to institutional protocols and Declaration of Helsinki standards. In April 2025, PubMed/MEDLINE and Google Scholar were searched for the terms *preservation rhinoplasty, LD technique, PD technique, internal nasal valve,* and *INV angle,* without date restrictions.

Study Selection

Two investigators independently reviewed titles and abstracts, with full-text review for eligibility. A third reviewer resolved discrepancies. Inclusion criteria were English-language publications (randomized controlled trials [RCTs], cohort, case series, cadaveric) on adult PR patients reporting relevant outcomes. Reviews, editorials, and animal studies were excluded.

Screening and Data Extraction

Using Rayyan, 2 investigators extracted data including demographics, study design, technique type, and pre- and postoperative INV measurements.[15]

Table 1. Theoretical Effects of Different DPR Techniques on the INV

Category	Technique	Key Maneuver	Effect on INV
	PD	En bloc descent of nasal pyramid into face	May widen INV if moderate; excessive impaction risks narrowing
FTs	LD	Descent with lateral wedge osteotomies at piriform margin	Usually widens INV due to lateral release
	High-strip	Dorsum lowered via high/medium/low septal strip resection	INV generally preserved or widened depending on strip height
	SR (classic)	Preserves bony/cartilaginous roof after dorsal reduction	Maintains INV geometry; prevents open roof deformity
STs	SR (modified)	Partial preservation of bony cap with reshaping	INV stable; adapts to dorsal contour
	SR (hybrid)	Combines SRT with spreader flaps/graft for stability	Enhances INV support and functional outcome

Bias Assessment

Risk of bias was assessed using validated tools: Cochrane risk of bias 2 (RoB 2),[16] methodological index for non-randomized studies (MINORS),[17] and quality appraisal for cadaveric studies (QUACS).[18] Two assessors evaluated bias, with a third ensuring consensus.

Statistical Analysis

A random-effects meta-analysis was utilized. The primary outcome was postoperative INV angle. Pooled mean differences and 95% confidence intervals (CIs) were computed. Heterogeneity was evaluated using the Q statistic and I^2 index (>50% indicating significance). A forest plot was created using RevMan 5.4.7.[19]

RESULTS

A total of 234 records were identified by the literature search once duplicates had been excluded, including 31 from PubMed and 203 from Google Scholar. After screening 201 titles and abstracts, 190 were excluded due to irrelevance. Full-text screening was conducted on 11 articles, of which 2 were excluded—one for lacking relevant outcomes and another for duplication. Ultimately, a total of 9 studies were selected for qualitative analysis. Of these, 7 studies qualified for inclusion in the meta-analysis evaluating postoperative INV angles. A subset analysis was performed, comprising 4 clinical studies and 3 cadaveric studies. (Fig. 2) (Table 2).

Study Characteristics

The study designs varied and included 2 randomized controlled trials, 3 cadaveric studies, 3 cohort studies, and 1 pilot study. Most studies originated from Switzerland (n = 3), followed by Turkey (n = 2), with individual studies from Egypt, the Netherlands, Portugal, and the United States.

Across all studies, 324 patients were analyzed, with 217 (67.0%) undergoing preservation rhinoplasty. Patient age, reported in 6 clinical studies (excluding cadaveric research), ranged from 18 to 51 years, highlighting the procedure's application primarily among young to middle-aged adults. The mean follow-up period was 10.1 months (range: 5–25.5 mo). Most studies reported short- to mid-term outcomes, with limited long-term data available.

DPR techniques across included studies varied, encompassing push-down (PD), let-down (LD), spare roof (SR), and combined approaches. INV angle measurements were primarily conducted using CBCT, except 1 cadaveric study utilizing tangential photography.

Two studies reported objective nasal airflow outcomes using rhinomanometry and acoustic rhinometry but did not assess the INV angle. Alan et al[22] utilized active anterior rhinomanometry to compare DPR with dorsal reduction rhinoplasty. In the DPR group, total nasal volume showed a significant increase at 12 months postoperatively ($P = 0.031$). There was no change in total nasal resistance, and no significant differences in rhinomanometric measurements were detected between the DPR and dorsal reduction rhinoplasty groups. Alsakka et al used acoustic rhinometry in patients undergoing DPR and reported a nonsignificant increase in nasal cross-sectional area and volume postoperatively, indicating a trend toward improved nasal patency.[21] Neither study evaluated changes in the INV angle.

Meta-analysis of Clinical Studies by LD/PD techniques (INV Angle Change)

Four clinical studies (N = 118 patients: Stergiou et al, 2020; Alsakka et al, 2024; Stergiou et al, 2021; Stergiou et al, 2022) reported pre- and postoperative INV angles suitable for meta-analysis.[12,21,23,24]

The pooled standardized mean difference (SMD) indicated a statistically significant postoperative increase in the INV angle following DPR (SMD = 0.52; 95% CI: 0.02–1.02, $P = 0.04$).

However, heterogeneity among these studies was moderate to substantial ($I^2 = 63\%$, Tau2 = 0.15, $\chi^2 = 8.10$, $P = 0.04$), primarily influenced by an outlier study (Stergiou et al, 2020),[12] which exhibited a notably large effect size (SMD = 3.60) despite a limited sample size (n = 5). A sensitivity analysis excluding this outlier study effectively reduced heterogeneity to $I^2 = 0\%$, yielding a more conservative and robust pooled estimate (SMD = 0.43; 95% CI: 0.16–0.69, $P = 0.002$); (Fig. 3).

These findings consistently suggest that DPR techniques lead to a modest yet clinically meaningful improvement in INV angles, supporting their potential benefit in enhancing nasal airway function.

Technique-specific Meta-analysis of Cadaveric Studies

In addition to clinical outcomes, a technique-specific meta-analysis was performed on cadaveric studies assessing the impact of distinct DPR techniques—PD, low-strip LD, and SR—on the INV angle. Three studies (van Zijl et al, 2025; Dias et al, 2021; Abdelwahab et al, 2020) comprising 46 nasal specimens were included.[9,25,26]

- PD technique: The PD technique was evaluated in the study by Abdelwahab et al, which included 3 specimens. Postoperative INV angle decreased (from 11.36 ± 1.28 degrees to 9.31 ± 0.58 degrees), although the change was not statistically significant (SMD = −1.65; 95% CI: −3.91 to 0.61; $P = 0.15$).[26]
- Low-strip LD technique: Two studies (Abdelwahab et al, 2020; van Zijl, 2025) assessed LD in a combined total of 13 specimens. The pooled result showed a trend toward INV angle increase (SMD = 0.86; 95% CI: −0.24 to 1.95; $P = 0.13$), but without statistical significance. Individually, van Zijl et al reported an INV angle increase from 10.0 ± 3.0 degrees to 14.3 ± 3.5 degrees, suggesting potential morphological improvement.[9,26]
- SR technique: Dias et al evaluated SR in 7 specimens, reporting a significant INV angle increase from 31.6 ± 6.8 degrees to 44.0 ± 9.4 degrees (SMD = 1.42; 95% CI: 0.20–2.63; $P = 0.02$), indicating a potentially robust functional benefit.[25]

Pooled Technique-specific Analysis

Across all 3 techniques, the combined standardized mean difference was 0.59 (95% CI: −0.50 to 1.68; $P = 0.29$),

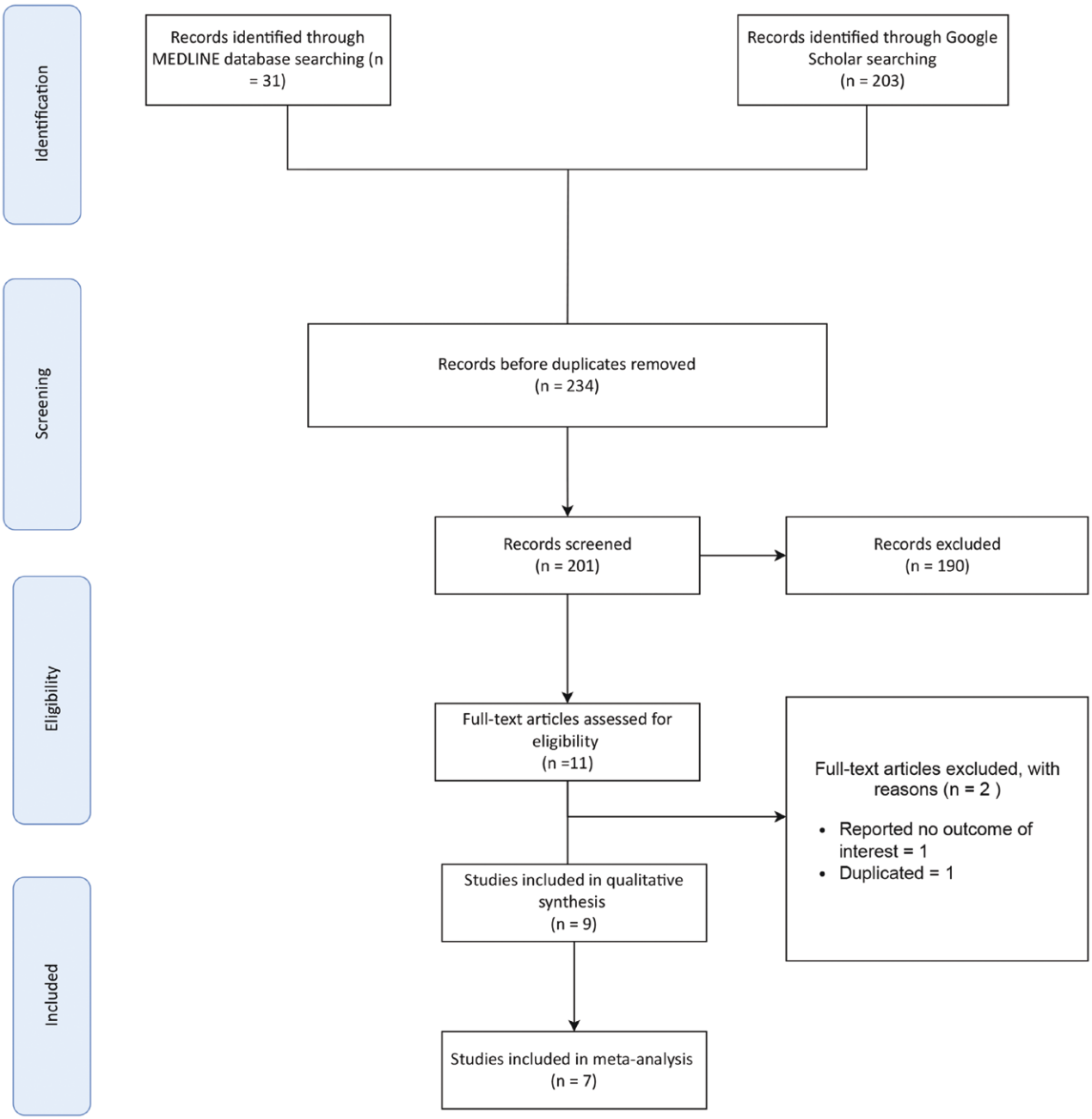

Fig. 2. PRISMA flowchart.

with moderate heterogeneity ($I^2 = 63.7\%$, $P = 0.06$). Notably, subgroup analysis revealed statistically significant differences between techniques ($P = 0.02$), emphasizing that the choice of DPR method significantly impacts postoperative INV outcomes. The SR technique demonstrated the most favorable and statistically supported improvement in INV angle (Fig. 4).

Bias Assessment

Risk of bias assessments used an appropriate validated tool.

- RCTs (Alsakka et al, 2024; Alan et al, 2023): RoB 2 indicated low overall risk, highlighting robust randomization, adequate blinding, and complete outcome reporting.[21,22]
- Cohort and Pilot Studies (Stergiou et al, 2020; Emre et al, 2024; Stergiou et al, 2021; Stergiou et al, 2022): MINORS criteria revealed moderate to high methodological quality, though some lacked prospective sample size calculations and long-term follow-up.[12,20,23,24]
- Cadaveric Studies (van Zijl et al, 2025; Dias et al, 2021; Abdelwahab et al, 2020): QUACS indicated acceptable

Table 2. Summary Table of Studies Assessing Alterations in INV Angle Following DPR

Study ID	Author, Year	Design	N (DPR)	DPR Type	Comparator	Septo-/Turbinoplasty	Preoperative INV (°)	Follow-up in mo	Postoperative INV (°)	Δ INV (°)	Tool	View
S01	van Zijl, 2025[9]	PMHS	10	Low-strip (LD)	None	No	10.01	NA	14.29	4.28	CT	Axial
S02	Emre, 2024[20]	Cohort	64	PD/LD	DHR	Yes	NA	6	NA	NA	Acoustic rhinometry	NA
S03	Alsakka, 2024[21]	RCT	25	PD	DHR	Yes	13.56 ± 2.96	3–11	14.51 ± 2.84	+0.95 ± 4.10	CBCT	NA
S04	Alan et al, 2023[22]	RCT	15	Not specified	DHR	No	NA	3–12	NA	NA	Rhinomanometry	NA
S05	Stergiou et al, 2022[23]	Prospectiv e Cohort	58	LD	None	Yes	19.88 ± 3.3	1–50	22.04 ± 4.1	+2.16 ± 5.26	CBCT	NA
S06	Stergiou et al, 2022[24]	Prospectiv e Cohort	30	LD)	None	Yes	20.77±3.2	1–18	21.82 ± 5.7	+1.05 ± 6.54	CBCT	NA
S07	Dias et al, 2021[25]	PMHS	7	SR	DHR	No	31.55	NA	2 mm 32.82 4 mm 38.43 6 mm 44.01	+1.27 to +12.46	Tangential photographs	NA
S08	Abdelwahab et al, 2020[26]	PMHS	3	LD	PD, DHR	Yes	11.36±1.28	NA	LD: 11.56±2.12 PD: 9.31° ± 0.58°	LD: +0.20±2.48 PD: −2.05 ±1.41	CBCT	Modified coronal
S09	Stergiou et al, 2020[12]	Pilot	5	PD or LD	None	Yes	26.2 ± 1.8	4—6	32.3 ± 1.2	+6.1 ± 2.16	CBCT	Coronal

PMHS, postmortem human study.

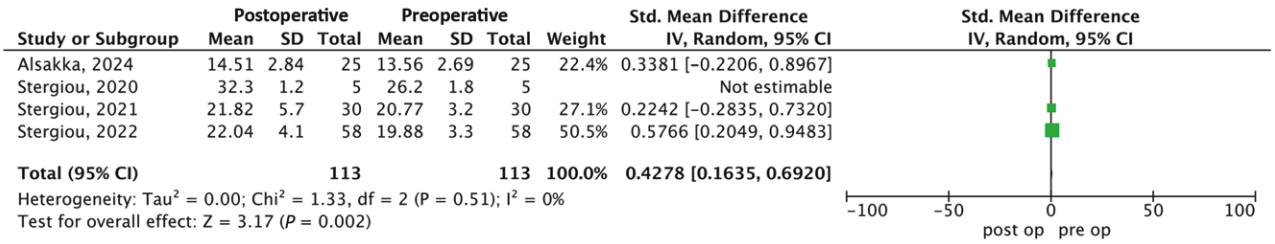

Fig. 3. Forest plot of INV angle changes pre- and postrhinoplasty across included clinical studies. A significant overall increase in INV angle was observed postoperatively (SMD: 0.43 [0.16, 0.69], $P = 0.002$) with no heterogeneity ($I^2 = 0\%$).

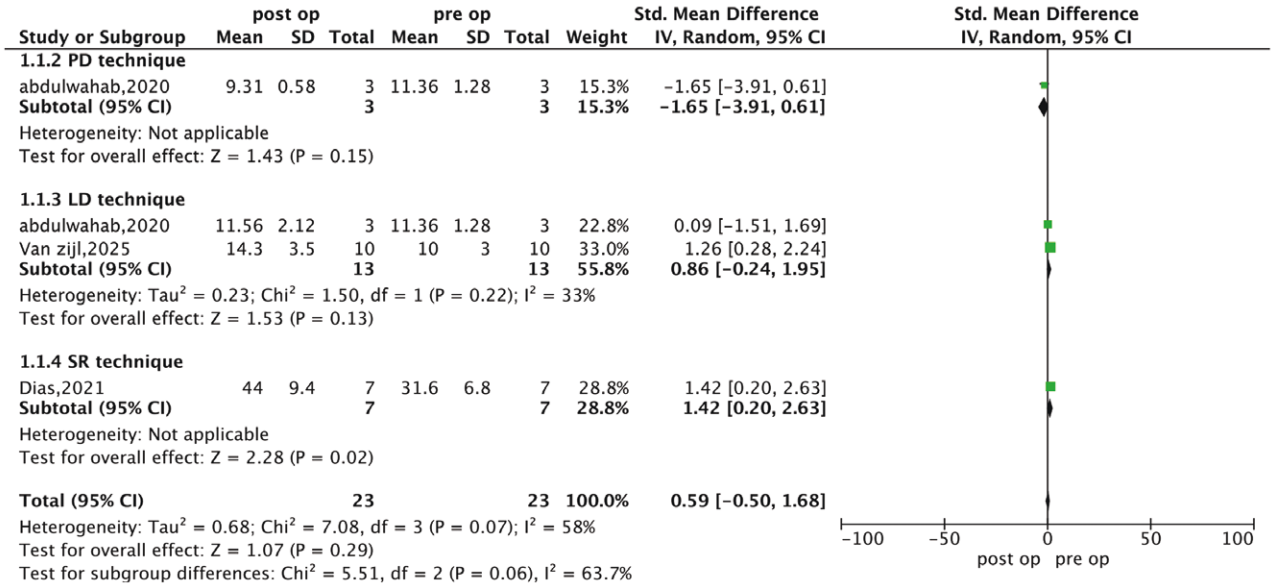

Fig. 4. Forest plot showing changes in INV angle after DPR by technique. The SR technique showed a significant increase in INV angle, although PD and LD techniques showed no significant change. Subgroup differences were significant ($P = 0.06$); overall heterogeneity was moderate ($I^2 = 63.7\%$).

anatomical methodologies but inherently limited external validity due to nonliving specimens and absence of functional validation[9,25,26] (Fig. 5).

DISCUSSION

PR techniques aim to maintain the native nasal architecture while improving both aesthetic and functional outcomes.[4–6] The INV, the narrowest portion of the nasal airway, plays a critical role in postoperative function, and its geometry is directly influenced by the choice of DPR technique[7,8] (Table 3).

Mechanistic Basis of INV Changes

Different DPR methods exert distinct mechanical effects on the INV.[6,9,10] In FTs (PD and LD), the entire osseocartilaginous dorsum descends en bloc.[5,9] The LD maneuver tends to widen the INV through controlled impaction and septal strip excision,[9,10] whereas the PD technique may paradoxically narrow the valve by seating the dorsal complex deeper into the pyriform aperture.[10,26] In contrast, STs preserve the cartilaginous middle vault and avoid complete separation of the upper lateral cartilages from the septum, thereby maintaining a more stable INV geometry and reducing the risk of postoperative collapse.[6,11] These theoretical distinctions align with cadaveric and imaging studies, which have demonstrated widening of the valve with LD and SR methods, and in some cases narrowing with PD approaches.[9,10,12,25,26]

Foundation versus Surface Techniques

A key distinction in DPR lies between FTs and STs, as proposed by Ferreira and Toriumi.[6] FTs, such as PD and LD, achieve dorsal reduction through impaction osteotomies and variable septal strip excisions. These maneuvers alter the position of the entire osseocartilaginous dorsum and can directly influence INV, depending on the degree of descent. Our review shows that LD generally increases the INV angle,[9,23,24] whereas PD may reduce or leave it unchanged.[10,26]

In contrast, STs, including the SR technique, modulate the dorsum more superficially, preserving the cartilaginous middle vault and often retaining the bony cap.[6,27] This minimizes INV disruption and may provide

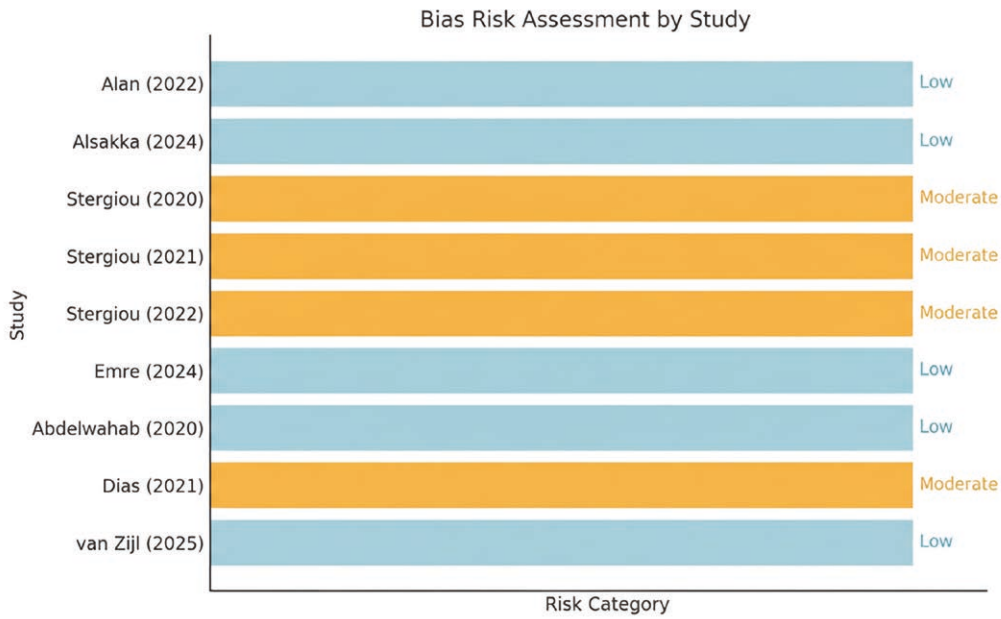

Fig. 5. Visual summary of bias risk assessment across included studies using QUACS, MINORS, and RoB 2 tools. Studies were categorized into "low" or "moderate" risk based on tool-specific scoring criteria. Blue bars represent low-risk studies, and orange bars indicate moderate risk.

Table 3. Summary of Bias Risk Assessment Across Included Studies Using QUACS, MINORS, and RoB 2 Tools

Study ID	Author (Year)	Tool	Score/Risk	Bias Risk	Key Notes
S01	van Zijl,2025[9]	QUACS	13/13	Low	All domains met; no methodological concerns
S07	Dias,2021[25]	QUACS	10/13	Moderate	Missing researcher education, observer validation, and consistency
S08	Abdelwahab, 2020[26]	QUACS	10/13	Moderate	Same as Dias: education and validation issues
S02	Emre, 2024[20]	MINORS	22/24	Low	Strong design, only lacked prospective sample size calculation
S05	Stergiou et al, 2022[23]	MINORS	13/16	Moderate	No control group or baseline equivalence
S06	Stergiou et al, 2022[24]	MINORS	12/16	Moderate	No sample size calculation or comparative groups
S09	Stergiou et al, 2020[12]	MINORS	10/16	Moderate	Lacked prospective data and control arms
S03	Alsakka et al, 2024[21]	RoB 2	Low risk	Low	Low risk across all domains
S04	Alan et al, 2023[22]	RoB 2	Low risk	Low	Unclear randomization process

Studies were categorized into "low" or "moderate" risk based on tool-specific scoring criteria.

superior functional outcomes. Dias et al[25] demonstrated that the SR technique produced the largest angle increase (+12.46 degrees) among all included studies, and Santos et al[28] confirmed both functional and aesthetic gains with this approach. These findings suggest that STs may offer a distinct advantage in preserving valve integrity compared with FTs.

Evidence from Cadaveric and Clinical Studies

Our review confirmed that these biomechanical differences translate into measurable anatomical outcomes. Van Zijl et al[9] demonstrated a significant increase in INV angle using the low-strip LD technique, and Stergiou et al similarly reported functional gains with the same method.[23,24] Dias et al documented the largest improvement with the SR technique (+12.46 degrees).[25] Conversely, Abdelwahab et al observed a decrease in the INV angle following PD, raising concerns about airway compromise.[26]

Clinical studies also support these findings through objective and subjective measures. CBCT analysis consistently shows INV widening after DPR.[12,29,30] Emre et al reported functional improvement via acoustic rhinometry,[20] whereas Alan et al observed increased nasal volume without significant resistance change.[22] Importantly, Kim et al found that patient-reported outcomes significantly improved after DPR, which is consistent with our pooled anatomical findings.[31] Together, these data suggest that both objective and subjective outcomes converge to support the functional merits of DPR.[12,20,24,31]

Meta-analysis Findings

A pooled analysis of 4 clinical studies (118 patients) demonstrated a statistically significant increase in INV angle following DPR (SMD = 0.52; 95% CI: 0.02–1.02; P = 0.04).[12,21,23,24] Moderate heterogeneity (I^2 = 63%) was largely driven by an outlier. Sensitivity analysis excluding this study yielded a more conservative and homogeneous effect (SMD

= 0.43; 95% CI: 0.16–0.69; $P = 0.002$; $I^2 = 0\%$), supporting the robustness of the pooled estimate.[12,23,24] Subgroup analysis confirmed significant technique-specific differences ($P = 0.02$): STs such as SR provided the greatest functional benefit,[25,28] LD offered moderate improvement,[9,23,24] and PD showed inconsistent or negative effects.[10,26]

Comparative Perspective

Compared with traditional dorsal hump reduction (DHR), which often disrupts midvault support and predisposes to postoperative obstruction,[1,2,32,33] DPR appears to preserve or enhance valve function.[6–8,34,35] Foppiani et al reported significant gains in nasal volume with DPR, whereas DHR did not provide similar benefits.[32] The consistency between anatomical (INV widening), physiological (acoustic rhinometry, rhinomanometry), and subjective outcomes (patient satisfaction, breathing function) strengthens the clinical relevance of DPR and highlights its dual functional–aesthetic role.[12,20,22,26,31,36]

Limitations and Future Directions

Despite these encouraging results, several limitations of this study should be noted. Objective functional outcomes were underreported, with only a minority of studies using acoustic rhinometry or rhinomanometry.[20,22] Validated PROMs were inconsistently applied, although they were included in some studies.[23,24,31] Most studies were limited by small sample sizes and short follow-up periods, precluding definitive conclusions about long-term functional benefits.[20,22,24,26] Variability in imaging modalities (CT versus CBCT) also introduced heterogeneity.[9,12,29,30]

Future research should focus on well-powered randomized controlled trials directly comparing PD, LD, and SR techniques, with standardized use of CBCT and validated functional outcome tools.[20,21,29–31] Longer follow-up and exploration of patient-specific predictors would further strengthen evidence-based DPR practice.[6,27,37,38]

CONCLUSIONS

This systematic review and meta-analysis demonstrated that DPR techniques exert differential effects on INV. FTs such as LD generally widen the valve, although PD may narrow it; STs such as SR appear to maximize functional preservation.[9,23–26,28] Pooled evidence shows a modest but clinically meaningful improvement in INV angle,[12,21,23,24] and these findings are reinforced by patient-reported functional gains.[20,22,24,31] Collectively, this convergence of anatomical, physiological, and subjective evidence supports DPR as a functionally sound alternative to traditional reduction rhinoplasty.[6,33,36,37] Technique-specific selection—particularly between FTs and STs—remains essential, and high-quality comparative studies are needed to refine surgical decision-making.[27,37,38]

Reyof Saeed Alharthi
Department of Otolaryngology – Head and Neck Surgery
King Faisal Specialist Hospital and Research Centre
Jeddah, Saudi Arabia
E-mail: reyofsaeedalharthi@gmail.com

DISCLOSURE

The authors have no financial interest to declare in relation to the content of this article.

REFERENCES

1. Nigro CE, Nigro JF, Mion O, et al. Nasal valve: anatomy and physiology. *Braz J Otorhinolaryngol.* 2009;75:305–310.
2. Bloching MB. Disorders of the nasal valve area. *GMS Curr Top Otorhinolaryngol Head Neck Surg.* 2007;6:Doc07.
3. Goudakos JK, Fishman JM, Patel K. A systematic review of the surgical techniques for the treatment of internal nasal valve collapse. *Clin Otolaryngol.* 2017;42:60–70.
4. Lothrop OA. An operation for correcting the aquiline nasal deformity; the use of new instrument; report of a case. *Boston Med Surg J.* 1914;170:835–837.
5. Cottle MH. Nasal roof repair and hump removal. *AMA Arch Otolaryngol.* 1954;60:408–414.
6. Ferreira MG, Toriumi DM. A practical classification system for dorsal preservation rhinoplasty techniques. *Facial Plast Surg Aesthet Med.* 2023;25:305–312.
7. Daniel RK.. The preservation rhinoplasty: a new rhinoplasty revolution. *Aesthet Surg J.* 2018;38:228–229.
8. Aman M, Saban Y. The high strip technique in dorsal preservation rhinoplasty. *Facial Plast Surg Clin N Am.* 2025;33:167–175.
9. van Zijl FVWJ, van der Eerden AW, Stubos M, et al. Low-strip dorsal preservation rhinoplasty opens the internal nasal valve intension nose deformity. *Laryngoscope.* 2025;135:1–8.
10. Patel PN, Abdelwahab M, Most SP. A review and modification of dorsal preservation rhinoplasty techniques. *Facial Plast Surg Aesthet Med.* 2020;22.
11. Ma CC, Most SP, Patel PN. Preservation rhinoplasty—outcomes in dorsal preservation rhinoplasty. *Facial Surg.* 2024. Published online 18 Oct 2024.
12. Stergiou G, Tremp M, Finocchi V, et al. Functional and radiological assessment after preservation rhinoplasty: a clinical study. *In Vivo.* 2020;34:2659–2665.
13. Moher D, Liberati A, Tetzlaff J, et al; PRISMA Group. Preferred reporting items for systematic reviews and meta-analyses: the PRISMA statement. *PLoS Med.* 2009;6:e1000097.
14. Higgins JPT, Green S. Cochrane handbook for systematic reviews of interventions. In: *Version 5.0.2.* Wiley; 2008:1–649.
15. Ouzzani M, Hammady H, Fedorowicz Z, et al. Rayyan—a web and mobile app for systematic reviews. *Syst Rev.* 2016;5:210.
16. Sterne JA, Savović J, Page MJ, et al. RoB 2: a revised tool for assessing risk of bias in randomized trials. *BMJ.* 2019;366:l4898.
17. Slim K, Nini E, Forestier D, et al. Methodological index for non-randomized studies (MINORS). *ANZ J Surg.* 2003;73:712–716.
18. Wilke J, Krause F, Niederer D, et al. Appraising the methodological quality of cadaveric studies: validation of the QUACS scale. *J Anat.* 2015;226:440–446.
19. The Nordic Cochrane Centre. *Review Manager (RevMan 5) [Computer program]. Version 5.4.* The Cochrane Collaboration; 2020.
20. Emre IE, Koyluoglu YO, Seyhun N, et al. Comparison of nasal airways after structural vs dorsal preservation rhinoplasty. *Ear Nose Throat J.* 2024;103:126S–134S.
21. Alsakka MA, ElBestar M, Gharib FM, et al. Dorsal preservation rhinoplasty versus dorsal hump reduction: a randomized prospective study. *Eur Arch Otorhinolaryngol.* 2024;281:3655–3669.
22. Alan MA, Kahraman ME, Yüksel F, et al. Comparison of dorsal preservation and dorsal reduction rhinoplasty: rhinomanometry and NOSE/SCHNOS scales. *Aesthetic Plast Surg.* 2023;47:728–734.

23. Stergiou G, Fortuny CG, Schweigler A, et al. A multivariate analysis after preservation rhinoplasty: a prospective study. *J Plast Reconstr Aesthet Surg*. 2022;75:369–373.
24. Stergiou G, Schweigler A, Finocchi V, et al. Quality of life (QoL) and outcome after preservation rhinoplasty using the ROE questionnaire. *Aesthetic Plast Surg*. 2022;46:1773–1779.
25. Dias DR, Rosa F, Santos M, et al. Middle vault changes after humpectomy by spare roof technique versus component dorsal hump reduction. *Facial Plast Surg Aesthet Med*. 2021;23:156–161.
26. Abdelwahab MA, Neves CA, Patel PN, et al. Impact of dorsal preservation rhinoplasty versus dorsal hump resection on the internal nasal valve. *Aesthetic Plast Surg*. 2020;44:879–887.
27. Ferreira MG, Santos M. Spare roof technique: preservation rhinoplasty in the era of osteo- and chondroplasty. In: Elwany S, ed. *Current Rhinology*. Springer; 2024: 857–70.
28. Santos M, Rego AR, Coutinho M, et al. Spare roof technique in reduction rhinoplasty: prospective study of 100 patients. *Laryngoscope*. 2019;129:2702–2706.
29. Rouientan A, Khodaparast MB, Safi Y. Evaluation of CBCT and MDCT in rhinoplasty. *Head Face Med*. 2024;20:1.
30. Tsolakis IA, Venkat D, Hans MG, et al. Comparing cone-beam CT and acoustic reflection for airway analysis. *Am J Orthod Dentofacial Orthop*. 2016;150:643–650.
31. Kim DH, Jang DW, Hwang SH. Comparison of patient-reported outcomes between dorsal preservation and conventional dorsal hump reduction rhinoplasty: a systematic review and meta-analysis. *Aesthetic Plast Surg*. 2025;49:4846–4856.
32. Foppiani JA, Joy N, Alvarez AH, et al. Dorsal preservation vs component hump reduction rhinoplasty: outcomes. *Plast Reconstr Surg Glob Open*. 2024;12:e6103.
33. Jasso-Ramírez E, Burgos-Páez A, Béjar FS, et al. Twisted nose: preservation rhinoplasty with modified push-down/let-down technique. *Plast Reconstr Surg*. 2023;151:749–757.
34. Anco N, Caballero G, Adrianzen G. Preservation rhinoplasty: a new approach to mestizo noses. *Plast Reconstr Surg Glob Open*. 2023;11:e4972.
35. Montes-Bracchini JJ. Preservation rhinoplasty (let-down technique) for endonasal dorsal reduction. *Facial Plast Surg Clin North Am*. 2021;29:59–66.
36. Patel PN, Most SP. Combining open structural and dorsal preservation rhinoplasty. *Clin Plast Surg*. 2022;49:97–109.
37. Toriumi DM, Kridel RW, Papel ID, et al. Dorsal preservation versus structural techniques. *Facial Plast Surg Clin North Am*. 2024;32:603–624.
38. Öztürk G. High and low septal strip excision in dorsal preservation rhinoplasty. *Ann Plast Surg*. 2023;90:294–300.