TIMELINE

Centenary of Brodmann's map — conception and fate

Karl Zilles and Katrin Amunts

Abstract | Rarely in the history of neuroscience has a single illustration been as influential as the cytoarchitectonic map of the human brain published by Korbinian Brodmann in his monograph from 1909. The map presents the segregation of the cerebral cortex into 43 areas, as visible in cell body-stained histological sections. More importantly, Brodmann provided a comparative neuroanatomical approach and discussed ontogenetic and pathological aspects as well as structural–functional correlations. One hundred years later, a large number of neuroscientists still use Brodmann's map for localizing neuroimaging data obtained in the living human brain.

Korbinian Brodmann (FIG. 1) started his work in the late nineteenth century (TIMELINE). In the early nineteenth century, the phrenologists Gall and Spurzheim had claimed a correlation between different, localizable psychic "faculties" in the brain and the protuberances of the skull[1]. However, the real breakthrough came with the discoveries of Broca[2] and Wernicke/Lichtheim[3], who identified language-related regions in the cerebral cortex and proposed an underlying cognitive theory. They demonstrated for the first time that lesions of circumscribed regions of the brain are responsible for the loss of different language functions like speech production or comprehension in aphasic patients. The rise of neurophysiology led to controversial discussions between scientists arguing for a holistic interpretation of the cortex and those supporting the localization paradigm. Whereas the followers of a holistic concept emphasized the role of the entire cerebral cortex in the execution of any brain function (one of the most prominent being John Hughlings-Jackson[4]), those in favour of the localization paradigm were convinced that these functions are localizable to specific cortical areas. Brodmann started his cytoarchitectonic studies in the middle of this battle. He was influenced by Darwinism and fascinated by the attempt of Oskar and Cécile Vogt[5] to parcellate the cerebral cortex into microstructural and functional units. During the next three decades, Otfried Foerster[6], Alfred Walter Campbell[7], Grafton Elliott Smith[8], Constantin Freiherr von Economo and Georg N. Koskinas[9] argued for localizable anatomical and functional correlation and the segregation of cortical entities (FIG. 2).

One of Brodmann's greatest merits was to integrate evolutionary ideas and the histological analysis of the cortex with functional localization. The centenary of Brodmann's publication[10] (FIG. 1) is a timely opportunity to remember his pioneering concepts and their fate.

Cytoarchitecture: more than localization

It seems that the theory of evolution was intensively discussed between Brodmann and Oskar Vogt, who founded the largest brain research institute of this time in Berlin (the Neurobiologisches Laboratorium; FIG. 1). This resulted in comparative studies of human and non-human primate brains and the brains of other mammals[11], and led to the concept of phylogenetically old (paleocortical and archicortical) and more recent (neocortical) subdivisions of the cerebral cortex. Paleo- and archicortical areas (the histologically defined allocortex) differ from the canonical six-layered structure of the neocortex (the histologically defined isocortex) by having fewer or more layers. The distribution of cell bodies in the grey matter of the forebrain, the formation of cortical layers, the presence of particular cell types and the arrangement of cells in clusters and columns were among the features that enabled Brodmann to parcellate the cerebral cortex into 'areas' (BOX 1; FIG. 1). The microscopical structure and classification of these areas are in parallel to the evolutionary distinction between old and new cortical subdivisions. Based on this integrative concept (histology with phylogeny), Brodmann indicated through his numbering system homologies between the cortical areas of different mammals. This underlines the meaning of cytoarchitecture and topography as important arguments in comparative neuroanatomy. Implicitly, Brodmann demonstrated that the architectonic parcellation of the human cortex can be understood only by comparison with different mammalian brains. He also speculated about anthropological aspects of his findings and criticized the generalization made by Huxley in his famous Pithecometra principle, which states that all differences between humans and great apes are less than the differences between the great apes and lower primates[12].

Brodmann's map of the human cortex[10] displays 43 cytoarchitectonic areas, whereas monkeys and great apes have only around 30 areas (see Supplementary information S1 (fig)). Each cortical area of his human map is labelled by a number between 1 and 52, but areas with the numbers 12–16 and 48–51 are not shown in his map. Brodmann explained these 'gaps' with the fact that some areas are not identifiable in the human cortex but are well developed in other mammalian species. This holds true particularly for the olfactory, limbic and insular cortices. The insular cortex is segregated into areas 14–16 in Old World monkeys (for example, *Cercopithecus*) and into areas 13–16 in prosimians (for example, *Lemuridae*). Brodmann could not find homologous areas in the human brain.

© 2010 Macmillan Publishers Limited. All rights reserved

Brodmann assumed that the polymorphism of cells and the connectivity between cells and areas is more complex in the human brain than in the brains of monkeys and great apes. He also speculated about cytoarchitectonic differences between different human races, matching the ideological prejudices of his time[13,14].

In the 1909 monograph, the chapter on the functional meaning of his cytoarchitectonic and localization studies is surprisingly small (only 36 of the 324 pages). Five years later, however, he published a large review[15], in which he tried to reconcile the cytoarchitectonic parcellation with electrophysiological observations in animals and with lesion studies in pathologically altered human brains. He summarized findings about various neurological and psychiatric diseases caused by pathological events during the formation of the cerebral cortex, and further emphasized that regionally specific architectonic disturbances are important for understanding brain disorders.

Mapping beyond Brodmann's map

The fate of Brodmann's map reflects changing neuroscientific concepts during the past 100 years. After the publication of his monograph, Brodmann emphasized the impact of his cytoarchitectonic approach on neurology and psychiatry. The clinical relevance of cytoarchitecture was already a major topic in the Vogts' Neurobiologisches Laboratorium, where Brodmann carried out his studies. The Vogts used myelin-stained histological sections to study brain architecture (that is, myeloarchitecture). Their myeloarchitectonic map has many more areas (a total of 200 according to REF. 5) than that of Brodmann, because the Vogts further subdivided the Brodmann areas on the basis of the

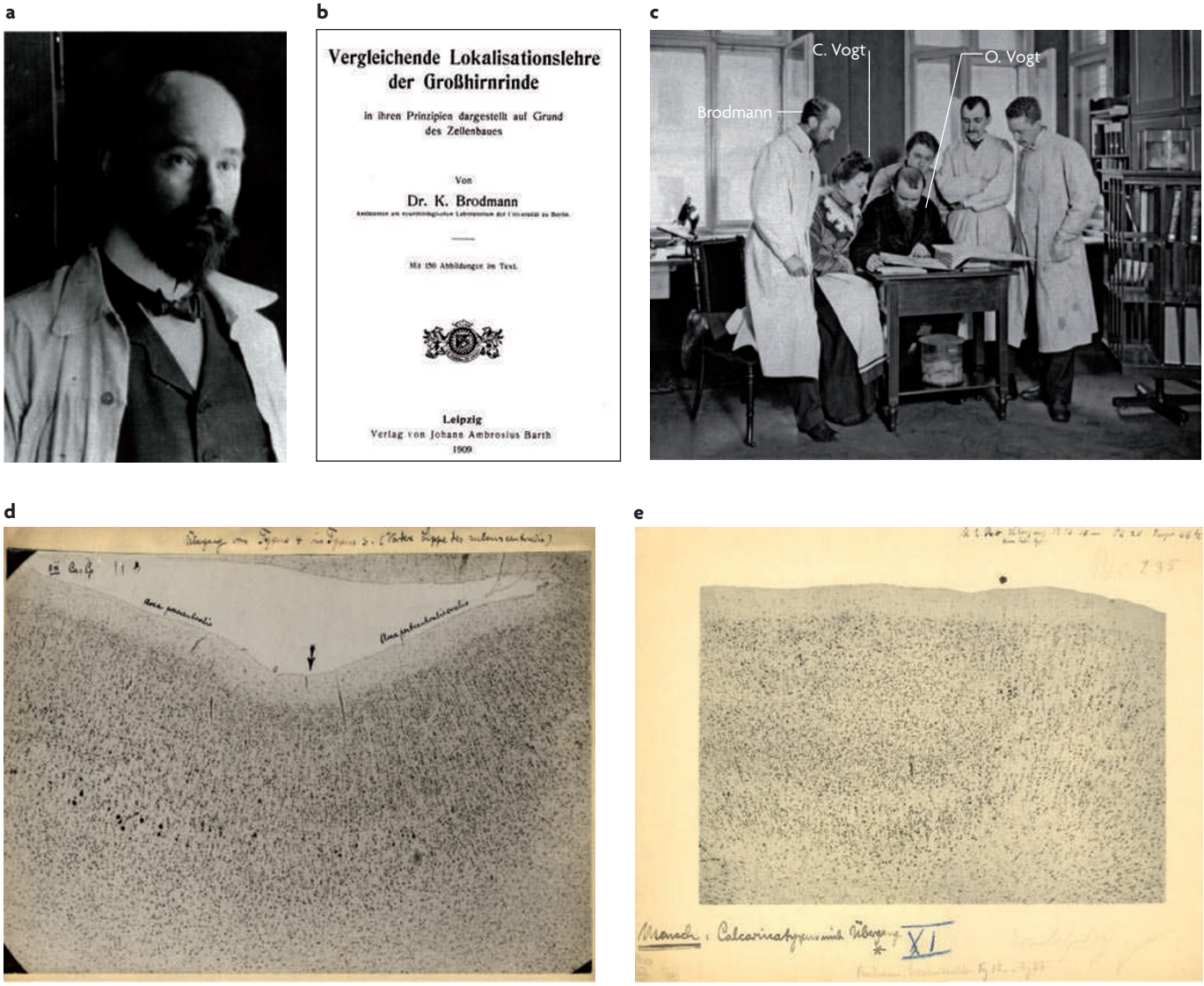

Figure 1 | **Korbinian Brodmann and his work. a** | Korbinian Brodmann. **b** | The cover page of Brodmann's seminal monograph from 1909. **c** | Brodmann in the Neurobiologisches Laboratorium of Cécile and Oskar Vogt in Berlin. **d** | One of Brodmann's cytoarchitectonic micrographs, showing the border (indicated by the arrow) between Area 4 (primary motor cortex; left side) and Area 3 (primary somatosensory cortex; right side). The handwritten inscription in the upper right corner reads (in translation): "transition between type 4 and type 3; anterior wall of the central sulcus". **e** | Another of Brodmann's cytoarchitectonic maps, showing the border (indicated by the asterisk) between area 17 (primary visual cortex (V1)) and area 18 (secondary visual cortex (V2)). The handwritten inscription in the lower left corner reads (in translation): "human brain: calcarina type with transition". The images are reproduced, with permission, from the archive of the C. & O. Vogt-Institute of Brain Research, University Düsseldorf, Germany.

© 2010 Macmillan Publishers Limited. All rights reserved

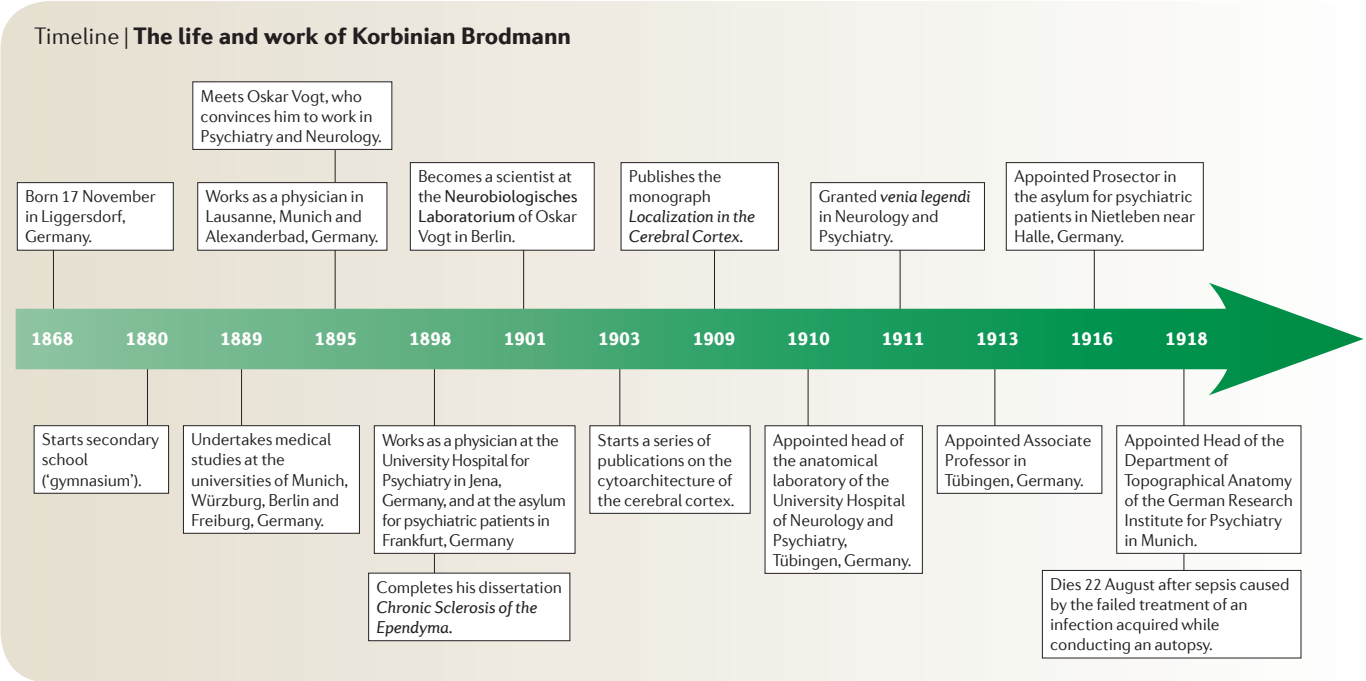

regionally more differentiated architecture of intracortical nerve fibres. The principal subdivisions of major cortical areas, however, are comparable between the cyto- and myeloarchitectonic maps. The Vogts envisaged a multimodal atlas of the cerebral cortex that could be made by combining Brodmann's cytoarchitectonic map with their own.

Von Economo's and Koskinas' (1925) monumental description of the cytoarchitecture of the human cerebral cortex is not only a further development of this research but also a tribute to Brodmann's scientific achievements[9]. Both authors identified more cortical areas than Brodmann (FIG. 2) and introduced a new ontology after those of Brodmann and the Vogts[5]. Von Economo's and Koskinas' classification system consists of a letter for the respective lobe of the forebrain in which the area is found, a second letter (or pair of letters) indicating the major type of cytoarchitecture, and a third or more letters for areal or subareal specifications. In the first half of the twentieth century, Brodmann's approach was also the basis for the studies of the whole cerebral cortex by the Russian school[16] (FIG. 2). All these maps provide similar overall parcellation schemes, but they differ considerably in the precise configuration, number and extent of the cortical areas.

Parallel to these studies, a strong opposition was formed by other researchers[17,18] (FIG. 2). Bailey and von Bonin, for instance, described how they came to doubt Brodmann's map after having accepted this type of research in their earlier work. They made photographs of over 300 sites in the cerebral cortex, "pasted them on cardboards and shuffled them like playing cards. Only those whose provenience we could recognize were retained"[17]. They failed in most cases and came to the conclusion that most brain areas cannot be distinguished from each other by pure cytoarchitectonic criteria. Furthermore, they argued that the cerebral cortex was probably over-parcellated by Brodmann and in the myeloarchitectonic studies of the Vogts and their followers, in particular. Bailey and von Bonin noted that "the efforts of all these authors were meticulous to the point of hair splitting"[17]. Thus, they highlighted one of the inherent problems in Brodmann's approach — the lack of observer independency, reproducibility and objectivity. Recent advances in image analysis have helped to overcome the subjectiveness of the parcellation of histological sections[19–22].

A further major problem with Brodmann's map was identified by Lashley and Clark: "there is significant individual variation in the architectonic structure of areas similarly located in different specimens of the same species."[18] In fact, the lack of data on intersubject variability of cytoarchitectonic areas is a major drawback of the Brodmann map and a challenge for contemporary researchers[23].

The comeback of the map and its fate

In the 1980s Brodmann's map gained unexpected popularity with the introduction of novel functional and structural neuroimaging techniques. These technologies address another of Bailey's and von Bonin's criticisms of Brodmann's cytoarchitecture: by imaging the living human brain during the performance of defined experimental tasks and registering functional and architectonic data in a common reference space it became possible to link architectonic units and their function. Consequently, Brodmann's map turned out to be integral to various sterotaxic atlases and software packages. In this context, it was necessary to 'translate' the two-dimensional information of the original map into a three-dimensional representation. As the original map did not contain data on the intrasulcal surface, these atlases have had to guess where the areal borders are located in these parts of the brain. This is a major problem because the intersulcal surface occupies two thirds of the whole cortical surface[24]. The stereotaxic atlas of Talairach and Tournoux[25] is probably the most popular example of the revival of Brodmann's map in stereotaxic atlases and a demonstration of the inherent problems. The impression of a match between sulcal landmarks and areal borders may lead to the wrong conclusion that landmarks are sufficient for the localization of a cytoarchitectonic border. Brodmann already pointed to this misconception (BOX 2). Semir Zeki correctly stated: "In fact, this type of localization is simply an approximation of the Talairach atlas, not of cytoarchitecture, which requires histological studies, analyses of intersubject variability, objective methods

© 2010 Macmillan Publishers Limited. All rights reserved

of defining cortical borders, and a direct registration in 2D- or 3D-space to cortical surfaces or volumes of actual brain" (translation from REF. 26 by K.A. and K.Z.).

Modified versions of Brodmann's map, frequently based on the Talairach and Tournoux atlas, are extensively used in the neuroimaging literature to describe the localization of activations as 'Brodmann areas' (BAs). This procedure, however, can be misleading without knowledge of the text that accompanies the drawing of the map.

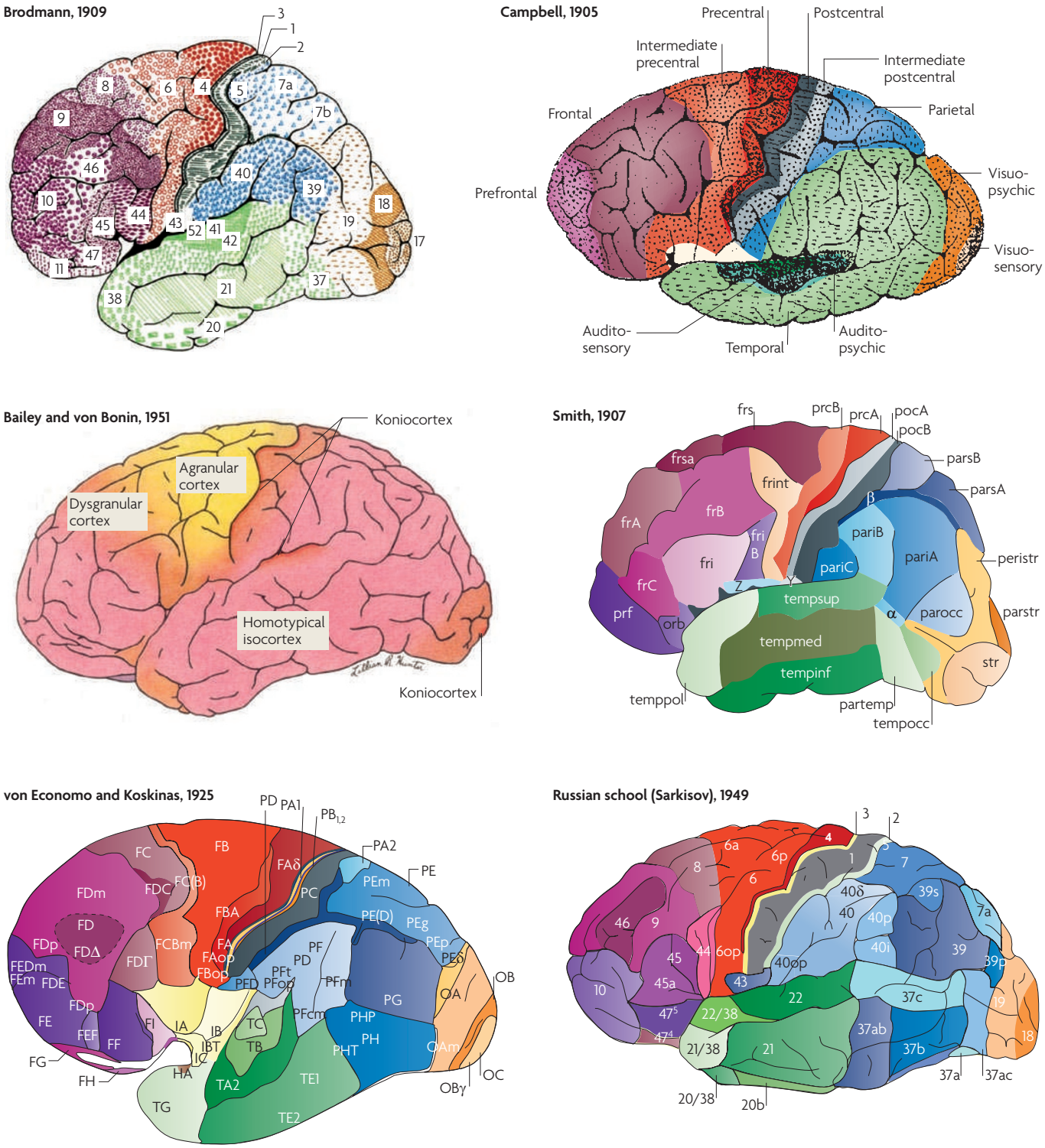

Figure 2 | **Lateral views of the cortical maps of Campbell, Smith, von Economo and Koskinas, Sarkisov, Bailey and von Bonin, and Brodmann.** Differences between the maps are apparent and may be caused by inter-subject variability but may also be caused by problems of observer-dependent parcellation techniques and different concepts of cortical organization. Colour similarities indicate similarities in structure. The original letters and numbers used to label the different areas are shown. Images are modified from REFS 7,8, 9,16,17,27.

© 2010 Macmillan Publishers Limited. All rights reserved

Box 1 | An introduction to Brodmann's brain map

The Brodmann map is a drawing of a lateral and a medial view of a schematized human brain (FIG. 2). It displays the segregation of the cerebral cortex into 43 cortical areas belonging to 11 regions. Each of the areas is characterized by a particular cytoarchitecture. Brodmann wrote: "Only those regional differentiations of the cortical structure had been taken into account, which are apparent in the laminar organization of a cross-sectioned gyrus, in the positioning, size, packing density and distribution of cells, that is, in the cytoarchitectonic differences. Histological differences *sensu strictu*, that is, details of single cells, appearance of fibrils and tigroid substance as well as details of the structure of cell nuclei, etc., are not used topographically."[11] Brodmann analysed the cytoarchitecture in cell body-stained, horizontal sections of human brains (he never stated how many). The first area that appeared in the most dorsal horizontal section was labelled Area 1; the following areas were labelled by consecutive numbers corresponding to the sequence of their appearance in the more ventrally located histological section. Brodmann was convinced that every cytoarchitectonic area is an organ that subserves a particular function. This hypothesis could not be rigorously tested in his time, except for some so-called primary areas such as the primary visual cortex. This area receives heavy projections from the retina via the lateral geniculate body and generates a neuronal representation of the visual field. Recent experimental studies in animals, lesion studies and functional imaging studies in the human brain demonstrated that his map is incomplete or even wrong in some of the brain regions. For example, the tri-partition of the occipital (visual) cortex suggested by Brodmann is in sharp contrast to the several dozens of visual areas of recent maps (for example, REF. 40).

For example, the map presents the primary auditory cortex (area 41) on the free surface of the superior temporal gyrus (FIG. 2), but Brodmann described in the text of the monograph the extent of the primary auditory cortex as hidden in the lateral fissure. Some recent articles reproduced or cited Brodmann's map of 1909 when referring to the orbitofrontal area 12, but this area is not mentioned in this map. It was introduced by Brodmann in a later modification of the map[27] by which he tried to 'harmonize' the monkey and the human brain maps.

Brodmann's map, when used as a pure localizational tool and source of signposts of BA labels, can generate misleading architectonic localizations of functional imaging data, because the map does not reflect the intersubject variability of cortical areas. The localization of activation foci can be expressed only in terms of probability, as the cytoarchitectonic borders and the activation foci are highly variable between subjects. Consequently, cytoarchitectonic maps as structural references for functional studies must be probabilistic[28–31] (FIG. 3).

With neuroimaging developments and new applications for neuroimaging, the limitations of Brodmann's pioneering map and the need for further cytoarchitectonic research became apparent. This had been envisaged by Brodmann (BOX 2). Recent research focused on intersubject variability, registering cytoarchitectonic data in a common reference space, developing reproducible and observer-independent definitions of cortical areas and borders, and including connectivity, molecular and functional aspects (for an overview see REFS 32,33). Brodmann's cytoarchitectonic approach has

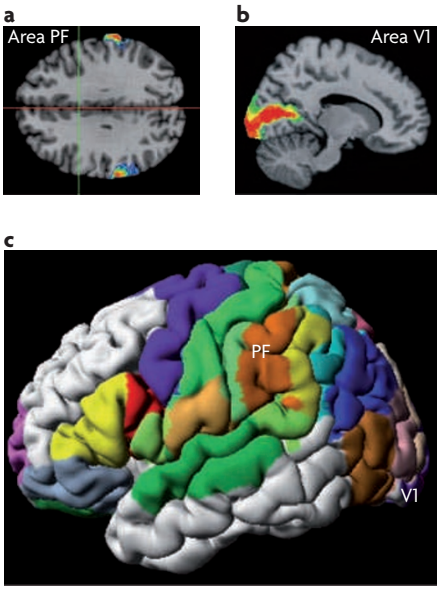

Figure 3 | **Probability maps of the human cortex based on quantitative cytoarchitecture and statistical tests for the localization of borders between areas.** The Jülich–Düsseldorf cytoarchitectonic probabilistic brain atlas is based on observer-independent mapping of cortical areas in ten post-mortem brains[34,41]. **a**,**b** | Cytoarchitectonic probabilistic maps of (**a**) area PF of the inferior parietal lobule (corresponding to a part of Brodmann's area 40) and (**b**) the primary visual area (V1) (corresponding to Brodmann's area 17) in standard reference space of the MNI[42,43]. Red indicates regions of high overlap (low intersubject variability); blue–green indicates regions of low overlap (high variability). **c** | Lateral view of the MNI reference brain with maximum probability map, illustrating the current status of the Jülich–Düsseldorf atlas. The maximum probability map[30] has been generated on the basis of cytoarchitectonic probabilistic maps in standard reference space; it assigns each voxel of the reference space to the area with the highest probability. Grey regions are not yet mapped. Published maps are available at: http://www.fz-juelich.de/inm/spm_anatomy_toolbox. Part **b** is modified, with permission, from REF. 32 © (2006) Macmillan Publishers Ltd. All rights reserved.

Box 2 | A fictive interview with Korbinian Brodmann

Are cytoarchitectonic areas sharply delineable? Or are there broad transition zones that indicate a continuous shift in cytoarchitecture?

Brodmann: "The transition between two neighbouring types, that is, the laminar differentiation between these types occurs more or less in a circumscribed manner, at some points so suddenly, that a sharp linear border is present between the neighbouring fields."[11]

Does your map of the cortical surface precisely reproduce the topographical position of cortical areas and their borders?

Brodmann: "It must be stated that the projection of the spatial cortical centres onto the hemispherical surface is always a humble attempt, and that the schematic drawing carries with it in many respects anatomical imprecision and even mistakes. Borders between neighbouring fields, which are found in the depths of sulci, must be omitted or projected to the free surface; this condition leads in many cases (areas 2, 3, 5, 6, 18, 19, etc.) to a shift of the borders from the wall of a sulcus to the crown of a gyrus. […] Any person, who wants to learn about the precise borders of particular fields and about their extent in detail, must invest efforts to study these borders in the original sections."[11]

Do macroscopical landmarks predict the position of the borders of cytoarchitectonic areas?

Brodmann: "The borders do not match, with a few exceptions, sulci and gyri of the cortical surface, or any other external morphological features."[11]

Does your brain map provide a complete picture of cortical segregation?

Brodmann: "Only the basic organizational plan of the cerebral cortex […] was the aim of my attempt, and I confess without any hesitation that using a detailed histological analysis, namely the novel methods […] further differentiations and, probably, delineations of histologically differing fields will be found. I hope, however, that I achieved a preliminary result of the histological localization of the cerebral cortex within the constraints of my work."[11]

© 2010 Macmillan Publishers Limited. All rights reserved

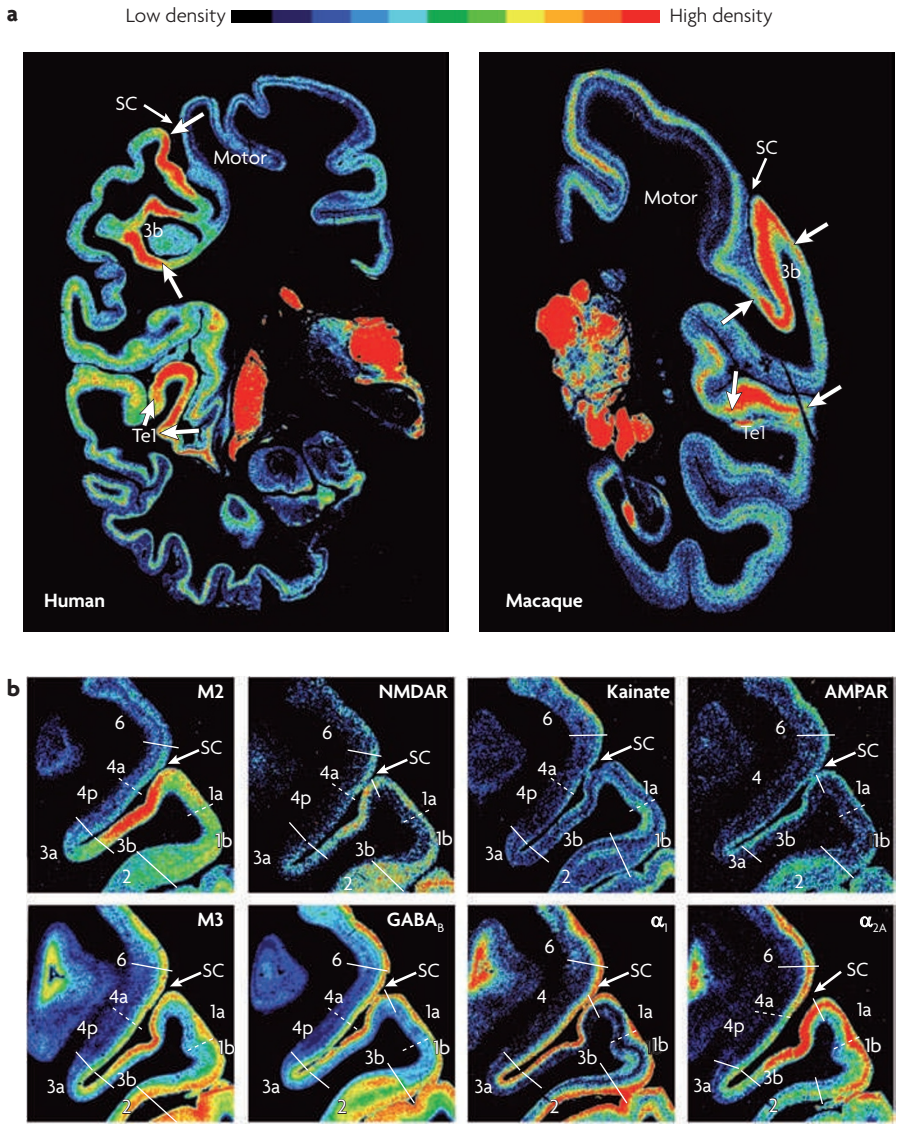

Figure 4 | **Cortical maps based on the quantitative *in vitro* receptor autoradiography of the regional and laminar distribution of neurotransmitter receptors in the human and macaque brain. a** | Cholinergic muscarinic M2 receptors (labelled with [^{3}H]oxotremorine-M) in coronal sections through a human (left) and a macaque (right) hemisphere. Homologous cortical areas show identical (for example, 3b primary somatosensory cortex, Te1 (REF. 44), primary auditory cortex) or very similar (for example, motor cortex) regional and laminar expression levels of this muscarinic subtype. **b** | Various transmitter receptors around the central sulcus demonstrate the segregation of the cerebral cortex into cortical areas. Most of the receptor architectonic borders (indicated by arrows) are found in precisely the same position in adjoining cell body-stained sections for cytoarchitectonic[44–47] analysis. Multi-receptor architectonic analysis, however, reveals additional borders. 1, 1a and 1b indicate somatosensory area 1 with an anterior (1a) and posterior (1b) subarea; 2 indicates somatosensory area 2; 3, 3a and 3b indicate Brodmann's area 3 (primary somatosensory cortex), with area 3a responsible for proprioceptive representation and area 3b responsible for touch representation); 4, 4a and 4p indicate Brodmann's area 4, with 4a being the anterior part of the primary motor cortex and 4p being the posterior part of the primary motor cortex; 6 indicates the lateral premotor cortex (part of Brodmann's area 6). The architectonic subdivisions revealed by changes in receptor density coincide with the localization of cytoarchitectonic borders in most cases. However, the consideration of multiple receptors enables the identification of more detailed parcellations (Brodmann's area 4 is subdivided into 4a and 4p, area 3 is further subdivided into 3a and 3b, et cetera) and hints at functional aspects of cortical organization[47]. α_1, noradrenergic α_1 receptor; α_{2A} noradrenergic α_{2A} receptor; AMPAR, α-amino-3-hydroxy-5-methyl-4-isoxazole propionic acid receptor; GABA$_B$, GABA (γ-aminobutyric acid)-ergic GABA$_B$ receptor; M2, cholinergic muscarinic M2 receptor; M3 cholinergic muscarinic M3 receptor; NMDAR, *N*-methyl-D-aspartate receptor; sc, central sulcus.

become more powerful through the inclusion of his map in a multimodal brain map. For example, multi-receptor mapping provides a multimodal perspective of the anatomical, functional and molecular organization of the brain and may serve as a reference for clinical and pharmacological studies of brain diseases[34] (FIG. 4). The relation between cytoarchitecture and connectivity was greatly advanced by the introduction of diffusion tensor imaging (for example, REF. 35) and fibre tracking (for example, REFS 36,37). However, these methods are still in their infancy, as the registration of fibre tracts cannot replace studies of synaptic and functional connectivity. The development of fibre-tracking techniques with much higher spatial resolution is urgently required. High-resolution MRI enables architectonic definitions of only a few cytoarchitectonic areas *in vivo*[38,39], and it is still far from providing a sufficiently detailed map of all Brodmann areas.

Conclusions and perspectives

The aim of architectonic brain mapping research today is to provide a microstructural frame for data produced by multimodal analyses of the cerebral cortex. Brodmann's map was the pioneering piece of work in the field and still has great impact on neuroscientific and clinical brain research. It is unique in that it forms the basis for the ongoing analysis of the relation between function or dysfunction and cortical structure. The results of architectonic brain mapping during the past 100 years highlight the microstructural segregation of the cerebral cortex and its implications for understanding psychological and pathological processes. In conclusion, Brodmann's map is not simply a tool for localization. To say it in Brodmann's own words in the introduction to his 100-year-old monograph: "Our goal is to produce a comparative, organic theory of the cerebral cortex based on anatomical features"[10].

Karl Zilles is at the Institute of Neuroscience and Medicine (INM-2), Research Center Jülich, Leo-Brandt Straße, 52428 Jülich, Germany, and at the C. & O. Vogt Institute for Brain Research, Heinrich Heine University Düsseldorf, Moorenstr. 5, 40225 Düsseldorf, Germany.

Katrin Amunts is at the Institute of Neuroscience and Medicine (INM-1), Research Center Jülich, Leo-Brandt Straße, 52428 Jülich, Germany, and at the Department of Psychiatry and Psychotherapy, RWTH Aachen University, Pauwelsstr. 30, 52074 Aachen, Germany.

Correspondence to K.A.
e-mail: k.amunts@fz-juelich.de

doi:10.1038/nrn2776
Published online 4 January 2010

© 2010 Macmillan Publishers Limited. All rights reserved

1. Gall, F. J. & Spurzheim, J. C. Anatomie et Physiologie du Systéme Nerveux en Général, et du Cerveau en Particulier (Schoell, Paris, 1810).
2. Broca, P. in *Broca's Region* (eds Grodzinsky, Y. & Amunts, K.) 291–304 (Oxford Univ. Press, New York, 2006).
3. Lichtheim, L. On aphasia. *Brain* **7**, 433–484 (1885).
4. Hughlings-Jackson, J. Notes on the physiology and pathology of language. *The Medical Times and Gazette* **1**, 659–662 (1866).
5. Vogt, C. & Vogt, O. Allgemeinere Ergebnisse unserer Hirnforschung. *J. Psychol. Neurol.* **25**, 292–398 (1919).
6. Foerster, O. Über die Bedeutung und Reichweite des Lokalisationsprinzips im Nervensystem. *Verh. Dtsch Ges. Inn. Med.* **46**, 117–211 (1934).
7. Campbell, A. W. *Histological Studies on the Localisation of Cerebral Function* (Cambridge Univ. Press, Cambridge, UK, 1905).
8. Elliot Smith, G. A new topographical survey of the human cerebral cortex, being an account of the distribution of the anatomically distinct cortical areas and their relationship to the cerebral sulci. *J. Anat.* **41**, 237–254 (1907).
9. von Economo, C. & Koskinas, G. N. *Die Cytoarchitektonik der Hirnrinde des erwachsenen Menschen* (Springer, Berlin, 1925).
10. Brodmann, K. *Vergleichende Lokalisationslehre der Großhirnrinde in ihren Prinzipien dargestellt auf Grund des Zellenbaues* (Barth, Leipzig, 1909); English translation available in Garey, L. J. *Brodmann's Localization in the Cerebral Cortex* (Smith Gordon, London, 1994).
11. Brodmann, K. Beiträge zur histologischen lokalisation der Grosshirnrinde. III. Die rindenfelder der niederen affen. *J. Psychol. Neurol.* **4**, 177–226 (1905).
12. Huxley, T. H. *Evidence as to Man's Place in Nature* (Williams & Norgate, London, 1863).
13. Brodmann, K. Neue Forschungsergebnisse der Großhirnrindenanatomie mit besonderer Berücksichtigung anthropologischer Fragen. *Verh. Ges. Dtsch Naturf. Ärzte* **85**, 200–240 (1913).
14. Gould, S. J. *The Mismeasure of Man* (Norton, New York, 1981).
15. Brodmann, K. in *Allgemeine Chirurgie der Gehirnkrankheiten* (eds Knoblauch, A., Brodmann, K. & Hauptmann, A.) 86–426 (Verlag von Ferdinand Enke, Stuttgart, 1914).
16. Sarkisov, S. A., Filimonoff, I. N. & Preobrashenskaya, N. S. *Cytoarchitecture of the Human Cortex Cerebri* (Medgiz, Moscow, 1949) (in Russian).
17. Bailey, P. & von Bonin, G. *The Isocortex of Man* (Univ. Illinois Press, Urbana, 1951).
18. Lashley, K. S. & Clark, G. The cytoarchitecture of the cerebral cortex of *Ateles*: a critical examination of architectonic studies. *J. Comp. Neurol.* **85**, 223–305 (1946).
19. Schleicher, A., Amunts, K., Geyer, S., Morosan, P. & Zilles, K. Observer-independent method for microstructural parcellation of cerebral cortex: a quantitative approach to cytoarchitectonics. *Neuroimage* **9**, 165–177 (1999).
20. Annese, J., Gazzaniga, M. S. & Toga, A. W. Localization of the human cortical visual area MT based on computer aided histological analysis. *Cereb. Cortex* **15**, 1044–1053 (2005).
21. Schmitt, O. & Böhme, M. A robust transcortical profile scanner for generating 2-D traverses in histological sections of richly curved cortical courses. *Neuroimage* **16**, 1103–1119 (2002).
22. Jones, S. E., Buchbinder, B. R. & Aharon, I. Three-dimensional mapping of cortical thickness using Laplace's equation. *Hum. Brain Mapp.* **11**, 12–32 (2000).
23. Zilles, K. *et al.* A quantitative analysis of sulci in the human cerebral cortex: development, regional heterogeneity, gender difference, asymmetry, intersubject variability and cortical architecture. *Hum. Brain Mapp.* **5**, 218–221 (1997).
24. Zilles, K., Armstrong, E., Schleicher, A. & Kretschmann, H. J. The human pattern of gyrification in the cerebral cortex. *Anat. Embryol.* **179**, 173–179 (1988).
25. Talairach, J. & Tournoux, P. *Coplanar Stereotaxic Atlas of the Human Brain* (Thieme, Stuttgart, 1988).
26. Zeki, S. Zu Brodmanns Area 18 und Area 19. *Exp. Brain Res.* **36**, 195–197 (1979).
27. Brodmann, K. in *Handbuch der Neurologie* (ed. Lewandowsky, M.) 206–307 (Springer, Berlin, 1910).
28. Roland, P. E. & Zilles, K. Structural divisions and functional fields in the human cerebral cortex. *Brain Res. Rev.* **26**, 87–105 (1998).
29. Zilles, K., Schleicher, A., Palomero-Gallagher, N. & Amunts, K. in *Brain Mapping: The Methods* (eds Mazziotta, J. C. & Toga, A.) 573–602 (Elsevier, Amsterdam, 2002).
30. Eickhoff, S. *et al.* A new SPM toolbox for combining probabilistic cytoarchitectonic maps and functional imaging data. *Neuroimage* **25**, 1325–1335 (2005).
31. Amunts, K. *et al.* Broca's region revisited: cytoarchitecture and intersubject variability. *J. Comp. Neurol.* **412**, 319–341 (1999).
32. Toga, A. W., Thompson, P. M., Mori, S., Amunts, K. & Zilles, K. Towards multimodal atlases of the human brain. *Nature Rev. Neurosci.* **7**, 952–966 (2006).
33. Roland, P. E. & Zilles, K. Brain atlases - a new research tool. *Trends Neurosci.* **17**, 458–467 (1994).
34. Zilles, K. & Amunts, K. Receptor mapping: architecture of the human cerebral cortex. *Curr. Opin. Neurol.* **22**, 331–339 (2009).
35. Pierpaoli, C., Jezzard, P., Basser, P. J., Barnett, A. & Di Chiro, G. Diffusion tensor MR imaging of the human brain. *Radiology* **201**, 637–648 (1996).
36. Johansen-Berg, H. & Rushworth, M. F. Using diffusion imaging to study human connectional anatomy. *Annu. Rev. Neurosci.* **32**, 75–94 (2009).
37. Mori, S. & Zhang, J. Principles of diffusion tensor imaging and its applications to basic neuroscience research. *Neuron* **51**, 527–539 (2006).
38. Fatterpekar, G. M. *et al.* Cytoarchitecture of the human cerebral cortex: MR microscopy of excised specimens at 9.4 Tesla. *Am. J. Neurorad.* **23**, 1313–1321 (2002).
39. Walters, N. *et al. In vivo* identification of human cortical areas using high resolution MRI: an approach to structure-function correlation. *Proc. Natl. Acad. Sci. USA* **100**, 2981–2986 (2003).
40. Fellemann, D. J. & van Essen, D. C. Distributed hierarchical processing in the primate cerebral cortex. *Cereb. Cortex* **1**, 1–47 (1991).
41. Amunts, K., Schleicher, A. & Zilles, K. Cytoarchitecture of the cerebral cortex - more than localization. *Neuroimage* **37**, 1061–1065 (2007).
42. Caspers, S. *et al.* The human inferior parietal cortex: cytoarchitectonic parcellation and interindividual variability. *Neuroimage* **33**, 430–448 (2006).
43. Amunts, K., Malikovic, A., Mohlberg, H., Schormann, T. & Zilles, K. Brodmann's areas 17 and 18 brought into stereotaxic space - where and how variable? *Neuroimage* **11**, 66–84 (2000).
44. Morosan, P. *et al.* Human primary auditory cortex: cytoarchitectonic subdivisions and mapping into a spatial reference system. *Neuroimage* **13**, 684–701 (2001).
45. Geyer, S. *et al.* Two different areas within the primary motor cortex of man. *Nature* **382**, 805–807 (1996).
46. Geyer, S., Schleicher, A. & Zilles, K. Areas 3a, 3b, and 1 of human primary somatosensory cortex: I. Microstructural organisation and interindividual variability. *Neuroimage* **10**, 63–83 (1999).
47. Zilles, K. *et al.* Architectonics of the human cerebral cortex and transmitter receptor fingerprints: reconciling functional neuroanatomy and neurochemistry. *Eur. Neuropsychopharmacol.* **12**, 587–599 (2002).

Acknowledgements
This work was partly supported by the Initiative and Network Fund of the Helmholtz Association within the Helmholtz Alliance on Systems Biology (Human Brain Model project to K.Z.). Further support by the Deutsche Forschungsgemeinschaft (AM 118/1-2, K.A.) and the German Ministry for Education and Research (01GW0613, 01GW0623, 01GW0771 to K.A.) is acknowledged. We thank our teams in Düsseldorf and Jülich, in particular S. Caspers, M. Falk, S. Eickhoff, H. Mohlberg, P. Morosan, N. Palomero-Gallagher and A. Schleicher.

Competing interests statement
The authors declare no competing financial interests.

FURTHER INFORMATION
Karl Zilles' homepage: http://www.fz-juelich.de/inm/index.php?index=319
Katrin Amunts' homepage: http://www.fz-juelich.de/inm/inm-1/index.php?index=307

SUPPLEMENTARY INFORMATION
See online article: S1 (fig)

ALL LINKS ARE ACTIVE IN THE ONLINE PDF

© 2010 Macmillan Publishers Limited. All rights reserved