i An update to this article is included at the end

Clinical Neurology and Neurosurgery 153 (2017) 27–34

Contents lists available at ScienceDirect

Clinical Neurology and Neurosurgery

journal homepage: www.elsevier.com/locate/clineuro

Impact of timing of cranioplasty on hydrocephalus after decompressive hemicraniectomy in malignant middle cerebral artery infarction

Tobias Finger[a,*], Vincent Prinz[a], Evelyn Schreck[a], Alexandra Pinczolits[a], Simon Bayerl[a], Thomas Liman[b], Johannes Woitzik[a], Peter Vajkoczy[a]

[a] Department of Neurosurgery, Universitätsmedizin Charite, Berlin, Germany
[b] Department of Neurology, Universitätsmedizin Charite, Berlin, Germany

ARTICLE INFO

Article history:
Received 16 October 2016
Received in revised form 2 December 2016
Accepted 3 December 2016
Available online 9 December 2016

Keywords:
Hemicraniectomy
Malignant middle cerebral artery infarction
Shunt dependence
Cranioplasty
Hydrocephalus

ABSTRACT

Objective: Patients with malignant middle cerebral artery infarction frequently develop hydrocephalus after decompressive hemicraniectomy. Hydrocephalus itself and known shunt related complications after ventriculo-peritoneal shunt implantation may negatively impact patientsí outcome. Here, we aimed to identify factors associated with the development of hydrocephalus after decompressive hemicraniectomy in malignant middle cerebral artery infarction.

Patients and methods: A total of 99 consecutive patients with the diagnosis of large hemispheric infarctions and the indication for decompressive hemicraniectomy were included. We retrospectively evaluated patient characteristics (gender, age and selected preoperative risk factors), stroke characteristics (side, stroke volume and existing mass effect) and surgical characteristics (size of the bone flap, initial complication rate, time to cranioplasty, complication rate following cranioplasty, type of implant, number of revision surgeries and mortality).

Results: Frequency of hydrocephalus development was 10% in our cohort. Patients who developed a hydrocephalus had an earlier time point of bone flap reimplantation compared to the control group (no hydrocephalus = 164 ± 104 days, hydrocephalus = 108 ± 52 days, $p < 0.05$). Additionally, numbers of revision surgeries after cranioplasty was associated with hydrocephalus with a trend towards significance ($p = 0.08$).

Conclusion: Communicating hydrocephalus is frequent in patients with malignant middle cerebral artery infarction after decompressive hemicraniectomy. A later time point of cranioplasty might lead to a lower incidence of required shunting procedures in general as we could show in our patient cohort.

© 2016 Elsevier B.V. All rights reserved.

1. Introduction

Over last years the treatment of patients with space occupying middle cerebral artery infarctions has fundamentally changed. More and more early surgical decompressive hemicraniectomies are performed to prevent increased intracranial pressure due to developing cerebral edema. This change of paradigm was necessary due to the poor outcome of conservative treatment in these patients with mortality rates of up to 78%. Several large prospective randomized trials have clearly demonstrated a significant reduction of mortality and improvement of patient outcome after hemicraniectomy [1–4]. In particular patients between 18 and 60 years, an infarct volume exceeding 145 cm^3, an initial NIHSS score of >15 taken to surgery within the first 48 h after symptom onset benefit from a decompressive hemicraniectomy. An absolute risk reduction of 50% concerning mortality and 42% concerning a modified Ranking Score ≥4 after 12 months can be achieved [3]. The benefit of the initial surgical treatment can still be found 3 years after hemicraniectomy [5]. However, despite these promising results, some patients develop complications that are solely related to the hemicraniectomy. The influence of those surgical complications on the long term outcome is insufficiently recognized and discussed.

Besides the classical surgical complications (wound infections, meningitis, cerebral abscess formation, hematomas, cerebrospinal fluid (CSF) fistulas etc.) there is a certain spectrum of complica-

* Corresponding author at: Department of Neurosurgery Charité-Universitätsmedizin Berlin, Augustenburger Platz 1, 13353, Berlin, Germany.
E-mail address: tobias.finger@charite.de (T. Finger).

http://dx.doi.org/10.1016/j.clineuro.2016.12.001
0303-8467/© 2016 Elsevier B.V. All rights reserved.

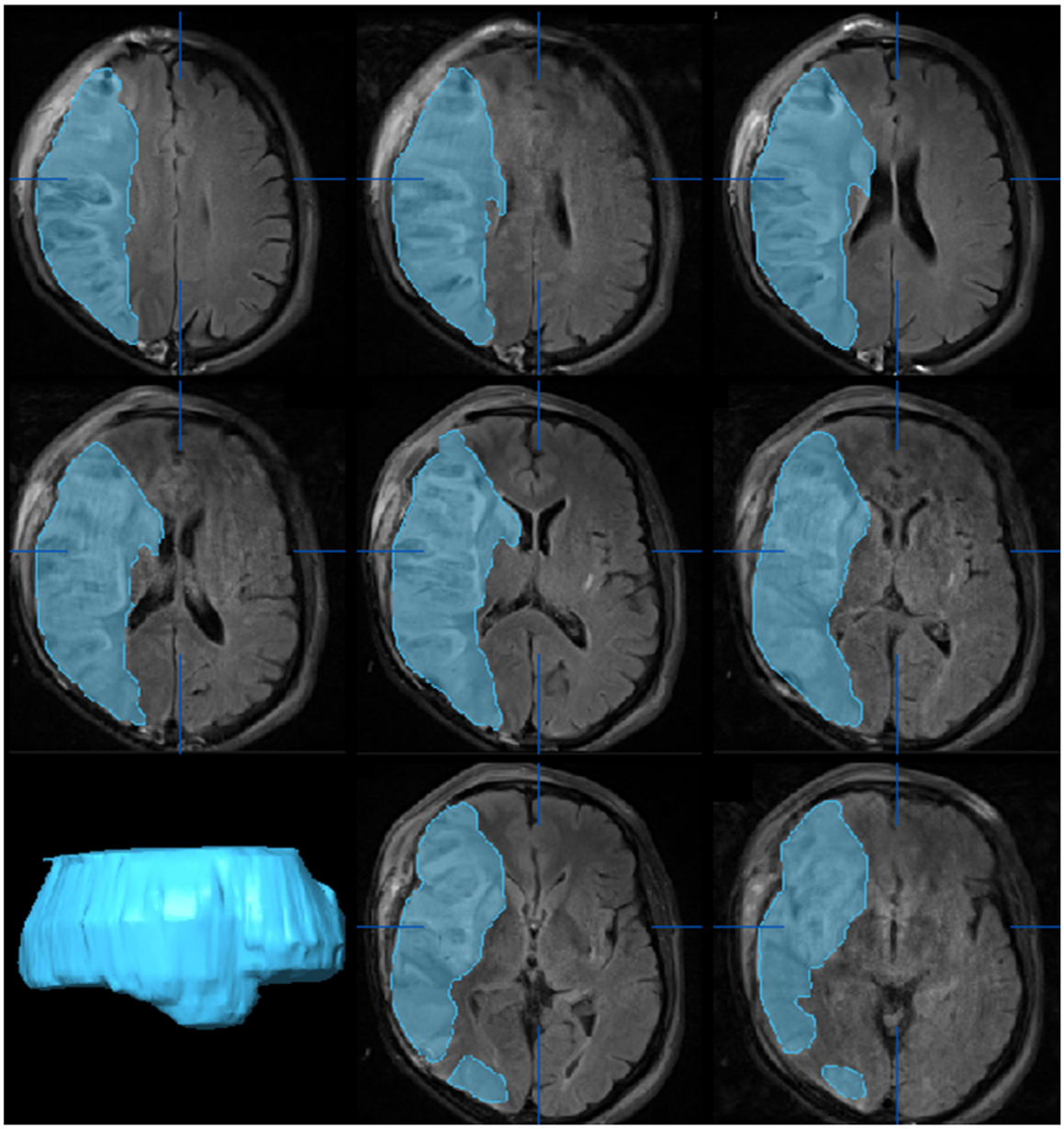

Fig. 1. Preoperative MRI scan showing a large right sided malignant middle cerebral artery infarction (grey).

tions that can be attributed to a wrong allocation of CSF, impaired CSF circulation and malabsorption of CSF following decompressive hemicraniectomy. Development of hydrocephalus and subsequent increase of intracranial pressure (ICP) is probably one of the more frequent complications in this spectrum. Numbers up to 47,8% have been reported [6–9]. There seems to be evidence that the development of hydrocephalus after decompressive hemicraniectomy may have a negative influence on the neurological outcome [10]. On the other hand, reports of the sinking skin flap syndrome describe paradoxical herniation as a possible result of a reduced intracranial pressure [11,12]. In a small prospective patient cohort 26% of the patients developed a sinking skin flap syndrome radiographically, only 11% had relevant clinical symptoms [13]. Further the development of extra-axial fluid collections is yet another CSF related complication that has been reported with an incidence of 18% in these patients [14,15] while its clinical relevance is insufficiently understood. Ropper et al. could show that all the extra-axial fluid collections in patients after decompressive hemicraniectomy because of a malignant middle cerebral artery infarction resolved spontaneously [15].

Beyond decompressive craniectomy for treatment of malignant middle cerebral artery infarction of course decompressive surgery as well is performed following severe traumatic brain injury [16,17]. As shown in a review by Stiver et al. development of post-cranioplasty hydrocephalus is a common complication [18]. A recent retrospective study reviewing the data of all patients at their institution who underwent cranioplasty following craniectomy for stroke, subarachnoid haemorrhage, epidural hematoma, subdural hematoma, and trauma reported an incidence of 13,5% for post-cranioplasty hydrocephalus [19]. In contrast, only 1% of patients with head injury and without craniectomy develop hydrocephalus, while up to 30% develop hydrocephalus following aneurysmal SAH [20,21]. Hydrocephalus itself is associated with a poorer neurological outcome following traumatic brain injury [22,23].

In this retrospective study, we aimed to elucidate the incidence of the development of hydrocephalus after decompressive hem-

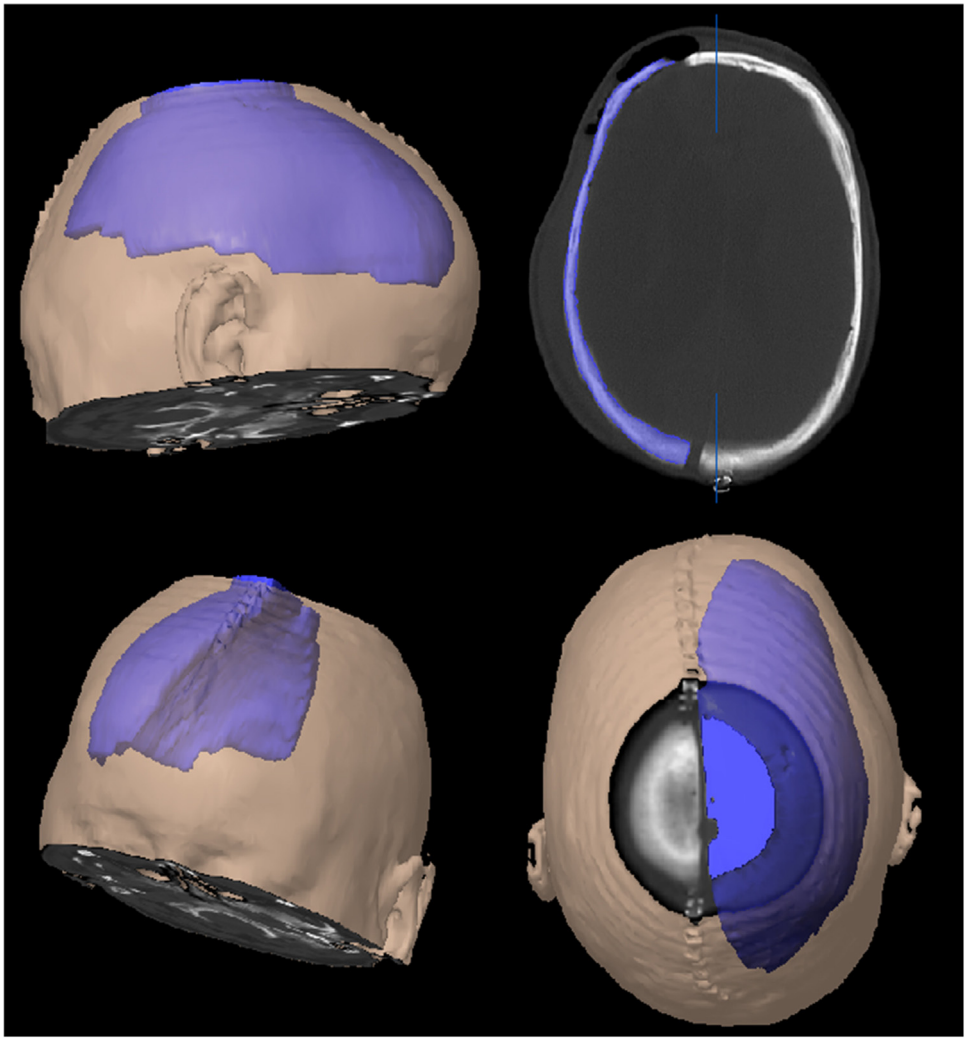

Fig. 2. Postoperative CCT scan after right sided hemicraniectomy showing the measured bone flap (grey).

icraniectomy in patients with malignant middle cerebral artery infarction. It is known that the development of hydrocephalus in these patients has a negative influence on the outcome. The outcome is even further impaired by well-known surgery and shunt related complications [10]. However, so far this group of patients is insufficiently recognized and characterized. We therefore tried to identify risk factors that may allow the clinician to anticipate the development of hydrocephalus in certain patients and possibly find ways to further decrease the incidence.

2. Methods

Clinical data was collected by a chart review approved by the local ethics committee (reference number: EA2/169/13). A total of 99 consecutive patients were included in this retrospective analysis. All patients had the diagnosis of a large middle cerebral artery infarction with an infarct volume exceeding 145 cm^3 with the indication for decompressive hemicraniectomy. Excluded were patients with other underlying conditions being the cause for a decompressive hemicraniectomy (e.g. intracerebral haemorrhage, acute subdural hematoma, subarachnoid haemorrhage with intracerebral haemorrhage, cerebral edema, subdural empyema).

Patients were operated after a previously published protocol with an anterior posterior extent of the craniotomy of at least 15 cm, the temporal bone is removed down to the temporal skull base, the

Table 1
Patient characteristics.

	w/o hydro	with hydro	p-value
Age (years)	52,9 ± 11,7	53,7 ± 5,6	0.83
Gender (m/f)	55/34	6/4	0.91
Hypertension (%)	53%	30%	0.17
Atrial fibrillation (n)	18%	10%	0.53
Coronary heart disease (n)	9%	0%	0.32
History of myocardial infarction (n)	10%	0%	0.29
Patent foramen ovale (n)	12%	20%	0.50
History of heart valve corrections (n)	7%	0%	0.39
IDDM (n)	19%	0%	0.13
Hypercholesterolemia (n)	24%	10%	0.33
Obesity (n)	12%	10%	0.83
Chronic obstructive pulmonary disease (n)	2%	10%	0.18
History of autoimmune disease (n)	2%	0%	0.63
History of Cancer (n)	1%	10%	0.06
Alcohol abuse (n)	4%	10%	0.45
Nicotine abuse (n)	28%	40%	0.43
Drug abuse (n)	3%	0%	0.56
Intake of anticoagulants (n)	10%	10%	0.92

Table 2
Stroke characteristics.

	w/o hydro	with hydro	p-value
Stroke volume (cm^3)	251 ± 90	224 ± 96	0,39
Volume of the ipsilateral hemisphere (cm^3)	656 ± 84	620 ± 98	0,28
Volume of the contralateral hemisphere (cm^3)	536 ± 65	494 ± 75	0,09
Side (left/right)	33/56	4/6	0,86
NIHSS score on admission	18,4 ± 6,3	18,9 ± 5,7	0,83
GCS score on admission	11,6 ± 3,7	10,8 ± 2,8	0,52

dura was opened in stellate technique, we did not perform resection of the temporal muscle or the temporal lobe, closure was performed in accordance to the rapid closure technique [24,25]. The surgical procedures were performed in one institution between 2005 and 2013.

Patients were divided in two groups: 1) patients without hydrocephalus (w/o hydro) and 2) patients with hydrocephalus (with hydro). Criteria for clinical relevant hydrocephalus was enlargement of the ventricular system with clinical improvement after CSF drainage either through an already existing external ventricular drainage, repeated lumbar punctures or the placement of a lumbar drain with the option of continuous CSF drainage of 5–10 ml/h over a minimum time period of at least 24 h. Clinical improvement of the patient is tantamount to an increased alertness. A few scoring systems exist that try to quantify a patientís alertness. Here we used the measuring range of zero and below of the Richmond Agitation Sedation Scale (RASS) [26–28]. It is a very reliable and easy to use scoring system with a high inter-rater reliability that is firmly implemented into the daily routine on our ICU. Nurses and physicians each rate every patient once every 8 h and document the score. An increment of the RASS score of at least 2 points or up to zero was defined as clinical improvement.

Both groups were then compared concerning certain patient, stroke and the surgical characteristics. The following patient characteristics were analyzed: gender, age and selected preoperative risk factors (hypertension, atrial fibrillation, coronary heart disease, patent foramen ovale, insulin dependent diabetes mellitus (IDDM), history of myocardial infarction, history of heart valve corrections, hypercholesterolemia, obesity, chronic obstructive pulmonary disease, history of autoimmune disease, history of cancer, alcohol abuse, nicotine abuse, drug abuse, intake of anticoagulants). Important stroke characteristics were the side and the stroke volume. The volume was evaluated with the software 'iPlan Cranial 3.0' (Brainlab©) on the first CCT scan or MRI scan after decompressive hemicraniectomy (Fig. 1).

To better evaluate the existing mass effect of the stroke we also measured the volume of the ipsilateral and contralateral hemisphere pre- and postoperatively. We believe that this information is a more accurate parameter compared to the measurement of maximum midline shift. Size of the bone flap in volume of removed bone, initial complication rate, time until cranioplasty, complication rate after cranioplasty (<30 days and >30 days), type of implant, distance of the apical craniotomy from the midline, number of revision surgeries and mortality were the surgery related factors that we evaluated (Fig. 2).

The Mann-Whitney test (values were not normal distributed) or the student T-test (values are normal distributed) were used to test differences in continuous variables, and the $\chi 2$ test for those in proportions. All statistical tests were 2-tailed, and statistical significance was set at $p < 0.05$. SPSS software (SPSS 21.0) was used for all analyses.

3. Results

Patient, stroke and surgical characteristics are summarized in Tables 1–3. In total, we evaluated 99 patients with a mean age of 53 years ± 11 years with a gender distribution of 62% male and 38% female patients. All patients had malignant middle cerebral artery infarction and were operated within the first 72 h after symptom onset. In our patient cohort 10 of the 99 patients developed a hydrocephalus with the need for the implantation of a ventriculo-peritoneal shunt (VP-Shunt) (Fig. 3). From the 10 hydrocephalus patients eight patients developed a post-cranioplasty hydrocephalus and two patients a post-craniectomy hydrocephalus. All surgical procedures were performed in a staged fashion.

Eight out of 99 patients developed a contralateral midline shift (8,1%). None of these 8 patients showed clinical symptoms for a syndrome of the trephined with improvement of neurological deficits after cranioplasty [29].

After statistical evaluation of the patient characteristics we could not find any predisposing factor that was found more often in the hydrocephalus group. Only the history of previous cancer showed a slight tendency ($p = 0.06$) towards the development of hydrocephalus, statistically not significant.

Initial stroke volume assessment did not show any difference between the two groups. In group "w/o hydro" the mean stroke volume was 251 ± 90 cm^3 compared to 224 ± 96 cm^3 in group "with hydro" ($p = 0.39$). Comparing the volumes of the ipsi- and contralateral hemispheres did neither reveal any significant difference (ipsilateral: group "w/o hydro" = 656 ± 84 cm^3, group "with hydro" = 620 ± 98 cm^3, $p = 0{,}28$; contralateral: group "w/o hydro" = 536 ± 65 cm^3, group "with hydro" = 494 ± 75 cm^3, $p = 0.09$).

The initial neurological admission status measured with the NIHSS score (group "w/o hydro" = 18,4 ± 6,3, group "with hydro" = 18,9 ± 5,7, $p = 0.83$) and the GCS score (group "w/o hydro" = 11,6 ± 3,7, group "with hydro" = 10,8 ± 2,8, $p = 0.52$) did not show any differences between the two groups either [30–32].

Table 3
Surgical characteristics.

	w/o hydro	with hydro	p-value
Bone flap volume (cm^3)	106 ± 34	105 ± 24	0.95
Complications after decompression (n)	135/89	18/10	0.62
Time until cranioplasty (days)	164 ± 104	108 ± 52	0.**046**
Volume of the ipsilateral hemisphere pre-cranioplasty (cm^3)	630 ± 185	595 ± 130	0.53
Volume of the contralateral hemisphere pre-cranioplasty (cm^3)	503 ± 79	537 ± 65	0.21
Distance of the apical craniotomy from the midline (mm)	22,4 ± 3,9	21,0 ± 4,0	0.30
Complications after cranioplasty <30d (n)	23/89	4/10	0.14
Complications after cranioplasty >30d (n)	20/89	3/10	0.55
Type of implant (bone/CAD/bone cement)	10/0/0	82/4/3	0.36
Number of revision surgeries after cranioplasty (n)	39/89	15/10	0.08
Mortality (%)	2,2%	0%	0.63

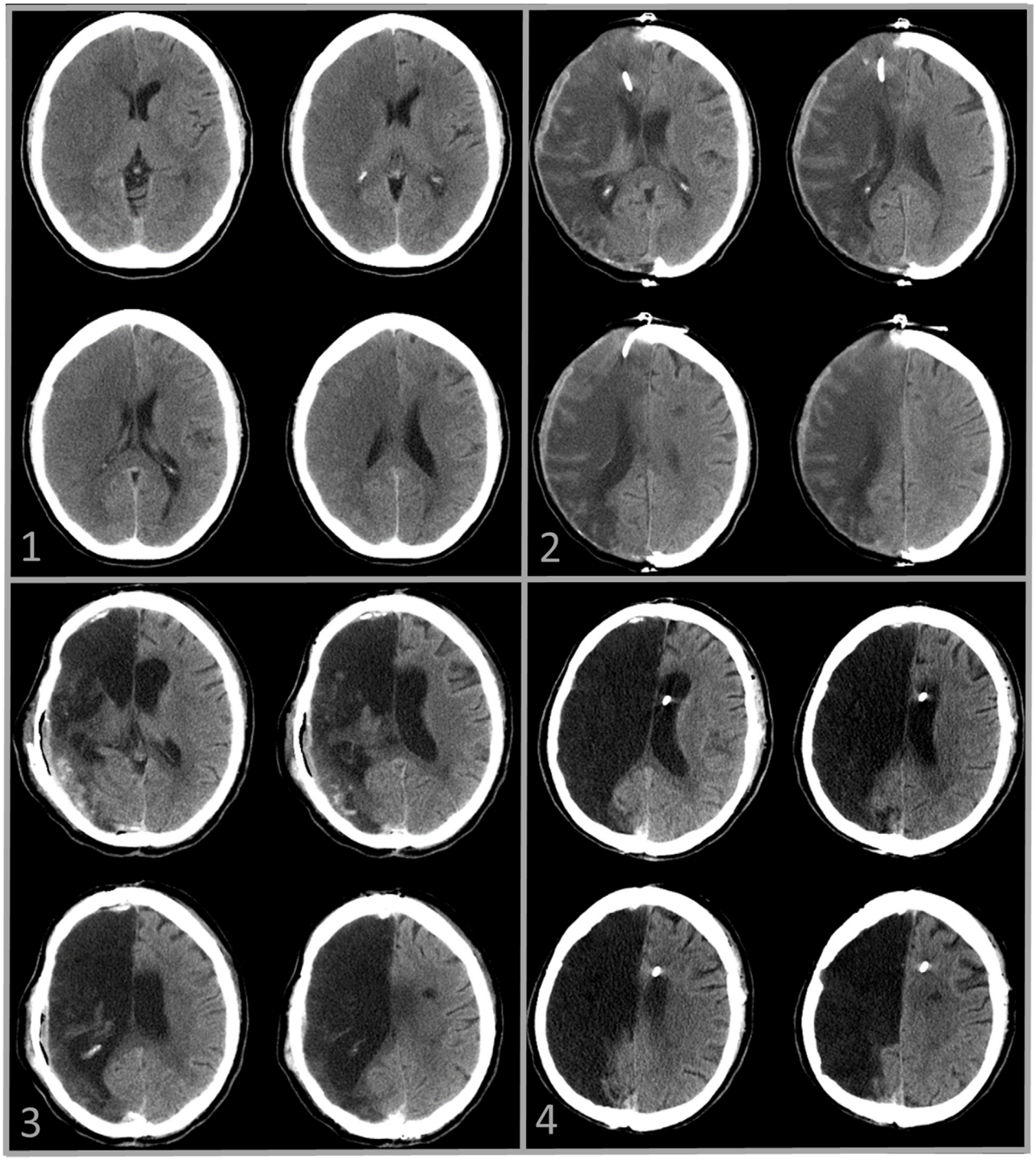

Fig. 3. CCT imaging showing the clinical course of a patient that developed hydrocephalus. 1: preoperative CCT. 2: postoperative CCT. 3: follow up CCT showing hydrocephalus after cranioplasty. 4: CCT scan 1 month after VP shunt implantation.

The size of the craniotomy (group "w/o hydro" = $106 \pm 34\,cm^3$, group "with hydro" = $105 \pm 24\,cm^3$, $p = 0.95$) and the number of complications after the decompressive hemicraniectomy did also not have an influence on the development of hydrocephalus. Likewise, we did not see any effect of the amount of complications after cranioplasty, the type of implant or the number of revision surgeries. Mortality after cranioplasty was 2% on average over both groups.

Comparing the volumes of the ipsi- and contralateral hemispheres on the planning CCT scans pre-cranioplasty did neither reveal any significant difference (ipsilateral: group "w/o hydro" = $630 \pm 185\,cm^3$, group "with hydro" = $595 \pm 130\,cm^3$, $p = 0{,}53$; contralateral: group "w/o hydro" = $503 \pm 79\,cm^3$, group "with hydro" = $537 \pm 65\,cm^3$, $p = 0.21$) between the two groups.

Finally, the time between the initial decompression and the cranioplasty was the only factor that seemed to have impact on the development of hydrocephalus. Over all 99 patients the time point of reimplantation was scattered widely, between 38 and 658 days. Patients that developed hydrocephalus had a statistically significant earlier time point of reimplantation compared

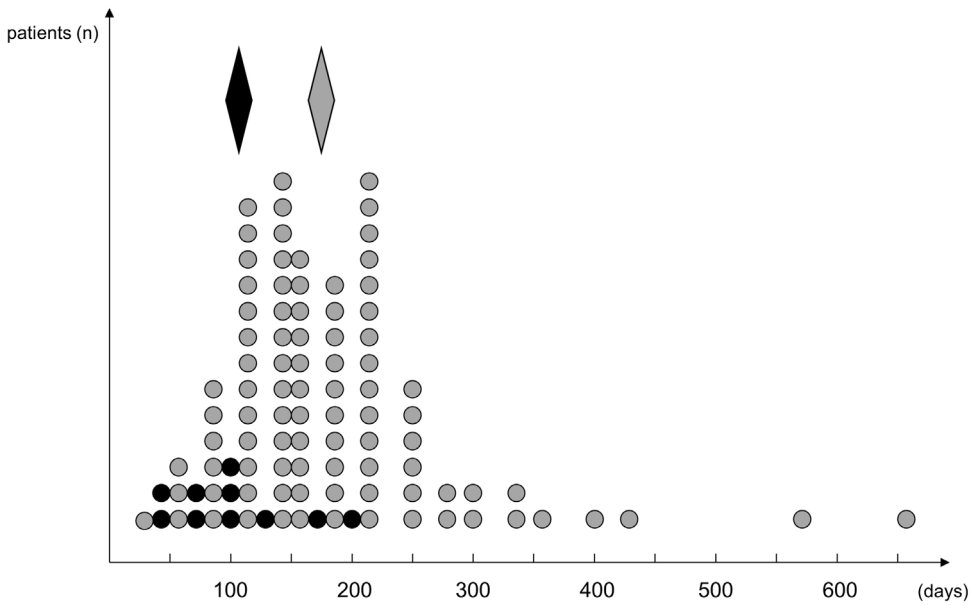

Fig. 4. Distribution of patients mapped according to the time point of cranioplasty. (grey circle = one patient group "w/o hydro", black circle = one patient group "with hydro", grey rhomb = mean time interval group "w/o hydro", black rhomb = mean time interval group "with hydro").

to the control group (group "w/o hydro" = 164 ± 104 days, group "with hydro" = 108 ± 52 days, $p < 0.05$) (Fig. 4). If you calculate this into an odds ratio and compare patients that were reimplanted <100 days from the initial decompression to patients that were reimplanted >100 days, the result is 4.2. When comparing the same population divided by the reimplantation time point of >150 days versus <150 days the odds ratio is 3.1.

4. Discussion

This study has the following main findings: 1) The incidence for development of hydrocephalus in patients following hemicraniectomy due to a malignant middle cerebral artery infarction is 10%. 2) An earlier time point of cranioplasty was the only factor predisposing a patient towards the development of hydrocephalus. 3) Patients who were reimplanted within the first 100 days after the initial decompression developed a hydrocephalus 4.2 times more likely compared to patients that were operated on later. 4) Other factors like the size of the bone flap, the patientsí age or the number of complications did not influence hydrocephalus development.

There is a number of data available on the incidence of hydrocephalus in trauma patients after decompressive hemicraniectomy [33–36]. Rates of 10–15% of patients who develop hydrocephalus have been reported in this context. [16,18,19,21,22]. However, so far only a few publications analyzed the incidence and related factors concerning the development of hydrocephalus after decompressive hemicraniectomy because of malignant middle cerebral artery infarction [6,7,9,10]. In those publications, the rate of hydrocephalus development ranges from 0% to 48%. If all this data is pooled a total of 68 patients with malignant middle cerebral artery infarction and decompressive hemicraniectomy were evaluated. Twelve of these patients developed a hydrocephalus with the need for a shunt procedure which calculates into a combined incidence of around 18%. In our study 10 out of the 99 patients developed hydrocephalus with the need for a VP shunt implantation which equates to an incidence of 10%. Interestingly this amount corresponds to the rates of clinical relevant hydrocephalus in patients after trauma related decompressive craniectomy. Thus it has to be considered that the average range of 10% hydrocephalus development may be a strict surgery dependent factor, irrespective of the underlying pathology that led to surgery.

In contrast to previous studies, our study showed a higher rate of hydrocephalus development in patients with an earlier time point of cranioplasty. Due to the retrospective nature of our analysis we tried to address confounding factors that may have influenced the clinical decision making pre cranioplasty.

One major argument would be a classic chicken or egg causality dilemma: It could be argued that some of our patients in group "with hydro" developed an early hydrocephalus and were therefore operated on earlier. However, if that was the case we should find differences in the hemispheric volumes on the planning CCT scans pre-cranioplasty. Patients in group "with hydro" should than show larger volumes due to the already existing hydrocephalus compared to patients in group "w/o hydro". In our study there was no statistical significant difference between those two groups. As all surgical procedures were performed in a staged fashion (no simultaneously cranioplasty and VP shunt implantation), we believe that the timing of the cranioplasty procedure was not related to the timepoint of hydrocephalus development. In two patients, the VP shunt was implanted before cranioplasty and in the other 8 patients it was vice versa. Therefore, we cannot rule out a selection bias concerning the timing of cranioplasty and its possible correlation to the timepoint of hydrocephalus development in this retrospective study but we believe that this is rather unlikely.

We hypothesize that the increased number of patients developing hydrocephalus with early cranioplasty may be related to an impaired venous outflow and a temporary increased pressure on the arachnoid villi. Those extend into the dural venous sinuses (e.g. sup. sagittal sinus) and are together with the choroid plexuses and the lymphatics the primary sites of CSF absorption. The rate of absorption is pressure dependent [37–39]. An earlier reimplantation of the bone flap may happen in a time window when the venous outflow situation is still slightly impaired due to the changes after decompressive craniectomy (e.g. space occupying infarct tissue). Putting the bone flap back in may cause additional pressure on the arachnoid villi, increase the venous pressure, lower the CSF absorption and therefore be the reason for hydrocephalus development. In patients where the bone flap is reimplanted on a later timepoint the venous outflow situation may have normalized and

the changes caused by the cranioplasty may not reach the venous pressure threshold that causes impairment of CSF absorption.

Another point of criticism could be that we did not perform a multivariate analysis to level other possible factors of influence. Due to the small sample size and outcome variable with n = 10 of patients with malignant stroke who develop hydrocephalus we were not able to perform multivariable analysis and adjust for possible cofounders.

We are aware that this study has certain limitations. The retrospective nature of this study and the fact that the data only represents the results of a single center are the two most significant ones. However, to the best of our knowledge this is the first study including almost 100 patients evaluating the incidence of hydrocephalus after decompressive craniectomy after malignant middle cerebral artery infarction. Furthermore, in this study clinical data in addition to radiological findings for decision making concerning shunt implantation was used.

At present the timing of cranioplasty is hotly debated among peers. We are looking forward to the long term follow up results of the large hemicraniectomy studies, as shunt related complications (infection, overdrainage, underdrainage etc.) may have an influence on the long term outcome. So far, we cannot make a general recommendation concerning the "right" time point of reimplantation, but our data strongly suggest not to reimplant within the first 100 days after decompression.

5. Conclusion

Communicating hydrocephalus is a serious complication that can arise after decompressive hemicraniectomy in patients with malignant middle cerebral artery infarction. Our data demonstrate that the incidence of clinically relevant hydrocephalus with the need for a shunting procedure appears to be lower than previously assumed. A later time point of cranioplasty correlated with a lower incidence of required shunting procedure in our patient cohort. Prospective randomized trials are warranted to clarify this issue.

Conflict of interest

All authors certify that they have no affiliations with or involvement in any organization or entity with any financial interest (such as honoraria; educational grants; participation in speakers' bureaus; membership, employment, consultancies, stock ownership, or other equity interest; and expert testimony or patent-licensing arrangements), or non-financial interest (such as personal or professional relationships, affiliations, knowledge or beliefs) in the subject matter or materials discussed in this manuscript.

Funding

Vincent Prinz is participant in the Charité Clinical Scientist Program funded by the Charité – Universitätsmedizin Berlin and the Berlin Institute of Health.

Ethical approval

All procedures performed in studies involving human participants were in accordance with the ethical standards of the institutional and/or national research committee and with the 1964 Helsinki declaration and its later amendments or comparable ethical standards. Clinical data was collected by a chart review approved by the local ethics committee (reference number: EA2/169/13).

References

[1] J. Hofmeijer, L.J. Kappelle, A. Algra, G.J. Amelink, J. van Gijn, H.B. van der Worp, et al., Surgical decompression for space-occupying cerebral infarction (the hemicraniectomy after middle cerebral artery infarction with life-threatening edema trial [HAMLET]): a multicentre, open, randomised trial, Lancet Neurol. 8 (2009) 326–333.
[2] E. Juttler, S. Schwab, P. Schmiedek, A. Unterberg, M. Hennerici, J. Woitzik, et al., Decompressive surgery for the treatment of malignant infarction of the middle cerebral artery (DESTINY): a randomized, controlled trial, Stroke 38 (2007) 2518–2525.
[3] K. Vahedi, J. Hofmeijer, E. Juettler, E. Vicaut, B. George, A. Algra, et al., Early decompressive surgery in malignant infarction of the middle cerebral artery: a pooled analysis of three randomised controlled trials, Lancet Neurol. 6 (2007) 215–222.
[4] K. Vahedi, E. Vicaut, J. Mateo, A. Kurtz, M. Orabi, J.P. Guichard, et al., Sequential-design, multicenter, randomized, controlled trial of early decompressive craniectomy in malignant middle cerebral artery infarction (DECIMAL Trial), Stroke 38 (2007) 2506–2517.
[5] M. Geurts, H.B. van der Worp, L.J. Kappelle, G.J. Amelink, A. Algra, J. Hofmeijer, et al., Surgical decompression for space-occupying cerebral infarction: outcomes at 3 years in the randomized HAMLET trial, Stroke 44 (2013) 2506–2508.
[6] M.H. Lee, J.T. Yang, H.H. Weng, Y.K. Cheng, M.H. Lin, C.H. Su, et al., Hydrocephalus following decompressive craniectomy for malignant middle cerebral artery infarction, Clin. Neurol. Neurosurg. 114 (2012) 555–559.
[7] R. Rahme, A.G. Weil, M. Sabbagh, R. Moumdjian, A. Bouthillier, M.W. Bojanowski, Decompressive craniectomy is not an independent risk factor for communicating hydrocephalus in patients with increased intracranial pressure, Neurosurgery 67 (2010) 675–678, discussion 678.
[8] S. Takeuchi, Y. Takasato, H. Masaoka, T. Hayakawa, H. Yatsushige, K. Shigeta, et al., Hydrocephalus following decompressive craniectomy for ischemic stroke, Acta Neurochi. Suppl. 118 (2013) 289–291.
[9] A. Waziri, D. Fusco, S.A. Mayer, G.M. McKhann 2nd, E.S. Connolly Jr., Postoperative hydrocephalus in patients undergoing decompressive hemicraniectomy for ischemic or hemorrhagic stroke, Neurosurgery 61 (2007) 489–493, discussion 493–484.
[10] S. Takeuchi, Y. Takasato, H. Masaoka, T. Hayakawa, H. Yatsushige, K. Nagatani, et al., Hydrocephalus after decompressive craniectomy for hemispheric cerebral infarction, J. Clin. Neurosci. 20 (2013) 377–382.
[11] P.T. Akins, K.H. Guppy, Sinking skin flaps, paradoxical herniation, and external brain tamponade: a review of decompressive craniectomy management, Neurocrit. Care 9 (2008) 269–276.
[12] J. Gadde, P. Dross, M. Spina, Syndrome of the trephined (sinking skin flap syndrome) with and without paradoxical herniation: a series of case reports and review, Del. Med. J. 84 (2012) 213–218.
[13] M. Sarov, J.P. Guichard, S. Chibarro, E. Guettard, O. Godin, A. Yelnik, et al., Sinking skin flap syndrome and paradoxical herniation after hemicraniectomy for malignant hemispheric infarction, Stroke 41 (2010) 560–562.
[14] S.V. Nalbach, A.E. Ropper, I.F. Dunn, W.B. Gormley, Craniectomy-associated Progressive Extra-Axial Collections with Treated Hydrocephalus (CAPECTH): redefining a common complication of decompressive craniectomy, J. Clin. Neurosci. 19 (2012) 1222–1227.
[15] A.E. Ropper, S.V. Nalbach, N. Lin, I.F. Dunn, W.B. Gormley, Resolution of extra-axial collections after decompressive craniectomy for ischemic stroke, J. Clin. Neurosci. 19 (2012) 231–234.
[16] F.L. Stephens, C.M. Mossop, R.S. Bell, T. Tigno Jr., M.K. Rosner, A. Kumar, et al., Cranioplasty complications following wartime decompressive craniectomy, Neurosurg. Focus 28 (2010) E3.
[17] E. Munch, P. Horn, L. Schurer, A. Piepgras, T. Paul, P. Schmiedek, Management of severe traumatic brain injury by decompressive craniectomy, Neurosurgery 47 (2000) 315–322, discussion 322–313.
[18] S.I. Stiver, Complications of decompressive craniectomy for traumatic brain injury, Neurosurg. Focus 26 (2009) E7.
[19] M. Zanaty, N. Chalouhi, R.M. Starke, S.W. Clark, C.D. Bovenzi, M. Saigh, et al., Complications following cranioplasty: incidence and predictors in 348 cases, J. Neurosurg. 123 (2015) 182–188.
[20] R. Jabbarli, A.M. Bohrer, D. Pierscianek, D. Muller, K.H. Wrede, P. Dammann, et al., The CHESS score: a simple tool for early prediction of shunt dependency after aneurysmal subarachnoid hemorrhage, Eur. J. Neurol. 23 (2016) 912–918.
[21] C.C. Liao, M.C. Kao, Cranioplasty for patients with severe depressed skull bone defect after cerebrospinal fluid shunting, J. Clin. Neurosci. 9 (2002) 553–555.
[22] L. Mazzini, R. Campini, E. Angelino, F. Rognone, I. Pastore, G. Oliveri, Posttraumatic hydrocephalus: a clinical, neuroradiologic, and neuropsychologic assessment of long-term outcome, Arch. Phys. Med. Rehabil. 84 (2003) 1637–1641.
[23] A. Marmarou, M.A. Foda, K. Bandoh, M. Yoshihara, T. Yamamoto, O. Tsuji, et al., Posttraumatic ventriculomegaly: hydrocephalus or atrophy? A new approach for diagnosis using CSF dynamics, J. Neurosurg. 85 (1996) 1026–1035.
[24] E. Guresir, H. Vatter, P. Schuss, A. Oszvald, A. Raabe, V. Seifert, et al., Rapid closure technique in decompressive craniectomy, J. Neurosurg. 114 (2011) 954–960.
[25] S. Wagner, H. Schnippering, A. Aschoff, J.A. Koziol, S. Schwab, T. Steiner, Suboptimum hemicraniectomy as a cause of additional cerebral lesions in

patients with malignant infarction of the middle cerebral artery, J. Neurosurg. 94 (2001) 693–696.
[26] E.W. Ely, B. Truman, A. Shintani, J.W. Thomason, A.P. Wheeler, S. Gordon, et al., Monitoring sedation status over time in ICU patients: reliability and validity of the Richmond Agitation-Sedation Scale (RASS), JAMA 289 (2003) 2983–2991.
[27] C.N. Sessler, M.S. Gosnell, M.J. Grap, G.M. Brophy, P.V. O'Neal, K.A. Keane, et al., The Richmond Agitation-Sedation Scale: validity and reliability in adult intensive care unit patients, Am. J. Respir. Crit. Care Med. 166 (2002) 1338–1344.
[28] A. Yu, J. Teitelbaum, J. Scott, G. Gesin, B. Russell, T. Huynh, et al., Evaluating pain, sedation, and delirium in the neurologically critically ill-feasibility and reliability of standardized tools: a multi-institutional study, Crit. Care Med. 41 (2013) 2002–2007.
[29] K. Ashayeri, M.J. E, J. Huang, H. Brem, R.G. C, Syndrome of the trephined: a systematic review, Neurosurgery 79 (2016) 525–534.
[30] K. Ghandehari, Challenging comparison of stroke scales, J. Res. Med. Sci. 18 (2013) 906–910.
[31] L.K. Kwah, J. Diong, National Institutes of Health Stroke Scale (NIHSS), J. Physiother. 60 (2014) 61.
[32] S. Weingarten, R. Bolus, M.S. Riedinger, L. Maldonado, S. Stein, A.G. Ellrodt, The principle of parsimony: Glasgow Coma Scale score predicts mortality as well as the APACHE II score for stroke patients, Stroke 21 (1990) 1280–1282.
[33] X.F. Yang, L. Wen, F. Shen, G. Li, R. Lou, W.G. Liu, et al., Surgical complications secondary to decompressive craniectomy in patients with a head injury: a series of 108 consecutive cases, Acta Neurochir. (Wien) 150 (2008) 1241–1247, discussion 1248.
[34] I. Choi, H.K. Park, J.C. Chang, S.J. Cho, S.K. Choi, B.J. Byun, Clinical factors for the development of posttraumatic hydrocephalus after decompressive craniectomy, J. Korean Neurosurg. Soc. 43 (2008) 227–231.
[35] P. De Bonis, A. Pompucci, A. Mangiola, L. Rigante, C. Anile, Post-traumatic hydrocephalus after decompressive craniectomy: an underestimated risk factor, J. Neurotrauma 27 (2010) 1965–1970.
[36] G. Fotakopoulos, E. Tsianaka, G. Siasios, K. Vagkopoulos, K. Fountas, Posttraumatic hydrocephalus after decompressive craniectomy in 126 patients with severe traumatic brain injury, J. Neurol. Surg. A Cent. Eur. Neurosurg. (2015).
[37] A.V. Lorenzo, L.K. Page, G.V. Watters, Relationship between cerebrospinal fluid formation, absorption and pressure in human hydrocephalus, Brain 93 (1970) 679–692.
[38] G.V. Watters, L. Page, A.V. Lorenzo, R.W. Cutler, C.F. Barlow, Relationship between cerebrospinal fluid (CSF) formation, absorption and pressure in human hydrocephalus, Trans. Am. Neurol. Assoc. 94 (1969) 153–156.
[39] H. Williams, The venous hypothesis of hydrocephalus, Med. Hypotheses 70 (2008) 743–747.

Update

Clinical Neurology and Neurosurgery
Volume 181, Issue , June 2019, Page 138

DOI: https://doi.org/10.1016/j.clineuro.2019.04.003

Clinical Neurology and Neurosurgery 181 (2019) 138

Contents lists available at ScienceDirect

Clinical Neurology and Neurosurgery

journal homepage: www.elsevier.com/locate/clineuro

Corrigendum

Corrigendum to "Impact of timing of cranioplasty on hydrocephalus after decompressive hemicraniectomy in malignant middle cerebral artery infarction" [Clin. Neurol. Neurosurg. (2017) 27–34]

Tobias Finger[a,*], Vincent Prinz[a], Evelyn Schreck[a], Alexandra Pinczolits[a], Simon Bayerl[a], Thomas Liman[b], Johannes Woitzik[a], Peter Vajkoczy[a]

Department of Neurosurgery, Universitätsmedizin Charite, Berlin, Germany
Department of Neurology, Universitätsmedizin Charite, Berlin, Germany

The authors would like to make amendments to author contribution by indicating Authors Tobias Finger, Vincent Prinz contributed equally to this work.

Tobias Finger MD[a,1] and Vincent Prinz MD[a,1], Evelyn Schreck[a], Alexandra Pinczolits PhD[a], Simon Bayerl MD[a], Thomas Liman MD[b], Johannes Woitzik MD[a], Peter Vajkoczy MD[a]

[a]Department of Neurosurgery, Universitätsmedizin Charite, Berlin
[b]Department of Neurology, Universitätsmedizin Charite, Berlin
[1]Tobias Finger and Vincent Prinz contributed equally to this work.

The authors would like to apologise for any inconvenience caused.

DOI of original article: https://doi.org/10.1016/j.clineuro.2016.12.001
* Corresponding author.
E-mail address: tobias.finger@charite.de (T. Finger).

https://doi.org/10.1016/j.clineuro.2019.04.003

Available online 01 May 2019
1303-8467/ © 2019 Elsevier B.V. All rights reserved.