Check for updates

Effects of Cranioplasty on Contralateral Subdural Effusion After Decompressive Craniectomy: A Literature Review

Wu Zhou[1], Zhihua Wang[1], Huaxin Zhu[1], Zhiping Xie[1], Yeyu Zhao[1], Chengcai Li[1], Shenke Xie[1], Jilai Luo[1], Meihua Li[1], Jianguo Yao[2]

Key words
- Contralateral subdural effusion
- Cranioplasty
- Decompressive craniectomy
- Hydrocephalus

Abbreviations and Acronyms
CSE: Contralateral subdural effusion
CSEDC: Contralateral subdural effusion after decompressive craniectomy
CSF: Cerebral spinal fluid
DC: Decompressive craniectomy
ICP: Intracranial pressure
LP: Lumboperitoneal
SP: Subdural peritoneal
TBI: Traumatic brain injury
VP: Ventriculoperitoneal

From the [1]Department of Neurosurgery, The First Affiliated Hospital of Nanchang University, and [2]Jiangxi Academy of Medical Sciences, Nanchang, Jiangxi Province, China

To whom correspondence should be addressed: Meihua Li, M.D., Ph.D. [E-mail: limeihua2000@sina.com]

Wu Zhou and Zhihua Wang are co—first authors.

Citation: World Neurosurg. (2022) 165:147-153. https://doi.org/10.1016/j.wneu.2022.06.117

Journal homepage: www.journals.elsevier.com/world-neurosurgery

Available online: www.sciencedirect.com

1878-8750/$ - see front matter © 2022 Elsevier Inc. All rights reserved.

■ BACKGROUND: **Contralateral subdural effusion (CSE) after decompressive craniectomy (CSEDC) is occasionally observed. Cranioplasty is routinely performed for reconstruction and has recently been associated with improving contralateral subdural effusion. We sought to systematically review all available literature and evaluate the effectiveness of cranioplasty for CSE.**

■ METHODS: **A PubMed, Web of Science, and Google Scholar search was conducted for preferred reporting items following the guidelines of systematic review and meta-analysis, including studies reporting patients who underwent cranioplasty because of CSEDC.**

■ RESULTS: **The search yielded 8 articles. A total of 56 patients ranging in age from 21 to 71 years developed CSEDC. Of them, 32 patients underwent cranioplasty. Eighteen cases with symptomatic CSE underwent cranioplasty alone, 2 cases received Ommaya drainage later because of a recurrence of CDC, and 1 case underwent a ventriculoperitoneal shunt because the CSE did not resolve completely and the ventricle was dilated again. The symptoms of 14 cases lessened without recurrence after simultaneous cranioplasty and drainage or a shunt. The total success rate (CSE disappeared without recurrence) was 90.6% for patients who underwent cranioplasty; however, the total incidence of hydrocephalus was 40.1%.**

■ CONCLUSIONS: **This review suggests that cranioplasty is effective for the treatment of CSEDC, particularly intractable cases, but early cranioplasty may be more effective. In addition, hydrocephalus is fairly common after cranioplasty and requires further treatment.**

INTRODUCTION

Contralateral subdural effusion (CSE) is defined as a new subdural effusion (SE) on the opposite side of the decompressive craniectomy (DC) and has the same computed tomography density as cerebrospinal fluid (CSF).[1,2] Cases diagnosed with CSE after decompressive craniectomy (CSEDC) are rarely reported.[3-5] Although many theories have been proposed to explain the development of CSE, the pathogenesis by which it develops remains somewhat obscure. Most SE cases are asymptomatic and clinically silent.[6] A risk for delayed or missed diagnosis may exist for patients without obvious clinical symptoms or signs. Only patients with deteriorated clinical status undergo imaging examinations and are eventually diagnosed with CSE. Some researchers have suggested that more aggressive treatments are needed because CSE tends to cause a midline shift and neurologic deterioration.[7]

Cranioplasty is performed to reconstruct the skull and potentially prevent some complications. It has long been observed that cranioplasty often facilitates neurologic recovery after traumatic brain injury (TBI) by restoring intracranial pressure (ICP) dynamics and allowing increased rehabilitation activities.[8,9] Published reports describing the effects of cranioplasty on CSE are mostly in the form of case reports and small series (Figure 1). This systematic review evaluated the reported effects of cranioplasty on CSE and the associated changes in neurologic function.

METHODS

Study Selection

A PubMed, Web of Science, and Google Scholar search adherent to Preferred Reporting Items for Systematic Reviews and Meta-Analyses was performed for all articles containing the terms "cranioplasty" and "subdural effusion," or "subdural hygroma." No restrictions on the date of publication were made. Articles

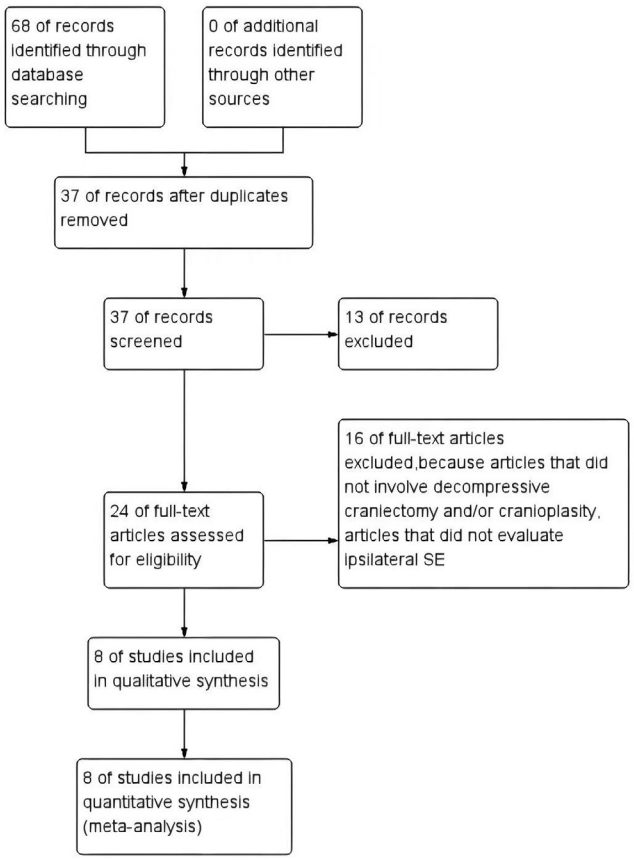

Figure 1. PRISMA flowchart illustrating the details of the literature search and review for studies describing the effect of cranioplasty on contralateral subdural effusion.

were limited to English and studies with human subjects. Eligible cases were extracted from the articles (case reports, case series, cohort studies, randomized controlled trials, systematic reviews, and meta-analyses). Two researchers (Wu Zhou and Zhihua Wang) independently reviewed the articles, and discrepancies were solved by consensus with the co-first authors. The references of the included studies were also reviewed to identify additional relevant studies.

After the initial list of studies was generated, the titles and abstracts were reviewed. Reviewers discussed and ensured consistency in the application of inclusion criteria before selecting a study. Studies were selected if they met the following criteria: 1) reports that contained cases with CSEDC; 2) reports that contained imaging examinations before and after cranioplasty; 3) reports that contained follow-up information after cranioplasty. A full-text review of all target literature was conducted following the title and abstract reviews. Studies and cases that did not meet the inclusion criteria were excluded.

Data Extraction

The detailed information included age, sex, the reason for DC, imaging examination before and after cranioplasty, results of clinical follow-up and prognosis, and time from DC to CSE. However, not all studies provided detailed information on each case. Therefore the comparative analysis was limited by the nature of the source data. Statistical analysis of this review was not performed because a comparative analysis was not available.

RESULTS

Study Selection

A total of 37 studies were returned after repeated searches, and 8 met the inclusion criteria. A flow chart of the screening process is illustrated in **Figure 1**. Relevant information is summarized in **Table 1**.

Patient Profile

Of the total of 56 patients (male = 41, female = 15) who developed CSEDC (age 21–71 years old), 32 cases underwent cranioplasty (**Tables 1–3**). All cases received DC surgery due to severe TBI or intracranial hypertension resulting from massive cerebral infarction; necessary imaging examination before and after cranioplasty was reported in all studies. The time suffering from CSEDC was also reported and ranged from 1 to 62 days.

As shown in **Tables 1–3**, 32 patients with symptomatic CSEDC underwent cranioplasty. The ratio of males to females was 3:1 (24/8). The ages of the participants ranged from 21 to 71 years, with an average age of 46 years. The average time interval from DC to the confirmed diagnosis of CSE was 22.1 days. Some CSE patients may recurred after conservative treatment or drainage and were further treated after cranioplasty with or without shunt, but some patients required additional cerebrospinal fluid shunt.

As shown in **Table 2**, 18 cases with symptomatic CSE accepted cranioplasty alone. Eight cases initially underwent trepanation and drainage or received a shunt to evacuate the SE. The operation had successfully drained the effusion of these patients in the end. However, the effusion quickly recurred, and complete resolution was achieved after cranioplasty. Nine cases received cranioplasty directly, and CSE disappeared without recurrence in 7 patients, while 2 cases received Ommaya drainage later because of recurrence. One case underwent burr-hole drainage and received a subdural-peritoneal (SP) shunt sequentially, which only temporarily improved the symptoms of the patient. Finally, cranioplasty was performed but the CSE did not resolve completely and the ventricle was dilated again. A ventriculoperitoneal (VP) shunt was ultimately implanted, and the CSE disappeared but the ventricle remained dilated. The

Table 1. Studies Relevant to Cranioplasty as Treatment for Contralateral Subdural Effusion (CSE)

Author, Year	Study Design	Male-to-Female	Age, Years	Primary Disease	Interval Time	Treatment and Outcome
Salunke et al. 2015[6]	Case series	6:1	Mean of 32.1 (range, 27—52)	Six traumatic brain injuries and one middle cerebral artery infarction and aneurysmal subarachnoid hemorrhage	Mean of 27.4 days (range, 5—62 days)	Five patients underwent burr hole drainage that failed after temporary improvements and then a cranioplasty was performed. Two patients received cranioplasty directly. CSE in the seven patients resolved eventually, but three patients subsequently developed hydrocephalus and ventriculoperitoneal shunt procedures were then performed.
Wang et al. 2020[10]	Case report	1:0	47	head injury	4w	A patient underwent both burr-hole drainage operation and an Ommaya reservoir operation, which failed after temporary improvements and then a cranioplasty was performed. The patient subsequently developed hydrocephalus and ventriculoperitoneal shunt procedures were then performed.
Kilincer et al. 2005[5]	Case report	1:0	56	Aneurismal subarachnoid hemorrhage and accompanying middle cerebral artery infarction	1w	Burr-hole drainage was used first but the CSE recurred. Complete resolution of the effusion was achieved through a cranioplasty and a subduroperitoneal shunt procedure.
Author, year	**Study Design**	**Male: Female**	**Age, years**	**Primary Disease**	**Interval Time**	**Treatment and Outcome**
Su et al. 2011[1]	Case series	11:2	Mean of 45.7 (range, 29—75)	Taumatic brain injury	13 days (range, 3—22 days)	Six patients were treated conservatively. Six patients received burr-hole craniectomy; four of which were successfully treated and the other two patients subsequently received a subduroperitoneal shunt. A subduroperitoneal shunt was placed and a cranioplasty were simultaneously performed on one patient.
Ling et al. 2021[11]	Case series	10:1	Mean of 45.7 (range, 25—63)	traumatic brain injury or massive cerebral infarction	15.9 days (range, 4—30 days)	Three patients were treated conservatively.One patient received burr hole drainage; two patients received VP shunt; one patient received cranioplasty. Four patients underwent cranioplasty plus shut placement. One patient underwent trepanation and drainage, Ommaya drainage and LP shunt successively, but three patients subsequently developed hydrocephalus.
Wu et al. 2019[12]	Case report	1:0	45	traumatic cerebral infarction after traumatic brain injury	1w	. Burr-hole drainage was firstly used but the CSE recurred. Then complete resolution of the effusion was achieved through a cranioplasty and subduroperitoneal shunt procedure.
Author, year	**Study Design**	**Male: Female**	**Age, years**	**Primary Disease**	**Interval Time**	**Treatment and Outcome**
Lin et al. 2015[2]	Case series	6:3	Mean of 46.2 (range, 31—71)	TBI	20.9days (range,15—26 days)	Nine patients underwent simultaneous cranioplasty and recrived contralateral subdural - peritoneal shunt. All of the patients showed completely resolved CSE and reversed midline shifts, but three patients subsequently developed hydrocephalus and ventriculoperitoneal shunt procedures were then performed.
Wan et al. 2016[13]	Retrospective cohort	7:6	Mean of 32.1 (range, 21—35)	TBI	N.A	Six patients who underwent temporal muscle sticking were successfully resolved. Seven patients underwent early cranioplasty, the effusions of 5 patients gradually disappeared after cranioplasty, and the effusions of the other 2 patients also completely disappeared after an additional contralateral Ommaya drainage placement.

Table 2. Cranioplasty for Symptomatic Cases of Contralateral Subdural Effusion After Decompressive Craniectomy

Case	Author/Reference	Sex	Age (years)	Interval Time (days)	Therapy	Hydrocephalus
1	Salunke et al.[6]	M	52	5	Burr hole drainage; cranioplasty	NO
2	Salunke et al.[6]	M	35	15	Burr hole drainage; cranioplasty	YES
3	Salunke et al.[6]	M	43	18	Burr hole drainage; cranioplasty	YES
4	Salunke et al.[6]	M	45	17	Burr hole drainage; cranioplasty	NO
5	Salunke et al.[6]	M	30	62	Burr hole drainage; cranioplasty	YES
6	Salunke et al.[6]	M	27	30	Cranioplasty	NO
7	Salunke et al.[6]	F	48	45	Cranioplasty	NO
8	Wang et al.[3]	M	47	28	Ommaya reservoir; cranioplasty	YES
9	Kilincer et al.[13]	M	56	7	Burr hole drainage; cranioplasty & SP	NO
10	Su et al.[1]	M	34	14	Cranioplasty & SP	YES
11	Ling et al.[14]	M	63	4	Cranioplasty	YES
12	Ling et al.[14]	M	57	19	LP & cranioplasty	NO
13	Ling et al.[14]	M	36	30	LP & cranioplasty	YES
14	Ling et al.[14]	M	25	9	Burr hole drainage & cranioplasty & VP	YES
15	Ling et al.[14]	M	41	17	Cranioplasty & VP	YES
16	Wu et al.[15]	M	45	1	Burr hole drainage; SP; cranioplasty; VP	YES

Interval, interval time between decompressive craniectomy and contralateral subdural effusion; M, male; F, female; LP, lumboperitoneal shunting; VP, ventriculoperitoneal shunting; SP, subduroperitoneal shunting.

incidence of hydrocephalus after cranioplasty was 38.9% (7/18), so further shunt implantation might be necessary.

Fourteen cases with symptomatic CSE improved after simultaneous cranioplasty and burr hole drainage, an implantation of an SP shunt, a VP shunt, an Ommaya reservoir, or a lumboperitoneal (LP) shunt. Thirteen cases were treated with cranioplasty and a shunt (10 SP, 1 VP and 2 LP), and their effusion resolved completely. One case was treated with burr hole drainage first; however, the effusion recurred. Satisfactory results were achieved after simultaneous accomplishment of burr hole drainage, cranioplasty, and placement of a VP shunt. In short, these 14 cases who underwent cranioplasty plus burr hole drainage or shunt implantation almost completely resolved without recurrence. However, the incidence of hydrocephalus after surgery was 42.9% (6/14).

As shown in **Table 4**, the total success rate (CSE disappeared without recurrence) was 90.6%. The success rate of simultaneous cranioplasty and shunt placement was 100%, which was higher than cranioplasty alone (83.3%). However, the total incidence of hydrocephalus was 40.1%; the incidence of hydrocephalus after simultaneous cranioplasty and shunt placement was 42.9%, slightly higher than cranioplasty alone (38.9%).

DISCUSSION

Extensive DC is indicated for treating elevated ICP or diffuse brain edema due to severe TBI and ischemic or hemorrhagic stroke.[16-18] However, SE is a well-known complication of DC.[7] SE is defined as an acute or chronic accumulation of CSF in the subdural space, with an often changing composition.[19] Most SEs are on the same side of the DC. They are often asymptomatic and resolve spontaneously. This situation can mask the clinical manifestations and delay SE diagnosis. However, patients without SE had significantly better outcomes compared with those who developed SE after DC according to the Glasgow Outcome Scale. In addition, among the multiple factors in meta-analyses, only basal cistern involvement as viewed via computed tomography was associated with the development of SE after DC.[20] Although SE is a common complication after DC, CSEDC is rare and more likely to be symptomatic.[6] Due to the rarity of the data, it remains unclear how to best manage the CSE cases.

Mechanism Underlying Contralateral Subdural Effusion After Decompressive Craniectomy

The natural history of SE following DC remains unclear. The average time from the DC procedure to the onset of CSE was about 22 days. However, the mechanism by which CSE develops is unclear. Several possible mechanisms are responsible for the development of CSEDC. Tearing or disruption of the arachnoid layer may result in formation of a 1-way flap valve that promotes CSF leakage and accumulation in the subdural space by shear stress during the trauma or surgery. A disturbance in CSF circulation, particularly an absorption problem, would also increase the risk for the effusion accumulating through the torn arachnoid layer.[5,21] CSE

Table 3. Cranioplasty for Symptomatic Cases of Contralateral Subdural Effusion After Decompressive Craniectomy

Case Series	Author Reference	Included Patients	Mean Age (years)	Interval Time (days)	Therapy	Outcome
1	Lin et al.[2]	9 (M = 6, F = 3)	Mean of 46.2 (range, 31–71)	20.9 (range, 15–26)	Cranioplasty & SP	CSE completely resolved; Hydrocephalus (2 cases), VP
2	Wan et al.[12]	7 (M = 3, F = 4)	Mean of 28.3	NA	Cranioplasty; Ommaya drainage (2 cases)	CSE completely resolved; No hydrocephalus

M, male; F, Female; SP, subduroperitoneal shunting; CSE, contralateral subdural effusion; VP, ventriculoperitoneal shunting; NA, not available.

rarely occurs after DC in stroke patients,[22] suggesting the need for initial arachnoid rupture caused by trauma. A rapid reduction in ICP and outward cerebral herniation after decompression may produce a pressure gradient between the 2 hemispheres, which enlarges the contralateral subdural space and accumulates effusion, particularly when a possible rupture exists in the arachnoid layer after initial brain trauma.[4,5,23] In our experience, the more obvious the brain shift after DC, the more likely the contralateral subdural effusion. In addition, it has been proposed that shrinkage of the ipsilateral brain results from tissue retraction. A rapid decrease in ICP during the DC would also cause a pressure gradient between the 2 hemispheres and a brain shift, which would finally lead to enlargement of the contralateral subdural space and accumulation of SE.[5,13]

Treatment and Prognosis of Contralateral Subdural Effusion

The optimal treatment for SE has not been determined. Conservative treatment is recommended for asymptomatic SE. The majority of SE cases disappear gradually without surgical intervention. However, CSE may need more active treatment because of the tendency to cause a midline shift and/or neurologic deterioration. If the volume of the CSE and ICP gradually increases and causes a shift in the midline, appropriate surgery should be performed as soon as possible. Surgical options for symptomatic SE include Ommaya catheter drainage; cranioplasty; a temporal muscle sticking operation; placement of an SP, VP, or LP shunt; or a combination of these.[1-7,10,12,13,15,24] Burr hole drainage is considered as a simple procedure for SE. However, a craniotomy defect and a possible resistance gradient between hemispheres may cause the CSE to recur, indicating the resistance of burr hole drainage.[6] The advantage of Ommaya catheter drainage compared with traditional burr hole drainage is that a repeated puncture can be performed for continuous drainage. However, recurrence of CSE cannot be avoided.[24] Treating with a craniotomy for temporal muscle sticking is satisfactory, and intractable CSEs can be completely absorbed. However, the disadvantages of this surgery are that it requires at least 1 operation, a longer hospital stay, and higher medical costs.[24]

Cranioplasty has been reported as a new method for treating CSE. Some patients resolve after cranioplasty, but others require an additional shunt or drainage (Table 2). Wan et al[12] suggested that cranioplasty restores the dicrotic ICP waveform, helping to promote absorption of the CSE. Salunke et al[6] indicated that cranioplasty prevents the formation of CSE while conservative or burr hole drainage does not. The pressure gradient following DC is the main cause of development of CSE; cranioplasty restores the normal physiologic structure and stable state of the skull. Therefore the compliance and pressure-volume curve of brain tissue tend to be normal, thereby eliminating the pathologic basis of imbalance in ICP and promoting the reabsorption of fluid accumulation. Salunke et al[6] suggested that cranioplasty is recommended as the cornerstone for treating CSE. Several studies have reported good results with simultaneous cranioplasty and drainage or shunt placement for CSE.[1,2,14,22] Because of the potential failure of a shunt or drainage for CSE, cranioplasty can be performed at the same time, which solves the problem of outward protrusion, and the pressure gradient created by the cranioplasty contributes to the effect of the shunt or drainage on the SE. Drainage or shunt placement plus cranioplasty completely resolves SE aggregation and may promote narrowing and adhesion in the subdural and subarachnoid spaces, resulting in deterioration of CSF circulation and hydrocephalus.[14] Shunt placement plus cranioplasty as the recommended surgical procedure is applied to patients with acutely impaired consciousness or remarked neurologic deficits caused by extracerebral injury from CSE.[2]

However, how does one determine the best time for cranioplasty? The time for cranioplasty after DC has been critically discussed.[11,25] Cranioplasty (3–6 months after DC) does not seem to lower the postcranioplasty infection rate or the need

Table 4. Comparison of Cranioplasty Solely and Simultaneous Cranioplasty and Shunting

	Cranioplasty Solely	SCDS	Total
Number	17	15	32
Success rate (%)	83.3 (15/18)	100 (14/14)	90.6 (29/32)
Incidence of hydrocephalus (%)	38.9 (7/18)	42.9 (6/14)	40.1 (13/32)

SCDS, simultaneous cranioplasty and drainage or shunt.

to divert CSF.[25] Waziri indicated that delayed cranioplasty treatment is associated with the development of persistent hydrocephalus, requiring permanent diversion of the CSF.[26] By contrast, an early cranioplasty could effectively improve neurologic recovery, mainly due to the increased cerebral blood flow after the procedure.[27] Meanwhile, Salunke et al[6] and Wan et al[12] also demonstrated that early cranioplasty prevents the formation of CSE. Beauchamp et al[25] suggested that cranioplasty should be performed whenever an imaging examination shows reduced brain swelling. Therefore cranioplasty after DC as long as the swelling subsides may improve patient's neurologic symptoms and avoid some complications including CSE. Nevertheless, it is important to note that after cranioplasty, some patients may develop hydrocephalus after their CSE has resolved and further shunt implantation might be required.

Limitations

The majority of the literature consists of small case reports and series and thus limiting the description of the types of SE studies, general findings related to cranioplasty, and the range of clinical outcomes. Such case reports and series are inherently subject to reporting and selection biases. Although most current literature suggests that cranioplasty is effective for treating CSE, these changes may be related to a variety of factors and the cause cannot be assumed. Meta-analyses are not feasible due to the limited number of eligible studies and their variability. Ultimately, only a qualitative rather than quantitative assessment of these studies can be performed.

CONCLUSION

CSE may be a common complication after DC; however, most patients are asymptomatic and thus are unacknowledged or the clinical symptoms are masked for some reason, resulting in a missed diagnosis. This review also confirms that cranioplasty after DC is effective for treating CSE, particularly intractable cases, and early cranioplasty may be more effective. In addition, hydrocephalus is common after cranioplasty and requires further treatment. Although it is widely accepted that cranioplasty is a treatment for CSE, randomized controlled trials and other prospective cohort studies are necessary to determine the best time for cranioplasty.

CRediT AUTHORSHIP CONTRIBUTION STATEMENT

Wu Zhou: Conceptualization, Software, Writing — original draft. **Zhihua Wang:** Methodology, Writing — original draft. **Huaxin Zhu:** Validation. **Zhiping Xie:** Visualization, Validation. **Yeyu Zhao:** Investigation. **Chengcai Li:** Data curation. **Shenke Xie:** Visualization. **Jilai Luo:** Investigation. **Meihua Li:** Supervision, Writing — review & editing. **Jianguo Yao:** Supervision, Writing — review & editing.

REFERENCES

1. Su TM, Lee TH, Huang YH, Su FW, Chen WF. Contralateral subdural effusion after decompressive craniectomy in patients with severe traumatic brain injury: clinical features and outcome. *J Trauma*. 2011;71:833-837.

2. Lin MS, Chen TH, Kung WM, Chen ST. Simultaneous cranioplasty and subdural-peritoneal shunting for contralateral symptomatic subdural hygroma following decompressive craniectomy. *Sci World J*. 2015;2015:518494.

3. Wang HK, Lu K, Liang CL, Tsai YD, Wang KW, Liliang PC. Contralateral subdural effusion related to decompressive craniectomy performed in patients with severe traumatic brain injury. *Injury*. 2012;43:594-597.

4. Yang XF, Wen L, Li G, Zhan RY, Ma L, Liu WG. Contralateral subdural effusion secondary to decompressive craniectomy performed in patients with severe traumatic brain injury: incidence, clinical presentations, treatment and outcome. *Med Princ Pract*. 2009;18:16-20.

5. Su FW, Ho JT, Wang HC. Acute contralateral subdural hygroma following craniectomy. *J Clin Neurosci*. 2008;15:305-307.

6. Salunke P, Garg R, Kapoor A, Chhabra R, Mukherjee KK. Symptomatic contralateral subdural hygromas after decompressive craniectomy: plausible causes and management protocols. *J Neurosurg*. 2015;122:602-609.

7. Aarabi B, Chesler D, Maulucci C, Blacklock T, Alexander M. Dynamics of subdural hygroma following decompressive craniectomy: a comparative study. *Neurosurg Focus*. 2009;26:E8.

8. Corallo F, Lo BV, Calabro RS, De Cola MC. Can cranioplasty be considered a tool to improve cognitive recovery following traumatic brain injury? A 5-years retrospective study. *J Clin Med*. 2021:10.

9. Iaccarino C, Kolias AG, Roumy LG, Fountas K, Adeleye AO. Cranioplasty following decompressive craniectomy. *Front Neurol*. 2019;10:1357.

10. Krishnan P, Roy CS. Recurrent, symptomatic, late-onset, contralateral subdural effusion following decompressive craniectomy treated by cranial strapping. *Br J Neurosurg*. 2015;29:730-732.

11. Piedra MP, Nemecek AN, Ragel BT. Timing of cranioplasty after decompressive craniectomy for trauma. *Surg Neurol Int*. 2014;5:25.

12. Wan Y, Shi L, Wang Z, et al. Effective treatment via early cranioplasty for intractable contralateral subdural effusion after standard decompressive craniectomy in patients with severe traumatic brain injury. *Clin Neurol Neurosurg*. 2016;149:87-93.

13. Kilincer C, Simsek O, Hamamcioglu MK, Hicdonmez T, Cobanoglu S. Contralateral subdural effusion after aneurysm surgery and decompressive craniectomy: case report and review of the literature. *Clin Neurol Neurosurg*. 2005;107:412-416.

14. Ling H, Yang L, Huang Z, et al. Contralateral subdural effusion after decompressive craniectomy: what is the optimal treatment? *Clin Neurol Neurosurg*. 2021;210:106950.

15. Wu R, Ye Y, Ma T, Jia G, Qin H. Management of subdural effusion and hydrocephalus following decompressive craniectomy for posttraumatic cerebral infarction in a patient with traumatic brain injury: a case report. *BMC Surg*. 2019;19:26.

16. Hutchinson PJ, Kolias AG, Timofeev IS, et al. Trial of decompressive craniectomy for traumatic intracranial hypertension. *N Engl J Med*. 2016;375:1119-1130.

17. Beez T, Munoz-Bendix C, Steiger HJ, Beseoglu K. Decompressive craniectomy for acute ischemic stroke. *Crit Care*. 2019;23:209.

18. Brown DA, Wijdicks EF. Decompressive craniectomy in acute brain injury. *Handb Clin Neurol*. 2017;140:299-318.

19. Kristof RA, Grimm JM, Stoffel-Wagner B. Cerebrospinal fluid leakage into the subdural space: possible influence on the pathogenesis and recurrence frequency of chronic subdural hematoma and subdural hygroma. *J Neurosurg*. 2008;108:275-280.

20. Signorelli F, Ioannoni E, Olivi A, Montano N. Factors involved in the development of subdural hygroma after decompressive craniectomy for traumatic brain injury. A systematic review and meta-analysis. *J Clin Neurosci*. 2020;78:273-276.

21. Yang XJ, Hong GL, Su SB, Yang SY. Complications induced by decompressive craniectomies after traumatic brain injury. *Chin J Traumatol*. 2003;6:99-103.

22. Kilincer C, Hamamcioglu MK. Contralateral subdural effusion secondary to decompressive craniectomy: differences in patients with large hemispheric infarctions and traumatic brain injury. *Med Princ Pract*. 2010;19:499, 500.

23. Paredes I, Cicuendez M, Delgado MA, Martinez-Perez R, Munarriz PM, Lagares A. Normal

pressure subdural hygroma with mass effect as a complication of decompressive craniectomy. *Surg Neurol Int*. 2011;2:88.

24. Wang H, Chen F, Wen L, Zhu Y, Chen Z, Yang X. Cranioplasty as the treatment for contralateral subdural effusion secondary to decompressive craniectomy: a case report and review of the relevant literature. *J Int Med Res*. 2020;48: 1220766442.

25. Beauchamp KM, Kashuk J, Moore EE, et al. Cranioplasty after postinjury decompressive craniectomy: is timing of the essence? *J Trauma*. 2010;69: 270-274.

26. Waziri A, Fusco D, Mayer SA, McKhann GM 2nd, Connolly ES Jr. Postoperative hydrocephalus in patients undergoing decompressive hemicraniectomy for ischemic or hemorrhagic stroke. *Neurosurgery*. 2007.

27. Song J, Liu M, Mo X, Du H, Huang H, Xu GZ. Beneficial impact of early cranioplasty in patients with decompressive craniectomy: evidence from transcranial Doppler ultrasonography. *Acta Neurochir (Wien)*. 2014;156:193-198.

Conflict of interest statement: This work was supported by the National Natural Science Foundation of China (grant 81860225).

Received 19 January 2022; accepted 22 June 2022

Citation: World Neurosurg. (2022) 165:147-153.
https://doi.org/10.1016/j.wneu.2022.06.117

Journal homepage: ***www.journals.elsevier.com/world-neurosurgery***

Available online: ***www.sciencedirect.com***

1878-8750/$ - see front matter © 2022 Elsevier Inc. All rights reserved.