KNEE RADIOLOGICAL REPORT

Report Date:	November 25, 2025	Report ID:	KOA-20251125-50
Patient ID:	test	Age/Sex:	20/N/A
DIAGNOSIS:			

Disclaimer:

This report was generated with the assistance of artificial intelligence. While AI enhances report accuracy and efficiency, the final interpretation and responsibility for the clinical application of these findings remain with the interpreting radiologist. The AI analysis serves as a supportive tool and does not replace the expertise and judgment of a qualified physician.

Clinical History:

The patient is a 20-year-old presenting with a history of mild knee pain following a recent sports injury. The indication for this examination is to evaluate for any acute osseous abnormalities or early signs of joint pathology.

Technique:

Anteroposterior (AP), lateral, and skyline (patellar) radiographic views of the right knee were obtained. The images were subsequently analyzed using an artificial intelligence (AI) algorithm for assessment of osteoarthritis. AI Classification Confidence: 84.8%. Kellgren-Lawrence Grading System Applied.

Findings:

RADIOLOGY REPORT

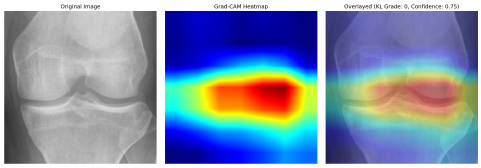

Impression:

No radiographic evidence of osteoarthritis is identified. The knee joint appears normal based on the Kellgren-Lawrence grading system (Grade 0).

Recommendations:

Given the absence of radiographic abnormalities and the patient's history of recent injury, conservative management is recommended. This includes rest, ice, compression, and elevation (RICE protocol) along with over-the-counter analgesics as needed for pain relief.

Risk Profile:

The risk of developing osteoarthritis is low in the absence of current radiographic findings. However, factors such as repetitive joint loading, previous knee injuries (e.g., ligament tears), family history of osteoarthritis, and obesity could potentially increase the risk over time. Maintaining a healthy weight, engaging in regular low-impact exercise, and avoiding activities that place excessive stress on the knee joint can help minimize future risk. Long-term outlook is generally favorable with appropriate preventative measures.

Essential Precautions:

The following precautions are advised to maintain knee health:

• Activity Modification: Avoid high-impact activities that cause persistent pain or swelling in the knee.

• Proper Warm-up: Always warm up before engaging in physical activity to prepare the muscles and joints.

• Weight Management: Maintain a healthy body weight to reduce stress on the knee joint.

• Early Intervention: Seek medical attention if you experience persistent or worsening knee pain, swelling, or stiffness.

• Strengthening Exercises: Focus on strengthening the muscles around the knee (quadriceps, hamstrings) to provide support and stability.

Treatment Options:

Given the absence of radiographic osteoarthritis, the treatment approach focuses on prevention and symptomatic relief.

• Conservative Management: Rest, ice, compression, and elevation (RICE) for acute pain.

• Over-the-Counter Analgesics: Acetaminophen or NSAIDs (ibuprofen, naproxen) for pain relief.

• Physical Therapy: A tailored exercise program to improve range of motion, strength, and stability.

• Weight Management: Maintaining a healthy weight to reduce stress on the knee joint.

• Bracing: Consider a knee brace during high-impact activities to provide additional support and stability, especially if there is a history of injury.

• Intra-articular Injections: While not typically indicated for Grade 0, hyaluronic acid or corticosteroid injections may be considered in the future if symptoms progress despite conservative measures.

Follow-Up And Monitoring:

Routine follow-up is not necessary in the absence of persistent or worsening symptoms. If the patient experiences recurrent or worsening knee pain, a repeat clinical evaluation and further imaging may be warranted. Advise the patient to continue with preventative measures and maintain a healthy lifestyle. Expected outcomes are excellent with continued adherence to recommended precautions and management strategies.