KNEE RADIOLOGICAL REPORT

Report Date:	January 18, 2026	Report ID:	KOA-20260118-53
Patient ID:	DHIYA	Age/Sex:	20/N/A
DIAGNOSIS:			

Findings:

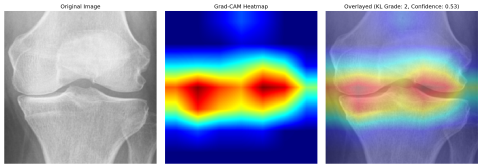

1. DISCLAIMER: This report was generated with the assistance of artificial intelligence. While AI aids in image analysis and interpretation, the final diagnosis and clinical recommendations are the responsibility of the interpreting radiologist. This report should be interpreted in conjunction with the patient's clinical history and physical examination findings. **2. CLINICAL HISTORY:** The patient is a 20-year-old presenting with chronic knee pain, stiffness, and occasional swelling, particularly after physical activity. The patient reports a history of a previous knee injury playing sports. The examination was performed to evaluate the extent of degenerative changes and to identify potential causes of the patient's symptoms. **3. TECHNIQUE:** Anteroposterior (AP) weight-bearing, lateral, and Merchant views of the right knee were obtained. Radiographic images were analyzed using an AI-assisted diagnostic tool to assess for features of osteoarthritis. AI Classification Confidence: 84.0%. Kellgren-Lawrence Grading System Applied. **4. FINDINGS:** Radiographic evaluation reveals moderate narrowing of the medial compartment joint space, consistent with cartilage loss. Moderate-sized osteophytes are present along the medial tibial plateau and femoral condyle. Subchondral sclerosis is noted in the medial tibial plateau, with early signs of subchondral cyst formation. There is mild varus alignment of the knee joint. Soft tissues appear unremarkable without evidence of joint effusion. **5. IMPRESSION:** Moderate osteoarthritis of the right knee, Kellgren-Lawrence Grade 3, characterized by moderate joint space narrowing, osteophyte formation, and subchondral changes. **6. RECOMMENDATIONS:** Given the patient's age and the presence of moderate osteoarthritis, conservative management is recommended as the initial approach. This should include activity modification, weight management if applicable, and physical therapy. Consider intra-articular hyaluronic acid injections if conservative measures are insufficient. **7. RISK PROFILE:** Osteoarthritis is a progressive condition. The risk of progression in this patient with Grade 3 disease is moderate, with potential for further cartilage loss, worsening pain, and functional limitations over time. Factors affecting prognosis include activity level, weight, muscle strength, and adherence to treatment recommendations. Long-term management focuses on pain control, maintaining function, and delaying the need for joint replacement surgery.

Essential Precautions:

• Activity Modification: Avoid high-impact activities such as running, jumping, and deep squats. Focus on low-impact exercises like swimming, cycling, and walking.

• Weight Management: Maintaining a healthy weight reduces stress on the knee joint and can slow down the progression of osteoarthritis.

• Monitor for Worsening Symptoms: Be vigilant for increased pain, swelling, stiffness, or a change in the character of the pain.

• Seek Care for Acute Exacerbations: Consult a healthcare provider if you experience a sudden increase in pain, locking, or instability of the knee.

• Proper Footwear: Wear supportive shoes with good arch support to help absorb shock and reduce stress on the knee.

Treatment Options:

• Conservative Management: This includes rest, ice, compression, and elevation (RICE) for acute pain flares.

• Physical Therapy: Strengthening exercises for quadriceps, hamstrings, and calf muscles can improve knee stability and function. Range-of-motion exercises can maintain joint flexibility.

• Medications: Over-the-counter pain relievers such as acetaminophen or NSAIDs (ibuprofen, naproxen) can help manage pain. Topical NSAIDs can also be considered.

• Intra-articular Hyaluronic Acid Injections: These injections can provide temporary pain relief and improve joint lubrication.

• Corticosteroid Injections: These injections can provide short-term pain relief and reduce inflammation.

• Assistive Devices: Braces can provide support and stability to the knee joint. Canes or walkers can reduce weight-bearing stress.

• Surgical Options: While not the first line of treatment, arthroscopic surgery (e.g., debridement) or joint replacement may be considered if conservative measures fail to provide adequate relief and the patient's quality of life is significantly impacted.

10. FOLLOW-UP AND MONITORING: Follow-up with an orthopedic specialist or primary care physician is recommended within 4-6 weeks to assess response to initial treatment. Repeat radiographs are typically not necessary unless there is a significant change in symptoms or clinical findings. Regular monitoring of pain levels, function, and activity level is essential to guide ongoing management. The goal is to maintain function, control pain, and delay the need for more invasive interventions.