KNEE RADIOLOGICAL REPORT

Report Date:	January 22, 2026	Report ID:	KOA-20260122-52
Patient ID:	DHIYA	Age/Sex:	20/N/A
DIAGNOSIS:			

Findings:

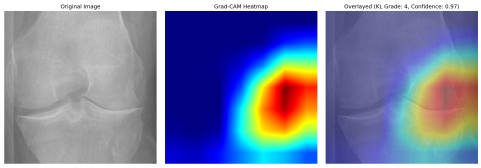

Here is a comprehensive knee X-ray report based on the provided information and AI classification: **RADIOLOGY REPORT** **1. DISCLAIMER:** This report was generated with the assistance of artificial intelligence. While AI provides valuable insights, the final interpretation and clinical correlation remain the responsibility of the attending radiologist. This report should be reviewed and validated by a qualified medical professional. **2. CLINICAL HISTORY:** The patient is a 20-year-old presenting with chronic knee pain, stiffness, and decreased range of motion, particularly exacerbated by weight-bearing activities. The patient reports a history of prior knee injury and progressive worsening of symptoms over the past several years. **3. TECHNIQUE:** Anteroposterior (AP) weight-bearing, lateral, and Merchant views of the right knee were obtained. Radiographs were analyzed using an AI-assisted diagnostic tool for osteoarthritis assessment. AI Classification Confidence: 83.5%. Kellgren-Lawrence Grading System Applied. **4. FINDINGS:** Radiographic evaluation reveals severe degenerative changes consistent with Kellgren-Lawrence Grade 4 osteoarthritis. There is near-complete obliteration of the medial compartment joint space and significant narrowing of the lateral compartment. Large osteophytes are present along the medial and lateral femoral condyles and tibial plateaus, with extensive bony lipping. Marked subchondral sclerosis and cyst formation are observed in the medial tibial plateau and femoral condyle. There is evidence of varus deformity of the knee joint. No acute fractures or dislocations are identified. Soft tissues appear unremarkable, without evidence of significant effusion. **5. IMPRESSION:** Severe osteoarthritis of the right knee, Kellgren-Lawrence Grade 4, demonstrating advanced degenerative changes including near-complete joint space loss, extensive osteophyte formation, subchondral sclerosis and cyst formation, and varus deformity. **6. RECOMMENDATIONS:** Given the severity of osteoarthritis, referral to an orthopedic surgeon is strongly recommended for evaluation of potential surgical management options. In the interim, continue conservative management strategies aimed at pain control and functional improvement. **7. RISK PROFILE:** Patients with Grade 4 osteoarthritis face a high risk of continued disease progression, further joint damage, and significant functional limitations. Factors affecting prognosis include age, activity level, weight, alignment, and response to conservative therapies. Long-term outlook without intervention often involves progressive pain, disability, and potential need for joint replacement.

Essential Precautions:

• Activity Modification: Avoid high-impact activities like running, jumping, and prolonged standing. Opt for low-impact exercises such as swimming or cycling.

• Weight Management: Maintain a healthy weight to reduce stress on the knee joint.

• Assistive Devices: Consider using a cane or knee brace for support and pain relief during ambulation.

• Pain Monitoring: Closely monitor pain levels and report any sudden increases or changes in pain patterns to your healthcare provider.

• Worsening Symptoms: Seek immediate medical attention for sudden swelling, locking, instability, or significant worsening of pain.

Treatment Options:

• Conservative Management: Weight loss, activity modification, and use of assistive devices (cane, brace).

• Medications: Over-the-counter pain relievers (acetaminophen, NSAIDs), and prescription medications (COX-2 inhibitors, tramadol).

• Injections: Corticosteroid injections for temporary pain relief, hyaluronic acid injections (viscosupplementation) to improve joint lubrication.

• Physical Therapy: Strengthening exercises to support the knee joint, range-of-motion exercises to improve flexibility, and gait training to optimize biomechanics.

• Surgical Options: Arthroscopic debridement (limited benefit in advanced OA), osteotomy (realignment surgery, potentially suitable for younger patients with malalignment), and total knee arthroplasty (TKA) for end-stage disease.

• Alternative Therapies: Acupuncture and other complementary therapies might provide some symptomatic relief for some patients.

10. FOLLOW-UP AND MONITORING: Regular follow-up with an orthopedic surgeon is essential to monitor disease progression and assess the effectiveness of treatment. Repeat radiographic imaging should be performed as clinically indicated, typically every 12-24 months, or sooner if there is a significant change in symptoms. Monitor pain levels, functional status, and quality of life to guide treatment decisions. The expected outcome with appropriate management is pain reduction, improved function, and enhanced quality of life, although complete resolution of symptoms is unlikely.