Name:

Age:

Gender:

HR : 208 bpm
PR : 166 ms
QRS : 91 ms
RR : 288 ms
QT : 363 ms
QTc : 363 ms

P/QRS/T : -153/36/44°
RV5/SV1 : 0.672 mV/-0.506 mV
RV5+SV1 : 1.178 mV
RV6/SV2 : 0.794 mV/0.874 mV
QTcF : 363 ms
25.0 mm/s 0.5-150Hz AC : 50Hz 10.0 mm/mV

DECK MOUNT

Date: 2026-03-13
Time: 14:55:54
Org:
Phone No:

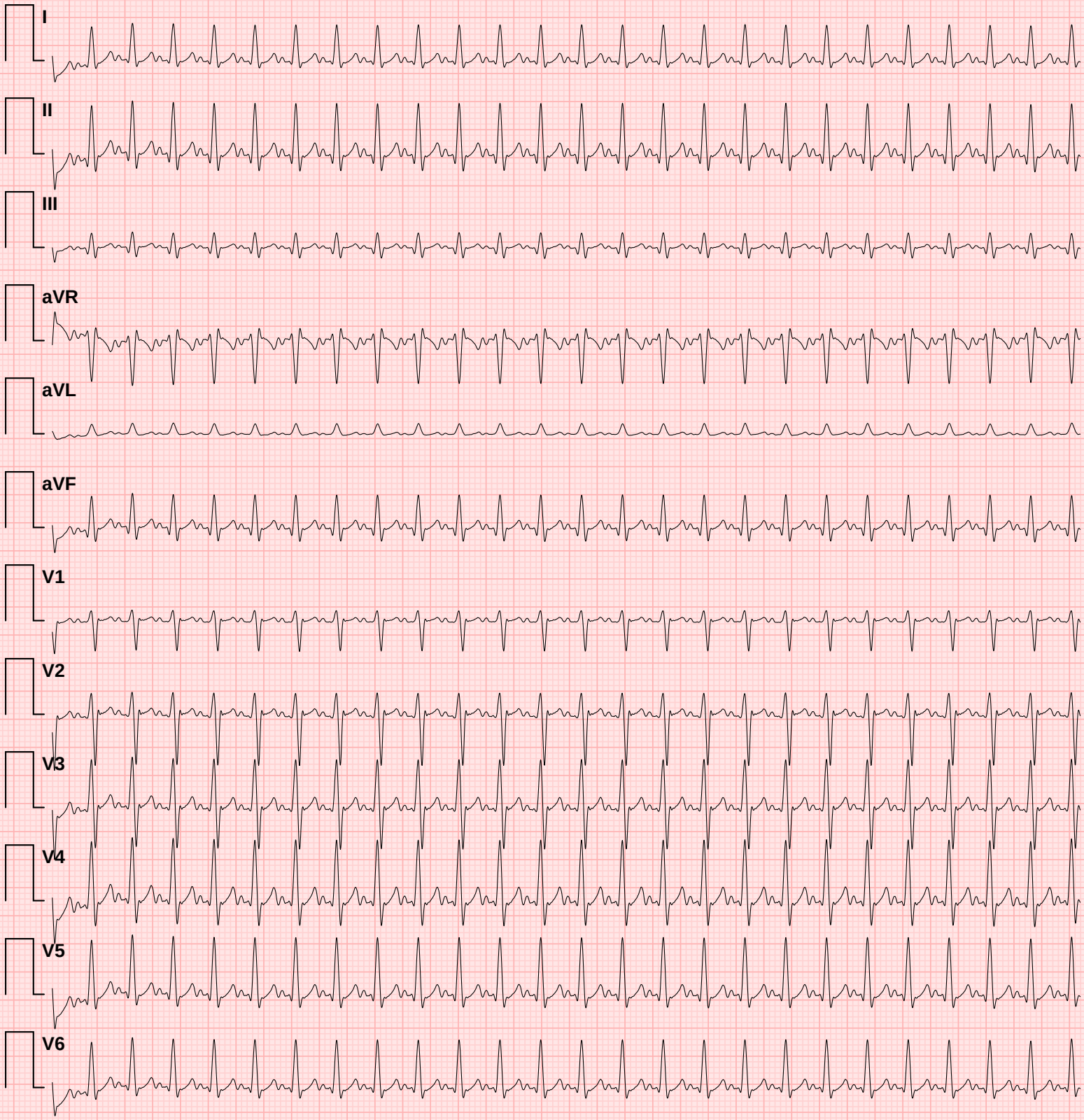

Doctor Name:

Doctor Sign:

✦ CONCLUSION ✦

1. Extreme Tachycardia
2. Short PR interval
3. Normal QRS duration
4. Normal QTc interval
5. Low HRV