Name:

Age:

Gender:

HR : 208 bpm
PR : 82 ms
QRS : 86 ms
RR : 288 ms
QT : 206 ms
QTc : 383 ms

P/QRS/T : -150/37/46°
RV5/SV1 : 0.671 mV/-0.502 mV
RV5+SV1 : 1.173 mV
RV6/SV2 : 0.796 mV/0.875 mV
QTcF : 312 ms
25.0 mm/s 0.5-150Hz AC : 50Hz 10.0 mm/mV

DECK MOUNT

Date: 2026-03-13
Time: 14:56:15
Org:
Phone No:

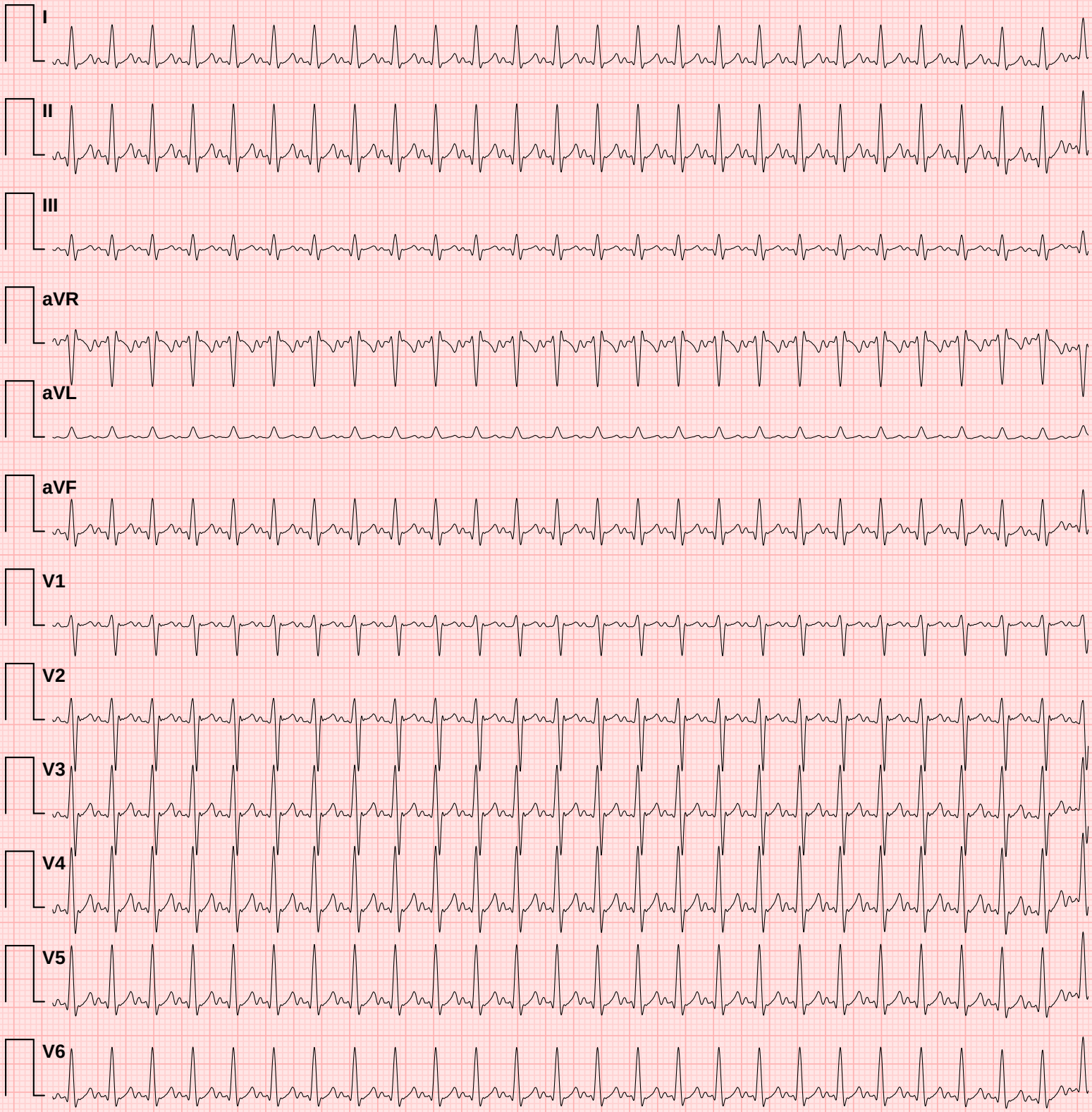

Doctor Name:

Doctor Sign:

✦ CONCLUSION ✦

1. Extreme Tachycardia
2. Short PR interval
3. Normal QRS duration
4. Normal QTc interval
5. Low HRV