Name: google

Age: 25

Gender: Male

HR	: 60 bpm	P/QRS/T	: -149/34/-137°
PR	: 119 ms	RV5/SV1	: 0.459 mV/-0.265 mV
QRS	: 52 ms	RV5+SV1	: 0.724 mV
RR	: 1000 ms	QTCF	: 338 ms
QT	: 338 ms	ST	: 0 ms
QTc	: 343 ms		

25.0 mm/s 0.5-150Hz AC : 50Hz 10.0 mm/mV

DECK MOUNT

Date: 2026-02-09

Time: 16:03:27

Org: Deckmount

Phone No: 5684768946

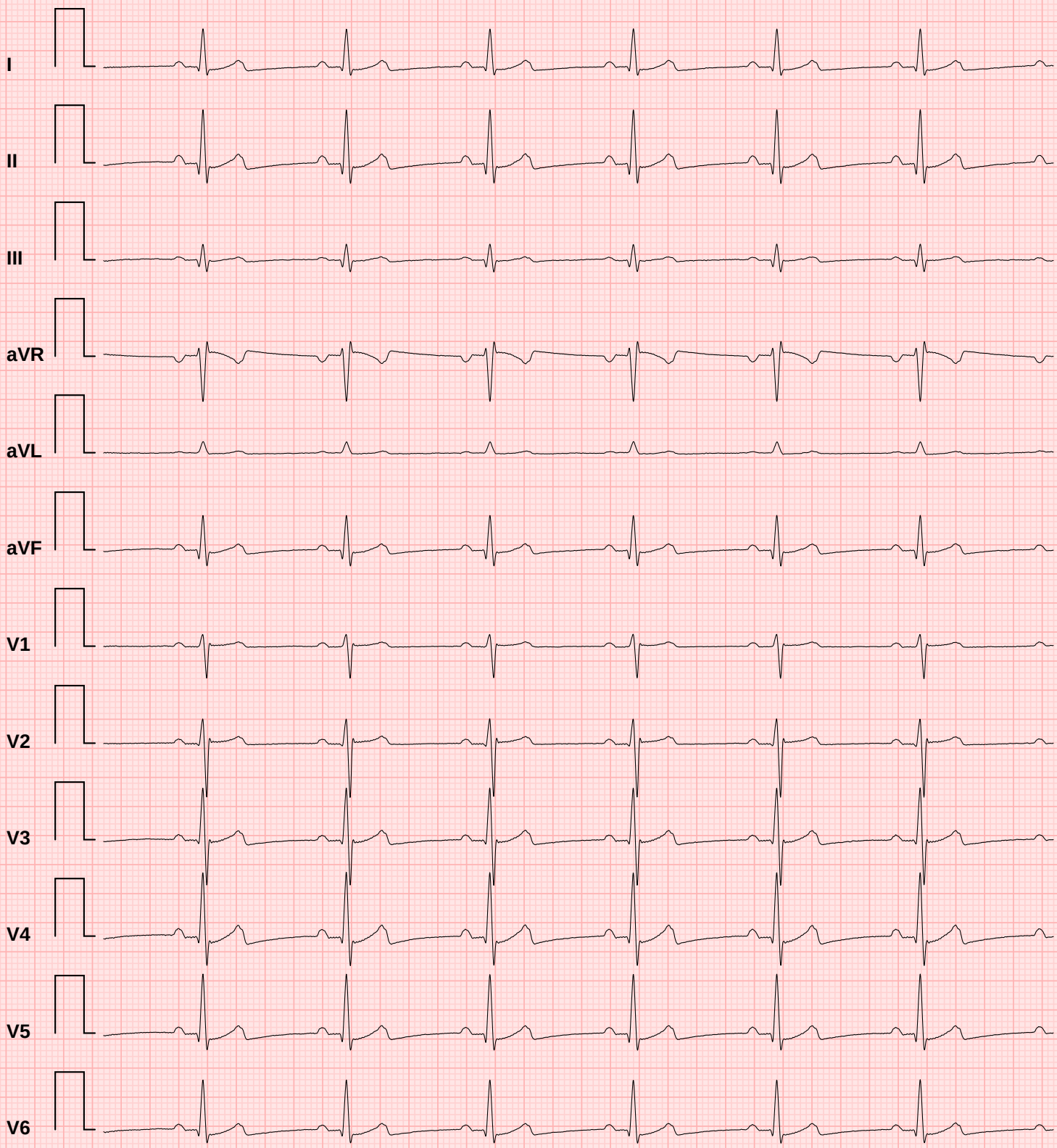

Doctor Name: Divyansh

Doctor Sign:

✦ CONCLUSION ✦

1. Bradycardia detected
2. Short PR interval
3. Normal QRS duration
4. Normal QTc interval
5. Good heart rate variability