Name: google

Age: 25

Gender: Male

HR	: 120 bpm	P/QRS/T	: --/--/--°
PR	: 170 ms	RV5/SV1	: 0.838 mV/-0.614 mV
QRS	: 85 ms	RV5+SV1	: 1.452 mV
RR	: 500 ms	QTCF	: 389 ms (0.389 s)
QT	: 309 ms	ST	: 0 ms
QTc	: 439 ms		

25.0 mm/s 0.5~35Hz AC : 50Hz 10.0 mm/mV

DECK MOUNT

Date: 09/02/2026

Time: 14:35:08

Org: Deckmount

Phone No: 5684768946

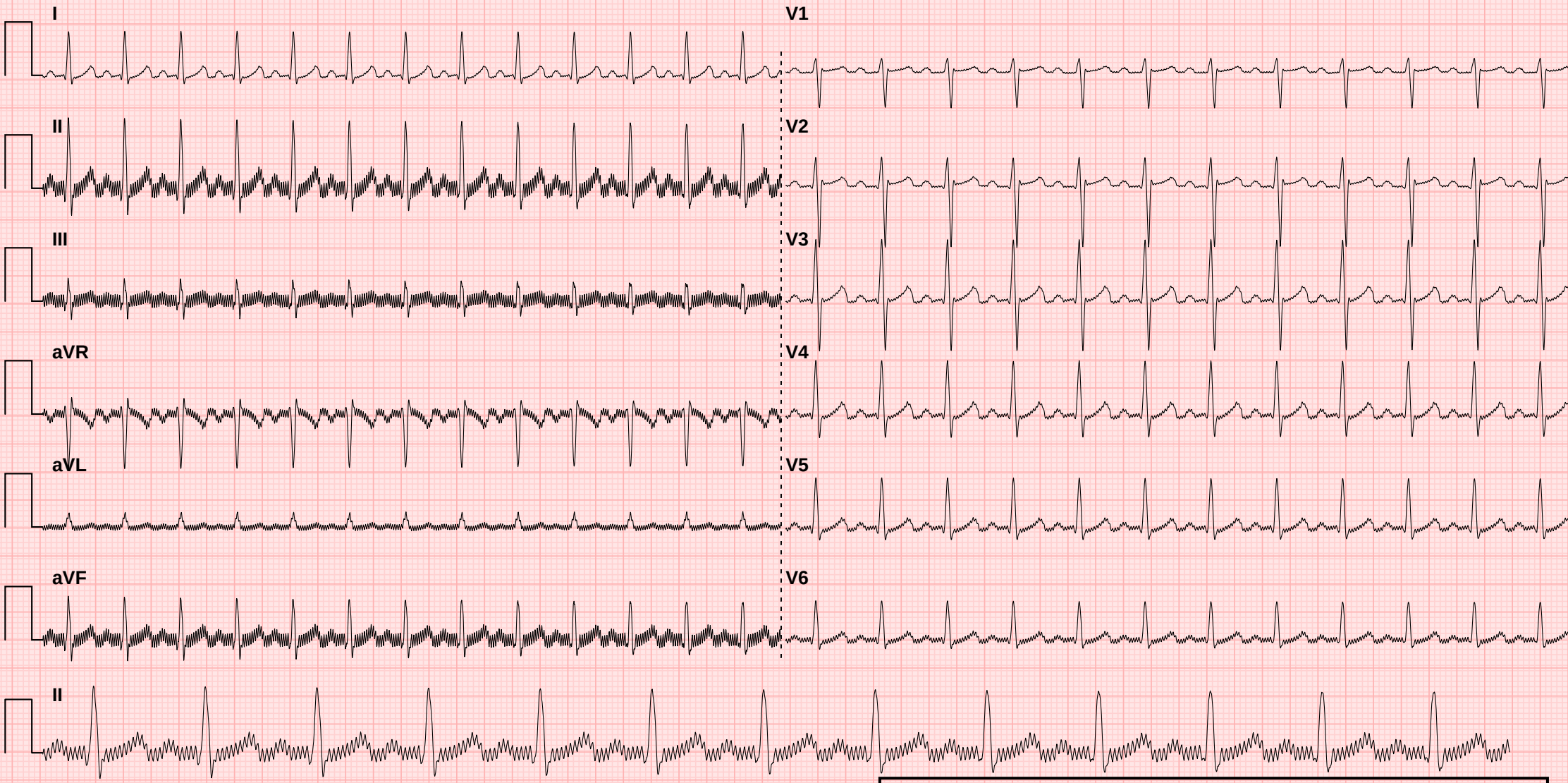

✦ CONCLUSION ✦

1. Tachycardia detected
2. Normal PR interval
3. Normal QRS duration
4. Normal QTc interval
5. Low HRV

Doctor Name: Divyansh

Doctor Sign: