Name: google

Age: 25

Gender: Male

HR	: 60 bpm	P/QRS/T	: --/--/--°
PR	: 283 ms	RV5/SV1	: 1.044 mV/-0.561 mV
QRS	: 106 ms	RV5+SV1	: 1.605 mV
RR	: 1000 ms	QTCF	: 340 ms (0.340 s)
QT	: 340 ms	ST	: 0 ms
QTc	: 335 ms		

25.0 mm/s 0.5-150Hz AC : 50Hz 10.0 mm/mV

DECK MOUNT

Date: 09/02/2026

Time: 15:08:04

Org: Deckmount

Phone No: 5684768946

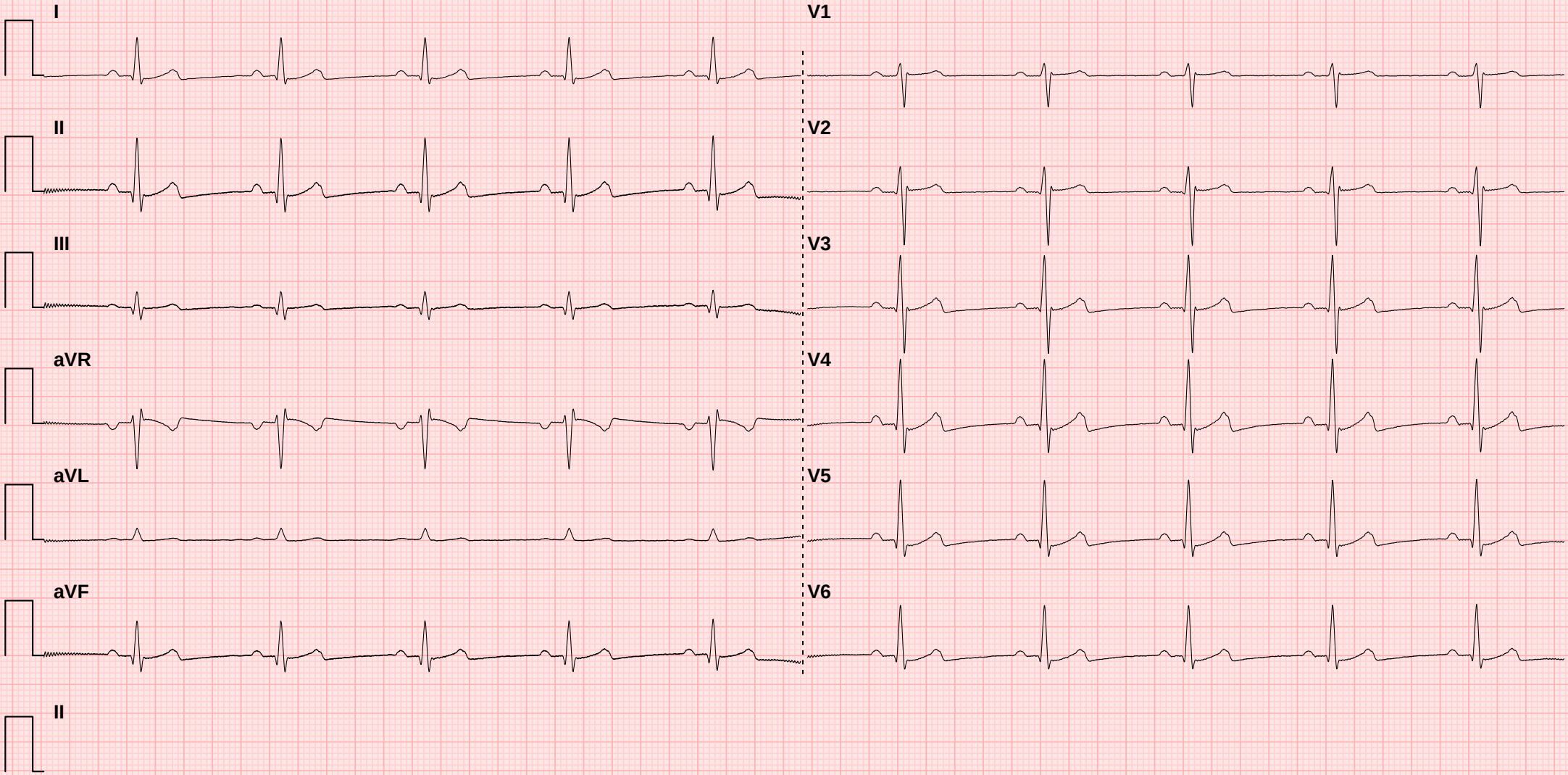

Doctor Name: Divyansh

Doctor Sign:

CONCLUSION

1. Normal heart rate
2. Prolonged PR interval
3. Borderline QRS duration
4. Normal QTc interval
5. Good heart rate variability