Retina Predict: Deep Learning-Based Diabetic Retinopathy Progression Analysis

Divyesh Shinde, Harshal Satam, Jeetkumar Rathod, Rajveer Rai

Department of Computer Engineering, MCT's Rajiv Gandhi Institute of Technology

Andheri, Mumbai

Guided by: Prof. Naina Kaushik

shindedivyeshavinash@gmail.com, jeetrathod134@gmail.com, satamharshal1402@gmail.com, rajveerrai098@gmail.com

Received xx/xx/xxxx; Revised xx/xx/xxxx; Accepted xx/xx/xxxx

Abstract**—***Diabetic Retinopathy (DR) is among the major causes of avoidable blindness on the global scale that has a considerable prevalence among patients with long-standing diabetes mellitus. Early and sensitive detection of the DR lesions play an important role in saving the incurable loss of vision and the standard manual screening method takes a long time, is not only costly, but also relies heavily on the presence of specialists. The paper introduces an automated DR detection system using deep learning, which is tested on a publicly available Blindness Detection dataset APTOS 2019 that consists of 3,662 fundus images. A systematic comparison of seven convolutional neural network (CNN) models, such as AlexNet, VGG19, ResNet50, DenseNet121, MobileNetV2, InceptionV3 and InceptionResNetV2, is done through transfer learning. In addition, a new hybrid system, which integrates InceptionResNetV2 with a Long Short-Term Memory network (LSTM), is suggested to increase the analysis of features in the sequence and to increase the rate of classification. A hybrid InceptionResNetV2-LSTM model with the best classification accuracy of 84.18 was found to be better than all single CNN baselines. The findings indicate the possibility of integrating convolutional and recurrent networks to implement a highly robust and automated method of screening of DR and provide a bright future of clinical decision support systems in the field of ophthalmology.*

©2026 ICRACE. All rights reserved

Keywords**—** *Diabetic Retinopathy, Deep Learning, Convolutional Neural Network, Transfer Learning, InceptionResNetV2, LSTM*

I. INTRODUCTION

Diabetic retinopathy (DR) is a microvascular complication of diabetes mellitus that affects the blood vessels of the retina and can cause permanent vision loss. DR is asymptomatic in early stages and cannot be detected until later stages, which often occur without regular screening. Traditional DR screening requires manual inspection by trained ophthalmologists, which is costly, time-consuming, and unscalable for large populations. As the number of diabetic patients continues to grow worldwide, automated screening systems have become increasingly essential, and recent advances in deep learning, especially convolutional neural networks (CNNs), have shown great potential in medical image analysis. CNNs can automatically extract discriminative features from retinal images and classify the severity of DR. This paper explores several CNN architectures and proposes a hybrid CNN–LSTM model for accurate DR detection.

II. LITERATURE REVIEW

Deep learning in the detection of diabetic retinopathy has been of significant research interest in the last decade. The initial research in this field had already shown that CNNs could be trained in an end-to-end fashion to detect DR using fundus images with competitive performance, paving way to further studies on more complex architectures and training methods.

In their landmark study, Gulshan et al. [1] used a deep neural network to classify retinal fundus images graded by certified ophthalmologists with a large dataset to achieve comparable sensitivity and specificity to certified ophthalmologists in detecting DR. This article demonstrated the feasibility of deep learning as a diagnostic instrument in clinical screening and sparked a series of further research. On the same note, Gargeya and Leng [2] also established that a CNN trained with little preprocessing was capable of differentiating normal fundus images and DR-positive fundus images with high diagnostic accuracy, which is an indication that it could be used in a resource-constrained environment.

Transfer learning has also become a very useful approach in medical imaging tasks where there is limited labeled data. Pratt et al. [3] tested a CNN with dropout regularization on the DR grading task, and reported promising results without the use of pre-trained weights, and later experiments demonstrated that using ImageNet pre-trained weights improved convergence speed and final accuracy significantly. VGG16, ResNet50 and InceptionV3 have also been applied to DR grading with varying success [4–6]. Overall, more architectures with skip connections like ResNet and DenseNet have been proven to be more effective than less complex ones like AlexNet and VGG on complex classification problems where subtle lesion morphology is required.

More recent studies have investigated the use of ensemble models and attention-based mechanisms to further improve DR grading performance. Wan et al. [7] suggested a collection of several CNNs that were trained using various augmentation

techniques, where they showed better generalization than single models. Architectures based on attention, like squeeze-and-excitation modules or transformer-style self-attention layers have also proven promising in selectively attending to diagnostically relevant regions of the retina [8].

Although CNNs are effective in extracting features of the local space, various researchers have investigated using recurrent neural networks (RNNs) to capture longer-range dependencies in image feature representations. LSTM architecture, a form of RNN that has been developed to overcome the vanishing gradient problem, has been applied to medical imaging data to model sequential image data. Hybrid CNN–LSTM models have been used in action recognition [9] and disease monitoring where a sequence of clinical images are used [10] and have shown benefits over the purely convolutional methods. Nevertheless, the use of hybrid CNN–LSTM models on still fundus images in the specific case of DR severity grading is a relatively understudied opportunity, which is worth considering to determine whether LSTM-processed sequences of CNN-extracted fundus features can benefit the classification of retinal images in a static image.

In spite of these developments, the available studies have a number of drawbacks. Most of the high performing models are tested on private or institution-specific data, which constrain reproducibility and generalizability. The imbalance in the available datasets between mild and moderate cases of DR and normal and severe cases leads to class imbalance that leads to models with inflated overall accuracy but weak sensitivity to clinically important intermediate grades. Moreover, the interpretability of deep learning models is a major obstacle to clinical usage, because clinicians would need to be able to explain how models make decisions to aid informed diagnosis.

IV. PROPOSED SYSTEM ARCHITECTURE

The offered system will be a hybrid deep learning architecture to identify and categorize diabetic retinopathy (DR) in retinal fundus images automatically. The architecture combines the extraction of spatial features with convolutional neural networks and the sequential extraction of feature with recurrent layers.

A. Overall System Pipeline

Fig. 1 shows the specifications of the proposed hybrid CNN-LSTM model. The given retinal image is initially subjected to several convolutional filters where space features are detected with the use of 3 x 3 filters and then ReLU activation is applied. Such layers can grab low-level and high-level visual images like edges, textures and lesion-specific images. The application of pooling layers helps to gradually decrease spatial dimensions with preservation of valuable features. Flattening of the resulting feature maps is followed by an LSTM network. The LSTM layer captures the relationships among the features that were extracted in the sequence of features, which allows a better ability to discriminate between the slight differences in the level of severity of the DR. Lastly, the fully connected layers are followed by a Softmax classifier, which yields the output probabilities of other classes of DR.

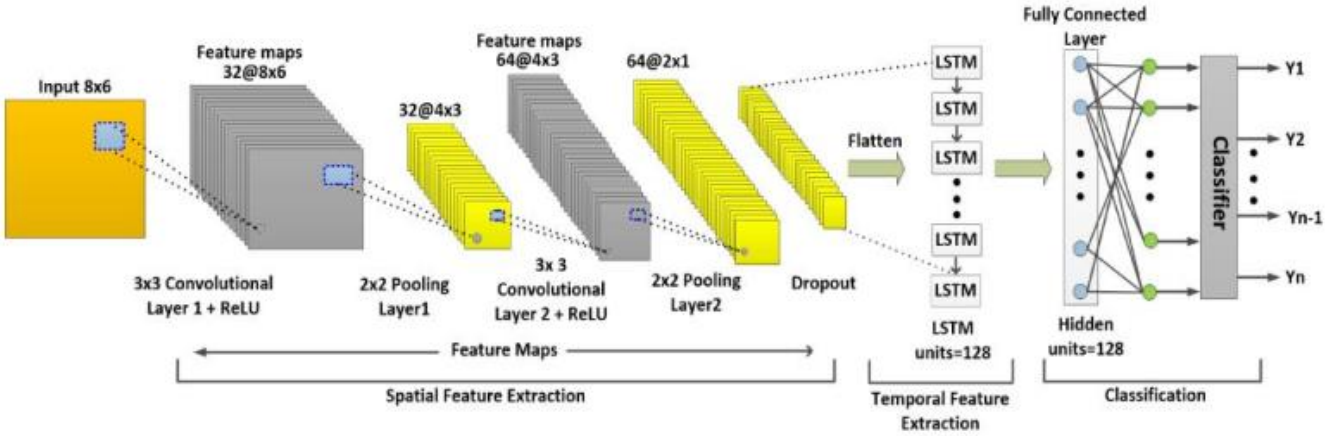

Fig. 1. Hybrid CNN–LSTM Network

B. System Workflow

Fig. 2 shows the general workflow of the proposed system. The pipeline starts with the preprocessing step, which involves resizing, normalizing, and enhancing of the input fundus images to enhance the image quality and accentuate retinal abnormalities. The methods of data augmentation are rescaling, horizontal flipping, and shear transformations, which aim to enhance the variability of datasets as well as reduce overfitting. The processed images are subsequently fed into the hybrid InceptionResNetV2-LSTM to be classified. The classifier classifies the input images to five level of severity namely: No DR, Mild, Moderate, Severe, and Proliferative DR. This organised pipeline makes sure that the learning of features is robust and the generalization is enhanced in the diverse image conditions.

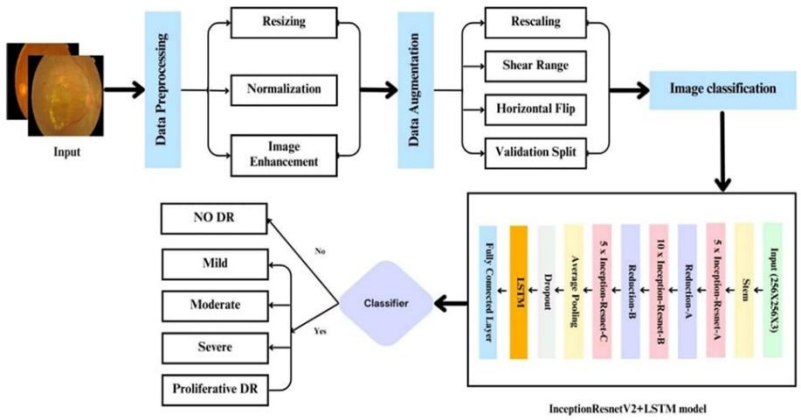

Fig. 2. The Proposed Workflow of the System

V. METHODOLOGY

A. Dataset

The dataset presented in this study is the APTOS 2019 dataset of the Blindness Detection, which is publicly available on the Kaggle platform. The data is in the form of 3,662 high-resolution retinal fundus images that have been labeled based on a five-class scale of DR severity: 0 - No DR, 1 - Mild NPDR, 2 - Moderate NPDR, 3 - Severe NPDR, and 4 - Proliferative DR. The data was taken with fundus cameras under clinical conditions. The dataset is also distinguished by the significant imbalance in classes, as most of the images belong to the No DR and Moderate DR groups, whereas the Mild, Severe, and Proliferative DR groups are significantly underrepresented. The data set was divided into training, validation and test subsets in a stratified random split with a 70, 15, and 15 percent proportion respectively. Stratified splitting also guarantees that the proportion of classes in each subset does not differ, so that no single class is overrepresented in the training or evaluation subsets. This division led to about 2,563 training images, 549 validation images, and 550 test images.

B. Data Preprocessing

Normalization of the input distribution and maximizing the visibility of diagnostic features of retinal images requires good preprocessing. All pictures were scaled to a common spatial resolution of 224 x 224 pixels to meet the requirements of the input of the tested CNN architectures. The pixel values were scaled within the range [0, 1]/255, and then each channel was standardized using channel-wise mean and standard deviation measures of the ImageNet dataset, as per the pre-training conditions of the tested architectures. Contrast Limited Adaptive Histogram Equalization (CLAHE) was used to enhance the contrast of pixel values locally to enhance the visibility of low-contrast lesions such as microaneurysms and early-stage hemorrhages without increasing noise in bright areas. Such preprocessing is essential especially to retinal fundus images where the pathological changes could be in the form of slight deviation of the healthy tissue around them. Online data augmentation was used to reduce overfitting and enhance the generalization of the model in the course of the training. Augmentation transformations were random rotations (within a range of +/-30 degrees), random horizontal and random vertical flips, random zoom and random shift, random brightness and random contrast. These changes are used to simulate the natural change in acquisition conditions and presentation of patients, which motivates the model to learn features that are robust against non-pathological variation of images.

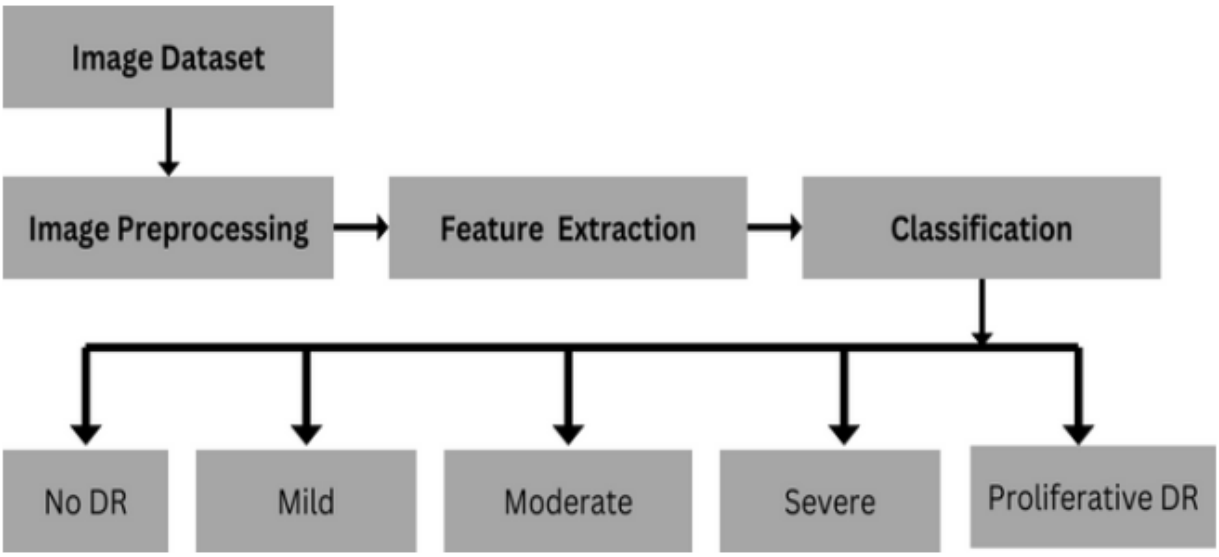

Fig. 3. Classification of Diabetic Retinopathy Dataset Based on Severity Levels

C. Feature Extraction

The key aim of the feature extraction phase is to automatically detect and encode the retinal fundus images visual signatures of DR-related retinal lesions. The first visible symptom of DR are microaneurysms, small round protrusions that occur due to the weakening of the capillary walls and which can be seen in the form of red dots on the fundus picture. Hemorrhages are defined as bigger red spots caused by the bursting of retinal blood vessels and can also have different forms such as dot, blot and flame shapes. Hard exudates are bright yellow deposits, which occur as a result of the leakage of lipids out of damaged blood vessels, whereas soft exudates (cotton wool spots) are pale, fluffy spots due to foci of infarction of the nerve fibre layer.

CNN architectures implicitly learn these features by their learned convolutional filter banks. The low level features which are detected by shallow layers include edges and color gradients, whereas deeper levels trigger when more complex composite features are present, which are lesion morphology and spatial distribution. ImageNet pre-training transfer learning gives a powerful initialisation to low- and mid-level feature detectors which are then fine-tuned on the APTOS dataset.

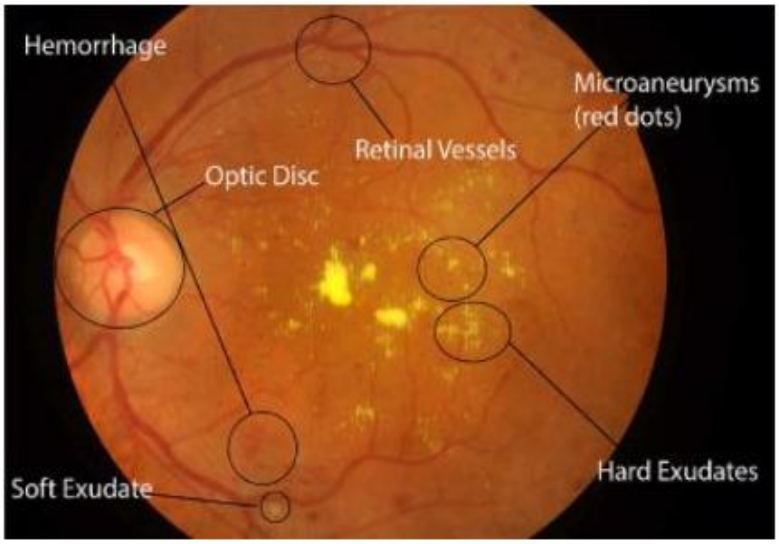

Fig. 4. Feature extraction from Fundus

D. Training and Evaluation

The data set is separated into training, validation and testing sets. The Adam optimizer and categorical cross-entropy loss function are used to train the models in 50 epochs.

The training was done in two stages. During the initial stage, the convolutional base was frozen, and only the added classification layers were trained, and the model was adjusted to the domain-specific class distribution without interfering with the pre-trained representations. During the second step, the convolutional base was unfrozen and the whole network was fine-tuned end to end with a lower learning rate to optimize feature representations to the DR grading task.

VI. RESULTS AND ANALYSIS

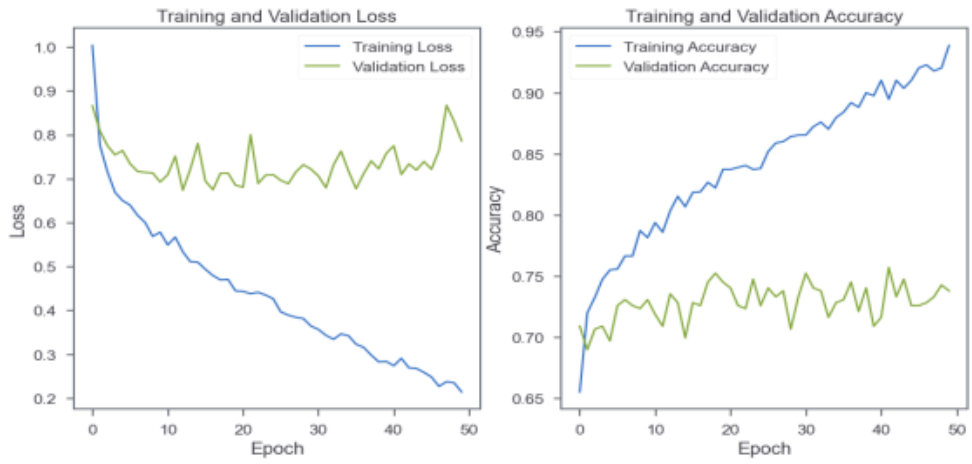

Fig. 5. Training and Validation Accuracy and Loss of the Hybrid Model

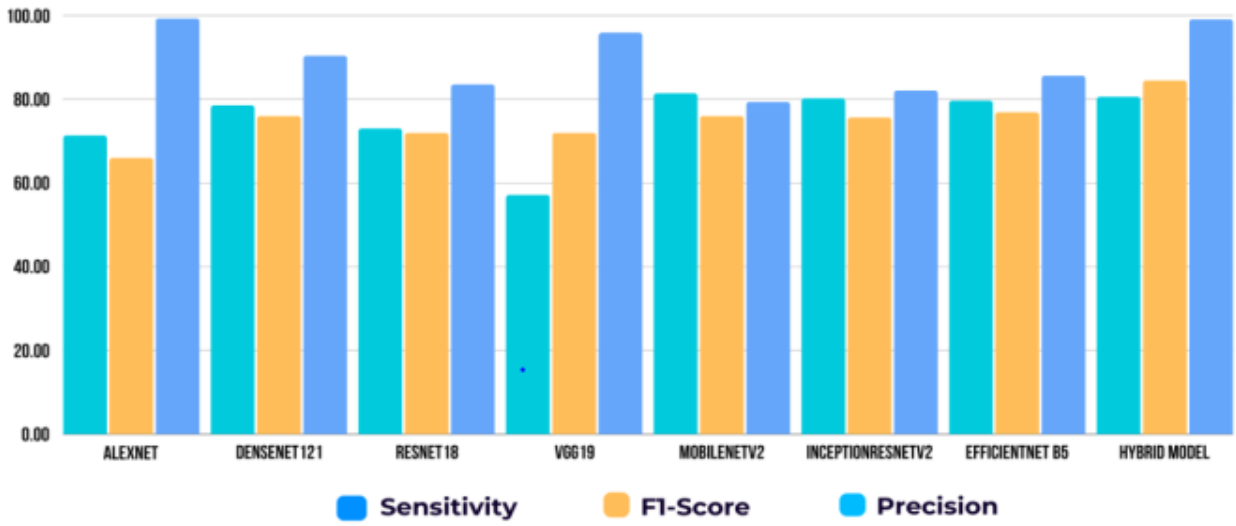

Fig. 6. Performance Comparison of Studied Architectures

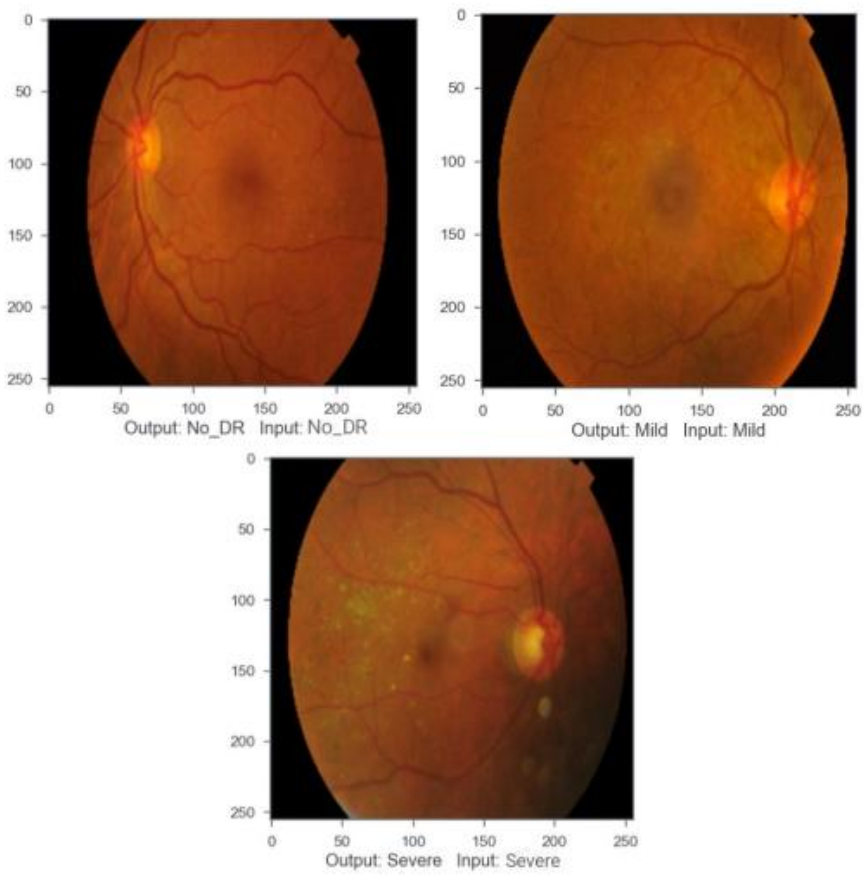

Fig. 7. Sample Input Fundus Image and Predicted Output Label

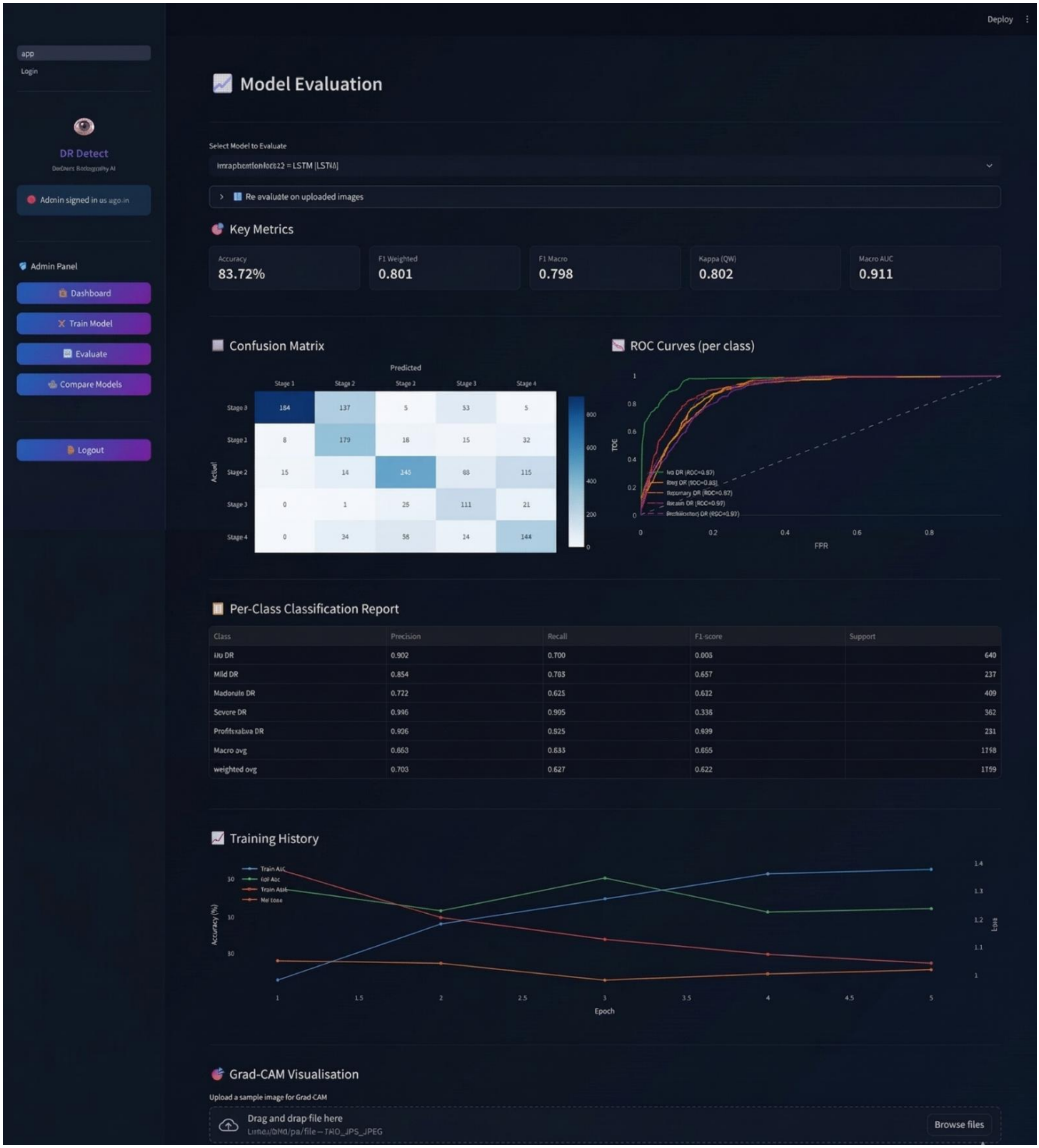

Fig. 8. Streamlit-based model evaluation dashboard showing performance metrics, confusion matrix, ROC curves, classification report, and training history.

VII. DISCUSSION

A. Strengths of the Proposed Approach

The automated DR detection framework that is discussed in this paper has a number of realistic benefits. First, minimal manual feature engineering is necessary in the end-to-end deep learning pipeline since the training process learns that fundus images with relevant lesion characteristics. This decreases reliance on domain-expert feature design, and allows adaptation to new datasets or imaging modalities using transfer learning. Second, the comparative analysis of seven CNNs on a common dataset and protocol offers an objective measure of comparing their respective strengths relative to the problem of grading of DR severity. Third, the hybrid InceptionResNetV2-LSTM architecture shows that incorporating recurrent processing into a CNN-based pipeline can provide significant improvements in accuracy with only minimal computational complexity and training time requirements.

B. Limitations

Although the results are encouraging, a number of limitations of this study should be noted. Although APTOS 2019 is publicly available and has become a commonly used benchmark, its scale is relatively small when compared to the large-scale datasets of some of the most successful DR detection systems. As with a much larger and more heterogeneous training set, the models will probably generalize better and become less sensitive to patient-specific imaging variation. Also, the data set is highly imbalanced in classes and the No DR and Moderate NPDR classes make up the most samples. Such imbalance can lead to biasness of the more represented classes, which may lead to reduced sensitivity to the less frequent yet clinically important categories of Severe NPDR and Proliferative DR. The classification performance of the best-performing model of 84.18% although competitive with other models tested on the APTOS data under similar conditions is lower than the performance rates of state-of-the-art systems trained on much larger proprietary data. The average overall accuracy is partly due to the challenge of the five-class grading task, where the classes of severity adjacent to one another have a similar lesion morphology by visual appearance. Binary DR detection (DR vs. No DR) would probably provide significantly better accuracy, but has relatively low clinical utility in comparison to full severity grading. The model interpretability is not a topic of this study but it is a significant concern to clinical deployment. To assist clinicians with the diagnostic decision-making process, the clinicians need clear and explainable results, and to find situations when automated predictions cannot be trusted. The lack of gradient-based visualization techniques or attention-based explanation techniques restrains how well the predictions of the model can be verified by respect of known clinical standards.

C. Directions for Future Work

It is possible to find several avenues of future research in order to overcome the limitations mentioned above. First, it would be better to train and evaluate on larger and more diverse datasets (or combinations of multiple publicly available DR datasets) to have a stronger evaluation of the generalizability of models. The sensitivity of underrepresented severity classes might be improved by techniques to deal with class imbalance, including class-weighted loss functions, oversampling (e.g. SMOTE), or synthetic image generation with generative adversarial networks (GANs). Second, implementing the mechanisms of attention (e.g., spatial attention modules) or transformer-based architectures into the suggested framework may enhance the model focus on retinal regions that are diagnostically significant and increase the classification performance. Semi-supervised and self-supervised learning plans provide further opportunities to take advantage of massive amounts of unlabeled fundus images, which are often in clinical practice. Third, implementations of explainable AI (XAI) methods, such as Gradient-weighted Class Activation Mapping (Grad-CAM) and Integrated Gradients, would allow visualizing the retinal areas, which most significantly affect model predictions, allowing clinical validation and establishing trust among clinicians. Lastly, exploring ensemble methods (using the predictions of a group of models that have been independently trained) may minimize prediction variance and provide more reliable estimates of accuracy on the whole range of severity. This paper will suggest an automated system to identify diabetic retinopathy by analysing images with deep learning. The experimental analysis shows that the hybrid CNN–LSTM model performs better as compared to the separate convolutional neural network models. The system developed can be used to assist ophthalmologists by assisting them in screening retinal images more quickly and detecting diabetic retinopathy in its early stages that can avert the development of serious cases of vision loss.

VIII. CONCLUSION

In this paper, a systematic review of deep learning methods to detect and grade diabetic retinopathy has been performed and tested on the APTOS 2019 Blindness Detection dataset. Seven pre-trained CNN architectures namely AlexNet, VGG19, ResNet50, DenseNet121, MobileNetV2, InceptionV3, and InceptionResNetV2 were tested through a standard experimental protocol that included transfer learning, preprocessing of images using CLAHE contrast enhancement, and data augmentation. It proposed and tested a new hybrid architecture that integrates InceptionResNetV2 with LSTM network, which had the highest classification accuracy of 84.18.

The comparative findings confirm that architectural fancy, such as multi-scale convolutional design and residual connectivity, have a significant impact on performance with the DR grading task. The hybrid CNN–LSTM architecture also shows that processing feature representations generated by CNN in a sequential way can offer an extra discriminative power, which cannot

be offered by spatial pooling alone. The results contribute to the sphere of deep learning approaches to analyzing retinal images and provide an empirically confirmed background to subsequent research in the field of automated screening of DR.

The automated DR detection device designs that have been created in this study could significantly reduce the workload of ophthalmological screening services so that patients who are at risk could be identified on time at the facility where the specialist in this field is scarce. The next step in developing automated DR screening tools towards clinical readiness should focus on model interpretability, resistance to imaging variability, and testing on larger, balanced datasets.

REFERENCES

[1] V. Gulshan et al., "Development and validation of a deep learning algorithm for detection of diabetic retinopathy in retinal fundus photographs," JAMA, vol. 316, no. 22, pp. 2402–2410, Dec. 2016.

[2] R. Gargeya and T. Leng, "Automated identification of diabetic retinopathy using deep learning," Ophthalmology, vol. 124, no. 7, pp. 962–969, Jul. 2017.

[3] H. Pratt, F. Coenen, D. M. Broadbent, S. P. Harding, and Y. Zheng, "Convolutional neural networks for diabetic retinopathy," Procedia Computer Science, vol. 90, pp. 200–205, 2016.

[4] M. D. Abràmoff, Y. Lou, A. Erginay, W. Clarida, R. Amelon, J. C. Folk, and M. Niemeijer, "Improved automated detection of diabetic retinopathy on a publicly available dataset through integration of deep learning," Investigative Ophthalmology & Visual Science, vol. 57, no. 13, pp. 5200–5206, Oct. 2016.

[5] X. He, Y. Zhang, X. Xiao, and Y. Ma, "Automated grading of diabetic retinopathy using deep convolutional neural network," in Proc. IEEE Int. Conf. Bioinformatics and Biomedicine (BIBM), Kansas City, MO, USA, 2019, pp. 2365–2371.

[6] A. Lahiri, A. Roy, D. Sheet, and P. K. Biswas, "Deep neural ensemble for retinal vessel segmentation in fundus images towards achieving label-efficient learning," in Proc. 38th Annu. Int. Conf. IEEE Engineering in Medicine and Biology Society (EMBC), Orlando, FL, USA, 2016, pp. 1340–1343.

[7] S. Wan, Y. Liang, and Y. Zhang, "Deep convolutional neural networks for diabetic retinopathy detection by image classification," Computers & Electrical Engineering, vol. 72, pp. 274–282, Nov. 2018.

[8] Z. Wang, Y. Yin, J. Shi, W. Fang, H. Li, and X. Wang, "Zoom-in-Net: Deep mining lesions for diabetic retinopathy detection," in Proc. Int. Conf. Medical Image Computing and Computer-Assisted Intervention (MICCAI), Quebec City, QC, Canada, 2017, pp. 267–275.

[9] J. Donahue et al., "Long-term recurrent convolutional networks for visual recognition and description," in Proc. IEEE Conf. Computer Vision and Pattern Recognition (CVPR), Boston, MA, USA, 2015, pp. 2625–2634.

[10] S. Gao, M. Ver Steeg, and A. Galstyan, "Efficient estimation of mutual information for strongly dependent variables," in Proc. 18th Int. Conf. Artificial Intelligence and Statistics (AISTATS), vol. 38, San Diego, CA, USA, 2015, pp. 277–286.

[11] X. Wang, Y. Lu, Y. Wang, and W.-B. Chen, "Diabetic retinopathy stage classification using convolutional neural networks," IEEE, 2018.

[12] M. Rehman, S. H. Khan, Z. Abbas, and S. M. D. Rizvi, "Classification of diabetic retinopathy images based on customized CNN architecture," IEEE, 2019.

[13] W. Zhang, J. Zhong, S. Yang, Z. Gao, J. Hu, Y. Chen, and Z. Yi, "Automated identification and grading system of diabetic retinopathy using deep neural networks," Knowledge-Based Systems, 2019.

[14] T. Shanthi and R. S. Sabeenian, "Modified AlexNet architecture for classification of diabetic retinopathy images," Elsevier, 2019.

[15] D. Das, S. K. Biswas, and S. Bandyopadhyay, "Detection of diabetic retinopathy using convolutional neural networks for feature extraction and classification (DRFEC)," Springer, 2022.

[16] G. Kalyani, B. Janakiramaiah, A. Karuna, and L. V. N. Prasad, "Diabetic retinopathy detection and classification using capsule networks," Springer, 2021.

[17] S. Das, K. Kharbanda, M. Suchetha, R. Raman, and E. D. Dhas, "Deep learning architecture based on segmented fundus image features for classification of diabetic retinopathy," Elsevier, 2021.

[18] V. Bellemo, Z. W. Lim, and G. Lim, "Artificial intelligence using deep learning to screen for referable and vision-threatening diabetic retinopathy in Africa: A clinical validation study," The Lancet Digital Health, 2019.

[19] Z. Khan, F. G. Khan, A. Khan, Z. U. Rehman, S. Shah, S. Oummar, F. Ali, and S. Pack, "Diabetic retinopathy detection using VGG-NIN: A deep learning architecture," IEEE Access, vol. 9, pp. 61408–61416, 2021.

[20] G. Huang, Z. Liu, L. van der Maaten, and K. Q. Weinberger, "Densely connected convolutional networks," in Proc. IEEE Conf. Computer Vision and Pattern Recognition (CVPR), Honolulu, HI, USA, Jul. 2017, pp. 4700–4708.

[21] M. D. Abramoff, J. M. Reinhardt, S. R. Russell, J. C. Folk, V. B. Mahajan, M. Niemeijer, and G. Quellec, "Automated early detection of diabetic retinopathy," 2010.

[22] S. Wilfred Franklin and S. Edward Rajan, "Computerized screening of diabetic retinopathy employing blood vessel segmentation in retinal images," 2014.

[23] B. Antal and A. Hajdu, "An ensemble-based system for automatic screening of diabetic retinopathy," 2014.

[24] M. D. Abramoff, "Automated analysis of retinal images for detection of referable diabetic retinopathy," 2013.

[25] R. Revathy, B. S. Nithya, J. J. Reshma, S. S. Ragendhu, and M. D. Sumithra, "Diabetic retinopathy detection using machine learning," IJERT, 2020.