Minimal Spanning Trees in Medical Image Processing

20MAT382- Computational Optimization and Application

Diya Susan Mathew,53

Abstract

This report explores the application of Minimal Spanning Trees (MSTs), specifically a modified Kruskal's algorithm, to pediatric chest X-ray image segmentation and denoising. By representing pixels as graph nodes and intensity differences as edge weights, the algorithm successfully segments distinct anatomical structures and pathological opacities (pneumonia) while reducing noise.

Contents

1 Introduction **3**

2 Methodology **3**
2.1 Implementation Approach and Graph Representation 3
2.2 Segmentation Criterion 3
2.3 Denoising Mechanism 3

3 Results and Analysis **3**
3.1 Quantitative Metrics 3
3.2 Visual Comparison and Parameter Sensitivity 4

4 Discussion **6**
4.1 Advantages and Limitations 6

5 Code Availability **6**

6 Conclusion **7**

1 Introduction

Medical image segmentation is crucial for diagnosis and treatment planning, as it allows clinicians to isolate distinct anatomical structures and pathological anomalies. The primary objective of this assignment is to apply graph theory—specifically Minimal Spanning Tree (MST) concepts—to segment gray-scale medical images while reducing noise. By treating image pixels as vertices and their intensity differences as edge weights, we can leverage a modified Kruskal's algorithm to identify boundaries between healthy tissue and pulmonary infections (pneumonia) in pediatric chest X-rays.

2 Methodology

2.1 Implementation Approach and Graph Representation

The input images were resized to 128×128 pixels to optimize the computational efficiency of the $O(E \log E)$ edge-sorting step. The image was transformed into a grid graph $G = (V, E)$, where V represents the pixels. Edges were constructed connecting 4-neighbor pixels (right and bottom). The edge weights $w(e)$ represent the absolute intensity differences between neighboring pixels:

$$w(v_{i,j}, v_{k,l}) = |I(i,j) - I(k,l)| \tag{1}$$

2.2 Segmentation Criterion

A modified Kruskal's algorithm was employed using a Union-Find data structure. Edges were sorted by weight in non-decreasing order. Two components C_u and C_v were merged if the edge connecting them satisfied the threshold criterion:

$$w(e) \leq \min(Int(C_u) + \tau(C_u), Int(C_v) + \tau(C_v)) \tag{2}$$

where $Int(C)$ is the maximum edge weight in the component's MST, and $\tau(C) = \frac{k}{|C|}$ is the adaptive threshold function. The scale parameter was set to $k = 300$ to prevent over-segmentation of subtle textures while preserving global anatomical boundaries.

2.3 Denoising Mechanism

Post-segmentation, denoising was achieved by replacing individual pixel values with the mean intensity of their respective segment $C(p)$:

$$I_{denoised}(p) = \frac{1}{|C(p)|} \sum_{q \in C(p)} I(q) \tag{3}$$

3 Results and Analysis

3.1 Quantitative Metrics

The algorithm was tested on three pediatric chest X-rays: Normal Lung, Viral Pneumonia, and Bacterial Pneumonia. Table 1 summarizes the performance metrics.

Table 1: Quantitative Segmentation Metrics (128×128 resolution, $k = 300$)

Image Classification	Segments	Comp. Time (s)	MSE	PSNR (dB)
Normal Lung	282	0.1828	407.24	22.03
Viral Pneumonia	218	0.3380	254.85	24.07
Bacterial Pneumonia	216	0.3599	203.02	25.06

3.2 Visual Comparison and Parameter Sensitivity

The normal lung generated the highest number of segments (282) due to the sharp, distinct boundaries between radiolucent (dark) air spaces, ribs, and the heart. In contrast, the pneumonia cases generated fewer segments because the pathological fluid blurs anatomical boundaries, creating large, uniform opacities that the algorithm correctly grouped together.

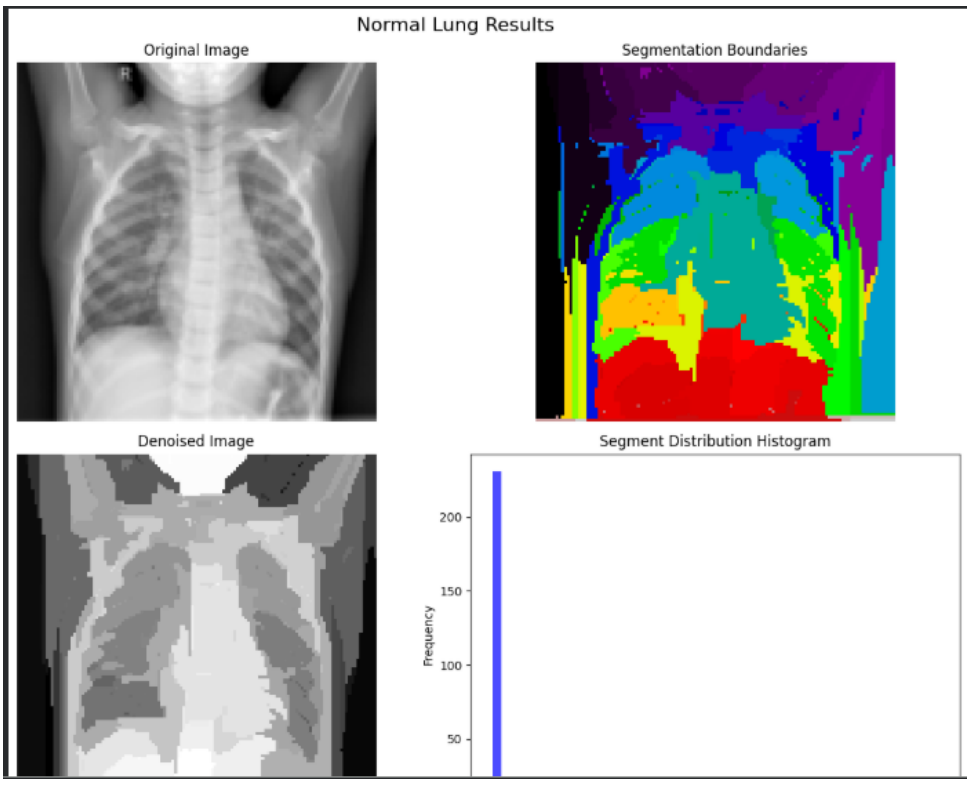

Figure 1: Results for Normal Lung: Original, Boundaries, Denoised, and Histogram.

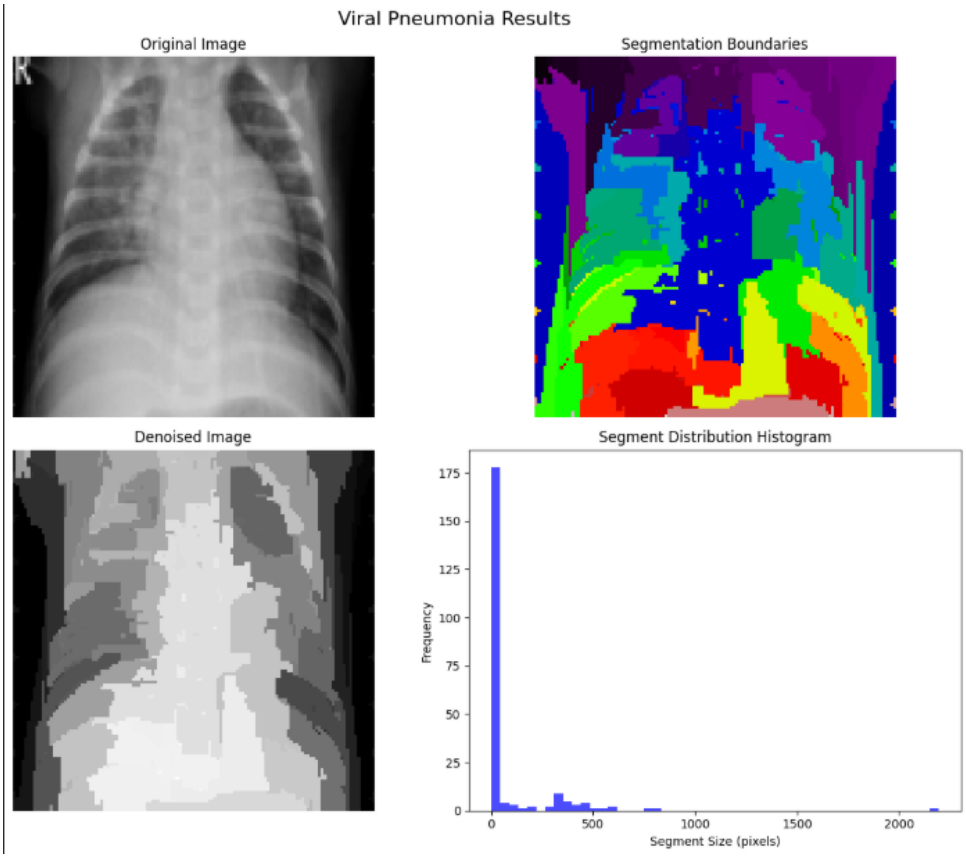

Figure 2: Results for Viral Pneumonia (Diffuse opacities).

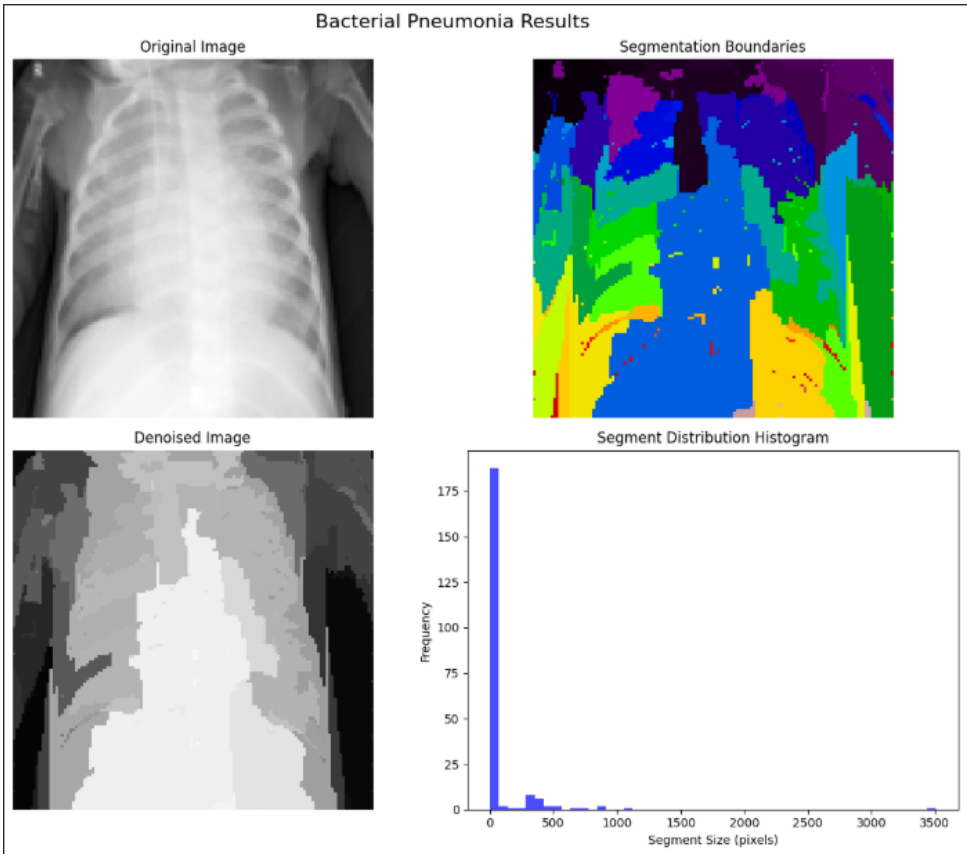

Figure 3: Results for Bacterial Pneumonia (Lobar consolidation).

4 Discussion

4.1 Advantages and Limitations

The primary advantage of the MST-based approach is its ability to preserve global image structures. It successfully identified the massive lobar consolidation in the Bacterial Pneumonia image as a distinct anomaly. The denoising step effectively smoothed the internal textures of segments while perfectly preserving the sharp edges between different anatomical regions.

A key limitation is computation time for high-resolution images. Because the algorithm relies on sorting $|E|$ edges, scaling to 1024×1024 native X-ray resolutions causes a computational bottleneck. Additionally, the Mean Squared Error (MSE) is inherently higher (407.24) for healthy lungs because the healthy texture is diverse; averaging these textures into solid segment blocks creates mathematical error compared to the original, despite looking visually cohesive.

5 Code Availability

The complete, well-documented Python implementation of the MST-based segmentation algorithm, including the evaluation metrics, image preprocessing steps, and visual generation functions, is available in the public GitHub repository for this assignment: `https://github.com/dais-x/Computational-Optimization-Assignment-1`.

6 Conclusion

The modified Kruskal's MST algorithm provides a highly effective, graph-based framework for medical image segmentation. By applying the algorithm to pediatric chest X-rays, we demonstrated its practical utility in distinguishing healthy anatomical boundaries from pathological consolidations. While highly sensitive to its thresholding parameter and resolution scale, the approach offers a robust foundation for automated medical diagnostics and targeted denoising.