جوستاف روسي انترناشيونال - مصر (EPE) * **طلب علاج أول مرة / متردد**

إسم المريض رباعياً : فاطمه صبحي عبدالمنعم محمد
المحافظة : القليوبيه **الحي / المدينة :** شبرا الخيمه اول **العنوان :** ++++++
رقم البطاقة : 28607011406006 **رقم التليفون :** 01227718440 **تاريخ تسجيل الإستمارة :** 17-10-2026
العمر(تاريخ الميلاد) : 01-07-1986 **المهنة :** ربه منزل

الإقرار

أقر انا الموقع أدناه انني لا اتمتع باي نظام علاج مثل:-التأمين الصحي-القوات المسلحه-الشرطة-الهيئات-المؤسسات او اي نظام يتعارض مع نظام العلاج علي نفقة الدولة- وسوف اتحمل كافة نفقات العلاج في حالة ثبوت غير ذلك

الإخصائي الاجتماعي **المقر بما فيه**
التوقيع:(----------) **التوقيع:**(----------)

التشخيص الإكلينيكي : سرطان بالثدي (مبادرة)
نتائج الأبحاث : (مرفق)
التشخيص النهائي : سرطان بالثدي (مبادرة)
خطة العلاج : علاج مبادرة سرطان الثدي زولاديكس تحت الجلد لمده 6 شهور [14163] **قسم العلاج :** الاورام
التعليق على التشخيص : ----------

تقرير اللجنة الثلاثية المتخصصة

الاسم: د/محمد كيلاني **الوظيفة:** ---------- **التوقيع:** ----------
الاسم: د/ندى حسن **الوظيفة:** ---------- **التوقيع:** ----------
الاسم: د/نرمين رمضان **الوظيفة:** ---------- **التوقيع:** ----------

أطلعت اللجنة علي لائحة العلاج الخاصة بالمجالس وتلتزم جهة العلاج بلائحة المجالس الطبية.
كما تقر اللجنة بأن البيانات المدونة فى هذا النموذج صحيحة.

تعتمد صحة البيانات المرفقة
رئيس اللجنة و مدير المستشفي.

تتعهد المستشفى أن لا يتم تنفيذ القرار إلا بعد مراجعة الملف الطبي للمريض وإعادة مناظرة المريض بالمستشفي قبل الصرف.

أعضاء اللجنة

ا.د/ ---------- **ا.د/** ---------- **د/** ---------- **د/** ----------

قرار اللجنة

التشخيص النهائي : ----------
خطة العلاج : ----------
المستشفي : ----------**قسم :** ----------
جهة العلاج : ----------**نفقات :** ----------
ملاحظات : ----------

رئيس	مدير عام	ختم
المجلس الطبي المتخصص	مديرية الشئون الصحية	شعار الجمهورية

Name: فاطمه صبحي عبدالمنعم محمد
National ID: 28607011406006



تقرير طبي

السيد

تحية طيبة وبعد,,

إيماء للطلب المقدم من	بشأن تقرير طبي للمريض
بقسم:	رقم طبي:

نتشرف بأن نوضح فيما يلي تقريرا عن حالته


تاريخ وساعة الدخول : -- --:-- yyyy-mm-dd	تاريخ وساعة الخروج : PM 01:17 05-07-2026

وبعد الكشف والفحوصات والمتابعة وجد انة

المريضة تعاني من ورم غير حميد بالثدى و تحتاج الي **Goserelin (Zoladex) subcutaneous**

التاريخ : 05-07-2026	الوقت : -- --:--
	الطبيب المعالج : د/شيماء لاشين





National ID – Front & Back
[[DOCTYPE:ID_FRONT_BACK]]

مبـــادرة رئيس الجمهورية
لدعـم صحة المرأة المصرية

04/23/2026

MDT FORM

Name:	Fatma Sobhy Abd Elmenaam Mohamoud	**MRN:**	6818
Age:	40 Y	**ID:**	28607011406006
Menopausal Sta	prem	**Phone:**	01147415895
NRS SCORE:	ps 1	**Marital Status:**	
BMI:		**Family History:**	
CO Morbidity:		**Reason Of MDT:**	

Clinical Data:

BX: idc

ER: 8/8 **PR:** 5/8 **HER2:** -ve **KI67:**

Sonomammography:

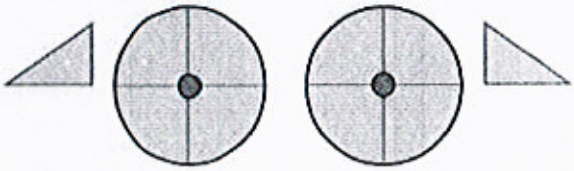
Mets Workup:

History:
PREM RT BREAST CANCER UNDERGONE RT BCS ON 8/10/2025 PT2 N1 3/18 ER8/8 PR 5/8 HER2 -VE KI 20% REC 3 AC and 8/9 weeks taxol for mdt for hormonal tt

Recommendations:

MDT Outcome & Plan
PORT (if not received)
adj endocrine ttt Femara + Zoladex (5y)
Zometa/6m


R L



T N M

SIGNATURE

MEDICAL ONCOLOGY	SURGERY	RADIOLOGY	PATHOLOGY	Nutrition	Psychiatric



جوستاف روسي

مبادرة رئيس الجمهورية لدعم صحة المرأة المصرية

الست المصرية هي صحة مصر

MDT FORM : 4/11/2025 G

Name	فاطمه صبحي عبد العليم	MRN	٢٦٤٨١ Co
		ID	٢٨٦٠٧٠١١٤٠٦٠٠٦
Age	٤٩	Phone	01147415895
Menopausal status		Marital status	
NRS SCORE		Family history	
BMI		REASON OF MDT	Post op
CO morbidity			

Clinical Data

BX: Rt Breast Cancer (up-front)

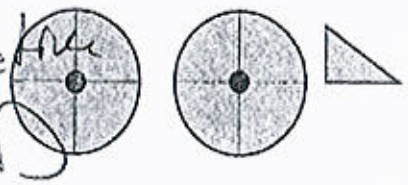
ER:	PR:	HER 2:	Ki67:
8/8	5/8	0	20%

Sonomammography: Rt Breast Conservative surgery & ALND

Mets Workup:

Surgical Margins => Free

Axillary LN



TNM

Recommendations: => +ve metastatic deposit 3/18 with No etranodal extension

Stage => pT2(m), pN1a

MDT OUTCOME & PLAN

① Adj Chemotherapy (3 AC + 9 wks Taxol)
② PORT
③ Adj hormonal

SIGNATURE

MEDICAL ONCOLOGY	SURGERY	RADIOLOGY	PATHOLOGY	Nutrition	Psychiatric

٤/١١/٢٠٢٥

MDT Form
[[DOCTYPE:MDT_FORM]]

STAVE/
USSY
TIONAL

atient Name	: الأستاذه / فاطمه صبحي عبدالمنعم محمد	Request No.	: 13004957
atient No.	: 28607011406006	Request Date	: 08/10/2025
ath No.	: 3075/25	Verification Date	: 15/10/2025
ex	: Female	Financial Category	: جوستاف روسي - نفقة الدولة
ge	: 39 Y	Department	: Out Patient
eferreing Doc :		Registered by	: Mrs.Mayada Hegazy

Pathology Report

Clinical Data: Right breast cancer, Up-Front.
Nature Specimen: Right breast conservative surgery, Extra-lateral margin, Extra-superior margin & Axillary lymph nodes dissection.

Gross Examination:
Right breast conservative surgery specimen measured 9.5x7x4 cm, with covering skin ellipse measured 7x1.5 cm.
Serialling showed three masses measured 4x2.5x2 cm, 2.7x2.5x2.1 cm and 2.1x1x1 cm. The least distance between the masses was 2 cm. The masses were less than 0.1cm from the least lateral materal margin, 0.4 m from superior margin, 0.5 cm from inferior margin and 1 cm from both (medial & deep margins).
Extra-superior margin: Fibrofatty tissue piece measured 4x2x1 cm.
Extra-lateral margin: Fibrofatty tissue piece measured 5.5x3x1.5 cm.
Axillary fat measured 7x5x2 cm, entangling 18 lymph nodes, the largest was 2.5x1.8x1.5 cm.
* 22 Blocks:
1:5- 1st Mass., 6- Area inbetween 1st & 2nd masses., 7&8- 2nd mass., 9- Area inbetween 2nd & 3rd masses., 10&11- 3rd mass., 12- Medial margin., 13- Lateral margin., 14- Extra-superior margin., 15- Inferior margin., 16- Superficial., 17- Deep., 18- Extra-lateral margin., 19- Skin., 20:22- L.Ns.
Gross was done by; Dr. Mennan Hossam.

* Frozen (Intra-operative) results:
- Positive lateral margin for (DCIS).
- Free other surgical margins.

Microscopic Examination:
Histological Type: Multifocal invasive duct carcinoma.

Verified by :
Dr.Duaa Mohamed

غرفة رقم (4) – الدور الأول – مبنى رقم (987) – كورنيش النيل – مصر القديمة – القاهرة – مصر
Room No. (4) - First Floor-Building No. 987- Nile Corniche - Misr El Qadema - Cairo, Egypt

Pathology Report
[[DOCTYPE:PATHOLOGY_REPORT]]

USTAVE
OUSSY
NATIONAL

Patient Name	: الأستاذه / فاطمه صبحي عبدالمنعم محمد	Request No.	: 13008334
Patient No.	: 28607011406006	Request Date	: 11/09/2025
Path No.	: 2811/25	Verification Date	: 16/09/2025
Sex	: Female	Financial Category	: جورستاف روسي - مبادره
Age	: 39 Y	Department	: Out Patient
Referreing Doc :		Registered by	: Mrs.Mayada Hegazy

Pathology Report

IPT:
- ER: Positive (score 8/8).
- PR: Positive (score 5/8).
- Her2: Negative (score 0).
- KI67%: 20%.

* Scoring system: "ER, PR"
ASCO-CAP ER/PR Test Guideline Recommendations: proportion of cells staining (0, no staining; 1, >1%; 2, between 1% and 10%; 3, between 11% and 33%; 4, between 34% and 66%
and 5, between 67%-100% of the cells staining). Intensity of positive tumor cells (0, none; 1, week, 2, intermediate; and 3, strong). Total score from 0 to 8.
* Scoring system: "Her2"
Reference: ASCO-CAP Her2 Test Guideline Recommendations, 2013.IHC 0: as defined by no staining observed or membrane staining that is incomplete and is faint/barely perceptible and within < 10% of the invasive tumor cells. IHC 1+: as defined by incomplete membrane staining that is faint/barely perceptible and within > 10% of the invasive tumor cells.
IHC 2+: based on circumferential membrane staining that is incomplete and/or weak/moderate and within >10% of
the invasive tumor cells or complete and circumferential membrane staining that is intense and within < 10% of the invasive tumor cells. IHC 3+: based on circumferential membrane staining that is complete, intense > 10% of tumor cells.

Signature
Dr. Walaa Ibrahem Ghoneim.
Dr. Heba El-Shafeey.

Verified by :
Dr.Duaa Mohamed

CAP ACCREDITED

غرفة رقم (4) – الدور الأول – مبنى رقم (987) – كورنيش النيل – مصر القديمة – القاهرة – مصر
Room No. (4) - First Floor-Building No. 987- Nile Corniche - Misr El Qadema - Cairo, Egypt

Pathology Report
[[DOCTYPE:PATHOLOGY_REPORT]]

GUSTAVE ROUSSY
INTERNATIONAL

Patient Name: Fatma Sobhy Abd Al Moneim	Date : 09/09/2025
Exam : MAMMOGRAPHY BOTH	Age : 39 Year(s)
Medical ID: 8193	Pat. ID: 111360

Bilateral Digital soft tissue mammography with high resolution breast sonography revealed:

Clinical summary: 40-year-old female with negative family history complaining of right breast lump of two months duration.

Findings:

Right breast.

- Heterogeneously dense breast parenchyma that may obscure small lesions. (ACR c)
- Outer breast Multiple irregular speculated high density mass lesions with surrounding distortion and suspicious clusters of pleomorphic microcalcifications seen within.
- Ultrasound demonstrated 7-10 o'clock, multiple irregular spiculated heterogenous hypoechoic solid mass lesions with surrounding echogenic halo, posterior acoustic shadowing and mild internal vascularity on color Doppler study seen at:
  - Index Lesion: 7&8 o'clock, 2 cm from nipple, 3 mm deep to the skin measuring 50 x 12 mm.
  - 9 o'clock, outer & middle third, measuring 11 x 9 mm & 14 x 12 mm.
  - 10 o'clock, 2.7 cm from nipple, 9 mm deep to the skin, measuring 14 x 8 mm.
- Normal skin/nipple/areola complex.
- Two level 1 pathological axillary LNs ,largest measured 16 x 9 mm.
- No pathological infra or supraclavicular lymph nodes.

Left breast.

- Heterogeneously dense breast parenchyma that may obscure small lesions. (ACR c)
- No speculations, masses asymmetry , distortion or suspicious microcalcifications.
- Ultrasound demonstrated No solid or cystic lesions
- Normal skin/nipple/areola complex.
- Non-specific axillary LNs.

Conclusion:-

Right breast (BIRADS 5): Multifocal suspicious process with ipsilateral pathological axillary lymph nodes (level 1).

Left breast (BIRADS 2): Breast adenosis .

Recommendation:-

For CESM , biopsy and histopathological correlation.

Best Regards,
DR, Amal Hegazi, M.Sc.

BIRADS classification of breast lesions according to the American College of Radiology used for breast assessment combined with recommendations:

Category & recommendations	Suspected Cancer Risk
BIRADS 0: Non-informative study.	
BIRADS 1: Normal study, routine screening	0 %
BIRADS 2: Benign findings, routine screening	0 %
BIRADS 3: Probably benign, for close follow up.	2 %
BIRADS 4: Probably malignant, for biopsy.	50 %
A: mild suspicion.	
B: moderate suspicion.	
C: high suspicion.	
BIRADS 5: Malignant, for biopsy.	98-100%
BIRADS 6: Pathologically proven malignant	

Signature Dr. Amal Hegazy

Mammogram
[[DOCTYPE:MAMMOGRAM]]

Name	Mrs. Fatma Sobhi Abd Al-Monaem Mohammed		
		Date	17/9/2025
ID	9925019710	Acc. No.	240265192

^{18}F-FDG PET/CT Scan

Clinical history Indication of the study: Status evaluation study for a case with previous history of suspected right breast focal lesion. No histopathology.

Technique:

- Total body PET scan was done 40 minutes after IV administration of 300 MBq of 18F-FDG.
- CT scanning was performed simultaneously without IV contrast material injection.
- Semi-quantitative analysis would be done for selected ROI.s & the normal threshold would be the normal blood pool liver SUV max.< 2

Previous exams:

- No previous PET-CT study for follow-up.

Head & Neck:

- Normal physiological biodistribution over scanned portion of the brain.
  (N.B; not all brain metastatic lesions could be detected on 18-FDG PET/CT due to physiologic uptake in brain. MRI brain is suggested in cases of clinical suspicion).
- Normal naso-/oro-pharynx, larynx, thyroid and salivary glands.
- No metabolically active cervical lymphadenopathy.

Torso:

Thorax:

- The right breast showed two small adherent rounded metabolic active focal lesions measuring about 2.5 cm with SUVmax.7.4, and another 3rd lesion is also within the right breast measuring 1.2 cm with SUVmax.6.7.
- Metabolic active right axillary lymph node measuring 1.5 cm with SUVmax.8.1. Other smaller low metabolic active adjacent right axillary lymph node.
- Bilateral tracer starved atelectasis and sub-pleural reticulations.
- No FDG hypermetabolic pulmonary nodules or masses seen.
- No enlarged FDG hypermetabolic hilar or mediastinal L.Ns seen.
- No pleural or pericardial effusion seen.
- Cardiac FDG uptake appears physiologic. No FDG-avid vascular abnormalities or metabolic evidence of inflammation.

PET Scan
[[DOCTYPE:PET_SCAN]]

د . هاني أحمد سامي
دكتوراه الأشعة التشخيصية
أستاذ بكلية طب القصر العيني

مركز الطاهرة للأشعة
TAHRA RADIOLOGY CENTER
EST. 1996

د . عصام علي الشيخ
دكتوراه الأشعة التشخيصية
أستاذ بكلية طب القصر العيني

Name	Mrs. Fatma Sobhi Abd Al-Monaem Mohammed		
ID	9925019710	Date	17/9/2025
		Acc. No.	240265192

Abdomen & Pelvis:

- Average size of the liver with non-uniform activity yet no FDG hypermetabolic focal lesions, mostly blood pooling. For dynamic MRI study of the liver assessment if warranted.
- No biliary tree dilatation.
- Average size of the spleen with no focal active lesions.
- Normal appearance of pancreas (no sizable active masses), adrenals and both kidneys.
- No enlarged FDG hypermetabolic abdominal or pelvic L.Ns seen.
- Congested mesentery with strandy reticulations.
- Normal physiological biodistribution over the bowel (non-uniform bowel uptake with no sizable masses) & urinary tracts.

Surveyed skeleton:

- No tracer active lytic or sclerotic osseous lesions seen.
- Faint marrow uptake of SUVmax. 2.5 yet no tracer active lytic or sclerotic osseous lesions seen, likely hematopoietic, for CBC correlation and follow up.

Opinion:

- Right breast multicentric metabolic hyperactive lesions with right axillary metabolic active lymph nodes, for mammographic correlation.
- Rest of the surveyed body is free from any other FDG hypermetabolic neoplastic masses.

Thanks for your referral;

Prof. Dr. Hani Ahmed Sami

Prof. Dr. Essam Ali El-Shiekh

Typed: H.S 20/09/25

Dr. Ahmed Kandeel

MD Nuclear Medicine

PET Scan
[[DOCTYPE:PET_SCAN]]