جوستاف روسي انترناشيونال - مصر (EPE) *

طلب علاج أول مرة / متردد

إسم المريض رباعياً : حياه صلاح عبدالتواب محمد
المحافظة : الفيوم **الحي / المدينة :** يوسف الصديق **العنوان :** حنا حبيب
رقم البطاقة : 27912202303723 **رقم التليفون :** 01111780457 **تاريخ تسجيل الإستمارة :** 21-10-2026
العمر(تاريخ الميلاد) : 20-12-1979 **المهنة :** ربه منزل

الإقرار

أقر انا الموقع أدناه انني لا اتمتع باي نظام علاج مثل:-التأمين الصحي-القوات المسلحه-الشرطة-الهيئات-المؤسسات او اي نظام يتعارض مع نظام العلاج علي نفقة الدولة- وسوف اتحمل كافة نفقات العلاج في حالة ثبوت غير ذلك

الإخصائي الاجتماعي **المقر بما فيه**
التوقيع:(----------) **التوقيع:**(----------)

التشخيص الإكلينيكي : سرطان بالثدي (مبادرة)
نتائج الأبحاث : (مرفق)
التشخيص النهائي : سرطان بالثدي (مبادرة)
خطة العلاج : علاج مبادرة سرطان الثدي علاج الالم ومضادات القئ لمرضي الاورام المنتشر [14456] **قسم العلاج :** الاورام
التعليق على التشخيص : ----------

تقرير اللجنة الثلاثية المتخصصة

الاسم: د/محمد كيلاني **الوظيفة:** ---------- **التوقيع:** ----------
الاسم: د/ندى حسن **الوظيفة:** ---------- **التوقيع:** ----------
الاسم: د/نرمين رمضان **الوظيفة:** ---------- **التوقيع:** ----------

أطلعت اللجنة علي لائحة العلاج الخاصة بالمجالس وتلتزم جهة العلاج بلائحة المجالس الطبية.
كما تقر اللجنة بأن البيانات المدونة فى هذا النموذج صحيحة.

تعتمد صحة البيانات المرفقة
رئيس اللجنة و مدير المستشفي.

تتعهد المستشفى أن لا يتم تنفيذ القرار إلا بعد مراجعة الملف الطبي للمريض وإعادة مناظرة المريض بالمستشفي قبل الصرف.

أعضاء اللجنة

ا.د/ ---------- **ا.د/** ---------- **د/** ---------- **د/** ----------

قرار اللجنة

التشخيص النهائي : ----------
خطة العلاج : ----------
المستشفي : ----------**قسم :** ----------
جهة العلاج : ----------**نفقات :** ----------
ملاحظات : ----------

رئيس	مدير عام	ختم
المجلس الطبي المتخصص	مديرية الشئون الصحية	شعار الجمهورية

Name: حياه صلاح عبدالتواب محمد
National ID: 27912202303723

تقرير طبي

السيد

تحية طيبة وبعد,,

إيماء للطلب المقدم من	**بشأن تقرير طبي للمريض**
بقسم:	**رقم طبي:**

نتشرف بأن نوضح فيما يلي تقريرا عن حالته


تاريخ وساعة الدخول : -- --:-- yyyy-mm-dd	**تاريخ وساعة الخروج :** PM 01:17 05-07-2026

وبعد الكشف والفحوصات والمتابعة وجد انة

المريضة تعاني من ورم غير حميد بالثدى و تحتاج الي Pin Medication And Anti Emetics

التاريخ : **05-07-2026**	**الوقت :** -- --:--
	الطبيب المعالج : د/شيماء لاشين





DNS
هدرسبس وريدى

National ID - Front & Back
[[DOCTYPE:ID_FRONT_BACK]]

Patient Name	:	Request No	: 13009491
Patient No	: 27912202303723	Request Date	: 17/10/2024
Path No.	: SR-1543/24	Verification Date	: 28/10/2024
Sex	: Female	Financial Category	:
Age	: 44 Y	Department	: Out Patient
Referring Doc	:	Registered by	: Mrs.Mayada Hegazy

Pathology Report

Clinical Data: Right breast cancer.

Nature of Specimen: Slide Revision

Gross Examination:
One paraffin block labeled by (6293) and Four slides were received.

Microscopic Examination:
* Histological type: Invasive duct carcinoma.
* Grade (differentiation+ nuclear pleomorphism+ mitosis): Grade II (3+2+1).
* DCIS: No.
* Angioinvasion: No.
* Perineural invasion: No.
* IPT:
- ER: No nuclear reaction of tumor cells (score 0/8).
- PR: Moderate nuclear reaction in 9% of tumor cells (score 4/8).
- Her2: Strong complete membrane reaction in >10% of tumor cells (score 3+).
- Ki67: 30% nuclear reaction of tumor cells.

Diagnosis:
Right breast cancer, Slide revision:
Invasive duct carcinoma, Grade II.
IPT:
- ER: Negative (score 0/8).
- PR: Positive (score 4/8).
- Her2: Positive (score 3+)
- Ki67: Positive in 30% of tumor cells

Verified by :
DR Menna Nabil

CAP
Room No. (9) - First Floor-Building No. 96 - 9th District - Nasr City - Cairo - Egypt

Pathology Report
[[DOCTYPE:PATHOLOGY_REPORT]]

Name: حياه صلاح عبد التواب محمد **MR. :** 3399	

Detailed Medical Report

السيد	

تحية طيبة وبعد,,

إيماء للطلب المقدم من		**بشأن تقرير طبي للمريض**	
بقسم:		**رقم طبي:**	

ننشرف بأن نوضح فيما يلي تقريرا عن حالته

تاريخ وساعة الدخول :		**تاريخ وساعة الخروج :**	

وبعد الكشف والفحوصات والمتابعة وجد انه

WT66 PREM RT BREAST CANCER CT3N3 MX IDC 2 ER-VE PR4/8 HER23+ DIAGNOSED 11/2024 INITIAL CTS BILAT PUL NODULES LARGEST 1.5 REC TAXOTERE HERCEPTIN THEN KEPT ON MAINTENANCE HERCEPTIN FROM 6/2025 FOR C17 HERCEPTIN 400 FOR SM CTS THEN MDT ACC TO RESULTS

MBC (CT AND SM ,,,,PENDING) C18 HERCEPTIN 400 IV (ECHO REQ)

mbc pending mammo and ct cap for c19 herceptin 440 echo ef 64 % on 24/3

MBC FOR C 20 HERCEPTIN 440 MG TODAY - SUPP INCLUDING VIT B12 AS PATIENT HAS SERVERE NUEROPATHY NEXT TWO VISITS AT PHARMACY ON 25/6/2026, 16/7/2026 FOR NEW ECHO REQ

FOR C 22 HERCEPTIN 440 MG NEW ECHO 24/6 EF 65 C23 C24 PHARM PATIENT COMPLAINS OF SEVERE HEADACHE , ONE EPISODE OF DISORIENTATION , WEAKENED MEMORY AND GENERALISED BONY ACHES FOR MRI BRAIN WITH CONTRAST

Pharmacy Visit Wt:68 For C23 Herceptin 408 mg ECHO 24/6 ... 62%

for c24 herceptin iv mri brain 13/8 >> a non enhancing tiny focus of high signal in both thalami, virchow-robin spaces rather than lacunar infarcts are impressive other wise normal

تحريرا في ,

التاريخ :	19-09-2026	**الوقت :**	

الطبيب المعالج : نهي سعيد علي محمد

يعتمد ,

MINISTRY OF HEALTH AND POPULATION
SPECIALIZED MEDICAL CENTER
SOUHAG CANCER CENTER

وزارة الصحة والسكان
أمانة المراكز الطبية المتخصصة
مركز أورام سوهاج

Patient Name	: السيده / حياه صلاح عبدالتواب محمد	Request No.	: 110111582
Patient No.	: 27912202302723	Request Date	: 25/08/2024
Path No.	: 6293/2024	Verification Date	: 05/09/2024
Sex	: Female	Financial Category	: مباشرة
Age	: 55 Y	Department	: مباشرة اورام ثدي - سوهاج
Referreing Doc	: Maro		

Pathology Report

CLINICAL DIAGNOSIS:Right breast UOQ mass.

NATURE OF SPECIMEN:TCNB.

GROSS EXAMINATION: The specimen consists of four tissue cores (1cm long,each), grayish in color, totally submitted in one cassette.

MICROSCOPIC PICTURE: Sections revealed infiltration by atypical epithelial cells arranged in cords and nests, the cells show pleomorphism, hyperchromatic nuclei and rare mitosis, the stroma is desmoplastic.

DIAGNOSIS:labelled as right breast UOQ mass, TCNB;
- Features of invasive duct carcinoma, NST, grade II.
- No ductal carcinoma in-situ component could be detected in examined section.

Signature:
Pathologist.Dr.Ghade Mostafa.
Dr:Cherry Gamal.

N.B : Specimens received at the department of pahology are examined and sampled for diagnostic purposes.The specimens are normally held for four weeks and then disposed. A request for return of the specimens must be made at the time of surgery or within four week

سوهاج : شارع كورنيش النيل القبلي مدينة سوهاج الطبية - تليفون : ٠٩٢٢١١٠٩٠١ ؛ ٠٩٢٢١١٠٩٠٧ - فاكس : ٠٩٢٢١١٠٦٠٢
E-MAIL : AWRAM2017@GMAIL.COM

Pathology Report
[[DOCTYPE:PATHOLOGY_REPORT]]

Patient Name	السيده / حياه صلاح عبدالتواب محمد	Request No.	110116124
Patient No.	27912202302723	Request Date	07/09/2024
Path No.	6694/2024	Verification Date	25/09/2024
Sex	Female	Financial Category	مباشرة
Age	55 Y	Department	مباشرة اورام ثدي - سوهاج
Referreing Doc	م		

Pathology Report

Conclusion:
-ER: (negative).
-PR: (negative).
-HER2/neu protein over expression: Positive (SCORE 3+).
-Ki67: the proliferation index of the tumor is 28%

Signature
Pathologist.Dr: Ahmad Roshdi

سوهاج : شارع كورنيش النيل القبلي مدينة سوهاج الطبية - تليفون : ٠٩٣٢١١٠٩٠١ ; ٠٩٣٢١١٠٩٠٧ - فاكس : ٠٩٣٢١١٠٦٠٣
E-MAIL : AWRAM2017@GMAIL.COM

Pathology Report
[[DOCTYPE:PATHOLOGY_REPORT]]

Patient Name	: الأستاذه / حياه صلاح عبد التواب محمد	Request No.	: 13007120
Patient No.	: 27912202303723	Request Date	: 09/10/2024
Path No.	: 3830/24	Verification Date	: 24/10/2024
Sex	: Female	Financial Category	: اورام دار السلام - نفقة الدولة
Age	: 44 Y	Department	: Out Patient
Referreing Doc.	:	IHC No.	:
		Registered by	: .marwa mohamed yousse

IMMUNOHISTOCHEMISTRY REPORT

Clinical Data: Right breast malignant looking solid mass lesion.
Nature of Specimen: Tru-cut biopsy.

Technique:
- Sections were prepared from the paraffin block, processed in Bench Mark ULTRA machine (Ventana) and stained by rabbit monoclonal antibodies using ultra view HRP DAB as chromogen and hematoxylin as counter stain. The sections treated against
- ER clone (1E2), PR clone (SP1), Her2 clone (4B5), & Ki67 clone (30-9).

Results:
- IPT (Positive control showed appropriate reactivity).
- ER: No nuclear reaction of tumor cells (score 0/8).
- PR: Weak nuclear reaction in 10% of tumor cells (score 3/8).
- Her2: Strong complete membrane reaction in >10% of tumor cells (score 3+).
- Ki67: 30% nuclear reaction of tumor cells.

Conclusion:
Right breast malignant looking solid mass lesion., Tru-cut biopsy:
Invasive duct carcinoma, Grade II.
IPT:
- ER: Negative (score 0/8).
- PR: Positive (score 3/8).
- Her2: Positive (score 3+).
- Ki67: Positive in 30% of tumor cells.

* Scoring system: "ER, PR"
ASCO-CAP ER/PR Test Guideline Recommendations: proportion of cells staining (0, no staining; 1,

Verified by :
Dr.Heba Hasan

Immunohistochemistry
[[DOCTYPE:IHC]]

Patient Name	الأستاذة / حياء صلاح عبد التواب محمد	Request No.	13007120
Patient No.	27912202303723	Request Date	09/10/2024
Path No.	3830/24	Verification Date	24/10/2024
Sex	Female	Financial Category	اورام دار السلام - تكلفة الدولة
Age	44 Y	Department	Out Patient
Referreing Doc.		Registered by	.marwa mohamed youss

IMMUNOHISTOCHEMISTRY REPORT

>1%; 2, between 1% and 10%; 3, between 11% and 33%; 4, between 34% and 66% and 5, between 67%-100% of the cells staining). Intensity of positive tumor cells (0, none; 1, week, 2, intermediate; and 3, strong). Total score from 0 to 8.

* Scoring system: "Her2"

Reference: ASCO-CAP Her2 Test Guideline Recommendations, 2013.IHC 0: as defined by no staining observed or membrane staining that is incomplete and is faint/barely perceptible and within < 10% of the invasive tumor cells. IHC 1+: as defined by incomplete membrane staining that is faint/barely perceptible and within < 10% of the invasive tumor cells. IHC 2+: based on circumferential membrane staining that is incomplete and/or weak/moderate and within < 10%of the invasive tumor cells or complete and circumferential membrane staining that is intense and within < 10% of the invasive tumor cells. IHC 3+: based on circumferential membrane staining that is incomplete, intense < 10% of tumor cells.

Signature
Dr. Walaa Ghonim.
Dr. Sagda Elkady

Verified by :
Dr.Heba Hasan

... Room No. (4) - First Floor-Building No. (67)- Nile Corniche - Misr El Qadeem - Cairo, Egypt

Immunohistochemistry
[[DOCTYPE:IHC]]

حياه صلاح عبدالله

ECHO REPORT

Name:

Date: ١ / 9 / 2025

EF	64%	55-75%	PWT	0.8	0.6-1.1cm
LVEDD	4.5	3.5-5.8cm	AO.R	2.3	2-3.7cm
LVESD	2.3	2-4cm	LA	3.8	2-4cm
FS	28%	25-45%	RV		0.7-2.3com(supine)
SWT	0.9	0.6-1.1cm	AO.CUSP		1.5-2.6cm

LV dimensions Normal
LV wall thickness Normal
LV diastolic function Normal
SWMA No RWMA
LA and Ao root dimensions Normal
Mitral Valve
Aortic valve N
Tricuspid valve N
Pulmonary valve
Right side and systolic function TAPSE: 2.5
Intracardiac masses and effusion

Dr / طارق

Presidential Program for Women's Health
Ministry of Health and Population

البرنامج الرئاسي لصحة المرأة
وزارة الصحة والسكان

MDT form

A-Patient ID:

1- Name : حياه صلاح عبد التواب محمد

Sex: Female

3- Medical number: 83235540

Old Med :

2-ID number:

Patient Age : 45 Y

3392-2024

Family history	-ve	Phone	01156263371	BMI		REASON OF MDT	
marital status		NRS Score		GROUP		Date of MDT	18/11/2024
Co morbidity	-ve	Menopausal status		Initial STAGE			

Clinical data

Breast Imaging :
rt breast mass UOQ with microcalcification 3.3x3 at 1 oclock

Mets Workup :
suspected pulmonary nodules

BX	ER	PR	Her 2 Neu	SISH	KI67
IDC	0/8	4/8	3		30
BX COMMENT: rt II	ER COMMENT:	PR COMMENT:	Her 2 Neu COMMENT:	SISH COMMENT:	

T	N	M
cT3	N3c SC	1 lung

Sonomammography

PATIENT HISTORY
Echo, labs

MDT OUTCOME & PLAN

MDT OUTCOME & PLAN
For 1st line Taxotere/Herceptin IV

SIGNATURE

MEDICAL ONCOLOGY	MEDICAL ONCOLOGY	RADIOLOGY	RADIOLOGY
SURGERY	SURGERY	PATHOLOGY	PATHOLOGY
Psychiatric	Psychiatric	Nutrition	Nutrition

MDT Form
[[DOCTYPE:MDT_FORM]]

جوستاف روسي

Patient's Name:	**Hayah Salah Abdeltawab**
Date:	**2026-04-08**
Referred by:	Prof.Dr. CAPwithC
Hospital:	**Goustave Roussey International Egypt**

MULTISCLICE POST CONTRAST C.T. EXAMINATION OF THE CHEST, ABDOMEN AND PELVIS REVEALED:

Known case of breast CA.

I- CHEST:

- Right breast lesion measuring 17 x 15 mm for sono-mammography.
- No pulmonary nodules, masses or cavitary lesions.
- Few bilateral scattered atelectatic bands.
- No consolidation or collapse.
- No hilar or mediastinal masses or lymph node enlargement.
- No pleural or pericardial collection.
- Normal CT appearance of the heart and great vessels.
- Left thyroid lobe hypodense nodule measuring 27 x 18 mm for sonography.

II- ABDOMEN AND PELVIS:

- Enlarged liver showing diffuse low parenchymal attenuation. No hepatic focal lesion or dilated biliary radicles.
- Both kidneys are normal site, average sized and showing smooth regular cortical outline and preserved parenchymal thickness and function. No stones or back pressure changes.
- Normal C.T appearance of the spleen, pancreas, suprarenal glands, aorta and IVC.
- The urinary bladder shows no evidence of gross masses or diverticulae or stones.
- Normal appearance of the pelvic organs with no pelvic masses or collections.
- Multiple subcentimetric para-aortic and bilateral external iliac lymph nodes largest measuring 17 mm at the left external iliac group.
- No ascites.
- L3 vertebral body small sclerotic area.

CT Scan
[[DOCTYPE:CT/SCAN]]

ROUSSY
INTERNATIONAL
EGYPT

Patient Name: Hayat Salah Abd Al Tawab Mohamed	Date : 09/11/2025
Exam : CT CAP+C (CT Chest Abd. Pelvis)	Age : 46 Year(s)
Medical ID: 3392/2024	Pat. ID: 93679

POST-CONTRAST CT SCAN OF THE CHEST , ABDOMEN AND PELVIS : .

Findings: As compared to last study dated 23/6/2025, the current study revealed

CHEST

- **Right breast speculated nodule 15 x 12 mm .**
- **Prominent bilateral axillary lymph nodes .**
- **Still noted tiny nodule 3mm is seen at right upper lobe with small patch of ground glass attenuation likely reactive.**
- No hilar or mediastinal lymph nodes.
- No evidence of pleural effusion, pleural thickening or masses seen.
- Normal cardiac size and shape with no gross abnormality of the cardiac chambers. No pericardial effusion detected.
- Normal appearance of the thoracic aorta and the great vessels.
- **N.B: still noted large left thyroid nodule.**

Abdomen & pelvis

- **Mild enlarged liver showing homogenous density.**
- * Average size spleen , no focal lesions.
- *Average size gall bladder , no gall stones.
- *No dilated intra or extra-hepatic bile ducts .
- *Patent main portal vein trunk and both branches.
- *Urinary bladder shows no masses or stones.
- *Normal C.T. appearance of the pancreas , adrenal glands, both kidneys ,bowel loops & other pelvic organs.
- *No retroperitoneal lymphadenopathy .
- *No ascites .
- ***Examined skeleton***
-

Opinion:

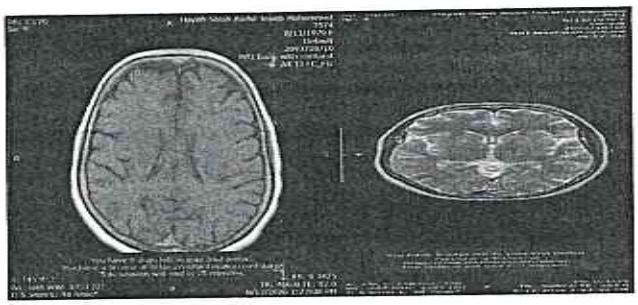
- ***Right upper lobe tiny nodule for follow up.***
- ***Hepatomegaly , no focal lesions.***

DR/Reham khedr...MD

CT Scan
[[DOCTYPE:CT_SCAN]]

جوستاف روسي انترناشونال

Patient's Name:	**Hayah Salah Abdul Tawab Mohammed**
Date:	**2026-08-13**
Referred by:	Prof.Dr. **no doctor**
Hospital:	**Goustave Roussey International Egypt**



MRI EXAMINATION OF THE BRAIN

MRI Technique:

- Axial T1, T2 and FLAIR WI's
- Sagittal T1WI
- Coronal T2 WI
- Axial DWI and ADC
- Axilal,sagittal,coronal T1WIs with contrast.

MR findings:

- Prominance of CSF-containing structures.
- A tiny focus of high signal is seen only on T2WIs in both thalami with no evidences of either enhancement or diffusion restriction.
- No other foci cerebral, cerebellar or brain stem areas of altered MR signal or abnormally-enhancing focal lesions.
- No midline shift or deformity .
- No intra,or extra axial collections or masses.
- No abnormally-enhancing cerebello -pontine angle masses.
- No gross posterior fossa abnormalities.
- Intact cervico medullary junction.
- Normal the cranial vault bones and the subgaleal tissue.No fracture lines or subgaleal collections.
- **Cuts taken in the para-nasal sinuses revealed mild ethmoidal sinusitis.**
- **Cuts taken in the orbits/sellar and para-sellar regions are unremarkable.**

IMPRESSIONS:

جوستاف روسي

Patient's Name:	**Hayah Salah Abdul Tawab Mohammed**
Date:	**2026-08-13**
Referred by:	Prof.Dr. **no doctor**
Hospital:	**Goustave Roussey International Egypt**

- **Mild brain involusional changes.**
- **A non-enhancing tiny focus of high signal in both thalami,Virchow-Robin spaces rather than lacunar infarcts are impressive. For clinical check up.**
- **Otherwise,normal brain MRI with contrast.**

Prof/Hanan El-Ahwal.