Journal of the American Academy of Orthopaedic Surgeons Advance Access, published on February 9, 2015 as doi:10.5435/JAAOS-D-13-00148
The latest version is at http://hwmaint.jaaos.org/cgi/doi/10.5435/JAAOS-D-13-00148

Review Article

Tennis Injuries: Epidemiology, Pathophysiology, and Treatment

Joshua S. Dines, MD
Asheesh Bedi, MD
Phillip N. Williams, MD
Christopher C. Dodson, MD
Todd S. Ellenbecker, DPT
David W. Altchek, MD
Gary Windler, MD
David M. Dines, MD

Abstract

Tennis places high loads on the joints of players, with supraphysiologic forces being generated at the shoulder and elbow hundreds of times per match. Acute injuries tend to affect the lower extremity; chronic injuries usually involve the upper extremity. Commonly encountered upper extremity conditions include rotator cuff injury, internal impingement, superior labral tears, and epicondylitis of the elbow. Serving is the most strenuous stroke in tennis, with the highest peak muscle activity in the shoulder and forearm occurring during this stroke. The kinetic chain links upper extremity, lower extremity, and core muscle segments by transmitting coordinated activation and motion; in this regard, any pathologic process that disturbs the groin, hip, and abdominal musculature can further result in an increased risk of injury to the shoulder and upper extremity. Evolution in equipment and in play surfaces has also affected the type and frequency of injuries. Prevention programs that address the muscular imbalances throughout the kinetic chain may help reduce the incidence of both acute and chronic injuries experienced by tennis athletes.

Tennis is one of the most popular sports in the world. Unlike many sports, the duration of actual play during a match is not determined by any time limit. Thus, matches can last for several hours, requiring hundreds of short, explosive bursts of energy.[1] The aerobic and anaerobic requirements of tennis, combined with the variety of strokes, result in a unique profile of injuries.[2] As in many overhead sports, the shoulder and elbow can be adversely affected by the repetitive trauma of chronic overuse; acute injuries tend to involve the lower extremities.

Kinetic Chain

High ball velocities and racquet positioning place large loads on the joints of tennis players,[3] with supraphysiologic forces being generated at the shoulder and elbow hundreds of times per match. To minimize the load to each joint, a player must make efficient use of the kinetic chain, particularly on power shots such as the serve, overhead smash, and groundstrokes. The tennis serve has been divided into five phases: (1) wind-up (knee flexion, trunk rotation), (2) early cocking, (3) late cocking (maximal abduction, external rotation), (4) acceleration, and (5) follow-through[4,5] (Figure 1). Serving is the most strenuous stroke in tennis, with the highest peak muscle activity in the shoulder and forearm occurring during this stroke.[4] The muscle segments and forces linked by the kinetic chain start with the feet and knees and travel from the lower extremity through the core (trunk/back) to the shoulder and elbow, ending at the wrist, hand, and

From the Hospital for Special Surgery, New York, NY (Dr. Joshua S. Dines, Dr. Williams, Dr. Dodson, Dr. Altchek, Dr. David M. Dines), Domino's Farms, University of Michigan, Ann Arbor, MI (Dr. Bedi), Physiotherapy Associates Scottsdale Sport Clinic, Scottsdale, AZ (Dr. Ellenbecker), and the Association of Tennis Professionals, Ponte Vedra Beach, FL (Dr. Windler).

J Am Acad Orthop Surg 2015;0:1-9

http://dx.doi.org/10.5435/JAAOS-D-13-00148

Copyright 2015 by the American Academy of Orthopaedic Surgeons.

Copyright © the American Academy of Orthopaedic Surgeons. Unauthorized reproduction of this article is prohibited.

Figure 1

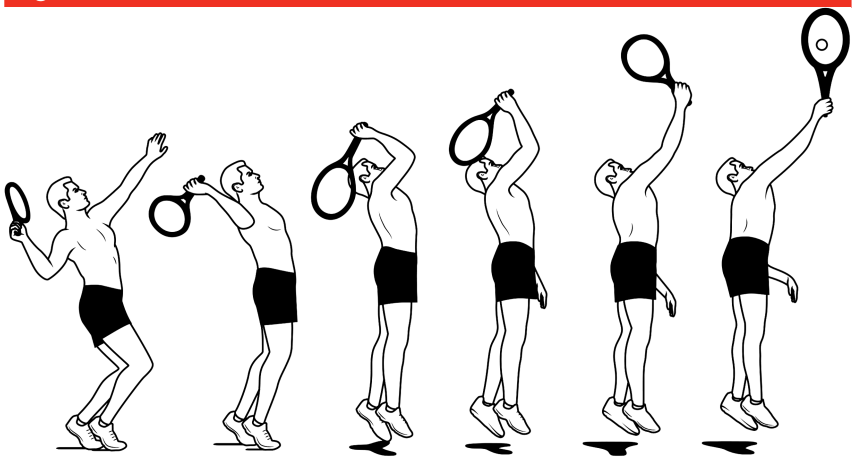

The phases of the tennis service motion.

ultimately the raquet.[3] Kibler[6] calculated that the leg-hip-trunk link produces 51% of the total kinetic energy. Breakdowns at a given point in the chain can result in injury at that point or manifest as an injury further down the chain. Elliott et al[4] analyzed shoulder and elbow joint loading among elite players at the 2000 Olympic Games. As serving speed increased, loading of the shoulder and elbow increased. However, players with more effective knee flexion and extension during the service motion experienced lower loads in the upper extremity, specifically elbow valgus loading and anterior shoulder stress.

Tennis-specific conditioning exercises of the important muscle segments help integrate the kinetic core to ensure injury-free competition. These exercises include squats for leg strengthening, to recruit power generation, and load absorption; trunk rotations; scapular stabilization; and shoulder and wrist co-contractions.[7,8]

Epidemiology of Injuries

A comprehensive meta-analysis of players among all levels by Pluim et al[2] reported an injury incidence range of 0.04 injury to 3.0 injuries per 1,000 hours played. Several studies have concluded that the lower extremity is most commonly injured (31% to 67%), followed by the upper extremity (20% to 49%), and lastly the trunk (3% to 21%).[2,9,10] In the lower extremity, the ankle and thigh are the most frequently injured; the shoulder and elbow showed the highest frequency in the upper extremity, and the low back is the most commonly injured body part in the central core.[10] Muscle strains were the most common type of injury, followed by inflammation and sprains.

Equipment

Over the past 30 years, racquets have changed from heavy, wood models weighing about 400 g to larger, lighter, and stiffer graphite composite models that weigh about 250 g.[11] Larger racquet head sizes allow the ball to be hit away from the central axis of the racquet; this generates a higher torque of the racquet in the hand. Consequently, this torque must be opposed by eccentric loading of the forearm muscles, which may induce microtrauma to the extensor muscles of the wrist and possibly cause tennis elbow.[11] String technology has also undergone significant change over the years.

These newer racquets and strings have improved performance through faster racquet head and ball speeds and increased ball spin; however, it is possible that these equipment changes may also be associated with increased injury rates. For example, the increase in stiffness in the racquet and strings results in increased vibration transmitted to the arm. The racquet at ball contact creates a moment that acts on the wrist extensor muscles, which stabilize the joint. The magnitude of this moment depends on where the ball strikes the string area. There are three "sweet spots" in a tennis

Dr. Joshua S. Dines or an immediate family member has received royalties from Biomet; is a member of a speakers' bureau or has made paid presentations on behalf of Arthrex; and serves as a paid consultant to Arthrex and ConMed Linvatec. Dr. Bedi or an immediate family member serves as a paid consultant to Pivot Medical and Smith & Nephew; has stock or stock options held in A3 Surgical; and serves as a board member, owner, officer, or committee member of the American Orthopaedic Society for Sports Medicine. Dr. Ellenbecker or an immediate family member serves as an unpaid consultant to the Hygenic Corporation. Dr. Windler or an immediate family member has stock or stock options held in Stryker. Dr. David M. Dines or an immediate family member has received royalties from Biomet; serves as a paid consultant to Biomimetic and Tornier; has received nonincome support (such as equipment or services), commercially derived honoraria, or other non-research–related funding (such as paid travel) from Biomet and Tornier; and serves as a board member, owner, officer, or committee member of American Shoulder and Elbow Surgeons. None of the following authors or any immediate family member has received anything of value from or owns stock in a commercial company or institution related directly or indirectly to the subject of this article: Dr. Williams, Dr. Dodson, and Dr. Altchek.

racquet: (1) the center of percussion, (2) the location on the strings where the highest rebound velocity occurs, and (3) the location of the impact that leads to low, smooth oscillations at the grip. Tennis players attempt to hit the ball at the center of all three sweet spots, and expert players are able to hit this location most consistently, thereby minimizing loads on the wrist and arm.[12] Segesser[13] suggested that racquet oscillations ranging from 80 to 200 Hz may contribute to the development of tennis elbow. Thus, vibration, in addition to racquet torque and "shock" to the arm, have all been implicated as causes of tennis elbow.[14]

Hand grip positions appear to affect the overall biomechanical loads transmitted to the upper extremity as well as stroke biomechanics. The four traditional grip positions for the forehand stroke are the semiwestern, full western, eastern, and continental.[15] In a study by Tagliafico et al[16] of 370 nonprofessional tennis players, ulnar-sided injuries (eg, extensor carpi ulnaris tendinitis, triangular fibrocartilage complex pathology) were significantly associated with western or semiwestern grips; radial-sided injuries (eg, flexor carpi radialis tendinitis, DeQuervain tendinopathy, intersection syndrome) were common with the eastern grip. Furthermore, it has been shown that reduced grip forces decrease the vibration load on the arm and thus may prevent tennis elbow.[12]

Tennis ball composition has remained largely unchanged over time. However, modern balls are more resistant to compression during impact with a racquet or surface. Because of the numerous brands of tennis balls used by professionals, it is difficult to identify a relationship between balls and injury.[11]

Play Surfaces

Unlike most sports, tennis is played on a variety of surfaces, including clay, grass, and acrylic (or hard) courts. Clay is considered a slow surface because there is more friction at the ball-surface interface, resulting in a larger loss of ball speed on contact with the court.[14] On hard courts, the faster speed of the ball subjects the upper extremity to more force. To date, however, there is little evidence linking surface with type or frequency of injury; however, Nigg and Yeardon[17] have shown that muscles are sensitive to surface stiffness and that frequently playing on different surfaces may be associated with injuries in the lower extremity.[9,14]

Shoulder Injuries

Tennis players often develop increased glenohumeral external rotation in the dominant shoulder at the expense of internal rotation.[18] Elliott[19] delineated the importance of shoulder internal rotation during both serves and forehand groundstrokes. In a study of baseball players, Myers et al[20] showed that pathologic glenohumeral internal rotation deficit is associated with internal impingement. Internal impingement was defined in collegiate baseball players as the mechanical abutment of the articular side of the posterior supraspinatus and anterior infraspinatus tendons against the posterosuperior aspect of the glenoid rim and labrum that occurs during the late cocking phase of throwing.[21] Similarly, tennis players can exhibit internal impingement during the late cocking phase of serving. Its etiology is controversial and beyond the scope of this review, but authors do agree that it exists as a spectrum of pathology that includes superior labrum anterior-to-posterior (SLAP) tears and rotator cuff tears as a result of repetitive overhead motions.[22] Rotator cuff tears can range from articular-sided fraying to full-thickness tears, while labral pathology ranges from mild fraying to displaced, unstable SLAP lesions. Although not as common, these unstable SLAP lesions can cause shoulder instability symptoms or biceps tendinitis.

Tennis players with internal impingement typically report pain during the service motion and overheads, although it may occur during their groundstrokes (Table 1). They frequently describe posterior shoulder pain, but anterior pain and mechanical symptoms may occur, as well. Occasionally, pain is accompanied by apprehension and a feeling of instability. On physical examination, the clinician should try to elicit signs of outlet or "external" impingement, as well as test the strength of the rotator cuff muscles. Several tests have been described to diagnose superior labral pathology, although no one test is reliably both sensitive and specific.[23] A recent article by Oh et al[24] found that positive O'Brien, Speed, and apprehension testing with the arm abducted about 90° and maximally externally rotated is 75% sensitive and 90% specific for diagnosing SLAP tears. Another test, known as the modified dynamic labral shear, is performed with the arm flexed 90° at the elbow, abducted in the scapular plane to above 120°, and externally rotating to tightness. A shear load is then applied to the joint by maintaining external rotation and horizontal abduction and lowering the arm from 120° to 60° abduction. A positive test is indicated by reproduction of the pain and/or a painful click or catch in the joint line along the posterior joint line between 120° and 90° abduction.[25] Kibler et al[25] found that this test was 72% sensitive, 98% specific, and 84% accurate in detecting labral pathology.

MRI is particularly useful for diagnosing pathologies associated with internal impingement. The ABER (abduction/external rotation) view simulates the contact between the rotator cuff and posterior glenoid rim in

Table 1

Injuries by Anatomic Region

Anatomic Region and Injury	Mechanism
Shoulder	
Internal impingement	Repetitive overhead motions
SLAP tears	Repetitive overhead motions
Elbow	
Lateral elbow tendinopathy	Backhand strokes with wrists flexed
Medial elbow tendinopathy	Excessive wrist snap on serves and forehand strokes, open-stance hitting, short-arming strokes
Wrist	
Extensor carpi ulnaris tendinitis	Ulnar deviation in nondominant wrist during two-handed backhand
Extensor carpi ulnaris subluxation	Sudden volar flexion ulnar deviation stress from hitting low forehand
Abdomen	
Abdominal muscle strain	Uncoiling and flexing of trunk during overhead serve
Low Back	
Lumbar strain	Change in intensity or duration of play, or change in stroke technique
Lumbar disk degeneration and herniation	Rotational forces and hyperextension during serve

SLAP = superior labrum anterior-to-posterior

the late cocking phase and may reveal partial-thickness rotator cuff tears.[26]

The mainstay of treatment of internal impingement is nonsurgical and focuses on restoration of normal range of motion (particularly internal rotation) and posterior rotator cuff and scapular muscle strength.[27] Correction of associated scapular dyskinesia, when present, is imperative. If nonsurgical management fails, arthroscopic surgery can be used to treat labral and/or rotator cuff tears. Sayde et al,[28] in a recent systematic review on return to play after type II SLAP repairs in throwing athletes, reported that 73% of all athletes were able to return to their previous levels of play, whereas only 63% of overhead athletes returned to their previous levels of play. None of these athletes, however, included tennis players. Rotator cuff tears, when present, should be treated based on the depth of the tear. Conway[29] reported the results of intratendinous tears in baseball players and found that 89% of patients were able to return to their previous level of play. In this study, all patients had some degree of associated labral pathology, which was treated concomitantly.

Elbow Injuries

Common elbow injuries in tennis players include lateral epicondylitis and flexor-pronator tendinitis. Lateral elbow tendinopathy (ie, tennis elbow) affects recreational players more commonly than it does professionals. Novice tennis players tend to hit their backhand strokes with their wrists in a more flexed position, whereas high-level players have an increase in wrist extension just before ball contact.[30] Less experienced players exhibit substantial eccentric contractions of the extensor muscles, causing the repetitive microtrauma seen in tennis elbow[30,31] (Table 1).

In contradistinction to lateral elbow tendinopathy, medial elbow tendinopathy is more common in high-level tennis players than in novices. The most common sites of involvement are tendinosis in the pronator teres and flexor carpi radialis muscles.[32] Possible causes include excessive wrist snap on serve and forehand strokes, open-stance hitting, and short-arming strokes[4] (Table 1).

Diagnosis is made by physical examination, although MRI can confirm the diagnosis. Tenderness over the affected epicondyle, pain and/or weakness with resisted wrist extension and forearm supination with lateral elbow tendinopathy, or pain and/or weakness with wrist flexion and forearm pronation in medial elbow tendinopathy are classic findings.

Most patients with elbow tendinopathy respond well to rest and physical therapy, including stretching and eccentric strengthening. Local modalities, such as cross friction massage and electrical stimulation, are often added. A trial of a larger racquet grip size and evaluation of technique can also be important in the nonsurgical management of this condition. Counterforce bracing can be effective when athletes return to play.[33,34] Recalcitrant cases may warrant a corticosteroid injection. Although studies have generally shown no long-term benefit with regard to tendon healing, a corticosteroid injection can substantially reduce acute symptoms. The benefits of treatments such as platelet-rich plasma are less clear at this time.[35]

When nonsurgical management fails, surgery can be successful in most cases.[34,36] Both arthroscopic and open approaches have been described; elimination of the pathologic angiofibroblastic tissue and/or repair of the tendon origin is a critical component of any surgical approach.

Rehabilitation and prevention programs for the elbow in tennis players emphasize strength and endurance exercises for the entire upper extremity

kinetic chain. In elite players, research has shown increases of as much as 20% to 30% in elbow extension, wrist flexion/extension, and forearm pronation strength in the dominant arm compared with the nondominant arm.[37]

Wrist Injuries

Tennis players are susceptible to overuse injuries to the wrist. Extensor carpi ulnaris (ECU) tendinitis is common in both the dominant and nondominant wrists due to the forearm and two-handed backhand, respectively, because the wrist is often in more ulnar deviation during these strokes[38] (Table 1). Treatment entails splinting, rest, NSAIDs, corticosteroid injection into the sheath, and technique modification.

Subluxation of the ECU tendon, although not truly an overuse syndrome, is an important differential diagnosis in the tennis player with ulnar wrist pain. Subluxation of the ECU results from rupture or attenuation of the ECU subsheath caused by a sudden volar flexion and ulnar deviation stress, such as hitting a low forehand[38] (Table 1). Diagnosis can be made by having the athlete actively ulnarly deviate the wrist in full supination, observing the ECU tendon subluxating ulnarward over the styloid. Acute injuries should be immobilized with the wrist pronated and dorsiflexed.[39] Reconstruction of the subsheath may be performed in chronic cases.

Abdominal and Groin Injuries

Abdominal muscle strain is one of the most common injuries related specifically to tennis players because the abdominal musculature plays a significant role in the service motion.[40] These debilitating injuries can give rise to prolonged periods of discomfort and withdrawal from competition due to the athlete's inability to serve effectively. Trunk rotation plays a critical role in generating power in tennis and other overhead sports, such as baseball, golf, cricket, and Olympic throwing events.[41,42] In the overhead service motion, the trunk is initially extended and rotated to create the potential energy necessary to generate a forceful serve. The uncoiling and flexing of the trunk is then initiated by the rectus abdominus, contralateral internal and external obliques, and iliopsoas muscles, while the gluteal muscles drive the core and take load off the abdominals.[43] Any asynchrony in the evolution of these events can result in a painful strain or frank tearing of any one of these muscles[44] (Table 1).

The diagnosis of abdominal muscle injuries in tennis players is usually straightforward. The common presenting history is acute lower abdominal pain, more commonly on the side opposite the serving arm, which is exacerbated by playing and is most pronounced during the serving motion. The pain frequently lessens soon after the injury, prompting the athlete to prematurely reattempt sports participation, which leads to a recurrence of the pain with worsening and prolongation of the symptoms. With repeated injury, the athlete may begin to have pain with daily activity.

Physical examination should begin with inspection, abdominal palpation, and auscultation in the athlete with acute abdominal pain to differentiate between peritoneal irritation and muscle strain. Passive range of motion of the hip should be assessed to rule out primary hip pathology. Additionally, the usual tension signs associated with a herniated nucleus pulposus should be assessed to rule out femoral nerve involvement. Finally, the clinician should check for an inguinal hernia and, when in doubt, consult the services of a general surgeon. The most provocative test for an abdominal strain is a resisted sit-up, although this test can also be positive in the case of an inguinal hernia or posterior inguinal wall weakness.

Plain radiographs are typically nondiagnostic but may occasionally demonstrate an avulsion injury. MRI and diagnostic ultrasonography are now commonly used to identify the exact muscle injured and to determine the severity of injury.[42] When stress fracture or osteitis pubis is suspected, a bone scan can help confirm the diagnosis.

Treatment of acute abdominal or groin strains generally requires a minimum rest of 1 to 2 weeks from all strenuous activities. Even walking may be difficult at first and can require the assistance of crutches. The use of ice and oral NSAIDs may be of benefit in reducing inflammation and pain. Once the acute phase of the process has abated, a gradual program of stretching should be initiated. As with virtually all muscle strains, stretching should precede any efforts at strengthening. Although isometric strengthening is usually the first phase of any reconditioning program, we have found that isotonic exercises are more appropriate initially because isometric exercises tend to produce more pain due to the intensity of the contraction. Before the athlete can return to play, an aerobic conditioning program, including bicycling and swimming, should be completed. Once the athlete has demonstrated toleration of such activities with little or no pain, a progressive return to tennis can ensue. It is not unusual for symptoms to persist for ≥6 months; therefore, athletes and clinicians alike should allow ample time for recovery and permit gradual return to play only when pain is minimal.

Low Back Injuries

Low back pain is common in tennis players. In one report, 38% of 143

professional tennis players missed a tennis tournament because of low back pain.[45] Forty-three players reported chronic low back pain, and 11 of 38 players with acute injuries (29%) had injuries to the lumbosacral spine. The high prevalence of low back pain in tennis players is not surprising given the large loads in axial rotation. The repetitive nature of the sport can fatigue supporting structures of the lumbar functional unit and overwhelm viscoelastic protective mechanisms of the intervertebral disks and ligaments. Additionally, low back pain can lead to tight hamstrings and limited hip rotation in athletes.[46] As a result, common low back injuries seen in tennis include paraspinal muscle strain, ligament sprain, and injury to the lumbar disk. These injuries are more likely the result of repetitive microtrauma rather than a single, major traumatic event.

Lumbar Strain

The most common back injury in tennis players is acute lumbar strain. Typically it presents as unilateral or bilateral low back pain, often with painful paraspinal muscle spasms. Frequently, there is a history of a change in the duration or intensity of play or a recent change in stroke technique (Table 1). Pain typically is localized to the back and is not accompanied by radicular symptoms. Physical examination generally elicits tenderness over the paraspinal muscles, and lumbar flexion may be limited due to paraspinal and hamstring muscle spasm. Lumbar extension usually is not pain limited; therefore, if pain with extension is severe, then other diagnoses, such as spondylolysis and disk or facet disease, should be considered. Straight-leg raise often reveals taut hamstrings but is negative for radicular symptoms. A neurovascular examination should be normal.

Lumbar Disk Degeneration and Herniation

The stroke that places the greatest stress on the lower back is the serve. The repetitive rotational forces applied to the lumbar spine, especially when coupled with hyperextension, places the lumbar disk at an increased risk for annular tears (Table 1). As a result, it is very common for tennis players to develop lumbar disk degeneration and herniation. Although it is possible for an acute lumbar disk herniation to occur from a sudden overload of the intervertebral disk with a subsequent annular tear, the process is typically more gradual and results from repetitive microtrauma.

Patients with a degenerative and/or herniated disk may present with back pain, leg pain, or both. If it is an acute herniation, the player usually recalls the sudden onset of low back pain. In more chronic cases, there may be a history of episodic sudden low back pain for a period of days, with intervening asymptomatic periods.

On physical examination, the athlete may exhibit a lumbar list, with spinal curvature concave to the painful side. Lumbar flexion is usually pain limited; likewise, lumbar extension is usually pain free as long as the facets are not compromised. Straight-leg raising is usually positive ipsilateral to the painful side. Motor, sensory, and reflex abnormalities depend on the extent and duration of nerve root involvement.

When disk pathology is suspected, plain radiographs and MRI scans should be obtained. Plain radiographs can rule out fracture and may show spondylolisthesis or subtle instability with dynamic flexion-extension views. MRI is the benchmark to confirm the diagnosis and can demonstrate acute, subacute, and chronic disk changes. Additionally, the spinal canal, neural foramen, and nerve roots can be evaluated for pathology.

Initial management includes rest and analgesia control with NSAIDs. Physical therapy (ie, trunk and abdominal flexibility, strengthening exercises) must also focus on unloading the lumbar disk. Lumbar stabilization techniques, which improve an athlete's awareness of his or her lumbar spine during all body positions and exercise routines, is important.

Return to play is variable and depends on the size and location of the disk herniation, degree of degenerative changes, and severity of any neurologic changes. It is mandatory that an athlete not return to play before becoming symptom free. Generally, these injuries can be successfully managed nonsurgically. Surgery is indicated only in players who have motor paralysis, bladder dysfunction (ie, cauda equina syndrome), or persistent pain that fails to respond to nonsurgical management.

Preventive conditioning strategies for these injuries include extensive core stability training. Imbalances in the trunk extension:flexion ratio may be responsible for the propensity for lumbar spine injuries in these athletes.[47,48] Therefore, both the flexors and extensors should be trained to ensure balanced muscle development. Additionally, rotational exercises should be a focus because of the predominance of trunk rotation required in all tennis strokes. It is important to train core musculature in all three planes (sagittal, frontal, and transverse), with an emphasis on rotation because of its constant presence in all tennis strokes.

Hip Injuries

Tennis players subject their bodies to extreme forces; the hip joint may experience forces up to five times body weight during activities such as running, jumping, and twisting. The forehand stroke requires greater hip external rotation, which may increase

the risk for anterior rotational instability and posterior impingement.[49] Through repetitive overuse injuries or direct trauma, injuries to surrounding or intra-articular structures may also occur. Most injuries to the hip joint are muscular strains or inflammation of the tendons and ligaments around the joint. These types of injuries generally improve with rest, ice, and various other traditional therapies. If the hip pain does not resolve, intra-articular injuries involving articular cartilage and the labrum should be considered.

For labral tears, groin pain, especially with twisting maneuvers, is the typical presenting complaint. If the labral tear is displaced into the joint, there is often a sense of catching or locking inside the hip. Dull, activity-induced positional pain that fails to improve with rest is a more subtle presentation. Frequently, the pain is misinterpreted by the player as a chronic groin strain or injury. "Groin pulls" that fail to respond effectively to traditional treatments warrant further evaluation for a labral tear within the joint. In athletes with persistent hip pain for longer than 6 to 8 weeks and with clinical signs and radiographic findings consistent with a labral tear, hip arthroscopy may be appropriate to either remove or repair the torn tissue.

Ankle Sprains

Ankle injuries are among the most common of all tennis injuries, with inversion ankle sprains predominating. No study to date has determined the incidence of ankle sprains on the various surface types in tennis, yet each surface presents unique risk factors.

Both static and dynamic restraints provide lateral ankle stability. The lateral ligaments include the anterior talofibular ligament, calcaneofibular ligament, and posterior talofibular ligament. These ligaments, along with the bony configuration of the ankle, provide the static restraints while the peroneal tendons are the primary dynamic stabilizers. Inversion sprains are graded I to III in order of increasing ligamentous disruption, laxity, and functional impairment.[50]

On examination, the clinician should systematically palpate the anterior talofibular, calcaneofibular, and posterior talofibular ligaments, syndesmosis, peroneal tendons, base of the fifth metatarsal, calcaneocuboid joint, and medial and lateral malleoli. The anterior drawer test can be used to assess the competency of the anterior talofibular ligament. The peroneal compression test can assess pain, crepitus, and "popping" at the posterior edge of the distal fibula during forceful eversion and dorsiflexion of the ankle.[51] It is important to recognize any symptomatic associated conditions, such as anterior impingement, subtalar instability, peroneal tendon pathology, and osteochondral lesions.

Treatment of acute lateral ankle sprains is dictated by the grade of sprain. Grade I and II sprains are best managed nonsurgically in phases. Phase I involves rest, ice, compression, and elevation. Phase II, not generally necessary for grade I injuries, is marked by a brief period of immobilization and protected weight bearing with external stabilization (ie, bracing or taping). Phase III centers on stretching, proprioception, and peroneal muscle strengthening. Historically, the treatment of grade III sprains has been more controversial, with some authors supporting nonsurgical management with the functional program outlined above and others espousing surgical treatment. However, literature to support primary surgical treatment of these injuries is limited.

Many professional tennis players use some type of supportive brace when playing. Both taping and bracing are effective, but taping has been shown to lose up to 50% of its mechanical strength after 20 minutes of play. A multidisciplinary approach using bracing along with proprioceptive training and muscle recruitment evaluation can be an effective prevention program for tennis players.

Summary

Tennis is one of the most popular sports in the world. Although injuries seen in tennis are common to other sports, its year-round nature, combined with the different surfaces on which it is played, equipment used, and biomechanics, leads to a unique spectrum of injuries. Acute injuries occur more frequently and more often affect the lower extremity. Chronic injuries also occur, but these tend to affect the upper extremity more frequently. Understanding how tennis equipment, the kinetic chain, and strokes affect the pathophysiology of these common injuries can help one treat them successfully. Additionally, preventive programs that are tennis specific and address the muscular imbalances identified in musculoskeletal profiling studies from elite players may help reduce the incidence of injuries that these athletes experience.[18]

References

Evidence-based Medicine: Levels of evidence are described in the table of contents. In this article, reference 25 is a level I study. References 23, 26, 28, 30, and 35 are level II studies. References 9, 10, 14, 16, 20, 21, and 24 are level III studies. References 3, 12, 18, 29, 32-34, 37, 46, 47, and 49 are level IV studies.

References printed in **bold type** indicate references published within the past 5 years.

1. Kovacs MS: Applied physiology of tennis performance. *Br J Sports Med* 2006;40(5): 381-385, discussion 386.
2. Pluim BM, Staal JB, Windler GE, Jayanthi N: Tennis injuries: Occurrence, aetiology, and prevention. *Br J Sports Med* 2006;40(5):415-423.
3. Eygendaal D, Rahussen FT, Diercks RL: Biomechanics of the elbow joint in tennis players and relation to pathology. *Br J Sports Med* 2007;41(11):820-823.
4. Elliott B, Fleisig G, Nicholls R, Escamilia R: Technique effects on upper limb loading in the tennis serve. *J Sci Med Sport* 2003;6(1): 76-87.
5. van der Hoeven H, Kibler WB: Shoulder injuries in tennis players. *Br J Sports Med* 2006;40(5):435-440.
6. Kibler WB: Biomechanical analysis of the shoulder during tennis activities. *Clin Sports Med* 1995;14(1):79-85.
7. Kibler WB, Chandler TJ: Sport-specific conditioning. *Am J Sports Med* 1994;22(3): 424-432.
8. Matsen FA III, Harryman DT II, Sidles JA: Mechanics of glenohumeral instability. *Clin Sports Med* 1991;10(4): 783-788.
9. Hutchinson MR, Laprade RF, Burnett QM II, Moss R, Terpstra J: Injury surveillance at the USTA Boys' Tennis Championships: A 6-yr study. *Med Sci Sports Exerc* 1995;27 (6):826-830.
10. Winge S, Jørgensen U, Lassen Nielsen A: Epidemiology of injuries in Danish championship tennis. *Int J Sports Med* 1989;10(5):368-371.
11. Miller S: Modern tennis rackets, balls, and surfaces. *Br J Sports Med* 2006;40(5): 401-405.
12. **Hennig EM: Influence of racket properties on injuries and performance in tennis. *Exerc Sport Sci Rev* 2007;35 (2):62-66.**
13. Segesser B: Sports injuries and sports damage in the elbow region (in Gernman). *Dtsch Z Sportmed* 1985;3:80-83.
14. Safran MR, Hutchinson MR, Moss R, Albrandt J: Comparison of injuries in elite boys and girls tennis players, in *Transactions of the 9th Annual Meeting of the Society of Tennis Medicine and Science*. Indian Wells, CA, 1999.
15. Abrams GD, Renstrom PA, Safran MR: Epidemiology of musculoskeletal injury in the tennis player. *Br J Sports Med* 2012;46 (7):492-498.
16. Tagliafico AS, Ameri P, Michaud J, Derchi LE, Sormani MP, Martinoli C: Wrist injuries in nonprofessional tennis players: Relationships with different grips. *Am J Sports Med* 2009;37(4):760-767.
17. Nigg BM, Yeadon MR: Biomechanical aspects of playing surfaces. *J Sports Sci* 1987;5(2):117-145.
18. Ellenbecker T, Roetert EP: Age specific isokinetic glenohumeral internal and external rotation strength in elite junior tennis players. *J Sci Med Sport* 2003;6(1): 63-70.
19. Elliott B: Biomechanics and tennis. *Br J Sports Med* 2006;40(5):392-396.
20. Myers JB, Laudner KG, Pasquale MR, Bradley JP, Lephart SM: Glenohumeral range of motion deficits and posterior shoulder tightness in throwers with pathologic internal impingement. *Am J Sports Med* 2006;34(3):385-391.
21. Halbrecht JL, Tirman P, Atkin D: Internal impingement of the shoulder: Comparison of findings between the throwing and nonthrowing shoulders of college baseball players. *Arthroscopy* 1999;15(3):253-258.
22. **Kibler WB, Kuhn JE, Wilk K, et al: The disabled throwing shoulder: Spectrum of pathology-10-year update. *Arthroscopy* 2013;29(1):141-161.e26.**
23. Parentis MA, Glousman RE, Mohr KS, Yocum LA: An evaluation of the provocative tests for superior labral anterior posterior lesions. *Am J Sports Med* 2006;34(2):265-268.
24. Oh JH, Kim JY, Kim WS, Gong HS, Lee JH: The evaluation of various physical examinations for the diagnosis of type II superior labrum anterior and posterior lesion. *Am J Sports Med* 2008;36(2): 353-359.
25. Ben Kibler W, Sciascia AD, Hester P, Dome D, Jacobs C: Clinical utility of traditional and new tests in the diagnosis of biceps tendon injuries and superior labrum anterior and posterior lesions in the shoulder. *Am J Sports Med* 2009;37(9): 1840-1847.
26. Herold T, Bachthaler M, Hamer OW, et al: Indirect MR arthrography of the shoulder: Use of abduction and external rotation to detect full- and partial-thickness tears of the supraspinatus tendon. *Radiology* 2006;240 (1):152-160.
27. Ellenbecker TS, Cools A: Rehabilitation of shoulder impingement syndrome and rotator cuff injuries: An evidence-based review. *Br J Sports Med* 2010;44(5): 319-327.
28. **Sayde WM, Cohen SB, Ciccotti MG, Dodson CC: Return to play after Type II superior labral anterior-posterior lesion repairs in athletes: A systematic review. *Clin Orthop Relat Res* 2012;470(6): 1595-1600.**
29. Conway JE: Arthroscopic repair of partial-thickness rotator cuff tears and SLAP lesions in professional baseball players. *Orthop Clin North Am* 2001;32(3): 443-456.
30. Blackwell JR, Cole KJ: Wrist kinematics differ in expert and novice tennis players performing the backhand stroke: Implications for tennis elbow. *J Biomech* 1994;27(5):509-516.
31. Riek S, Chapman AE, Milner T: A simulation of muscle force and internal kinematics of extensor carpi radialis brevis during backhand tennis stroke: Implications for injury. *Clin Biomech (Bristol, Avon)* 1999;14(7):477-483.
32. Vangsness CT Jr, Jobe FW: Surgical treatment of medial epicondylitis: Results in 35 elbows. *J Bone Joint Surg Br* 1991;73 (3):409-411.
33. Groppel JL, Nirschl RP: A mechanical and electromyographical analysis of the effects of various joint counterforce braces on the tennis player. *Am J Sports Med* 1986;14(3): 195-200.
34. Nirschl RP, Ashman ES: Elbow tendinopathy: Tennis elbow. *Clin Sports Med* 2003;22(4):813-836.
35. Mishra A, Pavelko T: Treatment of chronic elbow tendinosis with buffered platelet-rich plasma. *Am J Sports Med* 2006;34(11): 1774-1778.
36. Thornton SJ, Rogers JR, Prickett WD, Dunn WR, Allen AA, Hannafin JA: Treatment of recalcitrant lateral epicondylitis with suture anchor repair. *Am J Sports Med* 2005;33(10):1558-1564.
37. Ellenbecker TS, Roetert EP: Isokinetic profile of elbow flexion and extension strength in elite junior tennis players. *J Orthop Sports Phys Ther* 2003;33(2): 79-84.
38. Rettig AC: Athletic injuries of the wrist and hand: part II: Overuse injuries of the wrist and traumatic injuries to the hand. *Am J Sports Med* 2004;32(1):262-273.
39. Taleisnik J: The ligaments in the wrist, in Taleisnik J, ed: *The Wrist*. New York, NY, Churchill Livingstone, 1985, pp 442-448.
40. Maquirriain J, Ghisi JP, Kokalj AM: Rectus abdominis muscle strains in tennis players. *Br J Sports Med* 2007;41(11):842-848.
41. Chow JW, Shim JH, Lim YT: Lower trunk muscle activity during the tennis serve. *J Sci Med Sport* 2003;6(4):512-518.
42. **Conte SA, Thompson MM, Marks MA, Dines JS: Abdominal muscle strains in professional baseball: 1991-2010. *Am J Sports Med* 2012;40(3):650-656.**
43. Knudson D, Elliott B: Biomechanics of tennis strokes, in Hung GK, Pallis JM, eds: *Biomedical Engineering Principles in Sports*. New York, NY, Kluwer Academic / Plenum Publishers, pp 153-181.
44. Atkins JM, Taylor JC, Kane SF: Acute and overuse injuries of the abdomen and groin in athletes. *Curr Sports Med Rep* 2010;9(2): 115-120.

45. Marks MR, Haas SS, Wiesel SW: Low back pain in the competitive tennis player. *Clin Sports Med* 1988;7(2):277-287.

46. Vad VB, Gebeh A, Dines D, Altchek D, Norris B: Hip and shoulder internal rotation range of motion deficits in professional tennis players. *J Sci Med Sport* 2003;6(1):71-75.

47. Roetert EP, McCormick TJ, Brown SW, Ellenbecker TS: Relationship between isokinetic and functional trunk strength in elite junior tennis players. *Isokinet Exerc Sci* 1996;6:15-20.

48. Timm KE: Clinical applications of a normative database for the Cybex TEF and TORSO spinal isokinetic dynamometers. *Isokinet Exerc Sci* 1995;5: 43-49.

49. Klingenstein GG, Martin R, Kivlan B, Kelly BT: Hip injuries in the overhead athlete. *Clin Orthop Relat Res* 2012;470 (6):1579-1585.

50. Reed M, Feibel JB, Donley BG, Giza E: Athletic ankle injuries, in Kibler WB, ed: *Orthopaedic Knowledge Update: Sports Medicine 4*. Rosemont, IL, American Academy of Orthopaedic Surgeons, 2009, pp 199-214.

51. Sobel M, Geppert MJ, Olson EJ, Bohne WH, Arnoczky SP: The dynamics of peroneus brevis tendon splits: A proposed mechanism, technique of diagnosis, and classification of injury. *Foot Ankle* 1992;13 (7):413-422.