Proinflammatory cytokines, such as interleukin 1α and 1β and tumor necrosis factor α, might mediate fatigue in some patients. While preliminary studies of biologic therapies that inhibit cytokines have suggested a benefit against fatigue in some patients with inflammatory conditions, this approach has largely not led to improvement in clinical trials that focused on fatigue as the primary endpoint. Nonetheless, specific targeting with cytokine antagonists could represent a possible future approach for some patients.

PROGNOSIS

Acute fatigue significant enough to require medical evaluation is more likely to lead to an identifiable medical, neurologic, or psychiatric cause than is unexplained chronic fatigue. Evaluation of unexplained chronic fatigue most commonly leads to diagnosis of a psychiatric condition or remains unexplained. Identification of a previously undiagnosed serious or life-threatening culprit etiology is rare, even with longitudinal follow-up of patients with unexplained chronic fatigue. Complete resolution is uncommon, at least over the short term, but multidisciplinary treatment approaches can lead to symptomatic improvements that substantially improve quality of life.

FURTHER READING

Basu N et al: Fatigue is associated with excess mortality in the general population: Results from the EPIC-Norfolk study. BMC Med 14:122, 2016.

Ceban F et al: Fatigue and cognitive impairment in post-COVID-19 syndrome: A systematic review and meta-analysis. Brain Behav Immun 101:93, 2022.

Dukes JC et al: Approach to fatigue: Best practice. Med Clin North Am 105:137, 2021.

Roerink ME et al: Interleukin-1 as a mediator of fatigue in disease: A narrative review. J Neuroinflammation 14:16, 2017.

Sharpe M et al: Rehabilitative treatments for chronic fatigue syndrome: Long-term follow-up from the PACE trial. Lancet Psychiatry 2:1067, 2015.

26 Neurologic Causes of Weakness and Paralysis

Stephen L. Hauser

Normal motor function involves integrated muscle activity that is modulated by the activity of the cerebral cortex, basal ganglia, cerebellum, red nucleus, brainstem reticular formation, lateral vestibular nucleus, and spinal cord. Motor system dysfunction leads to weakness or paralysis, discussed in this chapter, or to ataxia **(Chap. 450)** or abnormal movements **(Chap. 447)**. *Weakness* is a reduction in the power that can be exerted by one or more muscles. It must be distinguished from increased *fatigability* (i.e., the inability to sustain the performance of an activity that should be normal for a person of the same age, sex, and size), limitation in function due to pain or articular stiffness, or impaired motor activity because severe *proprioceptive sensory loss* prevents adequate feedback information about the direction and power of movements. It is also distinct from *bradykinesia* (in which increased time is required for full power to be exerted) and *apraxia,* a disorder of planning and initiating a skilled or learned movement unrelated to a significant motor or sensory deficit **(Chap. 32)**.

Paralysis or the suffix "-plegia" indicates weakness so severe that a muscle cannot be contracted at all, whereas *paresis* refers to less severe weakness. The prefix "hemi-" refers to one-half of the body, "para-" to both legs, and "quadri-" to all four limbs.

The *distribution* of weakness helps to localize the underlying lesion. Weakness from involvement of upper motor neurons occurs particularly in the extensors and abductors of the upper limb and the flexors of the lower limb. Lower motor neuron weakness depends on whether involvement is at the level of the anterior horn cells, nerve root, limb plexus, or peripheral nerve—only muscles supplied by the affected structure are weak. Myopathic weakness is generally most marked in proximal muscles. Weakness from impaired neuromuscular transmission has no specific pattern of involvement.

Weakness often is accompanied by other neurologic abnormalities that help indicate the site of the responsible lesion **(Table 26-1)**.

Tone is the resistance of a muscle to passive stretch. Increased tone may be of several types. *Spasticity* is the increase in tone associated with disease of upper motor neurons. It is velocity dependent, has a sudden release after reaching a maximum (the "clasp-knife" phenomenon), and predominantly affects the antigravity muscles (i.e., upper-limb flexors and lower-limb extensors). *Rigidity* is hypertonia that is present throughout the range of motion (a "lead pipe" or "plastic" stiffness) and affects flexors and extensors equally; it sometimes has a cogwheel quality that is enhanced by voluntary movement of the contralateral limb (reinforcement). Rigidity occurs with extrapyramidal disorders such as Parkinson's disease. *Paratonia* (or *gegenhalten*) is increased tone that varies irregularly in a manner seemingly related to the degree of relaxation, is present throughout the range of motion, and affects flexors and extensors equally; it usually results from disease of the frontal lobes. Weakness with *decreased tone (flaccidity)* or normal tone occurs with disorders of *motor units.* A motor unit consists of a single lower motor neuron and all the muscle fibers that it innervates.

Muscle bulk generally is not affected by upper motor neuron lesions, although mild disuse atrophy eventually occurs. By contrast, atrophy is often conspicuous when a lower motor neuron lesion is responsible for weakness and also may occur with advanced muscle disease.

Muscle stretch (tendon) reflexes are usually increased with upper motor neuron lesions but may be decreased or absent for a variable period immediately after onset of an acute lesion. Hyperreflexia is usually—but not invariably—accompanied by loss of *cutaneous reflexes* (such as superficial abdominals; **Chap. 433**) and, in particular, by an extensor plantar (Babinski) response. The muscle stretch reflexes are depressed with lower motor neuron lesions involving specific reflex arcs. They generally are preserved in patients with myopathic weakness, except in advanced stages when they sometimes are attenuated. In disorders of the neuromuscular junction, reflex responses may be affected by preceding voluntary activity of affected muscles; such

TABLE 26-1 Signs That Distinguish the Origin of Weakness

SIGN	UPPER MOTOR NEURON	LOWER MOTOR NEURON	MYOPATHIC	PSYCHOGENIC
Atrophy	None	Severe	Mild	None
Fasciculations	None	Common	None	None
Tone	Spastic	Decreased	Normal/decreased	Variable/paratonia
Distribution of weakness	Pyramidal/regional	Distal/segmental	Proximal	Variable/inconsistent with daily activities
Muscle stretch reflexes	Hyperactive	Hypoactive/absent	Normal/hypoactive	Normal
Babinski sign	Present	Absent	Absent	Absent

activity may lead to enhancement of initially depressed reflexes in Lambert-Eaton myasthenic syndrome and, conversely, to depression of initially normal reflexes in myasthenia gravis (Chap. 459).

The distinction of *neuropathic* (lower motor neuron) from *myopathic* weakness is sometimes difficult clinically, although distal weakness is likely to be neuropathic, and symmetric proximal weakness myopathic. *Fasciculations* (visible or palpable twitches within a muscle due to the spontaneous discharge of a motor unit) and early atrophy indicate that weakness is neuropathic.

PATHOGENESIS

Upper Motor Neuron Weakness Lesions of the upper motor neurons or their descending axons to the spinal cord (Fig. 26-1) produce weakness through decreased activation of lower motor neurons. In general, distal muscle groups are affected more severely than proximal ones, and axial movements are spared unless the lesion is severe and bilateral. Spasticity is typical but may not be present acutely. Rapid repetitive movements are slowed and coarse, but normal rhythmicity is maintained. With corticobulbar involvement, weakness occurs in the lower face and tongue; extraocular, upper facial, pharyngeal, and jaw muscles are typically spared. Bilateral corticobulbar lesions produce a *pseudobulbar palsy*: dysarthria, dysphagia, dysphonia, and emotional lability accompany bilateral facial weakness and a brisk jaw jerk. Electromyogram (EMG) (Chap. 457) shows that with weakness of the upper motor neuron type, motor units have a diminished maximal discharge frequency.

Lower Motor Neuron Weakness This pattern results from disorders of lower motor neurons in the brainstem motor nuclei and the anterior horn of the spinal cord or from dysfunction of the axons of these neurons as they pass to skeletal muscle (Fig. 26-2). Weakness is due to a decrease in the number of muscle fibers that can be activated through a loss of α motor neurons or disruption of their connections to muscle. Loss of γ motor neurons does not cause weakness but decreases tension on the muscle spindles, which decreases muscle tone and attenuates the stretch reflexes. An absent stretch reflex suggests involvement of spindle afferent fibers.

When a motor unit becomes diseased, especially in anterior horn cell diseases, it may discharge spontaneously, producing *fasciculations*. When α motor neurons or their axons degenerate, the denervated muscle fibers also may discharge spontaneously. These single muscle fiber discharges, or *fibrillation potentials,* cannot be seen but can be recorded with EMG. Weakness leads to delayed or reduced recruitment of motor units, with fewer than normal activated at a particular discharge frequency.

Neuromuscular Junction Weakness Disorders of the neuromuscular junction produce weakness of variable degree and distribution. The number of muscle fibers that are activated varies over time, depending on the state of rest of the neuromuscular junctions. Strength is influenced by preceding activity of the affected muscle. In myasthenia gravis, for example, sustained or repeated contractions of affected muscle decline in strength despite continuing effort (Chap. 459). Thus, fatigable weakness is suggestive of disorders of the neuromuscular junction, which cause functional loss of muscle fibers due to failure of their activation.

Myopathic Weakness Myopathic weakness is produced by a decrease in the number or contractile force of muscle fibers activated within motor units. With muscular dystrophies, inflammatory myopathies, or myopathies with muscle fiber necrosis, the number of muscle fibers is reduced within many motor units. On EMG, the size of each motor unit action potential is decreased, and motor units must be recruited more rapidly than normal to produce the desired power. Some myopathies produce weakness through loss of contractile force of muscle fibers or through relatively selective involvement of type II (fast) fibers. These myopathies may not affect the size of individual motor unit action potentials and are detected by a discrepancy between the electrical activity and force of a muscle.

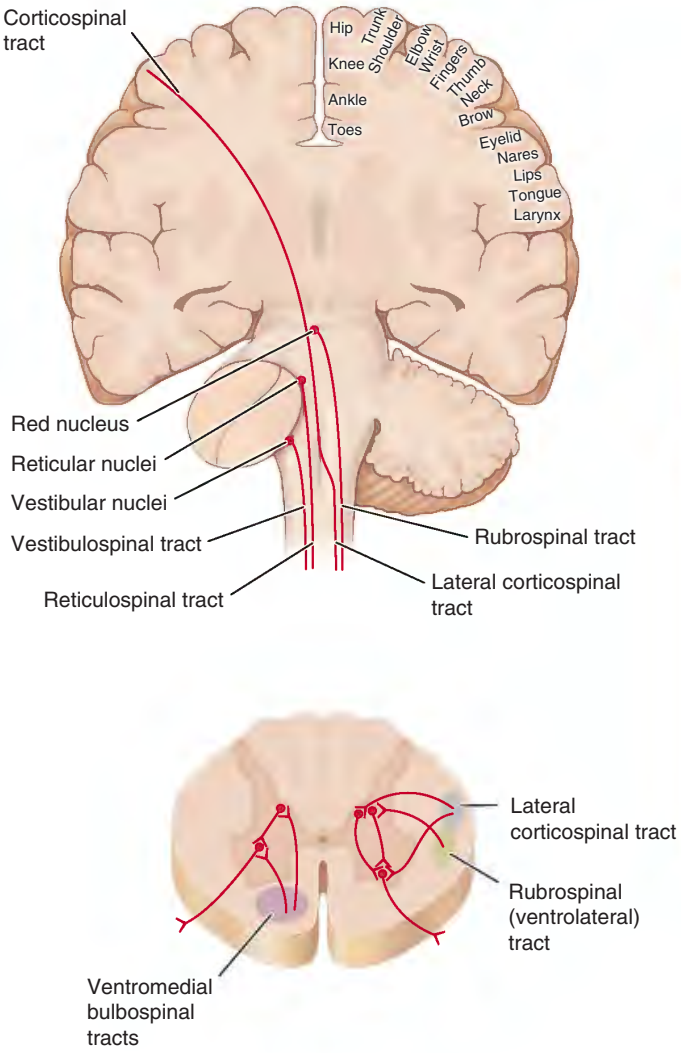

FIGURE 26-1 The corticospinal and bulbospinal upper motor neuron pathways. Upper motor neurons have their cell bodies in layer V of the primary motor cortex (the precentral gyrus, or Brodmann area 4) and in the premotor and supplemental motor cortex (area 6). The upper motor neurons in the primary motor cortex are somatotopically organized (*right side of figure*). Axons of the upper motor neurons descend through the subcortical white matter and the posterior limb of the internal capsule. Axons of the pyramidal or corticospinal system descend through the brainstem in the cerebral peduncle of the midbrain, the basis pontis, and the medullary pyramids. At the cervicomedullary junction, most corticospinal axons decussate into the contralateral corticospinal tract of the lateral spinal cord, but 10–30% remain ipsilateral in the anterior spinal cord. Corticospinal neurons synapse on premotor interneurons, but some—especially in the cervical enlargement and those connecting with motor neurons to distal limb muscles—make direct monosynaptic connections with lower motor neurons. They innervate most densely the lower motor neurons of hand muscles and are involved in the execution of learned, fine movements. Corticobulbar neurons are similar to corticospinal neurons but innervate brainstem motor nuclei. Bulbospinal upper motor neurons influence strength and tone but are not part of the pyramidal system. The descending ventromedial bulbospinal pathways originate in the tectum of the midbrain (tectospinal pathway), the vestibular nuclei (vestibulospinal pathway), and the reticular formation (reticulospinal pathway). These pathways influence axial and proximal muscles and are involved in the maintenance of posture and integrated movements of the limbs and trunk. The descending ventrolateral bulbospinal pathways, which originate predominantly in the red nucleus (rubrospinal pathway), facilitate distal limb muscles. The bulbospinal system sometimes is referred to as the extrapyramidal upper motor neuron system. In all figures, nerve cell bodies and axon terminals are shown, respectively, as *closed circles* and *forks*.

Psychogenic Weakness Weakness may occur without a recognizable organic basis. It tends to be variable, inconsistent, and with a pattern of distribution that cannot be explained on a neuroanatomic basis. On formal testing, antagonists may contract when the patient is supposedly activating the agonist muscle. The severity of weakness is out of keeping with the patient's daily activities.

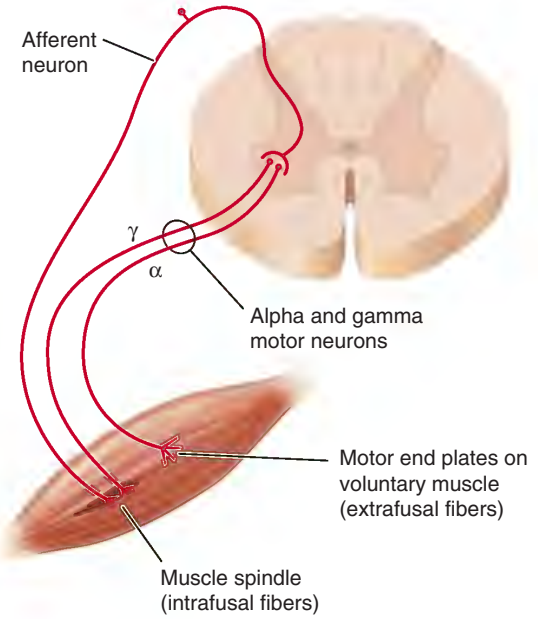

FIGURE 26-2 Lower motor neurons are divided into α and γ types. The larger α motor neurons are more numerous and innervate the extrafusal muscle fibers of the motor unit. Loss of α motor neurons or disruption of their axons produces lower motor neuron weakness. The smaller, less numerous γ motor neurons innervate the intrafusal muscle fibers of the muscle spindle and contribute to normal tone and stretch reflexes. The α motor neuron receives direct excitatory input from corticomotoneurons and primary muscle spindle afferents. The α and γ motor neurons also receive excitatory input from other descending upper motor neuron pathways, segmental sensory inputs, and interneurons. The α motor neurons receive direct inhibition from Renshaw cell interneurons, and other interneurons indirectly inhibit the α and γ motor neurons. A muscle stretch (tendon) reflex requires the function of all the illustrated structures. A tap on a tendon stretches muscle spindles (which are tonically activated by γ motor neurons) and activates the primary spindle afferent neurons. These neurons stimulate the α motor neurons in the spinal cord, producing a brief muscle contraction, which is the familiar tendon reflex.

DISTRIBUTION OF WEAKNESS

Hemiparesis Hemiparesis results from an upper motor neuron lesion above the midcervical spinal cord; most such lesions are above the foramen magnum. The presence of other neurologic deficits helps localize the lesion. Thus, language disorders, for example, point to a cortical lesion. Homonymous visual field defects reflect either a cortical or a subcortical hemispheric lesion. A "pure motor" hemiparesis of the face, arm, and leg often is due to a small, discrete lesion in the posterior limb of the internal capsule, cerebral peduncle in the midbrain, or upper pons. Some brainstem lesions produce "crossed paralyses," consisting of ipsilateral cranial nerve signs and contralateral hemiparesis **(Chap. 437)**. The absence of cranial nerve signs or facial weakness suggests that a hemiparesis is due to a lesion in the high cervical spinal cord, especially if associated with Brown-Séquard syndrome, consisting of loss of joint position and vibration sense on the side of the weakness, and loss of pain and temperature sense on the opposite side **(Chap. 453)**.

Acute or episodic hemiparesis usually results from focal structural lesions, particularly vascular etiologies, rapidly expanding lesions, or an inflammatory process. *Subacute hemiparesis* that evolves over days or weeks may be caused by subdural hematoma, infectious or inflammatory disorders (e.g., cerebral abscess, fungal granuloma or meningitis, parasitic infection, multiple sclerosis, sarcoidosis), or primary or metastatic neoplasms. AIDS may present with subacute hemiparesis due to toxoplasmosis or primary central nervous system (CNS) lymphoma. *Chronic hemiparesis* that evolves over months usually is due to a neoplasm or vascular malformation, chronic subdural hematoma, or a degenerative disease.

Investigation of hemiparesis **(Fig. 26-3)** of acute origin usually starts with a CT scan of the brain and laboratory studies. If the CT is normal, or in subacute or chronic cases of hemiparesis, MRI of the brain and/or cervical spine (including the foramen magnum) is performed, depending on the clinical accompaniments.

Paraparesis ***Acute paraparesis*** is caused most commonly by an intraspinal lesion, but its spinal cord origin may not be recognized initially if the legs are flaccid and areflexic. Usually, however, there is sensory loss in the legs with an upper level on the trunk; a dissociated sensory loss (loss of pain and temperature but not touch, position, and vibration sense) suggestive of a central cord syndrome; or hyperreflexia in the legs with normal reflexes in the arms **(Chap. 453)**. Imaging the spinal cord (Fig. 26-3) may reveal compressive lesions, infarction (proprioception usually is spared), arteriovenous fistulas or other vascular anomalies, or transverse myelitis **(Chap. 453)**.

Diseases of the cerebral hemispheres that produce acute paraparesis include anterior cerebral artery ischemia (shoulder shrug also is affected), superior sagittal sinus or cortical venous thrombosis, and acute hydrocephalus.

Paraparesis may also result from a cauda equina syndrome, for example, after trauma to the low back, a midline disk herniation, or an intraspinal tumor. The sphincters are commonly affected, whereas hip flexion often is spared, as is sensation over the anterolateral thighs. Rarely, paraparesis is caused by a rapidly evolving anterior horn cell disease (such as poliovirus or West Nile virus infection), peripheral neuropathy (such as Guillain-Barré syndrome; **Chap. 458**), or myopathy **(Chap. 460)**.

Subacute or chronic spastic paraparesis is caused by upper motor neuron disease. When associated with lower-limb sensory loss and sphincter involvement, a chronic spinal cord disorder should be considered **(Chap. 453)**. If hemispheric signs are present, a parasagittal meningioma or chronic hydrocephalus is likely. The absence of spasticity in a long-standing paraparesis suggests a lower motor neuron or myopathic etiology.

Investigations typically begin with spinal MRI, but when upper motor neuron signs are associated with drowsiness, confusion, seizures, or other hemispheric signs, brain MRI should also be performed. Electrophysiologic studies are diagnostically helpful when clinical findings suggest an underlying neuromuscular disorder.

Quadriparesis or Generalized Weakness Generalized weakness may be due to disorders of the CNS or the motor unit. Although the terms often are used interchangeably, *quadriparesis* is commonly used when an upper motor neuron cause is suspected, and *generalized weakness* is used when a disease of the motor units is likely. Weakness from CNS disorders usually is associated with changes in consciousness or cognition and accompanied by spasticity, hyperreflexia, and sensory disturbances. Most neuromuscular causes of generalized weakness are associated with normal mental function, hypotonia, and hypoactive muscle stretch reflexes. The major causes of intermittent weakness are listed in **Table 26-2**. A patient with generalized fatigability without objective weakness may have myalgic encephalomyelitis/chronic fatigue syndrome **(Chap. 461)**.

ACUTE QUADRIPARESIS Quadriparesis with onset over minutes may result from disorders of upper motor neurons (such as from anoxia, hypotension, brainstem or cervical cord ischemia, trauma, and systemic metabolic abnormalities) or muscle (electrolyte disturbances, certain inborn errors of muscle energy metabolism, toxins, and periodic paralyses). Onset over hours to weeks may, in addition to these disorders, be due to lower motor neuron disorders such as Guillain-Barré syndrome **(Chap. 458)**.

In obtunded patients, evaluation begins with a CT or MRI scan of the brain. If upper motor neuron signs are present but the patient is alert, the initial test is usually an MRI of the cervical cord. If weakness is lower motor neuron, myopathic, or uncertain in origin, the clinical approach begins with blood studies to determine the level of muscle enzymes and electrolytes and with EMG and nerve conduction studies.

SUBACUTE OR CHRONIC QUADRIPARESIS Quadriparesis due to upper motor neuron disease may develop over weeks to years from chronic myelopathies, multiple sclerosis, brain or spinal tumors, chronic subdural hematomas, and various metabolic, toxic, and infectious disorders. It may also result from lower motor neuron disease, a chronic

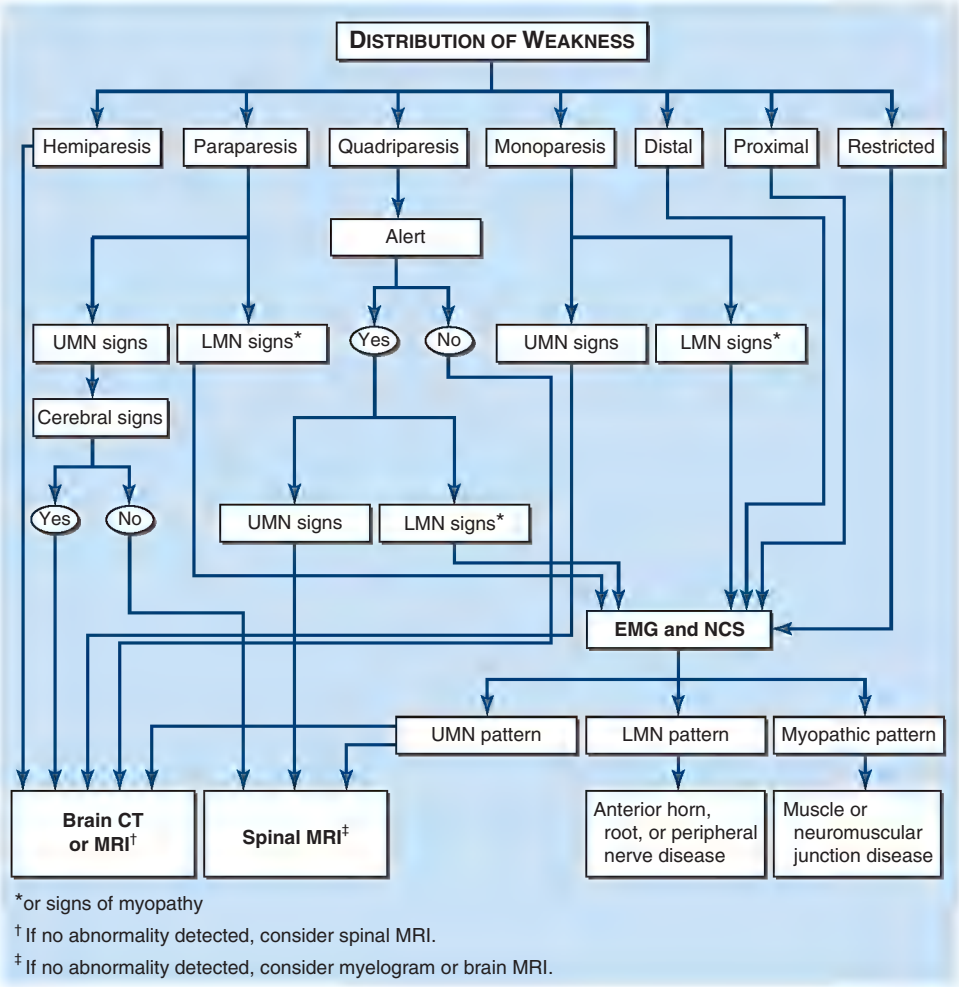

FIGURE 26-3 An algorithm for the initial workup of a patient with weakness. CT, computed tomography; EMG, electromyography; LMN, lower motor neuron; MRI, magnetic resonance imaging; NCS, nerve conduction studies; UMN, upper motor neuron.

neuropathy (in which weakness is often most profound distally), or myopathic weakness (typically proximal).

When quadriparesis develops acutely in obtunded patients, evaluation begins with a CT scan of the brain. If upper motor neuron signs have developed acutely but the patient is alert, the initial test is usually an MRI of the cervical cord. When onset has been gradual, disorders of the cerebral hemispheres, brainstem, and cervical spinal cord can usually be distinguished clinically, and imaging is directed first at the clinically suspected site of pathology. If weakness is lower motor neuron, myopathic, or uncertain in origin, laboratory studies can determine the levels of muscle enzymes and electrolytes, and EMG and nerve conduction studies help to localize the pathologic process (Chap. 460).

TABLE 26-2 Causes of Episodic Generalized Weakness

1. Electrolyte disturbances, e.g., hypokalemia, hyperkalemia, hypercalcemia, hypernatremia, hyponatremia, hypophosphatemia, hypermagnesemia
2. Muscle disorders
   a. Channelopathies (periodic paralyses)
   b. Metabolic defects of muscle (impaired carbohydrate or fatty acid utilization; abnormal mitochondrial function)
3. Neuromuscular junction disorders
   a. Myasthenia gravis
   b. Lambert-Eaton myasthenic syndrome
4. Central nervous system disorders
   a. Transient ischemic attacks of the brainstem
   b. Transient global cerebral ischemia
   c. Multiple sclerosis
5. Lack of voluntary effort
   a. Anxiety
   b. Pain or discomfort
   c. Somatization disorder

Monoparesis Monoparesis usually is due to lower motor neuron disease, with or without associated sensory involvement. Upper motor neuron weakness occasionally presents as a monoparesis of distal and nonantigravity muscles. Myopathic weakness rarely is limited to one limb.

ACUTE MONOPARESIS If weakness is predominantly distal and of upper motor neuron type and is not associated with sensory impairment or pain, focal cortical ischemia is likely (Chap. 438); diagnostic possibilities are similar to those for acute hemiparesis. Sensory loss and pain usually accompany acute lower motor neuron weakness; the weakness commonly localizes to a single nerve root or peripheral nerve, but occasionally reflects plexus involvement. If lower motor neuron weakness is likely, evaluation begins with EMG and nerve conduction studies.

SUBACUTE OR CHRONIC MONOPARESIS Weakness and atrophy that develop over weeks or months are usually of lower motor neuron origin. When associated with sensory symptoms, a peripheral cause (nerve, root, or plexus) is likely; otherwise, anterior horn cell disease should be considered. In either case, an electrodiagnostic study is indicated. If weakness is of the upper motor neuron type, a discrete cortical (precentral gyrus) or cord lesion may be responsible, and appropriate imaging is performed.

Distal Weakness Involvement of two or more limbs distally suggests lower motor neuron or peripheral nerve disease. Acute distal lower-limb weakness results occasionally from an acute toxic polyneuropathy or cauda equina syndrome. Distal symmetric weakness usually develops over weeks, months, or years and, when associated with numbness, is due to peripheral neuropathy (Chap. 457). Anterior horn cell disease may begin distally but is typically asymmetric and without accompanying numbness (Chap. 448). Rarely, myopathies present with distal weakness (Chap. 460). Electrodiagnostic studies help localize the disorder (Fig. 26-3).

Proximal Weakness Myopathy often produces symmetric weakness of the pelvic or shoulder girdle muscles (Chap. 460). Diseases of the neuromuscular junction, such as myasthenia gravis (Chap. 459), may present with symmetric proximal weakness often associated with ptosis, diplopia, or bulbar weakness and fluctuate in severity during the day. In anterior horn cell disease, proximal weakness is usually asymmetric, but it may be symmetric, especially in genetic forms. Numbness does not occur with any of these diseases. The evaluation usually begins with determination of the serum creatine kinase level and electrophysiologic studies.

Weakness in a Restricted Distribution Weakness may not fit any of these patterns, being limited, for example, to the extraocular, hemifacial, bulbar, or respiratory muscles. If it is unilateral, restricted