up to one-fourth infected. Persons who transmit infection or who have recently been infected and are still in the incubation period usually have no symptoms or only mild symptoms and seek medical attention only when notified of their exposure. Therefore, the clinician must encourage patients to participate in partner notification, must ensure that exposed persons are notified and treated, and must guarantee confidentiality to all involved. In the United States, local health departments often offer assistance in partner notification, treatment, and/or counseling. It seems both feasible and most useful to notify those partners exposed within the patient's likely period of infectiousness, which is often considered the preceding 1 month for gonorrhea, 1–2 months for chlamydial infection, and up to 3 months for early syphilis.

Persons with a new-onset STI have a *source* contact who gave them the infection; in addition, they may have a *secondary* (*spread* or *exposed*) contact with whom they had sex after becoming infected. The identification and treatment of these two types of contacts have different objectives. Treatment of the source contact (often a casual contact) benefits the community by preventing further transmission and benefits the source contact; treatment of the recently exposed secondary contact (typically a spouse or another steady sexual partner) prevents the development of serious complications (such as PID) in the partner, reinfection of the index patient, and further spread of infection. A randomized trial compared patients' delivery of therapy to partners exposed to gonorrhea or chlamydial infection with conventional notification and advice to partners to seek evaluation for STD; patients' delivery of partners' therapy, also known as *expedited partner therapy* (EPT), significantly reduced combined rates of reinfection of the index patient with *N. gonorrhoeae* or *C. trachomatis*. EPT, which is now commonly used by many practicing physicians, is currently permissible in 46 states and potentially allowable in the remaining four. (Updated information on the legal status of EPT is available at *https://www.cdc.gov/sti/hcp/clinical-guidance/expedited-partner-therapy.html?CDC_AAref_Val=https://www.cdc.gov/std/ept/*.)

In summary, clinicians and public health agencies share responsibility for the prevention and control of STIs. In the current health care environment, the role of primary care clinicians has become increasingly important in STI prevention as well as in diagnosis and treatment, and the resurgence of bacterial STIs like congenital syphilis—particularly in the setting of HIV co-infection—emphasizes the need for risk assessment and routine screening.

Acknowledgment

The author wishes to acknowledge King K. Holmes, MD, PhD, for his valuable contributions to this chapter in prior editions.

FURTHER READING

Cannon CA et al: On the horizon: Novel approaches to sexually transmitted infection prevention. Med Clin North Am 108:403, 2024.

Gottlieb SL et al: Advancing vaccine development for gonorrhoea and the Global STI Vaccine Roadmap. Sex Health 16:426, 2019.

Johnston C, Corey L: Current concepts for genital herpes simplex virus infection: Diagnostics and pathogenesis of genital tract shedding. Clin Microbiol Rev 29:149, 2016.

Kirkcaldy RD et al: *Neisseria gonorrhoeae* antimicrobial resistance among men who have sex with men and men who have sex exclusively with women: The Gonococcal Isolate Surveillance Project, 2005–2010. Ann Intern Med 158:321, 2013.

Mlisana K et al: Symptomatic vaginal discharge is a poor predictor of sexually transmitted infections and genital tract inflammation in high-risk women in South Africa. J Infect Dis 206:6, 2012.

Price MJ et al: Risk of pelvic inflammatory disease following *Chlamydia trachomatis* infection: Analysis of prospective studies with a multistate model. Am J Epidemiol 178:484, 2013.

Tuddenham S et al: Diagnosis and treatment of sexually transmitted infections: A review. JAMA 327:161, 2022.

Unemo M et al: Sexually transmitted infections: Challenges ahead. Lancet Infect Dis 17:e235, 2017.

U.S. Preventive Services Task Force: Screening for chlamydia and gonorrhea: US Preventive Services Task Force Recommendation Statement. JAMA 326:949, 2021.

U.S. Preventive Services Task Force: Behavioral counseling interventions to prevent sexually transmitted infections. JAMA 324:674, 2020.

Wiesenfeld HC et al: A randomized controlled trial of ceftriaxone and doxycycline, with or without metronidazole, for the treatment of acute pelvic inflammatory disease. Clin Infect Dis 13:ciaa101, 2020.

Workowski KA, Bachmann L: Sexually transmitted disease treatment guidelines, 2021. MMWR Recomm Rep 70:1, 2021.

142 Encephalitis

Karen L. Roos, Michael R. Wilson, Kenneth L. Tyler

DEFINITION

Encephalitis is defined as an inflammation of the brain caused either by infection, usually with a virus, or from a primary autoimmune process. This chapter will focus on infectious causes of encephalitis. Many patients with encephalitis also have evidence of associated meningitis (meningoencephalitis) and, in some cases, involvement of the spinal cord or nerve roots (encephalomyelitis, encephalomyeloradiculitis).

CLINICAL MANIFESTATIONS

Similar to meningitis, encephalitis is typically an acute febrile illness. The patient with encephalitis commonly has an altered state of consciousness (confusion, behavioral abnormalities), or a depressed level of consciousness ranging from mild lethargy to coma, and evidence of either focal or diffuse neurologic signs and symptoms. Patients with encephalitis may have hallucinations, agitation, personality change, behavioral disorders, and, at times, a frankly psychotic state. Focal or generalized seizures occur in many patients with encephalitis. Virtually every possible type of focal neurologic disturbance has been reported in viral encephalitis; the signs and symptoms reflect the sites of infection and inflammation. The most commonly encountered focal findings are aphasia, ataxia, upper or lower motor neuron patterns of weakness, involuntary movements (e.g., myoclonic jerks, tremor), and cranial nerve deficits (e.g., ocular palsies, facial weakness). Involvement of the hypothalamic-pituitary axis may result in temperature dysregulation, diabetes insipidus, or the development of the syndrome of inappropriate secretion of antidiuretic hormone (SIADH). Even though neurotropic viruses typically cause injury in distinct regions of the central nervous system (CNS), variations in clinical presentations make it impossible to reliably establish the etiology of a specific case of encephalitis on clinical grounds alone (see "Differential Diagnosis," below).

ETIOLOGY

In the United States, there are an estimated ~20,000 cases of encephalitis per year, although the actual number of cases is likely to be significantly higher. Despite comprehensive diagnostic efforts, most cases of acute encephalitis with a suspected viral etiology remain of unknown cause. Hundreds of viruses are capable of causing encephalitis, although only a limited subset is responsible for most cases in which a specific cause is identified **(Table 142-1)**. The most commonly identified viruses causing sporadic cases of acute encephalitis in immunocompetent adults are herpesviruses (herpes simplex virus [HSV] **[Chap. 197]**, varicella-zoster virus [VZV] **[Chap. 198]**, and Epstein-Barr virus [EBV] **[Chap. 199]**). Epidemics of encephalitis are caused by arboviruses **(Chap. 215)**, which belong to several different viral taxonomic groups including *Alphaviruses* (e.g., eastern equine encephalitis [EEE] virus and chikungunya virus), *Flaviviruses* (e.g., West Nile virus [WNV], St. Louis encephalitis virus, Japanese encephalitis virus,

TABLE 142-1 Viruses Causing Acute Encephalitis in North America

COMMON	LESS COMMON
Herpesviruses	Rabies
Cytomegalovirus[a]	Eastern equine encephalitis virus
Herpes simplex virus 1[b]	Powassan virus
Herpes simplex virus 2	Cytomegalovirus[a]
Human herpesvirus 6	Colorado tick fever virus
Varicella-zoster virus	Mumps
Epstein-Barr virus	Jamestown Canyon virus
Arthropod-borne viruses	
La Crosse virus	
West Nile virus[c]	
St. Louis encephalitis virus	
Zika	
Enteroviruses	

[a]Immunocompromised host. [b]The most common cause of sporadic encephalitis. [c]The most common cause of epidemic encephalitis.

Powassan virus, Zika virus, dengue virus, and tick-borne encephalitis virus), and *Bunyaviruses* (e.g., California encephalitis virus serogroup, La Crosse virus, Jamestown Canyon virus). Historically, the largest number of cases of arbovirus encephalitis in the United States has been due to St. Louis encephalitis virus and the California encephalitis virus serogroup. However, since 2002, WNV has been responsible for the majority of arbovirus meningitis and encephalitis cases in the United States. WNV caused 28,684 confirmed cases of neuroinvasive disease (encephalitis, meningitis, or myelitis) in the years 1999–2022 with 2641 deaths. In 2023, there were 1599 reported cases of neuroinvasive disease (encephalitis, meningitis, acute flaccid paralysis). The majority of cases occur in August and September. It is important to recognize that WNV epidemics are unpredictable and that cases have occurred in every state in the continental United States. Since 2006, there have been increasing numbers of cases of the tick-borne Powassan virus primarily in the northeastern United States and Minnesota and Wisconsin. New causes of viral CNS infections are constantly appearing, as evidenced by multiple outbreaks of cases of encephalitis in Southeast Asia caused by Nipah virus, a member of the Paramyxoviridae family; meningitis in Europe caused by Toscana virus, an arbovirus belonging to the Bunyavirus family; neurologic disorders associated with Zika virus, a flavivirus, in South America; and neurologic disorders associated with major epidemics of chikungunya virus, a togavirus, in Africa, India, and Southeast Asia. Dengue virus is common in >100 countries worldwide with cases on the rise in the Caribbean and Puerto Rico and rare cases reported in the United States in Florida and in southern Texas. Parechoviruses including human parechovirus 3 (HPeV3), members of the Picornavirus family, have been reported as causes of fever, sepsis, and meningitis in infants (age <3 months) in the United States and abroad.

LABORATORY DIAGNOSIS

CSF Examination Cerebrospinal fluid (CSF) examination should be performed in all patients with suspected viral encephalitis unless contraindicated by the presence of severely increased intracranial pressure (ICP). Ideally, at least 20 mL of the initial CSF sample should be collected, with 5–10 mL stored frozen for later studies, including additional direct detection tests like virus-specific polymerase chain reaction (PCR) or metagenomic next-generation sequencing, since many neuroinvasive viruses are only transiently present in the CSF. The characteristic CSF profile is indistinguishable from that of viral meningitis **(Chap. 143)** and typically consists of a lymphocytic pleocytosis, a mildly elevated protein concentration, and a normal glucose concentration. A CSF pleocytosis (>5 cells/μL) occurs in >95% of immunocompetent patients with documented viral encephalitis. In rare cases, a pleocytosis may be absent on the initial lumbar puncture (LP) but present on subsequent LPs. Patients who are severely immunocompromised by HIV infection, glucocorticoid or other immunosuppressant drugs, chemotherapy, or lymphoreticular malignancies may fail to mount a CSF inflammatory response. CSF cell counts exceed 500/μL in only about 10% of patients with encephalitis. Infections with certain arboviruses (e.g., EEE virus or California encephalitis virus), mumps, and lymphocytic choriomeningitis virus (LCMV) may occasionally result in cell counts >1000/μL, but this degree of pleocytosis should suggest the possibility of nonviral infections or other inflammatory processes. Atypical lymphocytes in the CSF may be seen in EBV infection and less commonly with other viruses, including cytomegalovirus (CMV), HSV, and enteroviruses. Increased numbers of plasmacytoid or Mollaret-like large mononuclear cells have been reported in WNV encephalitis. Polymorphonuclear pleocytosis occurs in ~45% of patients with WNV encephalitis and is also a common feature in CMV myeloradiculitis in immunocompromised patients. Large numbers of CSF polymorphonuclear leukocytes may be present in patients with encephalitis due to EEE virus, echovirus 9, and, more rarely, other enteroviruses. However, persisting CSF neutrophilia should prompt consideration of bacterial infection, leptospirosis, amebic infection, and noninfectious processes such as acute hemorrhagic leukoencephalitis **(Chap. 456)**. About 20% of patients with encephalitis will have a significant number of red blood cells (>500/μL) in the CSF in a nontraumatic tap. The pathologic correlate of this finding may be punctate microhemorrhages of the type seen with HSV; however, CSF red blood cells occur with similar frequency and in similar numbers in patients with nonherpetic focal encephalitides. A decreased CSF glucose concentration is distinctly unusual in viral encephalitis and should suggest the possibility of bacterial, fungal, tuberculous, parasitic, leptospiral, syphilitic, sarcoid, or neoplastic meningitis. Rare patients with mumps, LCMV, VZV, or advanced HSV encephalitis and many patients with CMV myeloradiculitis have low CSF glucose concentrations.

CSF POLYMERASE CHAIN REACTION

CSF PCR has become the primary diagnostic test for CNS infections caused by HSV, CMV, EBV, HHV-6, and enteroviruses. In the case of VZV CNS infection, CSF PCR and detection of virus-specific IgM or intrathecal antibody synthesis both provide important aids to diagnosis. The sensitivity and specificity of CSF PCRs vary with the virus being tested. The sensitivity (~96%) and specificity (~99%) of HSV CSF PCR are equivalent to or exceed those of brain biopsy. It is important to recognize that HSV CSF PCR results need to be interpreted after considering the likelihood of disease in the patient being tested, the timing of the test in relationship to onset of symptoms, and the prior use of antiviral therapy. A negative HSV CSF PCR test performed by a qualified laboratory at the appropriate time during illness in a patient with a high likelihood of HSV encephalitis based on clinical and laboratory abnormalities significantly reduces the likelihood of HSV encephalitis but does not exclude it. For example, in a patient with a pretest probability of 35% of having HSV encephalitis, a negative HSV CSF PCR reduces the posttest probability to ~2%, and for a patient with a pretest probability of 60%, a negative test reduces the posttest probability to ~6%. In both situations, a positive test makes the diagnosis almost certain (98–99%). There have been reports of initially negative HSV CSF PCR tests that were obtained early (≤72 h) following symptom onset and that became positive when repeated 1–3 days later. The frequency of positive HSV CSF PCRs in patients with herpes encephalitis also decreases as a function of the duration of illness, with only ~20% of cases remaining positive after ≥14 days. PCR results are generally not affected by ≤1 week of antiviral therapy. In one study, 98% of CSF specimens remained PCR positive during the first week of antiviral therapy, but the numbers fell to ~50% by 8–14 days and to ~21% by >15 days after initiation of antiviral therapy.

The sensitivity and specificity of CSF PCR tests for viruses other than HSV have not been definitively characterized. Enteroviral (EV) CSF RT-PCR appears to have a sensitivity and specificity of >95%. EV RT-PCR sensitivity for EV-A71 may be considerably lower (~30% in some reports). Patients with EV-D68-associated acute flaccid myelitis (AFM) only rarely have a positive CSF RT-PCR (<3%) but may have a positive test on nasopharyngeal swab specimens. Parechoviruses are also not detected by standard EV RT-PCRs. The specificity of EBV

CSF PCR has not been established. Positive EBV CSF PCRs associated with positive tests for other pathogens have been reported and may reflect reactivation of EBV latent in lymphocytes that enter the CNS as a result of an unrelated infectious or inflammatory process. In patients with CNS infection due to VZV, CSF antibody and PCR studies should be considered complementary because patients may have evidence of intrathecal synthesis of VZV-specific antibodies and negative CSF PCRs. In the case of WNV infection, CSF PCR appears to be less sensitive than detection of WNV-specific CSF IgM, although PCR testing remains useful in immunocompromised patients who may not mount an effective anti-WNV antibody response. The recent pandemic due to SARS-CoV-2 (COVID-19) has been associated with cases of encephalopathy due to the indirect effects on the nervous system of multiorgan system failure and/or to a hyperinflammatory syndrome and disseminated intravascular coagulation, but also with rare cases of true encephalitis caused by viral CNS invasion. In both sets of patients, nasopharyngeal reverse transcriptase (RT)-PCR tests for SARS-CoV-2 are positive, but only cases with encephalitis have a positive CSF RT-PCR for SARS-CoV-2. Rare cases of neuroinvasion by SARS-CoV-2 has also been detected by RT-PCR of brain tissue.

Unbiased metagenomic sequencing technologies capable of identifying infectious genomes in CSF, brain, and other tissues have recently shown great promise for rapid diagnosis of obscure cases of encephalitis and other brain infections, especially in immunocompromised patients.

CSF Culture CSF culture is generally of limited utility in the diagnosis of acute viral encephalitis. Culture may be insensitive (e.g., >95% of patients with HSV encephalitis have negative CSF cultures, as do virtually all patients with EBV-associated CNS disease) and often takes too long to significantly affect immediate therapy.

Serologic Studies and Antigen Detection For many arboviruses including WNV, serologic studies remain important diagnostic tools. Serum antibody determination is less useful for viruses with high seroprevalence rates in the general population such as HSV, VZV, CMV, and EBV. For viruses with low seroprevalence rates, diagnosis of acute viral infection can be made by documenting seroconversion between acute-phase and convalescent sera (typically obtained after 2–4 weeks) or by demonstrating the presence of virus-specific IgM antibodies. For viruses with high seroprevalence such as VZV and HSV, demonstration of synthesis of virus-specific antibodies in CSF, as shown by an increased IgG index or the presence of CSF IgM antibodies, may be useful and can provide presumptive evidence of CNS infection. Unfortunately, the delay between onset of infection and the host's generation of a virus-specific antibody response often means that serologic data are useful mainly for the retrospective establishment of a diagnosis, rather than in aiding acute diagnosis or management.

In patients with HSV encephalitis, antibodies to HSV-1 glycoproteins and HSV glycoprotein antigens have been detected in the CSF. Optimal detection of both HSV antibodies and antigen typically occurs after the first week of illness, limiting the utility of these tests in acute diagnosis. Nonetheless, HSV CSF antibody testing is of value in selected patients whose illness is >1 week in duration and who are CSF PCR negative for HSV. In the case of VZV infection, CSF IgM antibody tests may be positive when PCR fails to detect viral DNA, and both tests should be considered complementary rather than mutually exclusive.

Demonstration of CSF WNV IgM antibodies is diagnostic of WNV encephalitis because the high molecular weight of IgM antibodies restricts their passage from serum to CSF through the blood-brain barrier and their presence in CSF is therefore indicative of intrathecal synthesis. Timing of antibody testing may be important because the rate of CSF WNV IgM seropositivity increases during the first week after illness onset, reaching 80% or higher on day 7 after symptom onset. Although serum and CSF IgM antibodies generally persist for only a few months after acute infection, there are exceptions to this rule, and WNV serum IgM has been shown to persist in some patients for >1 year following acute infection.

MRI, CT, and EEG Patients with suspected encephalitis almost invariably undergo neuroimaging studies and often electroencephalogram (EEG). These tests help identify or exclude alternative diagnoses and assist in the differentiation between a focal and a diffuse encephalitic process. Specific focal findings in a patient with encephalitis should always raise the possibility of HSV encephalitis. Examples of focal findings found in HSV encephalitis include: (1) areas of increased signal intensity in the frontotemporal, cingulate, or insular regions of the brain on T2-weighted, fluid-attenuated inversion recovery (FLAIR), or diffusion-weighted magnetic resonance imaging (MRI) **(Fig. 142-1)**; (2) focal areas of low absorption, mass effect, and contrast enhancement in frontotemporal areas on computed tomography (CT); or (3) periodic focal temporal lobe spikes on a background of slow or low-amplitude ("flattened") activity on EEG. Approximately 10% of patients with PCR-documented HSV encephalitis may have a normal MRI, although nearly 80% will have asymmetric abnormalities in the temporal lobe, and an additional 10% in extratemporal regions. The addition of FLAIR and diffusion-weighted images to the standard MRI sequences enhances sensitivity. Children with HSV encephalitis may have atypical patterns of MRI lesions and often show involvement of brain regions outside the frontotemporal areas. CT is less sensitive than MRI and is normal in up to 20–35% of patients. EEG abnormalities occur in >75% of PCR-documented cases of HSV encephalitis; they typically involve the temporal lobes but are often nonspecific. Some patients with HSV encephalitis have a distinctive EEG pattern consisting of periodic, stereotyped, sharp-and-slow complexes originating in one or both temporal lobes and repeating at regular intervals of 2–3 s. The periodic complexes are typically noted between days 2 and 15 of the illness and are present in two-thirds of pathologically proven cases of HSV encephalitis.

Significant MRI abnormalities are found in only approximately two-thirds of patients with WNV encephalitis, a frequency less than that found with HSV encephalitis. When present, abnormalities often involve deep brain structures, including the thalamus, basal ganglia, and brainstem, rather than the cortex, and may only be apparent on T2/FLAIR images. Similar MRI patterns can be observed in patients infected with other arboviruses, including other flaviviruses such as Japanese encephalitis virus and St. Louis encephalitis virus, as well the *Alphavirus* EEE virus. EEGs in patients with WNV encephalitis typically show generalized slowing that may be more anteriorly prominent rather than the temporally predominant pattern of sharp or periodic discharges more characteristic of HSV encephalitis. Patients with VZV encephalitis may show multifocal areas of hemorrhagic and ischemic infarction, reflecting the tendency of this virus to produce a CNS vasculopathy rather than a true encephalitis. Immunocompromised

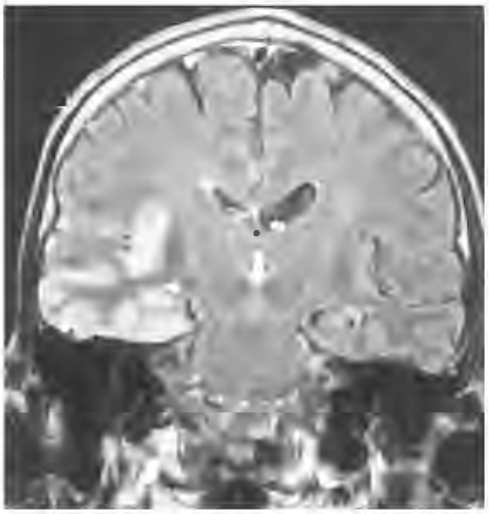

FIGURE 142-1 Coronal fluid-attenuated inversion recovery (FLAIR) magnetic resonance image from a patient with herpes simplex encephalitis. Note the area of increased signal in the right temporal lobe (*left side of image*) confined predominantly to the gray matter. This patient had predominantly unilateral disease; bilateral lesions are more common but may be quite asymmetric in their intensity.

TABLE 142-2 Use of Diagnostic Tests in Encephalitis

The best test for WNV encephalitis is the *CSF IgM antibody test.* The prevalence of positive CSF IgM tests increases by about 10% per day after illness onset and reaches 70–80% by the end of the first week. Serum WNV IgM can provide evidence for recent WNV infection, but in the absence of other findings does not establish the diagnosis of neuroinvasive disease (meningitis, encephalitis, acute flaccid paralysis).

Approximately 80% of patients with proven HSV encephalitis have *MRI* abnormalities involving the temporal lobes. This percentage likely increases to >90% when FLAIR and diffusion-weighted MRI sequences are also used. The absence of temporal lobe lesions on MRI reduces the likelihood of HSV encephalitis and should prompt consideration of other diagnostic possibilities.

The *CSF HSV PCR* test may be negative in the first 72 h of symptoms of HSV encephalitis. A repeat study should be considered in patients with an initial early negative PCR in whom diagnostic suspicion of HSV encephalitis remains high and no alternative diagnosis has yet been established.

Detection of *intrathecal synthesis* (increased CSF/serum HSV antibody ratio corrected for breakdown of the blood-brain barrier) of *HSV-specific antibody* may be useful in diagnosis of HSV encephalitis in patients in whom only late (>1 week after onset) CSF specimens are available and PCR studies are negative. Serum serology alone is of no value in diagnosis of HSV encephalitis due to the high seroprevalence rate in the general population.

Negative *CSF viral cultures* are of no value in excluding the diagnosis of HSV or EBV encephalitis.

VZV CSF IgM antibodies may be present in patients with a negative VZV CSF PCR. Both tests should be performed in patients with suspected VZV CNS disease.

The specificity of *EBV CSF PCR* for diagnosis of CNS infection is unknown. Positive tests may occur in patients with a CSF pleocytosis due to other causes. Detection of EBV CSF IgM or intrathecal synthesis of antibody to VCA supports the diagnosis of EBV encephalitis. Serologic studies consistent with acute EBV infection (e.g., IgM VCA, presence of antibodies against EA but not against EBNA) can help support the diagnosis.

In addition to broad-based PCR assays for bacterial and fungal infections, metagenomic next-generation sequencing (mNGS) allows for unbiased detection of nucleic acids from the whole range of infectious agents (except prions), which can then be confirmed by independent pathogen-specific techniques. Due to the sensitivity of this technology, there is a risk of false-positive results. As this technology becomes refined and the turnaround time faster, mNGS is likely to become a routine test on CSF for the diagnosis of encephalitis.

Abbreviations: CNS, central nervous system; CSF, cerebrospinal fluid; DWI, diffusion-weighted imaging; EA, early antigen; EBNA, EBV-associated nuclear antigen; EBV, Epstein-Barr virus; FLAIR, fluid-attenuated inversion recovery; HSV, herpes simplex virus; IgM, immunoglobulin M; MRI, magnetic resonance imaging; PCR, polymerase chain reaction; VCA, viral capsid antibody; VZV, varicella-zoster virus; WNV, West Nile virus.

adult patients with CMV often have enlarged ventricles with areas of increased T2 signal on MRI outlining the ventricles and subependymal enhancement on T1-weighted postcontrast images. Prominent cerebellar T2/FLAIR abnormalities have been observed with Powassan virus encephalitis and in children with herpesviruses like EBV and VZV. **Table 142-2** highlights specific diagnostic test results in encephalitis that can be useful in clinical decision-making.

Brain Biopsy Brain biopsy is now generally reserved for patients in whom CSF PCR studies fail to lead to a specific diagnosis and who have focal abnormalities on MRI, no serologic evidence of autoimmune disease, and continue to show progressive clinical deterioration despite treatment with acyclovir and supportive therapy.

DIFFERENTIAL DIAGNOSIS

Infection by a variety of other organisms can mimic viral encephalitis. In studies of biopsy-proven HSV encephalitis, common infectious mimics of focal viral encephalitis included mycobacteria, fungi, rickettsiae, *Listeria, Mycoplasma*, and other bacteria (including *Bartonella* sp.) as well as neurosyphilis. There are an increasing number of antibodies reported that cause autoimmune encephalitis and mimic those caused by viral infection, including those associated with antibodies against *N*-methyl-D-aspartate (NMDA) receptor, two components of the voltage-gated potassium channels/leucine-rich glioma inactivated protein-1 (LGI-1) and contracting-associated protein-like 2 (CASPR2), α-amino-3-hydroxy-5-methyl-4-isoxazolepropionic acid (AMPA), γ-aminobutyric acid (GABA) receptors, and glutamic acid decarboxylase (GAD 65) **(Chap. 99)**. In most cases, diagnosis is made by detection of the specific autoantibodies in serum and/or CSF. NMDA receptor antibodies have been reported in up to 25% of patients who have recovered from HSV encephalitis, and their presence should not exclude appropriate testing and treatment for HSV encephalitis. The development of NMDA receptor antibodies in patients with HSV encephalitis may contribute to new or worsening symptoms in the weeks following recovery from HSV encephalitis. Autoimmune encephalitis may also be associated with specific cancers (paraneoplastic) and onconeuronal antibodies (e.g., anti-Hu, Yo, Ma2, amphiphysin, CRMP5, CV2). Subacute or chronic forms of encephalitis may occur in association with autoantibodies against thyroglobulin and thyroperoxidase (Hashimoto's encephalopathy) and with prion diseases.

Infection caused by the ameba *Naegleria fowleri* can also cause acute meningoencephalitis (primary amebic meningoencephalitis), whereas that caused by *Acanthamoeba* and *Balamuthia* more typically produces subacute or chronic granulomatous amebic meningoencephalitis. *Naegleria* thrive in warm, iron-rich pools of water, including those found in drains, canals, and both natural and human-made outdoor pools **(Chap. 230)**. Infection has typically occurred in immunocompetent children with a history of swimming in potentially infected water. The CSF, in contrast to the typical profile seen in viral encephalitis, often resembles that of bacterial meningitis with a neutrophilic pleocytosis and hypoglycorrhachia. Motile trophozoites can be seen in a wet mount of warm, fresh CSF. There have been an increasing number of cases of *Balamuthia mandrillaris* amebic encephalitis in children and immunocompetent adults, mimicking acute viral encephalitis. This organism has also been associated with encephalitis in recipients of transplanted organs from a donor with unrecognized infection. No effective treatment has been approved, and mortality approaches 100%. There have been a few case reports of patients who recovered with nitroxoline therapy.

Encephalitis can be caused by the raccoon pinworm *Baylisascaris procyonis*. Clues to the diagnosis include a history of raccoon exposure, especially of playing in or eating dirt potentially contaminated with raccoon feces. Most patients are children, and many have an associated eosinophilia.

Once nonviral causes of encephalitis have been excluded, the major diagnostic challenge is to distinguish HSV from other viruses that cause encephalitis. This distinction is particularly important because in virtually every other instance the therapy is supportive, whereas specific and effective antiviral therapy is available for HSV, and its efficacy is enhanced when it is instituted early in the course of infection. HSV encephalitis should be considered when clinical features suggest involvement of the inferomedial frontotemporal regions of the brain, including prominent olfactory or gustatory hallucinations, anosmia, unusual or bizarre behavior or personality alterations, or memory disturbance. HSV encephalitis should always be suspected in patients with signs and symptoms consistent with acute encephalitis who have focal findings on clinical examination, neuroimaging studies, or EEG. The diagnostic procedure of choice in these patients is CSF PCR analysis for HSV. A positive CSF PCR establishes the diagnosis, and a negative test dramatically reduces the likelihood of HSV encephalitis (see above).

The anatomic distribution of lesions may provide an additional clue to diagnosis. Patients with rapidly progressive encephalitis and prominent brainstem signs, symptoms, or neuroimaging abnormalities may be infected by flaviviruses (WNV, St. Louis encephalitis virus, Japanese encephalitis virus), HSV, enterovirus A71 (EV-A71), rabies, or *Listeria monocytogenes*. Significant involvement of deep gray matter structures, including the basal ganglia and thalamus, should also suggest possible flavivirus infection. These patients may present clinically with prominent movement disorders (tremor, myoclonus) or other parkinsonian features. Patients with WNV infection can also present with a poliomyelitis-like AFM, as can patients infected with EV-A71, EV-D68, and less commonly, other enteroviruses. Acute flaccid paralysis is characterized by the acute onset of a lower motor neuron type of weakness with flaccid tone, reduced or absent reflexes, and relatively

preserved sensation. Patients often have multisegmental increased FLAIR and T2 signal in the anterior horns of the spinal cord and a CSF lymphocytic pleocytosis.

Epidemiologic factors may provide important clues to the diagnosis of viral encephalitis. Particular attention should be paid to the season of the year; the geographic location and travel history; and possible exposure to animal bites or scratches, rodents, and ticks. Although transmission from the bite of an infected dog remains the most common cause of rabies **(Chap. 214)** worldwide, in the United States very few cases of dog rabies occur, and the most common risk factor is exposure to bats—although a clear history of a bite or scratch is often lacking. The classic clinical presentation of encephalitic (furious) rabies is fever, fluctuating consciousness, and autonomic hyperactivity. Phobic spasms of the larynx, pharynx, neck muscles, and diaphragm can be triggered by attempts to swallow water (*hydrophobia*) or by inspiration (*aerophobia*). Patients may also present with paralytic (dumb) rabies characterized by acute ascending paralysis. Rabies due to the bite of a bat has a different clinical presentation than classic rabies due to a dog or wolf bite. Patients present with focal neurologic deficits, myoclonus, seizures, and hallucinations; phobic spasms are not a typical feature. Patients with rabies have a CSF lymphocytic pleocytosis and may show areas of increased T2 signal abnormality in the brainstem, hippocampus, and hypothalamus. Diagnosis can be made by finding rabies virus antigen in brain tissue or in the neural innervation of hair follicles at the nape of the neck. PCR amplification of viral nucleic acid from CSF and saliva or tears may also enable diagnosis. Serology is frequently negative in both serum and CSF in the first week after onset of infection, which limits its acute diagnostic utility. No specific therapy is available, and cases are almost invariably fatal, with isolated survivors having devastating neurologic sequelae.

State public health authorities provide a valuable resource concerning isolation of particular agents in individual regions. Regular updates concerning the number, type, and distribution of cases of arboviral encephalitis can be found on the Centers for Disease Control and Prevention and U.S. Geological Survey (USGS) websites (*http://www.cdc.gov* and *http://diseasemaps.usgs.gov*).

TREATMENT

Viral Encephalitis

Specific antiviral therapy should be initiated when appropriate. Vital functions, including respiration and blood pressure, should be monitored continuously and supported as required. In the initial stages of encephalitis, many patients will require care in an intensive care unit. Basic management and supportive therapy should include careful monitoring of ICP, fluid restriction, avoidance of hypotonic intravenous solutions, and suppression of fever. Seizures should be treated with standard anticonvulsant regimens, and prophylactic therapy should be considered in view of the high frequency of seizures in severe cases of encephalitis. As with all seriously ill, immobilized patients with altered levels of consciousness, encephalitis patients are at risk for aspiration pneumonia, stasis ulcers and decubiti, contractures, deep venous thrombosis and its complications, and infections of indwelling lines and catheters.

Acyclovir is of benefit in the treatment of HSV and should be started empirically in patients with suspected viral encephalitis, especially if focal features are present, while awaiting viral diagnostic studies. Treatment should be discontinued in patients found not to have HSV encephalitis, with the possible exception of patients with severe encephalitis due to VZV or EBV. HSV, VZV, and EBV all encode an enzyme deoxypyrimidine (thymidine) kinase that phosphorylates acyclovir to produce acyclovir-5′-monophosphate. Host cell enzymes then phosphorylate this compound to form a triphosphate derivative. It is the triphosphate that acts as an antiviral agent by inhibiting viral DNA polymerase and by causing premature termination of nascent viral DNA chains. The specificity of action depends on the fact that uninfected cells do not phosphorylate significant amounts of acyclovir to acyclovir-5′-monophosphate. A second level of specificity is provided by the fact that the acyclovir triphosphate is a more potent inhibitor of viral DNA polymerase than of the analogous host cell enzymes.

Adults should receive a dose of 10 mg/kg of acyclovir intravenously every 8 h (30 mg/kg per day total dose) for 21 days. Neonatal HSV CNS infection is less responsive to acyclovir therapy than HSV encephalitis in adults; it is recommended that neonates with HSV encephalitis receive 20 mg/kg of acyclovir every 8 h (60 mg/kg per day total dose) for a minimum of 21 days.

Prior to intravenous administration, acyclovir should be diluted to a concentration ≤7 mg/mL. (A 70-kg person would receive a dose of 700 mg, which would be diluted in a volume of 100 mL.) Each dose should be infused slowly over 1 h, rather than by rapid or bolus infusion, to minimize the risk of renal dysfunction. Care should be taken to avoid extravasation or intramuscular or subcutaneous administration. The alkaline pH of acyclovir can cause local inflammation and phlebitis (9%). Dose adjustment is required in patients with impaired renal glomerular filtration. Penetration into CSF is excellent, with average drug levels ~50% of serum levels. Complications of therapy include elevations in blood urea nitrogen and creatinine levels (5%), thrombocytopenia (6%), gastrointestinal toxicity (nausea, vomiting, diarrhea) (7%), and neurotoxicity (lethargy or obtundation, disorientation, confusion, agitation, hallucinations, tremors, seizures) (1%). Acyclovir resistance may be mediated by changes in either the viral deoxypyrimidine kinase or DNA polymerase. To date, acyclovir-resistant isolates have not been a significant clinical problem in immunocompetent individuals. It is now appreciated that some patients with worsening symptoms in the weeks following recovery from HSV encephalitis have developed NMDA receptor encephalitis requiring immunosuppression rather than having developed an acyclovir-resistant isolate. However, there have been reports of clinically virulent acyclovir-resistant HSV isolates from sites outside the CNS in immunocompromised individuals, including those with AIDS.

Oral antiviral drugs with efficacy against HSV, VZV, and EBV, including acyclovir, famciclovir, and valacyclovir, have not been evaluated in the treatment of encephalitis as primary therapy. Additional oral valaciclovir following a 14- to 21-day course of intravenous acyclovir does not improve outcomes in adult patients with HSV encephalitis. The role of adjunctive intravenous glucocorticoids in treatment of HSV and VZV infection remains unclear. Experimental models and case reports of HSV encephalitis suggest that glucocorticoids may be efficacious, although no data from randomized controlled human trials are available. Ganciclovir and foscarnet, as combination therapy, are used in the treatment of CMV-related CNS infections. Cidofovir (see below) may provide an alternative in patients who fail to respond to ganciclovir and foscarnet, although data concerning its use in CMV CNS infections are extremely limited.

Ganciclovir is a synthetic nucleoside analogue of 2′-deoxyguanosine. The drug is preferentially phosphorylated by virus-induced cellular kinases. Ganciclovir triphosphate acts as a competitive inhibitor of the CMV DNA polymerase, and its incorporation into nascent viral DNA results in premature chain termination. Following intravenous administration, CSF concentrations of ganciclovir are 25–70% of coincident plasma levels. The usual dose for treatment of severe neurologic illnesses is 5 mg/kg every 12 h given intravenously at a constant rate over 1 h. Induction therapy is followed by maintenance therapy of 5 mg/kg every day for an indefinite period. Induction therapy should be continued until patients show a decline in CSF pleocytosis and a reduction in CSF CMV DNA copy number on quantitative PCR testing (where available). Doses should be adjusted in patients with renal insufficiency. Treatment is often limited by the development of granulocytopenia and thrombocytopenia (20–25%), which may require reduction in or discontinuation of therapy. Gastrointestinal side effects, including nausea, vomiting, diarrhea, and abdominal pain, occur in ~20% of patients. Some patients treated with ganciclovir for CMV retinitis have developed retinal detachment, but the causal relationship to

ganciclovir treatment is unclear. Valganciclovir is an orally bioavailable prodrug that can generate high serum levels of ganciclovir, although studies of its efficacy in treating CMV CNS infections are limited.

Foscarnet is a pyrophosphate analogue that inhibits viral DNA polymerases by binding to the pyrophosphate-binding site. Following intravenous infusion, CSF concentrations range from 15 to 100% of coincident plasma levels. The usual dose for serious CMV-related neurologic illness is 60 mg/kg every 8 h administered by constant infusion over 1 h. Induction therapy for 14–21 days is followed by maintenance therapy (60–120 mg/kg per day). Induction therapy may need to be extended in patients who fail to show a decline in CSF pleocytosis and a reduction in CSF CMV DNA copy number on quantitative PCR tests (where available). Approximately one-third of patients develop renal impairment during treatment, which is reversible following discontinuation of therapy in most, but not all, cases. This is often associated with elevations in serum creatinine and proteinuria and is less frequent in patients who are adequately hydrated. Many patients experience fatigue and nausea. Reductions in serum calcium, magnesium, and potassium occur in ~15% of patients and may be associated with tetany, cardiac rhythm disturbances, or seizures.

Cidofovir is a nucleotide analogue that is effective in treating CMV retinitis and equivalent to or better than ganciclovir in some experimental models of murine CMV encephalitis, although data concerning its efficacy in human CMV CNS disease are limited. The usual dose is 5 mg/kg intravenously once weekly for 2 weeks, then biweekly for two or more additional doses, depending on clinical response. Patients must be prehydrated with normal saline (e.g., 1 L over 1–2 h) prior to each dose and treated with probenecid (e.g., 1 g 3 h before cidofovir and 1 g 2 and 8 h after cidofovir). Nephrotoxicity is common; the dose should be reduced if renal function deteriorates.

Intravenous ribavirin (15–25 mg/kg per day in divided doses given every 8 h) has been reported to be of benefit in isolated cases of severe encephalitis due to California encephalitis (La Crosse) virus. Ribavirin might be of benefit for the rare patients, typically infants or young children, with severe adenovirus or rotavirus encephalitis and in patients with encephalitis due to LCMV or other arenaviruses. However, clinical trials are lacking. Hemolysis, with resulting anemia, has been the major side effect limiting therapy.

No specific antiviral therapy of proven efficacy is currently available for treatment of WNV encephalitis. Patients have been treated with interferon-α, ribavirin, an Israeli IVIg preparation that contains high-titer anti-WNV antibody (Omr-IgG-am), and humanized monoclonal antibodies directed against the viral envelope glycoprotein (*www.clinicaltrials.gov*, identifiers NCT00927953 and 00515385). Omr-IgG-am did not improve outcomes in patients with WNV neuroinvasive disease, but the study design was potentially flawed as some patients received drug up to a week after symptom onset, when expected benefit may have been minimal. Of the six West Nile virus human vaccines that advanced into phase I clinical trials, only two live attenuated virus vaccines have advanced to phase II clinical trials. There has been success with four equine vaccines, but all require multiple primary doses and annual boosters. The ideal human WNV vaccine needs to provide complete and long-lasting protective immunity after the administration of a single dose. Effective vaccines are already in human use for prevention of other flavivirus infections including Japanese encephalitis and yellow fever.

The Centers for Disease Control and Prevention (CDC) Clinical Considerations for COVID-19 treatment in outpatients as of January 2024 state that the preferred treatment for mild to moderate COVID-19 infection in adults is oral ritonavir-boosted nirmatrelvir. This antiviral is U.S. Food and Drug Administration (FDA) approved in adults with mild-to-moderate COVID-19 with symptoms of <5 days in duration who are at high risk of developing severe COVID-19 due to older age (>50 years) or other risk factors. It has also been approved under emergency use authorization (EUA) for 12- to 17-year-olds. A 3-day course of intravenous remdesivir is the second preferred treatment option after ritonavir-boosted nirmatrelvir for adults and pediatric patients as young as 28 days. Immunocompromised patients may be treated with longer or additional courses. The FDA has issued an EUA for the use of COVID-19 convalescent plasma with high titers of anti–SARS-CoV-2 antibodies for the treatment of COVID-19 in immunocompromised patients from disease or immunosuppressive therapy. The antiviral molnupiravir can be used for therapy according to the CDC but has been less effective in clinical trials than ritonavir-boosted nirmatrelvir or remdesivir.

SEQUELAE

There is considerable variation in the incidence and severity of sequelae in patients surviving viral encephalitis. In the case of EEE virus infection, nearly 80% of survivors have severe neurologic sequelae. At the other extreme are infections due to EBV, California encephalitis virus, and Venezuelan equine encephalitis virus, where severe sequelae are unusual. For example, ~5–15% of children infected with La Crosse virus have a residual seizure disorder, and 1% have persistent hemiparesis. Detailed information about sequelae in patients with HSV encephalitis treated with acyclovir is available from the NIAID-Collaborative Antiviral Study Group (CASG) trials. Of 32 acyclovir-treated patients, 26 survived (81%). Of the 26 survivors, 12 (46%) had no or only minor sequelae, 3 (12%) were moderately impaired (gainfully employed but not functioning at their previous level), and 11 (42%) were severely impaired (requiring continuous supportive care). The incidence and severity of sequelae were directly related to the age of the patient and the level of consciousness at the time of initiation of therapy. Patients with severe neurologic impairment (Glasgow Coma Scale score 6) at initiation of therapy either died or survived with severe sequelae. Young patients (<30 years) with good neurologic function at initiation of therapy did substantially better (100% survival, 62% with no or mild sequelae) compared with their older counterparts (>30 years; 64% survival, 57% no or mild sequelae). Many patients with WNV infection have sequelae, including cognitive impairment; weakness; and hyper- or hypokinetic movement disorders, including tremor, myoclonus, and parkinsonism. In a large longitudinal study of prognosis in 156 patients with WNV infection, the mean time to achieve recovery (defined as 95% of maximal predicted score on specific validated tests) was 112–148 days for fatigue, 121–175 days for physical function, 131–139 days for mood, and 302–455 days for mental function (the longer interval in each case representing patients with invasive CNS disease).

CHRONIC ENCEPHALITIS

PROGRESSIVE MULTIFOCAL LEUKOENCEPHALOPATHY

Clinical Features and Pathology Progressive multifocal leukoencephalopathy (PML) is characterized pathologically by multifocal areas of demyelination of varying size distributed throughout the brain but sparing the spinal cord and optic nerves. In addition to demyelination, there are characteristic cytologic alterations in both astrocytes and oligodendrocytes. Astrocytes are enlarged and contain hyperchromatic, deformed, and bizarre nuclei and frequent mitotic figures. Oligodendrocytes have enlarged, densely staining nuclei that contain viral inclusions formed by crystalline arrays of JC virus (JCV) particles. Patients often present with visual deficits (45%), typically a homonymous hemianopia; mental impairment (38%) (dementia, confusion, personality change); weakness, including hemi- or monoparesis; and ataxia. Seizures occur in ~20% of patients, predominantly in those with lesions abutting the cortex.

Almost all patients have an underlying immunosuppressive disorder or are receiving immunomodulatory therapy. The most common immunosuppressive disorder associated with PML is AIDS, followed by hematologic malignancies, solid organ and hematopoietic stem cell transplant, and chronic inflammatory diseases, including sarcoidosis. It

has been estimated that up to 5% of AIDS patients will develop PML. There has been considerable progress in the development of disease-modifying therapies (DMTs) for multiple sclerosis and inflammatory bowel disease. Of the DMTs, the highest risk of PML is associated with natalizumab, a humanized monoclonal antibody that inhibits lymphocyte trafficking into CNS and bowel mucosa by binding to α_4 integrins. Overall risk in these patients has been estimated at ~4 PML cases per 1000 treated patients, but the risk depends on a variety of factors including anti-JCV antibody serostatus and the magnitude of the JCV antibody response, prior immunosuppressive therapy use, and duration of natalizumab therapy. Patients who lack detectable JCV antibody have a risk of developing PML of <0.1 case/1000 patients, whereas those who are JCV seropositive and have been exposed to prior immunosuppressive therapy and have received >24 months of natalizumab therapy have a risk of >1.3 cases/100 treated patients. Some recent studies suggest that extended dosing interval regimens of natalizumab (at 6- to 8-week intervals rather than the conventional 4-week interval) may significantly reduce the risk of PML. Among JCV-seropositive individuals, those with higher JCV antibody index values, presumably due to the "immunizing" effects of more frequent JCV reactivations, appear to be at higher risk than those with low antibody indices. Alternative therapies are preferred in patients who are JCV seropositive. PML cases have also been reported in patients receiving other immunomodulatory agents including rituximab, ocrelizumab, fingolimod, and dimethyl fumarate, although the relative risks have not been clearly established, and many individual cases are complicated by previous exposure to other therapies including natalizumab. Prolonged lymphopenia, a side effect of dimethyl fumarate, is associated with an increased risk of PML. The basic clinical and diagnostic features appear to be similar in HIV-associated PML and PML associated with immunomodulatory drugs with the exception of an increased likelihood of MRI enhancement of PML lesions in immunomodulatory cases. In natalizumab-associated PML, patients will also almost invariably develop clinical and radiographic worsening of lesions with discontinuation of therapy, attributed to development of immune reconstitution inflammatory syndrome (IRIS).

Diagnostic Studies The diagnosis of PML is frequently suggested by MRI. MRI reveals multifocal asymmetric, coalescing white matter lesions located periventricularly, in the centrum semiovale, in the parietal-occipital region, and in the cerebellum. These lesions have increased signal on T2 and FLAIR images and decreased signal on T1-weighted images. HIV-PML lesions are classically nonenhancing (90%), but patients with immunomodulatory drug-associated PML may have peripheral ring enhancement. PML lesions are not typically associated with edema or mass effect. CT scans, which are less sensitive than MRI for the diagnosis of PML, often show hypodense nonenhancing white matter lesions. JCV infection may also induce rare cases of encephalitis and cerebellitis in immunocompromised patients that are distinct from PML and have differing neuroimaging features.

The CSF is typically normal, although mild elevation in protein and/or IgG may be found. Pleocytosis occurs in <25% of cases, is predominantly mononuclear, and rarely exceeds 25 cells/μL. PCR amplification of JCV DNA from CSF has become an important diagnostic tool. The presence of a positive CSF PCR for JCV DNA in association with typical MRI lesions in the appropriate clinical setting is diagnostic of PML, reflecting the assay's relatively high specificity (92–100%); however, sensitivity is variable, and a negative CSF PCR does not exclude the diagnosis. In HIV-negative patients and HIV-positive patients not receiving antiretroviral therapy (ART), sensitivity is likely 70–90%. In ART-treated patients, sensitivity may be closer to 60%, reflecting the lower JCV CSF viral load in this relatively more immunocompetent group. Patients with natalizumab-associated PML have highly variable amounts of JCV DNA in CSF. Some patients may have negative CSF PCRs performed in commercial laboratories, where assay detection thresholds are typically >100 JCV DNA copies/μL, but positive results in reference laboratories using supersensitive techniques (detection of 10 JCV copies/μL or less). CSF studies with quantitative JCV PCR indicate that patients with low JCV loads (<100 copies/μL) have a generally better prognosis than those with higher viral loads. Patients with negative CSF PCR studies may require brain biopsy for definitive diagnosis. In biopsy or necropsy specimens of brain, JCV antigen and nucleic acid can be detected by immunocytochemistry, in situ hybridization, or PCR amplification.

Serologic studies of JCV antibody are of modest value in diagnosis of PML due to the high basal seroprevalence level, although the absence of detectable JCV antibody may be useful in reducing the likelihood of PML in the differential diagnosis, as PML results from viral reactivation in previously infected individuals and virtually all confirmed cases have been JCV seropositive at diagnosis. Antibody testing may also be useful in risk stratification of patients receiving immunomodulatory therapies.

TREATMENT

Progressive Multifocal Leukoencephalopathy

No consistently effective therapy for PML is available. There are case reports of potential beneficial effects of the 5-HT_{2a} receptor antagonist mirtazapine, which may inhibit binding of JCV to its receptor on oligodendrocytes. Retrospective noncontrolled studies have also suggested a possible beneficial effect of treatment with interferon-α. Neither of these agents has been tested in randomized controlled clinical trials. A prospective multicenter clinical trial to evaluate the efficacy of the antimalarial drug mefloquine failed to show benefit. Intravenous and/or intrathecal cytarabine were not shown to be of benefit in a randomized controlled trial in HIV-associated PML, although some experts suggest that cytarabine may have therapeutic efficacy in situations where breakdown of the blood-brain barrier allows sufficient CSF penetration. A randomized controlled trial of cidofovir in HIV-associated PML also failed to show significant benefit. Because PML almost invariably occurs in immunocompromised individuals, any therapeutic interventions designed to enhance or restore immunocompetence should be considered; a small series of patients treated with the PD-1 inhibitor pembrolizumab demonstrated clinical improvement and stabilization. Positive results in small case series have also been reported in patients receiving infusions of BK or JC virus–specific cytotoxic T lymphocytes. Perhaps the most dramatic demonstration of the benefit of restoring immune competence is disease stabilization and, in rare cases, improvement associated with an improved immune status of HIV-positive patients with AIDS following institution of ART. In HIV-positive PML patients treated with ART, 1-year survival is ~50%, although up to 80% of survivors may have significant neurologic sequelae. HIV-positive PML patients with higher CD4 counts (>300/μL) and low or nondetectable HIV viral loads have a better prognosis than those with lower CD4 counts and higher viral loads. Although institution of ART enhances survival in HIV-positive PML patients, the associated immune reconstitution in patients with an underlying opportunistic infection such as PML may also result in a severe CNS inflammatory syndrome (IRIS) associated with clinical worsening, CSF pleocytosis, and the appearance of new enhancing MRI lesions. Patients receiving natalizumab or other immunomodulatory therapies who are suspected of having PML should have therapy immediately halted. Patients should be closely monitored for development of IRIS, which is generally treated with intravenous glucocorticoids, although controlled clinical trials of efficacy remain lacking.

SUBACUTE SCLEROSING PANENCEPHALITIS

Subacute sclerosing panencephalitis (SSPE) is a rare, chronic, progressive demyelinating disease of the CNS associated with a chronic nonpermissive infection of brain tissue with measles virus. The frequency has been estimated at 1 in 100,000–500,000 measles cases. An average of five cases per year is reported in the United States. The incidence has declined dramatically since the introduction of a measles vaccine, but we may expect a rise in cases over the coming decades with increasing vaccine hesitancy and rising measles cases in the United States and