18 Low Back Pain

Steven P. Cohen, Eric J. Wang

EPIDEMIOLOGY

Low back pain (LBP) is among the leading causes of years lived with disability worldwide and the principal cause of work-related disability in nearly all industrialized countries. Between 28 and 34% of Americans experienced LBP in the past 3 months, with LBP accounting for >57 million unique patient visits. The all-cause medical costs in the United States are estimated to exceed $300 billion per year. Risk factors for chronic LBP include female sex, African-American race, older age, being unemployed, obesity, and sedentary lifestyle.

PAIN CATEGORIZATION

The categorization of pain is important because it predicates treatment decisions at all levels of care.

Nociceptive pain is the most common form of chronic pain in general and LBP in particular and results from activity in neural pathways secondary to actual or potentially tissue-damaging stimuli. Nociceptive LBP typically worsens with activities that stress the structures responsible for pain, is usually secondary to degenerative changes that occur over time, and with the exception of myofascial pain, tends to be progressive in nature. Mechanical pain can radiate to the upper and sometimes lower leg depending on the structure and level(s) involved and the magnitude of the stimulus (greater stimulation results in more distal radiation). However, referral patterns of mechanical pain tend to be more variable and more proximal than for radicular pain, and do not follow a dermatomal distribution.

Neuropathic pain is defined as pain caused by injury or disease affecting the somatosensory nervous system. In contrast to nociceptive pain, neuropathic pain is often accompanied by sensory abnormalities such as paresthesias, numbness, and sometimes allodynia; is more unpredictable and associated with wide fluctuations and paroxysms; and often presents with focal neurologic findings (e.g., loss of sensorimotor functions or reflexes). It is important to recognize that radiculopathy can occur without pain, and radicular pain frequently occurs in the absence of neurologic deficits.

The newest recognized category of pain is *nociplastic*, which is pain that develops due to abnormal processing of pain signals without evidence of tissue damage or pathology involving the somatosensory system (e.g., central sensitization). Nociplastic back pain, often termed "nonspecific LBP," is characterized by diffuse pain, superficial tenderness, and pain patterns that deviate from normal neuroanatomy. Patients may experience pain-induced weakness, multiple concomitant pain conditions, and sensory deficits outside of classic dermatomal maps. Table 18-1 provides a summary of the distinguishing characteristics among nociceptive, neuropathic, and nociplastic pain conditions.

Clinical studies estimate that more than one-third (range <10–55%) of patients with chronic LBP report neuropathic qualities, with 10–20% of the overall back pain population having nociplastic pain. However, different pain categories may occur simultaneously. For example, the predisposing pathology that results in herniated disks (disk degeneration with annular tears) and spinal stenosis (bulging, degenerative disks, facet joint and ligamentum flavum hypertrophy, spondylolisthesis [e.g., anterior (anterolisthesis) or posterior (retrolisthesis) displacement of a vertebral body, decreasing the diameter of the spinal canal]) frequently results in concomitant nociceptive pain, and individuals with central sensitization often experience neuropathic and nociceptive pain at lower thresholds than other people. Studies performed in

TABLE 18-1 Distinguishing Characteristics of Nociceptive, Neuropathic, and Nociplastic Low Back Pain

CLINICAL CHARACTERISTIC	NOCICEPTIVE PAIN	NEUROPATHIC PAIN	NOCIPLASTIC PAIN
Etiology	Cumulative stress	Usually preceded by spine degeneration; herniated disk may sometimes occur after inciting event	Usually insidious, but sometimes occurs after physically or psychologically traumatic event
Onset	Insidious	Usually insidious	Usually insidious
Examples/causes	Degenerative spondylosis, myofascial pain	Herniated disk, spinal stenosis	Nonspecific back pain; may present as mechanical or radicular pain
Descriptors	Aching, deep, throbbing	Sharp, shooting, lancinating	Usually similar to neuropathic descriptors, but may include nociceptive ones as well
Sensory deficits	Uncommon	Common	Occur sometimes, but often outside of any dermatomal distribution
Motor deficits	May be pain-induced	Frequent	Pain-induced weakness, fatigue common
Hypersensitivity	Occasionally, with myofascial pain	Common	Extremely common
Pain pattern	May be referred into leg (usually proximally) in nondermatomal distribution	Reflects dermatomal pattern	Diffuse, often outside of any anatomic pain patterns
Precipitating/relieving factors	Worse with activities that stress structure	More unpredictable; spinal stenosis may be alleviated by forward flexion	Unpredictable, typically worse with stress
Autonomic signs	Uncommon	Present in up to 25% of patients	Sympathetic nervous system hyperactivity and postural orthostatic tachycardia syndrome (POTS) very common
Accompanying symptoms	Co-existing psychopathology common, and increased rate of neck pain	Higher levels of psychological stress and quality of life decrements than in nociceptive pain	Very high levels of psychological distress and sleep abnormalities; generally co-prevalent with other nociplastic conditions
Diagnosis	Imaging correlated with history and physical exam and diagnostic blocks	History and neurologic exam, instruments such as s-LANSS and painDETECT[a]	History (e.g., multiple concomitant nociplastic and nonnociplastic conditions), physical exam (e.g., diffuse tenderness), instruments (central sensitization inventory), and psychophysical tests (conditioned pain modulation)

[a]S-LANSS (self-report version of the Leeds Assessment of Neuropathic Symptoms and Signs) and painDETECT are patient-reported questionnaires used to distinguish neuropathic from nonneuropathic pain. Developed before the term *nociplastic pain* was proposed, individuals scoring in the predominantly or likely "neuropathic pain" range in the absence of identifiable nerve damage are often presumed to have nociplastic pain.

orthopedic populations suggest that over half of individuals may have mixed pain phenotypes.

NATURAL COURSE

MECHANICAL LBP

The distinction between acute (<3 months' duration) and chronic LBP is important as it is the major factor in determining prognosis. In one systematic review involving 11 studies with acute nonradicular pain, 80% (95% confidence interval [CI], 61–100%), 67% (95% CI, 50–83%), 57% (95% CI, 46–68%), and 65% (95% CI, 54–75%) of patients experienced pain at 1, 3, 6, and 12 months, respectively. In systematic reviews evaluating patients with predominantly chronic LBP, stagnant rates of improvement in pain were reported, with few patients improving dramatically after 6 months and a small percentage worsening.

RADICULAR LBP

In patients with radicular pain, between 15 and 40% of individuals experience persistent symptoms at 6 months to 1 year, with most studies also finding that herniated disks typically resorb within 2 years but often reherniate. For spinal stenosis, most patients also remain stable, with a small percentage progressing, although unlike disk herniations, the underlying pathology does not recede. Risk factors for pain persistence and poor outcomes for both axial and radicular symptoms include greater disease burden, older age, psychopathology, poor job satisfaction, and secondary gain.

ETIOLOGIES

NOCICEPTIVE PAIN

Myofascial Pain Muscles, ligaments, and fascia may be sources of mechanical pain, as they are imbued with nociceptors, collectively comprise a large surface area within spinal structures, are heavily involved in loadbearing and movements, and provide structural support to other potential pain generators. Studies examining muscle histology have found higher levels of neuropeptides (substance P, bradykinin), neurotransmitters (norepinephrine, 5-hydroxytryptamine), and inflammatory cytokines (e.g., tumor necrosis factor α, interleukins); lower pH levels; and more numerous vascular abnormalities in active trigger points than in latent trigger points and normal muscle. Studies using electromyography have also found higher myoelectric tone in patients with back pain compared to controls.

Back muscles can be divided into deep intrinsic muscles that connect to the vertebral column (semispinalis, rotatores, multifidus), intermediate muscles (erector spinae), and superficial muscles (e.g., latissimus dorsi). Although trigger points are frequently associated with muscle pain, these are more challenging to palpate in the low back compared to the mid-back and neck. Often co-prevalent with other etiologies or misdiagnosed as nonspecific (or nociplastic) pain, individuals with myofascial pain may present with focal or diffuse tenderness (and occasionally discrete trigger points), limited range of motion, increased muscle tension (and functional scoliosis in severe cases), and normal neurologic exams.

Discogenic Pain Disk degeneration is reported to account for 26–42% of patients with axial LBP, although selection bias (i.e., only those with suspected discogenic pain are included in discography prevalence studies), concomitant pain generators (e.g., disk degeneration predisposes to facet degeneration), the lack of a reference standard for identifying painful disks (high false-positive rate of discography), and flaws in studies utilizing diagnostic tests to identify painful disks (lack of multiple diagnostic tests with adequate controls) limit the precision of prevalence estimates. In healthy disks, nerve fibers are limited to the outer annulus, but in those with disk degeneration, they populate the inner annulus and even the nucleus pulposus. Disk degeneration is associated with upregulation of inflammatory cytokines and other molecules, which may sensitize intradiscal nerve endings and cause hypermobility, which increases the mechanical stress on disks. Macroscopically, the tearing and degeneration of annular fibers increases the stress on intact annular rings to the point of exceeding the mechanical pain threshold and facilitates contact between intradiscal cytokines and sensitized nerve endings.

Clinically, discogenic pain manifests as pain worsened with sitting or bending forward. It is more likely to be bilateral than facet or sacroiliac (SI) joint pain and frequently radiates into the upper and sometimes lower leg in a nondermatomal distribution. Since most individuals have evidence of disk degeneration by their fourth decade of life and a majority of individuals will experience LBP at least once, it can be challenging to establish a cause–effect relationship between pathology and symptoms. Provocative and analgesic discography are sometimes used to correlate degenerated disks with pain but are characterized by high false-positive rates in some populations (e.g., those with psychiatric morbidities, somatization, multiple other pain conditions) (Fig. 18-1).

Facet Joint Pain Facet joint pain affects approximately 10–15% of individuals with axial LBP, increasing with age. It may arise from the synovial lining, fibrous capsule, and bone, all of which are innervated with nociceptors. Disk degeneration generally precedes facet degeneration and increases loadbearing on the joints. Individuals with facet joint pain are more likely to experience unilateral, paraspinal pain and tenderness than those with predominantly discogenic pain, although the referral patterns overlap and advanced disease is usually bilateral. Individuals with facet joint arthritis may experience morning stiffness, and unlike those with discogenic pain, sitting may alleviate their symptoms. The diagnosis of facet joint pain is made via anesthetic blocks of the medial branches innervating the joints or the joints themselves, but anesthetic blocks are subject to high false-positive rates.

Sacroiliac Joint Pain Pain arising from the SI complex may be secondary to pathology involving the ligaments connecting the ilia and sacrum posteriorly and anteriorly (extraarticular) or the joint itself (intraarticular, e.g., internal bony structures, capsule, synovial lining). The SI joint is a true synovial joint, with the upper third being a syndesmosis, the lower two-thirds lined by synovium, and the lower third containing an anteriorly situated joint capsule, all of which contain nociceptors. Studies have found equal prevalence rates between extraarticular and intraarticular pathology, with the former being more common in younger individuals, after trauma, and in those with prominent tenderness and less degeneration on imaging. Pain from the SI joint is more likely to be unilateral than discogenic or facetogenic pain and is generally most marked inferior to the L5 vertebral level, with about half of patients experiencing nondermatomal pain radiating into the leg(s), including below the knee in about a quarter of cases. Depending on the pathology, pain from the SI joint may also be referred into the groin and be mistaken for hip pathology. The reference standard

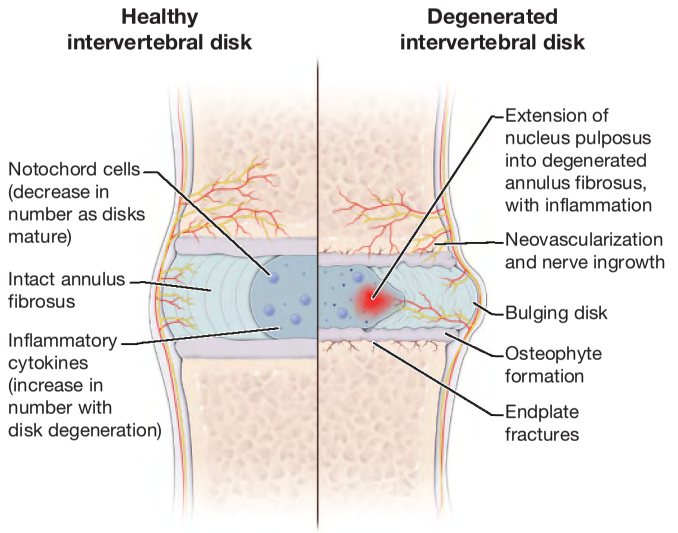

FIGURE 18-1 Schematic drawing of a coronal view demonstrating a healthy intervertebral disc (left) and a degenerated disc (right). *(Redrawn with permission from Seffrah Jin.)*

for diagnosis is low-volume anesthetic blocks, although some studies have found that a battery of three or more provocative tests on physical examination (e.g., Patrick's test [external rotation of the hip with the patient supine and the knee flexed], Gaenslen's test [leg hyperextension off the edge of the exam table in the supine position, with the other leg flexed at the knee toward the chest], SI joint distraction [dorsolateral pressure on the anterior superior iliac spines of the iliac crests with the patient supine], or compression [downward pressure on the front side of the iliac crest in the lateral position with the affected side up and the hips and knees flexed]) has high sensitivity and specificity for detecting intra-articular SI joint pain (Table 18-2).

RADICULAR PAIN

Herniated Disc The annual incidence of symptomatic lumbar disk herniation is about 1%, with a point prevalence between 1.5 and 4%. However, the prevalence of asymptomatic disk herniation is much higher, ranging from 29 to 43%, increasing with age. Between 38 and 56% of symptomatic individuals report an inciting event, with falls, lifting, and motor vehicle collisions being the three most common causes.

Persons with a herniated disk typically present with LBP radiating into the lower leg following a dermatomal distribution, although there is significant overlap and variability in dermatomes, and up to 40% of individuals have multilevel involvement. Patients frequently report sensory deficits and neurologic motor deficits (25–30%) and occasionally are found to have asymmetrical or diminished reflexes, most pronounced when L4 or S1 is involved (<20%). The sensitivity of the straight leg raising test (Table 18-2) is ~80% for L5 and more caudad nerve roots, with the sensitivity of the femoral stretch test (Table 18-2) exceeding 50% for mid-lumbar nerve root involvement.

Spinal Stenosis Spinal stenosis affects approximately 11% of the U.S. population, with the prevalence dramatically increasing with age. Stenosis may be central (<10 mm anteroposterior diameter) or involve the lateral recesses or foramina (<3 mm). Anatomic etiologies include bulging or herniated disks, facet joint hypertrophy, spondylolisthesis, and ligamentum flavum buckling and hypertrophy, all of which can also independently cause axial pain. Neurogenic claudication, which has a sensitivity of 88% (95% CI, 78–98%), is a hallmark of spinal stenosis but has low specificity. Symptoms of neurogenic claudication include back pain radiating into the legs that is exacerbated by activity and improved by rest, especially sitting. The most common levels affected by spinal stenosis are L4–5 (92%) and L3–4 (66%), with most people having multiple nerve root involvement. Typically, leaning forward (e.g., shopping cart sign) alleviates symptoms. Other signs and symptoms of spinal stenosis include a wide-based gait, poor balance, pain worsened by lumbar extension, and diminished vibratory perception. As with radicular symptoms secondary to a herniated disk, the diagnosis of lumbosacral stenosis (with or without neurogenic claudication) is made by a combination of history, physical examination, and imaging (e.g., magnetic resonance imaging [MRI]); see Figs. 18-2 through 18-4.

HISTORY AND PHYSICAL EXAM (SEE ALSO CHAP. V8)

History and physical examination may be used to identify patients who require further diagnostic workup and have indications for advanced therapies, including surgery, but are rarely pathognomonic. Inspection may provide clues of congenital or unusual pathology (e.g., birthmarks and doughy lipomas can indicate spina bifida, and an unusual patch of hair over the spine may indicate underlying bony pathology), while observation of gait can suggest nonspinal pathology (e.g., Parkinson's disease or antipsychotic drug use causing propulsive gait; a central lesion causing spastic gait; muscular dystrophy, spinal or gluteal muscle weakness, or hip pathology causing waddling gait; peroneal neuropathy, a large herniated disk, Guillain-Barré syndrome, multiple sclerosis, or another neurologic condition causing steppage gait or foot drop). Paraspinal tenderness overlying an area of "fullness" or increased muscle tension can indicate muscle spasm or a muscle tear, which can sometimes be distinguished through ultrasound, while midline tenderness may indicate ligamentous injury.

Spine alignment should be viewed from multiple dimensions. Scoliosis can predispose patients to disk and facet joint degeneration. Scoliosis, defined as a sideways curvature of the spine, or curvature in a coronal plane, can predispose patients to disk and facet joint degeneration. Functional scoliosis or decreased lordosis (natural inward or anterior curvature of the spine) can indicate muscle spasm or postural dysfunction (which may disappear with flexion), and exaggerated lordosis can be secondary to a tethered spinal cord or abdominal muscle weakness. Range of motion can indicate specific pathology but is most frequently associated with nonspecific pain-induced limitations. For example, decreased extension can indicate spinal stenosis or spondylolisthesis, diminished forward flexion can suggest discogenic pain, and pain when rising from sitting or with transitional movements might warrant workup for SI joint pain. True or apparent leg length discrepancies (20% have a clinically relevant leg length discrepancy exceeding 9 mm), which can be distinguished by measurements from the umbilicus, anterior superior iliac spine, or greater trochanter to the medial malleolus, may predispose patients to a host of biomechanical problems including SI joint pain, accelerated disk and facet joint degeneration, and myofascial strain. Nonorganic signs (e.g., overreaction, pain with sham stimulation) may signify underlying psychopathology and are associated with treatment failure.

Specific tests are generally more specific for radicular than axial pain. Clinical studies have found that older age, positive treadmill test (a decrease in ambulatory capacity and an increase in pain with progressively greater grades of inclination), positive Romberg's test (Chap. 433), pain that disappears with sitting, and perineal numbness have strong predictive value for lumbosacral stenosis. For detecting a herniated disk, the straight leg raising test (with the patient prone, the examiner gently straightens and raises the leg of the affected side by flexing the hip, reproducing radicular pain at an elevation between 30° and 70°) has high sensitivity but widely variable specificity for L5–S2 (L5–S1 are most commonly affected) nerve root involvement, with the femoral stretch test (the knee is passively flexed to the thigh while the hip is gently extended, reproducing radicular pain in the anterior thigh) being less studied but reasonably sensitive for mid-lumbar nerve root involvement. In contrast, the crossed straight leg raising test (eliciting radicular pain on the affected side when raising the leg on the unaffected, contralateral side) demonstrates consistently high (>85%) specificity but low sensitivity. For mechanical back pain, centralization (referred pain that is perceived as receding toward the midline with repeated movements), pain worse with sitting, and midline tenderness suggest discogenic pain, whereas paraspinal tenderness is weakly associated with injection-confirmed (e.g., lumbar medial branch nerve block) facet joint pain. An array of at least three positive SI provocation tests (e.g., Patrick's, Gaenslen's, compression, distraction; Table 18-2) is associated with accurately identifying the intraarticular SI joint as the principal pain generator. Compared to other sources of LBP, pain below L5 and radiation into the groin are also more likely to indicate SI joint pain.

A neurologic exam can indicate nerve root involvement (i.e., radicular pain), with reflexes (patellar reflex indicating L4 and sometimes L2 or L3 involvement, Achilles reflex indicating S1 pathology) being the most objective measure. However, these too must be considered in context as about 5% of younger individuals but over one-third of older individuals have absent reflexes and about one-quarter of people have asymmetrical reflexes. Although tenderness over the sciatic notch with internal rotation of the extended hip (Freiberg's test) may suggest piriformis syndrome, tenderness elicited on rectal or pelvic examination may improve selection for diagnostic injections. When cauda equina syndrome is suspected, assessing sensation in the perianal area and a rectal exam to evaluate sphincter tone is necessary, and urgent confirmation through MRI might be needed.

Table 18-3 summarizes the main etiologies of LBP and their usual clinical features, diagnostic tests, and treatments.

RED FLAGS

The term "red flags" has been used to denote signs or symptoms that suggest the potential presence of serious spinal (e.g., cauda equina syndrome) or nonspinal pathology (e.g., infectious, visceral [pelvic and

TABLE 18-2 Summary of Common Physical Exam Maneuvers for the Low Back

TEST	DESCRIPTION	COMMENTS
Lumbar Radiculopathy		
Straight leg raising (SLR)	The patient is in a supine position. The examiner passively flexes the leg of the affected side at the hip, reproducing radicular pain.	SLR has greatest sensitivity (80%) for impingement of the L5 or S1 nerve roots; sensitivity markedly decreases for nerve roots cephalad to L4. Unreliable for eliciting radicular symptoms from spinal stenosis.
Crossed SLR	The patient is in a supine position. The examiner passively flexes the leg of the nonaffected (contralateral) side at the hip, reproducing radicular pain in the affected leg.	High specificity (>85%) but low sensitivity.
Femoral stretch	The patient is in a prone position. The examiner passively extends the leg of the affected side at the hip, reproducing radicular pain in the thigh.	Modest sensitivity (50%) for L2–L4 nerve root impingement.
Sacroiliac (SI) Joint Provocation		
Compression	The patient is in a lateral decubitus position with the affected side up, with hips and knees flexed; the examiner exerts downward pressure on the superior border of the iliac crest.	There are no physical examination maneuvers that reliably distinguish between intraarticular and extraarticular pathologies, but most tests have been studied based on blocks diagnosing intraarticular pathology. Estimated sensitivities and specificities for individual tests vary greatly. The thigh thrust, FABER, and pelvic torsion tests have relatively greater sensitivities (up to 50–80%), whereas the compression and distraction tests have relatively greater specificities (up to 70–80%). A battery of ≥3 tests is generally accepted as having the greatest overall sensitivity (potentially ≥90%) and specificity (potentially ≥80%).
Thigh thrust (posterior shear test [POSH]; femoral shear test)	The patient extends their unaffected leg while in a supine position. On the affected side, the examiner flexes the patient's hip to 90° and simultaneously flexes the ipsilateral knee while applying downward pressure along the longitudinal axis of the femur.	
Distraction (gapping test)	The patient is in a supine position. On the affected side, the examiner applies downward (dorsolateral) pressure on the ipsilateral anterior superior iliac spine (ASIS).	
Flexion, abduction, and external rotation (FABER; Patrick's test)	The patient is in a supine position. On the affected side, the examiner flexes the patient's hip and knee and positions the foot under the contralateral knee (abduction). While stabilizing the contralateral ASIS with one hand, the examiner uses their other hand to apply downward pressure on the knee of the affected side (external rotation).	
Pelvic torsion (Gaenslen's test)	The patient is in a supine position, usually on the edge of an examining table. The examiner hyperextends the leg of the affected side while maximally flexing the hip and knee of the unaffected side against the patient's abdomen.	
SI Joint Mobility/Alignment		
Standing hip flexion test (SHFT; Gillet's test; Stork test)	The patient stands upright with both feet on level ground. The patient is instructed to lift one leg by flexing their hip and knee toward the chest. The examiner stands behind the patient and observes the spine and pelvis. The test is repeated in the other leg for comparison.	During hip flexion, the ipsilateral ASIS should rise slightly while the posterior superior iliac spine (PSIS) drops slightly. If these motions are paradoxical (i.e., PSIS rises with hip flexion) or asymmetrical, this suggests SI joint mobility dysfunction.
Deep Gluteal Syndrome/Piriformis Syndrome		
Freiberg's sign	The patient is in a supine position. The examiner passively extends, adducts, and internally rotates the thigh and calf ("log roll") on the affected side.	Assesses potential impingement of the sciatic nerve by nonspine structures (e.g., piriformis muscle, gluteal muscles) by stretching the piriformis and associated (e.g., gemelli) muscles, which can produce symptoms similar to those of lumbar radiculopathy.
Flexion, adduction, and internal rotation (FADIR; FAIR test)	The patient is in a supine position. On the affected side, the examiner flexes the patient's hip and knee, and while maximally adducting the thigh, internally rotates the hip.	
Pace test	In a sitting position, the patient is asked to abduct and externally rotate their hip, eliciting pain.	There are variants in which the patient lies supine with the hips and knees flexed.
Beatty test	The patient is positioned in a lateral decubitus position with the affected side up. Elevating the affected leg elicits pain in the buttocks.	Unlike the FAIR test and Freiberg's sign, this test causes contraction of the piriformis muscle and thus may not reliably elicit sciatic nerve entrapment symptoms.
Spondyloarthropathy/Ankylosing Spondylitis		
Schober test	The patient stands upright, and horizontal lines are drawn across L5 and 10 cm superior to L5. The patient is asked to bend forward and touch their toes. If the distance between the drawn lines increases <5 cm, this indicates decreased range of motion and is a positive result.	Numerous modifications exist regarding the location of the drawn lines. Nonspecific for inflammatory spinal arthritis (i.e., other conditions such as discogenic pain associated with decreased forward flexion can lead to a positive result).
Nonorganic Signs/Functional Disorders		
(Neurologic and/or psychiatric consultations potentially indicated prior to interventional procedures)		
Hoover's sign	The patient is in a supine position. The examiner asks the patient to flex the leg of the affected side at the hip, against resistance. If an organic source of neuropathy or paresis is present, with normal effort, the unaffected leg will involuntarily push downward on the examination table.	A discordant response might suggest malingering or the presence of a functional neurologic disorder (e.g., conversion disorder).
Tripod sign	With the patient in a seated position, elevating the affected leg may result in pain in the leg and back.	Leaning back and resting both hands on the table should reduce the pain. Failure to do this may suggest nonorganic pathology or malingering.
Waddell signs	Five categories of signs: (1) nonanatomic distribution of tenderness; (2) pain from sham stimulation (i.e., lumbar pain from gentle downward force on the shoulders); (3) distraction (i.e., positive SLR test in supine position but not while sitting, or while preoccupied); (4) regional disturbances (i.e., motor or sensory findings that do not correlate with areas of pathology); and (5) overreaction (i.e., disproportionate physical or emotional responses on exam).	A greater number of positive signs is associated with a greater risk of treatment failure.

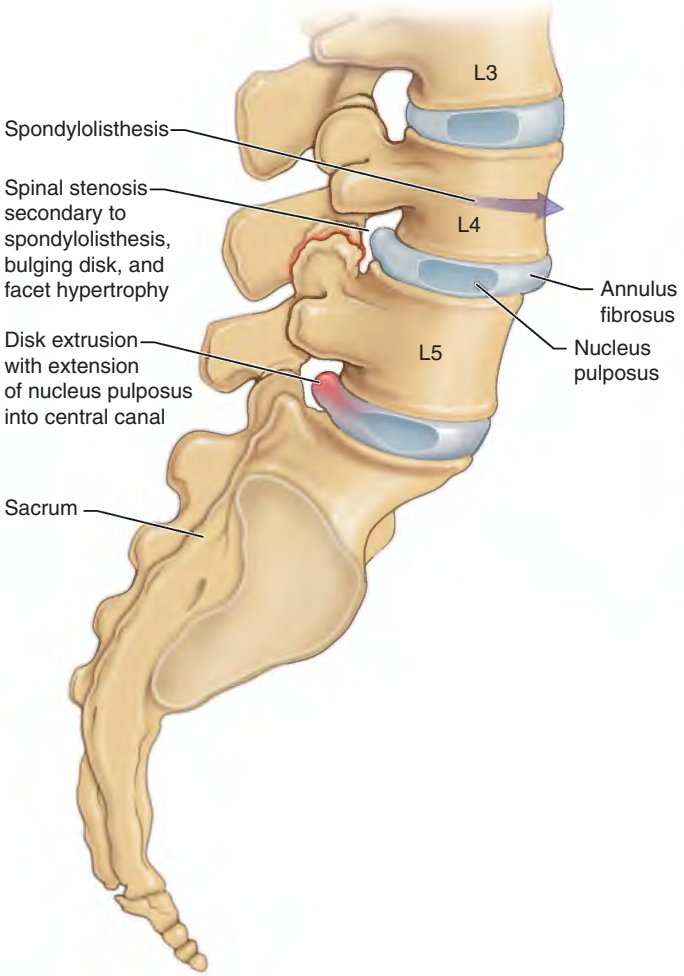

FIGURE 18-2 Sagittal view of the lumbar spine depicting L4-5 spinal stenosis secondary to spondylolisthesis, a bulging disc and facet joint hypertrophy, and an L5-S1 herniated nucleus pulposus. *(Redrawn with permission from Seffrah Jin.)*

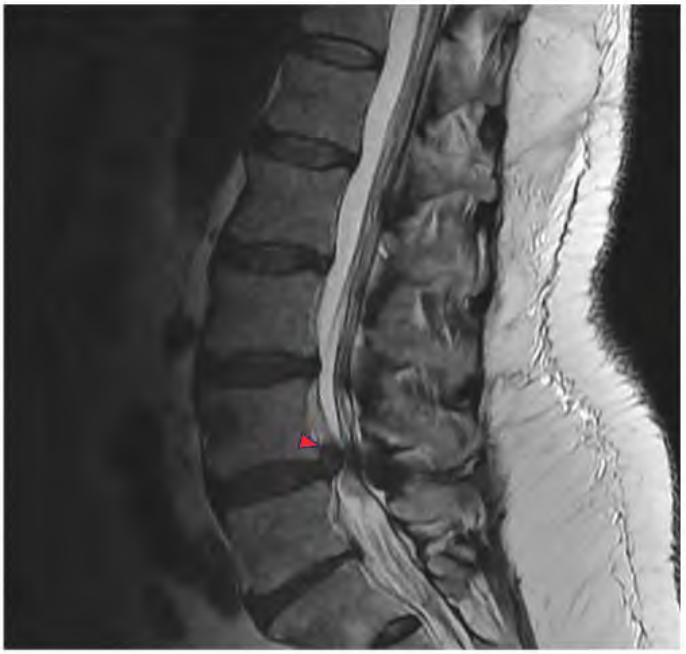

FIGURE 18-3 In this T2-weighted sagittal lumbar MRI, severe central canal stenosis secondary to a disk herniation is visualized at L4–5 (*arrowhead*). This patient appears to also have partial lumbarization of the sacrum, a risk factor for back pain.

FIGURE 18-4 In this T2-weighted axial lumbar MRI, bilateral neuroforaminal narrowing secondary to protrusion of the L4–5 disk (*arrowheads*) and severe bilateral facet joint hypertrophy (*asterisks*) are visualized.

retroperitoneal organs], traumatic, vascular, neoplastic, inflammatory, or endocrine) that may lead to permanent neurologic deficits if not urgently treated. In one review of 9940 patients with a chief complaint of LBP, 92.6% of patients endorsed at least one red flag, with the most common being night pain (58.1%); although the presence of one or more red flags could predict that a neurologic emergency was present, their absence did not meaningfully decrease the likelihood. **Table 18-4** summarizes red flag findings and their potential causes.

ANCILLARY TESTS

IMAGING

Advanced imaging is often used to associate symptoms with a potential etiology, but lacks specificity, with most studies demonstrating no significant correlation between imaging and symptoms, and a high percentage of abnormalities in populations without back pain. For acute LBP, red flags and serious or progressive neurologic deficits warrant imaging. For chronic LBP, MRI can be considered on a case-to-case basis, especially when considering invasive interventions such as surgery. For lumbar epidural steroid injections (ESIs), a randomized trial failed to demonstrate that MRI improved outcomes or meaningfully affected decision-making.

MRI is considered the gold standard for detecting soft tissue abnormalities including herniation, and can reveal active inflammation on certain sequences **(Chap. 434)**. Although MRI is superior for contrast resolution between structures, computed tomography (CT) can provide better spatial contrast, is more sensitive for some bone abnormalities, and has sensitivity >90% for identifying most lumbar pathology including disk herniations. Plain films can be used to evaluate scoliosis and spondylolisthesis and detect fractures (including pars interarticularis), although MRI is needed to determine acuity and chronicity (e.g., presence or absence of edema).

As a general principle, when pain symptoms persist or worsen despite optimal nonpharmacologic and pharmacologic treatments or if red flag symptoms arise, dedicated imaging (e.g., x-ray, CT, MRI) can clarify potential diagnoses. Focal lesions on radiologic exams that are physiologically or anatomically plausible sources of pain (e.g., disk herniation with nerve root impingement) might be targets for subsequent interventional pain procedures or surgical management, but because symptom severity does not always correlate with imaging findings, a thorough history and physical examination remain the foundation for accurate contextualization. Treatment decisions should rarely be predicated on imaging findings alone.

TABLE 18-3 Clinical Evaluation, Diagnosis, and Treatment of Low Back Pain Etiologies

ETIOLOGY	RISK FACTORS	TYPICAL ONSET	CLINICAL PRESENTATION	PHYSICAL EXAM	DIAGNOSTIC TESTS	TREATMENTS[a]
Mechanical Pain						
Myofascial pain	Strenuous activities, sedentary lifestyle, abrupt movements (sneezing)	Usually insidious (chronic) but sometimes acute (muscle tear or spasm)	Axial pain, occasionally referred into thigh, mid-back, or groin. Often superimposed with other etiologies.	Tenderness, occasionally trigger points. Midline tenderness in between spinous processes may indicate ligamentous injury.	Occasionally ultrasound or electromyography	*Pharmacologic*: NSAIDs; nonbenzodiazepine muscle relaxants; antidepressants (e.g., duloxetine, tricyclic compounds); topical analgesics (e.g., diclofenac, lidocaine in those with irritable nociceptors or allodynia) *Interventional*: trigger point injections
Intervertebral disks	Advanced age (although patients younger than those with facet joint pain), acute (torsional event) or repetitive trauma, genetic predisposition	Insidious, occasionally abrupt (e.g., annular tear)	Axial pain, may radiate into extremities, more likely to be bilateral than SI or facet joint pain, worse with sitting	Midline tenderness, reduced range of motion (especially forward flexion)	Discography (high false-positive rate), bony vibration test; MRI generally nonspecific but high-intensity zone correlates with discography results	*Pharmacologic*: NSAIDs; antidepressants (e.g., duloxetine) *Interventional*: biacuplasty or IDET can be considered, but evidence for long-term benefit is mixed and disk puncture may increase risk of future disk degeneration; the benefit for intradiscal corticosteroid injections or ESI unclear
Vertebrogenic	Advanced age/osteoporosis, trauma	Abrupt (trauma) or insidious	Axial pain that may radiate into upper leg, worsened with activities	Midline tenderness	MRI to identify endplate abnormalities and acuity, plain films for acute fractures. Bony vibration test sometimes used.	*Pharmacologic*: NSAIDs; antidepressants (e.g., duloxetine); topical analgesics (e.g., diclofenac, lidocaine) only if superimposed soft tissue pain. Judicious use of opioids can be considered for severe pain secondary to acute fracture(s). *Interventional*: In acute vertebral compression fracture(s) (<6 weeks) with severe pain or disability, percutaneous vertebral augmentation (vertebroplasty or kyphoplasty) can be considered. The benefit for vertebral augmentation in chronic fractures is mixed. In patients with chronic axial pain with Modic type 1 or type 2 vertebral endplate/bone marrow changes on MRI and in whom other lumbar structures are less likely to be the predominant source of pain, basivertebral nerve RFA can be considered.
Facet joints	Increases with age, repetitive strain, genetic predisposition	Insidious	Axial pain may radiate into upper and occasionally lower legs. About half are bilateral.	Paraspinal tenderness, improved with sitting	CT or MRI generally reveals degeneration. Diagnostic medial branch or intraarticular injections.	*Pharmacologic*: NSAIDs; antidepressants (e.g., duloxetine) *Interventional*: RFA of the relevant medial branch nerves when preceded by a positive diagnostic block (e.g., ≥50% reduction in pain)
SI joint	Bimodal prevalence (younger individuals with unilateral extraarticular pathology often secondary to trauma, older people with bilateral intraarticular pathology). True and apparent leg length discrepancies, hip pathology, inflammatory arthritis (intraarticular), and lumbar spine surgery are predisposing factors.	Abrupt for extraarticular, insidious for intraarticular.	Unilateral (younger individuals, post-trauma) or bilateral (older individuals, intraarticular). About half of cases radiate into leg, sometimes below knee.	Tenderness below L5; positive provocative tests. Most painful area located near posterior superior iliac spine.	Advanced imaging (especially CT) may indicate intraarticular pathology. Battery of provocative tests correlate well with diagnostic injections.	*Pharmacologic*: NSAIDs; antidepressants (e.g., duloxetine); topical analgesics (e.g., diclofenac, lidocaine) only if superimposed soft tissue pain *Interventional*: Intra- and/or extra-articular SI joint injection; RFA of the sacral lateral branch nerves for extraarticular pathology; minimally invasive fusion of the SI joint in refractory cases involving joint degeneration or instability

(*Continued*)

TABLE 18-3 Clinical Evaluation, Diagnosis, and Treatment of Low Back Pain Etiologies (Continued)

ETIOLOGY	RISK FACTORS	TYPICAL ONSET	CLINICAL PRESENTATION	PHYSICAL EXAM	DIAGNOSTIC TESTS	TREATMENTS[a]
Predominantly Radicular Pain						
Herniated disk	Peak prevalence 30–50 years, preexisting disk degeneration, trauma, genetic predisposition, lifestyle (heavy lifting, smoking), obesity	Often abrupt, may be insidious	May be unilateral or bilateral (large, central herniation) pain radiating into leg in dermatomal distribution	Most patients also have back pain. Sensory loss and neurologic weakness common; may be associated with diminished reflexes. Straight leg raising test usually positive for lower lumbar levels.	MRI or CT scan, myelography when contraindicated. Electrodiagnostic tests or selective nerve root blocks may be confirmatory.	*Pharmacologic*: NSAIDs; nonbenzodiazepine muscle relaxants; antidepressants (e.g., duloxetine). Gabapentinoids are commonly used (gabapentin, pregabalin), but systematic reviews and meta-analyses suggest minimal benefit when balanced against potential harms (e.g., dizziness, somnolence, gait disturbance). *Interventional*: ESIs, which are likely most effective in the acute phase of radicular pain secondary to disk herniation. ESIs might confer a weak but potentially meaningful surgery-sparing effect.
Spinal stenosis	Advanced age, concomitant spinal pathology (disk degeneration, spondylolisthesis, facet hypertrophy)	Usually insidious	Usually unilateral for lateral recess or foraminal stenosis; central stenosis may be unilateral or bilateral. Wide-based gait, often affects multiple dermatomes. Pain often improves with sitting. Although the severity of pain and disability may wax and wane, the causes of spinal stenosis (e.g., spondylolisthesis, degenerative changes/osteophyte formation) often progress with age.	Sensory and motor deficits; SLR test usually negative. Improved walking ability when bending forward.	MRI or CT scan	*Pharmacologic*: NSAIDs; nonbenzodiazepine muscle relaxants; antidepressants (e.g., duloxetine). Gabapentinoids are commonly used (gabapentin, pregabalin), but systematic reviews and meta-analyses suggest minimal benefit when balanced against potential harms, especially in the elderly (e.g., dizziness, somnolence, gait disturbance). *Interventional*: ESIs commonly used and may confer short-term and sometimes intermediate-term benefit, but evidence for long-term benefit is mixed given the progressive pathology.
Neuropathy	Underlying neuropathic pain condition (e.g., herpes zoster, diabetic amyotrophy)	Generally insidious, acute for herpes zoster	Lumbosacral dermatomes less common with herpes zoster than thoracic dermatomes. Unilateral (herpes zoster), occasionally bilateral (advanced neuropathies). Advanced neuropathies usually multidermatomal.	Sensory and motor loss, diminished reflexes	Workup for underlying cause; advanced imaging may rule out disk pathology	*Pharmacologic*: gabapentinoids (gabapentin, pregabalin), antidepressants (e.g., SNRIs, TCAs), topical local anesthetics (e.g., lidocaine patches or creams), topical capsaicin. Other anticonvulsants (e.g., oxcarbazepine, lamotrigine) are occasionally used, but minimal evidence is available. *Interventional*: peripheral nerve blocks might confer analgesia, but evidence for long-term benefit is minimal or negative for certain conditions (e.g., PHN).
Nociplastic Pain						
Nonspecific back pain	Central sensitization, more common in females, peak age 20s to 50s, genetic predisposition	Usually insidious, but >20% report a physical or psychological inciting event	Bilateral, often involves other spinal regions, frequently radiates into legs. Most patients have other nociplastic and nonnociplastic pain conditions. High co-prevalence rate of mood disorders and sleep dysfunction.	Marked diffuse tenderness, provocative tests often positive but nonspecific, neurologic exam nonfocal	Based on clinical presentation. Patients often score in "neuropathic" range on validated instruments (painDETECT); central sensitization inventory and conditioned pain modulation may confirm central sensitization.	*Pharmacologic*: NSAIDs; nonbenzodiazepine muscle relaxants; antidepressants (e.g., duloxetine); gabapentinoids (gabapentin, pregabalin); over-the-counter topical analgesics (e.g., diclofenac, lidocaine, menthol). Nonpharmacologic therapies (e.g., physical therapy, targeted exercise) should be prioritized.

Mixed Pain Phenotypes						
Most neuropathic conditions have concomitant mechanical pain (e.g., spinal stenosis may be from facet hypertrophy or degenerated/herniated disks, which in themselves can cause mechanical pain); herpes zoster can cause cutaneous inflammatory pain.						
Postlaminectomy syndrome	Younger age, female sex, opioid use, greater presurgical disease burden, more concurrent pain conditions (e.g., baseline central sensitization)	Poor patient selection (e.g., irrelevant surgical levels), pseudoarthroses, and retained fragments may result in no benefit. Epidural scar tissue, arachnoiditis, and muscle wasting may present with worsening pain weeks or months after surgery. Adjacent segment disease can take >1 year to manifest.	Often involves axial and radicular pain in a multidermatomal fashion	Sensory loss and weakness common. Neurologic signs may be in multiple dermatomes. Muscle wasting and/or loss or lordosis may be appreciated. Superficial tenderness is common in individuals with nociplastic pain.	MRI with gadolinium, or even myelography. Diagnostic blocks (e.g., discography, facet blocks) are associated with a high false-positive rate.	*Pharmacologic*: NSAIDs; nonbenzodiazepine muscle relaxants; antidepressants; gabapentinoids (depending on whether neuropathic or nociceptive symptoms predominate) *Interventional*: Epidural lysis of adhesions can be considered in individuals with epidural scar tissue. SCS can be considered in refractory cases, especially those in whom neuropathic symptoms predominate.

[a]Nonpharmacologic treatments such as physical therapy, along with the management of concomitant mood disorders and maladaptive coping mechanisms (e.g., via pain psychology or CBT), should be considered for all patients with chronic pain.

Abbreviations: CBT, cognitive-based therapy; CT, computed tomography; ESI, epidural steroid injection; IDET, intradiscal electrothermal therapy; MRI, magnetic resonance imaging; NSAID, nonsteroidal anti-inflammatory drug; PHN, postherpetic neuralgia; RFA, radiofrequency ablation; SCS, spinal cord stimulation; SI, sacroiliac; SLR, straight leg raise; SNRI, serotonin-norepinephrine reuptake inhibitor; TCA, tricyclic antidepressant.

TABLE 18-4 "Red Flag" Symptoms and Corresponding Pathology

Demographics	
Age ≤18 years	Congenital defect, tumor, spondylolysis, or spondylolisthesis
Age >50 years	Tumor, fracture, vascular abnormality (aortic aneurysm)
Social and Treatment Related	
Intravenous drug use	Infection
Anticoagulant use	Hematoma
Recent procedure	Hematoma (complication after spine procedure) or infection
Immunocompromised state	Infection
Trauma	Fracture, hematoma
History of cancer	Tumor
Symptoms	
Fever, night sweats, chills	Infection, tumor
Weight loss	Tumor, infection
Saddle anesthesia	Cauda equina syndrome
Urinary or rectal incontinence, sexual dysfunction	Cauda equina syndrome
Rapidly progressive or severe neurologic symptoms	Cauda equina syndrome
Pain not relieved by rest or at night	Tumor, infection
Physical Exam Signs	
Saddle anesthesia	Cauda equina syndrome
Decreased rectal tone	Cauda equina syndrome

ELECTRODIAGNOSTIC TESTING

Electromyography and nerve conduction studies are often used to identify peripheral sources of nerve and muscle injury. This determination is particularly pertinent in cases of multiple dermatomal involvement or atypical extremity pain, when symptoms and imaging findings are conflicting, and in cases of transitional anatomy or aberrant innervation. Transitional anatomy, which includes variations of "lumbarization" of the S1 spinal segment (i.e., a sixth vertebral body is present), or more commonly "sacralization" of L5 (i.e., a partial or complete anatomic fusion of L5 with S1), is present in 15–35% of the population and is associated with an increased prevalence of back pain. Studies have generally found sensitivity rates ranging from 36 to 64% for radicular pain in the absence of focal neurologic findings and from 51 to 86% in patients with an abnormal neurologic examination. The specificity of electrodiagnostic testing is also variable, ranging between 50 and 60%.

SELECTIVE NERVE ROOT BLOCKS

Selective nerve root blocks (SNRBs) can also be used to identify a symptomatic nerve root in ambiguous cases. SNRBs are performed in a manner similar to that of transforaminal ESIs but, by definition, involve the blockade of only a single nerve root (i.e., avoidance of epidural spread), with studies finding that high-volume injections (>0.5 mL) undermine specificity. There have been no randomized studies evaluating the effect of SNRB on postsurgical decompression outcomes, although retrospective studies have generally found a modest correlation between pain relief after SNRB and surgery. One systematic review assessing the accuracy of SNRB in detecting radiculopathy in patients with LBP and lower limb pain found 93% sensitivity and 26% specificity based on very low-quality studies and concluded that the addition of SNRB to routine presurgical workup is not cost-effective.

TREATMENT

Low Back Pain

MULTIMODAL AND INTERDISCIPLINARY STRATEGIES

Contemporary strategies for managing acute and chronic LBP prioritize the optimization of nonpharmacologic modalities (e.g., physical therapy, exercise, cognitive-behavioral therapy, heat, massage) with a graded, patient-centered incorporation of pharmacologic, interventional (e.g., fluoroscopic injections), and surgical treatments for increasingly refractory symptoms. Because most cases of acute LBP resolve within 6 weeks, over-the-counter analgesics in addition to nonpharmacologic treatments such as targeted physical therapy, core-strengthening exercises, and education frequently suffice without the need for imaging or prescription analgesics. The biopsychosocial model recognizes that psychological (e.g., underlying mood disorders) and social factors (e.g., systemic barriers to care) contribute to the overall perception and experience of pain, and these issues should be identified and addressed when possible. An interdisciplinary team that involves specialists from pain medicine, orthopedic, and/or neurosurgical spine surgery, physical therapy, and psychology/psychiatry can facilitate a more nuanced, individualized, and comprehensive treatment plan. Studies have found that interdisciplinary treatment programs involving these specialties provide better improvements in pain, function, and quality of life, but restrictions in coverage from health care payors have hindered widespread implementation.

Pharmacotherapy Around a quarter of patients with acute LBP develop chronic symptoms. Chronic LBP is defined by symptoms that persist for >3 months. Pharmacologic options include nonsteroidal anti-inflammatory drugs (NSAIDs), nonbenzodiazepine muscle relaxants, and antidepressants (e.g., duloxetine, a serotonin and norepinephrine reuptake inhibitor, or tricyclic antidepressants) **(Chap. 14)**. Although frequently used, acetaminophen is unlikely to provide significant analgesia for back pain and is no longer recommended as a first-line agent. There is insufficient evidence for gabapentinoids (gabapentin or pregabalin) for either axial or radicular back pain. Opioids have not demonstrated significant long-term benefits for analgesia or function, but a temporary course may be considered on a case-by-case basis for debilitating acute pain or severe exacerbations of chronic LBP. Opioids are associated with risks of serious potential harms (e.g., respiratory depression, addiction, endocrinologic disturbances). If used, opioids should be prescribed at the lowest effective dose for the shortest duration of time feasible and with clearly defined treatment goals collaboratively made with the patient. Concomitant use of opioids with benzodiazepines should be avoided due to the increased risk of respiratory depression.

Psychological Therapies There is a high co-prevalence between psychopathology (e.g., depression, anxiety disorders, catastrophization, poor coping skills, somatic symptom disorder, fear avoidance, posttraumatic stress disorder, substance use disorders) and chronic back pain. Studies have found co-prevalence rates for depression ranging between 33 and 67%, for anxiety between 10 and 30%, for substance misuse disorders between 13 and 40%, and for axis II disorders (e.g., personality disorders), >50% in some studies. The lifetime co-prevalence rates of axis I and axis II conditions in individuals with chronic back pain are even higher. It is important to recognize that psychiatric conditions are not binary (present or absent), but rather exist along a continuum **(Chap. 463)**. Many chronic pain sufferers may still benefit from precision psychotherapies despite not formally meeting contemporaneous diagnostic criteria.

It is therefore important to identify and address underlying psychiatric and mood conditions. Studies have shown that targeted education, mindfulness-based stress reduction, operant therapy, biofeedback, progressive relaxation, and cognitive-behavioral therapies may benefit patients with back pain from various etiologies, with evidence generally being greatest for patients with chronic pain. No individual psychological therapy has demonstrated consistent superiority, and it is likely that the effectiveness of these therapies is greatly dependent upon the provider-specific and patient-specific characteristics that undergird the therapeutic relationships of psychiatric care. There is stronger and more consistent evidence for short-term than long-term benefit on pain and function, with the benefits waning without ongoing follow-up.

Physical Therapies Physical therapies have been a cornerstone of back pain treatment for decades. Physical therapists evaluate and educate patients regarding kinesiologic or functional abnormalities that contribute to pain and provide minimally invasive procedural interventions to help reduce symptoms and dysfunction. Physical therapists develop exercise regimens to address underlying causes of pain (e.g., correcting gait abnormalities) and provide treatments (e.g., hot and cold packs, manual therapies including manipulation, massage, neuromuscular reeducation). Exercise has been shown to reduce pain and increase function for radicular and nonradicular back pain, although the effects diminish over time if exercises cease. For acute back pain, although early resumption of activities including exercise (within 2 weeks of symptom onset) is widely recommended, studies are mixed regarding its long-term effect on pain and function. Most studies have failed to demonstrate one type of exercise as more beneficial than another, with yoga and Tai Chi being two of the more commonly studied therapies.

Integrative Medicine The use of integrative treatments for back pain has grown substantially but continues to be characterized by low-quality studies. Integrative medicine therapies can be provided via specialists (e.g., acupuncturists, chiropractors), physical therapies, and physicians. Although there are no trials comparing therapies stratified by specialty, specialists (acupuncturists, chiropractors) may have a greater knowledge base and more experience than generalists, which could theoretically be helpful for refractory cases. Massage may be beneficial in individuals with acute and chronic pain with prominent soft tissue symptoms (e.g., spasmodic or tension-based pain), but the analgesic benefits tend to be short-lived. Spinal manipulation may provide small benefits for acute and chronic back pain and physical function compared to the absence of therapy, but the effects diminish over time. Spinal manipulation is noninferior to other recommended physical therapies; there is mixed evidence for its benefit compared to sham or as an add-on treatment to other physical therapies. Acupuncture has been shown to be effective for pain and, to a lesser degree, several secondary outcomes in patients with acute and chronic LBP, although the effects tend to be modest and short-lived without continued therapy. Reviews have found similar effects for a wide variety of different types of acupuncture (e.g., electroacupuncture, moxibustion, auricular, cupping), with true acupuncture being slightly more effective than sham acupuncture (e.g., needles placed outside standard acupoints or applying pressure that fails to penetrate the skin). In turn, sham acupuncture is more effective than the absence of treatment, although this is likely due to placebo effects. There is no evidence to support one form of integrative treatment compared to others.

INTERVENTIONAL PAIN PROCEDURES

Most cases of LBP cannot be attributed to one anatomic source (nonspecific LBP). However, a thorough history and physical examination and the appropriate use of imaging can help identify potential targets for interventional procedures, which may provide analgesia and improve physical function when surgical indications have not been met or if contraindications for surgery exist. Most interventional pain procedures are performed fluoroscopically or with ultrasound in some cases.

LBP Without Radicular Symptoms (Axial LBP) Axial LBP most commonly involves the facet joints (e.g., zygapophyseal joint, or Z-joint, referring to the paired posterolateral articulations between the inferior articular process of a vertebra with the superior articular process of the subjacent vertebra), SI joints, intervertebral disks, vertebrae, or the paraspinal muscles and ligaments. It is important to recognize that patients can have pain from more than one of these structures simultaneously. However, estimating the prevalence of concomitant sources of spine pain remains challenging; among several structural abnormalities that may be present, only a few might be contributing to a patient's overall pain symptoms. Patients with similar radiologic findings frequently experience different severities and locations of pain from one another, likely as a consequence of each individual's confluence of biopsychosocial factors.

LUMBAR MEDIAL BRANCH NERVE BLOCKS AND ABLATION

Facet joint pain comprises 10–15% of cases of axial LBP, with prevalence increasing with age. The diagnosis of facetogenic pain can only be established through diagnostic medial branch blocks, which entail the administration of local anesthetic onto the medial branch nerves that innervate the facet joints thought to be contributing to the patient's axial pain. If the patient experiences significant improvement in pain and physical function, the diagnosis of facetogenic pain is confirmed and the same nerves can be ablated via radiofrequency ablation (RFA).

SI JOINT INTERVENTIONS

The SI joints are confirmed as the primary etiology in 20–35% of suspected cases of lower axial LBP. SI pain manifests predominantly inferior to the L5 vertebral level and is more likely to be unilateral than facetogenic pain or discogenic pain. The source of SI pain may be intraarticular, which is more likely to occur bilaterally and in older individuals, or extraarticular, which is frequently unilateral, more common in younger individuals (especially after trauma), and can be associated with unremarkable imaging. As noted earlier, the likelihood of SI pain is greatly increased when there are three or more positive provocative physical exam maneuvers (Table 18-2). In addition to being therapeutic, a low-volume intraarticular SI joint injection is the reference standard for diagnosis. Although the prevalence of intraarticular and extraarticular pathology is similar, the treatments are different. RFA of the sacral lateral branch nerves that innervate the extraarticular SI joint ligaments can be considered if intraarticular SI joint injections provide only transient relief, whereas minimally invasive fusion techniques may be indicated in refractory cases of intraarticular pathology or joint malalignment.

INTRADISCAL INJECTIONS AND THERMAL-BASED THERAPIES

Discogenic pain is the main pain generator in 26–42% of individuals with chronic, axial LBP. The diagnosis is suggested by certain physical exam findings, such as increased pain with forward lumbar flexion, sitting, or Valsalva maneuver. Provocative discography, which entails the administration of contrast into the nucleus pulposus to increase intradiscal pressure and reproduce the patient's symptoms, is purported to identify the specific disks contributing to the patient's pain. However, discography is characterized by high false-positive rates in certain populations (e.g., those with somatization and other psychiatric conditions; patients who have undergone prior spine surgery or have multifocal pain symptoms), and based on both animal and clinical studies, the procedure is associated with concerns regarding subsequent accelerated disk degeneration or injury. If the relevant disk(s) have not fragmented and there is no extrusion of intradiscal contents, intradiscal electrothermal therapy (IDET) or biacuplasty, which entails ablating the nervous tissue in the disk, might be considered, but the evidence for intermediate-term benefit is mixed. Intradiscal administration of corticosteroids or ESIs has also demonstrated mixed efficacy for short-term benefit. The intradiscal administration of bone marrow concentrate is a topic of emerging study, but concerns regarding hastened disk degeneration secondary to disk penetration with a large-bore needle and theoretical risks of tumor formation led to a 2019 U.S. Food and Drug Administration warning about stem cell therapies.

VERTEBRAL AUGMENTATION AND BASIVERTEBRAL NERVE ABLATION

Vertebrogenic pain can result from vertebral compression fractures (most commonly due to osteoporosis) or vertebral endplate inflammation. The vertebral endplates are anatomically discrete structures composed of an epiphyseal bone ring surrounding a cartilaginous interior that form the interface between vertebrae and adjacent disks. Due to the transition from the rigid,

rib-bearing thoracic spine to the more flexible lumbar spine, most fractures occur at the thoracolumbar junction (T11–L2), with the lower lumbar region being the second most common location. Most vertebral compression fractures are associated with mild to moderate pain that improves within 6–8 weeks of conservative therapy (e.g., physical therapy, oral analgesics), but up to 40% of cases might result in chronic pain. Infrequently (<10%), posterior lumbar compression fractures may be associated with nerve root impingement or spinal cord injury, in which case surgical consultation is warranted.

Although evidence is conflicting, vertebral augmentation via the percutaneous administration of cement into the fracture (vertebroplasty or kyphoplasty) can be considered for patients with severe pain or disability due to an acute (<6 weeks) compression fracture. This may work not only by stabilizing the fracture but also possibly by denervating nociceptive fibers. Posterior compression fractures may also cause facetogenic pain as the superior and inferior articular processes collapse on themselves.

Vertebral endplate inflammation due to trauma or degenerative changes may be present (though not necessarily be the primary etiology of pain) in up to 40% of patients with chronic axial lumbar pain. Vertebrogenic pain from endplate fractures or degeneration presents similarly to discogenic pain (e.g., worsened pain with bending forward, sitting, or activity), also occurs most frequently in the lower lumbar area, and can co-occur with discogenic pain. For patients in whom other structures of the spine (e.g., facet joints) are less likely to be the predominant source of their symptoms, and in whom Modic type 1 (hypointense signal on T1-weighted and hyperintense signal on T2-weighted MRI, indicating marrow edema) or type 2 changes (hyperintense signal on T1-weighted and isointense on T2-weighted MRI, signifying conversion of red hemopoietic bone marrow into yellow fatty marrow due to ischemia) are demonstrated on MRI, RFA of the basivertebral nerves that innervate the vertebral endplates can be considered.

TRIGGER POINT INJECTIONS OF MYOFASCIAL TAUT BANDS

Pain from paraspinal ligaments and muscles is frequently due to spasmodic activity that results in myofascial taut bands. Trigger point injections can relieve spasmodic activity by improving local blood flow via vasodilation and facilitate the removal of inflammatory mediators and cytokines. Evidence has not demonstrated the superiority of any specific injectate (e.g., saline, higher concentrations of local anesthetic with or without steroids, botulinum toxin), suggesting that the mechanism of action of trigger point injections is independent of the medication(s) administered.

LBP WITH RADICULAR SYMPTOMS (RADICULAR LBP)

Epidural Steroid Injections Radicular LBP is usually from spinal stenosis (e.g., central canal, lateral recess, or neuroforaminal) or disk pathology (e.g., bulge, herniation, extrusion) causing compression or irritation of one or more spinal nerve roots. Although most patients with acute radicular pain due to a herniated disk will clinically improve within 3 months with conservative management (e.g., over-the-counter analgesics and physical therapy), the natural history of pain from lumbar stenosis is more guarded. Whereas over two-thirds of herniated disks will retract within 2 years, the causes of spinal stenosis (e.g., spondylolisthesis, facet hypertrophy, ligamentum flavum hypertrophy) often progress with age. Although some studies have reported that spinal stenosis is less responsive to ESI than herniated disks, most studies have failed to show any differences in response rates, with several showing a poorer response rate for noncompressive (e.g., degenerative disks causing chemical irritation of nerve roots) pathologies. There is also some evidence for a weak but potentially meaningful surgery-sparing effect from ESIs for radicular pain.

Surgery Lumbar surgeries can be broadly categorized as entailing fusion of adjacent vertebral bodies, decompression of spinal nerve roots (i.e., diskectomy or laminectomy), or a combination. Lumbar interbody fusion is commonly performed for spinal instability (i.e., symptomatic or severe spondylolisthesis) or severe axial pain refractory to nonsurgical management and associated with severe functional disability. The precise indications for lumbar fusion remain controversial. Data are mixed regarding the effectiveness for axial back pain and disability based on randomized trials and observational cohorts, with the strongest evidence being for spondylolisthesis, which is often associated with instability. In individuals with single-level and sometimes two-level discogenic pain without posterior element involvement, the less invasive disk arthroplasty procedure has been shown to be at least as effective as circumferential or anterior fusion for pain and function with better preservation of motion; however, the quality of these studies has generally been poor, with most being industry funded. Adjacent segment disease (e.g., subsequent accelerated degeneration of adjacent disks and facet joints) can occur following both procedures but is more likely after a fusion, while the risk of postsurgical instability is greater following disk arthroplasty.

Lumbar nerve root decompression is indicated for severe or progressive neurologic deficits (i.e., loss of motor or sensory function or reflexes, indicating progressive radiculopathy) or for severe radicular pain refractory to interventional treatments (e.g., ESIs), medications, and physical therapy. The role of lumbar interbody fusion in addition to decompression is controversial, but studies have generally shown higher complication rates without greater benefit for nerve root compression without instability. Studies are mixed regarding whether surgical decompression is superior to conservative management for spinal stenosis, with meta-analyses generally finding a small benefit that diminishes after 2 years. For herniated disk, randomized trials have generally shown greater short-term reduction in pain and disability, but small and questionably meaningful benefits after 1 year. Minimally invasive surgical techniques are available for both lumbar stenosis (e.g., interspinal spacers, minimally invasive lumbar decompression) and herniated disks (e.g., chemonucleolysis, endoscopic discectomy), with low-quality data supporting at least short-term benefit for these procedures in well-selected patients.

FURTHER READING

Brinjikji W et al: Systematic literature review of imaging features of spinal degeneration in asymptomatic populations. AJNR Am J Neuroradiol 36:811, 2015.

Cohen SP et al: Effect of MRI on treatment results or decision making in patients with lumbosacral radiculopathy referred for epidural steroid injections: A multicenter, randomized controlled trial. Arch Intern Med 172:134, 2012.

Cohen SP et al: Chronic pain: An update on burden, best practices, and new advances. Lancet 397:2082, 2021.

Cohen SP et al: Multicenter study evaluating factors associated with treatment outcome for low back pain injections. Reg Anesth Pain Med 47:89, 2022.

Cook CJ et al: Systematic review of diagnostic accuracy of patient history, clinical findings, and physical tests in the diagnosis of lumbar spinal stenosis. Eur Spine J 29:93, 2020.

Itz CJ et al: Clinical course of non-specific low back pain: A systematic review of prospective cohort studies set in primary care. Eur J Pain 17:5, 2013.

Kasch R et al: Association of lumbar MRI findings with current and future back pain in a population-based cohort study. Spine (Phila Pa 1976) 47:201, 2022.

Katz JN et al: Diagnosis and management of lumbar spinal stenosis: A review. JAMA 327:1688, 2022.

Knezevic NN et al: Low back pain. Lancet 398:78, 2021.

Lo J et al: A systematic review of the incidence, prevalence, costs, and activity and work limitations of amputation, osteoarthritis, rheumatoid arthritis, back pain, multiple sclerosis, spinal cord injury, stroke, and traumatic brain injury in the United States: A 2019 Update. Arch Phys Med Rehabil 102:115, 2021.

19 Neck Pain

Fan Jiang, Soichiro Takamiya, Michael G. Fehlings

Neck pain is a highly prevalent global problem. In the United States, it is the fourth leading cause of disability and can affect people of all ages, genders, and professions. The lifetime prevalence is nearly 50%, women appear to be at a higher risk than men, and the incidence increases with age, peaking in late middle life. It is associated with sport- and work-related injuries, with low job satisfaction and poor work support having been found to play a role in work-related neck pain. Other risk factors include genetics, headaches, sleep disorders, smoking, obesity, sedentary lifestyle, secondary gain, history of neck pain, trauma, back pain, and poor overall physical or mental health.

Neck pain usually arises from diseases of the cervical spine and soft tissues of the neck, is typically precipitated by movement, and may be accompanied by focal tenderness and limitation of motion. Pain arising from the brachial plexus, shoulder, or peripheral nerves can sometimes be confused with cervical spine disease, but the history and examination usually identify a more distal origin for the pain (discussed later). The underlying causes of neck pain are diverse, and patients often present with nonspecific and vague symptoms; occipital headache is a common complaint. It is especially important to develop a systematic approach to evaluation and management, as well as to recognize dangerous etiologies including infection, malignancy, or spinal cord involvement from any cause.

When a patient presents with neck pain, the clinician should identify if the pain has a neuropathic component, indicating that the pain originates from identifiable nerves producing cervical radiculopathy. Causes of neuropathic neck pain include compression or irritation of cervical spinal nerves secondary to disk herniation, ligamentous hypertrophy, or facet overgrowth, among other etiologies, discussed below.

APPROACH TO THE PATIENT

Neck Pain

A complete clinical history is essential to gain an appreciation of the patient's chief complaints and to look for red flags. A patient's occupation, general health, and past medical history are important to identify likely pain generators and risk factors. A history of cancer, fever, and weight loss should prompt investigations to rule out malignancy and infectious etiologies. Characteristics of the pain (dull, sharp, electric, stabbing, spasms) and aggravating and alleviating factors should be determined. Any radiating pain into the occiput, arms, or hands can raise concern for radiculopathy. Patients should be specifically asked if they have experienced numbness or tingling in extremities; clumsiness in hands; change in handwriting; difficulty with buttons; unsteady gait; saddle paresthesia; and bladder or bowel incontinence.

Physical examination of the patient begins with observation. The head, neck, and shoulder should be examined for any deformity, mass, skin changes, or signs of trauma. Determining the location of the pain is imperative, as well as the quantity of pain and whether it is interfering with daily function and activities. The range of motion of the neck and shoulder should be assessed, and any restriction or guarding against movement noted. Fifty percent of cervical motion (flexion, extension, and rotation) originates from the atlantoaxial joint (C1-C2) and 50% from the subaxial (C3-C7); in general, any motion restriction needs to be further investigated to rule out underlying pathologies.

Radicular pain in the arms typically follows dermatomal distributions **(Table 19-1)**. Obtaining a precise description of the pain pattern can assist in determining if the pain is neuropathic and where the problem might originate. If a patient describes radiculopathy-like or other neuropathic pain, a complete neurologic examination is required, including assessment of the cranial nerves, motor strength, sensation, coordination, reflexes, and gait **(Chaps. 433, V6, and V7)**.

A few bedside tests are of particular value when assessing for radiculopathy or possible spinal cord involvement in patients presenting with neck pain. Spurling's maneuver is a test for radiculopathy originating from the cervical spine. It is performed by passively rotating and flexing a patient's neck laterally and performing axial compression to the top of the head. A test is considered positive if it triggers or worsens symptoms of upper extremity radiculopathy. Lhermitte's sign is elicited by gently flexing a patient's neck. It is considered positive and signifies underlying cervical spinal pathology if the maneuver reproduces electric pain down the spine or extremities. Also useful is Hoffmann's test, which should be performed whenever there is any suspicion of cervical spinal cord pathology. It is a sign of hyperreflexia

TABLE 19-1 Cervical Radiculopathy: Neurologic Features

CERVICAL NERVE ROOT	EXAMINATION FINDINGS			PAIN DISTRIBUTION
	REFLEX	SENSORY	MOTOR	
C5	Biceps	Lateral deltoid	Rhomboids[a] (elbow extends backward with hand on hip) Infraspinatus[a] (arm rotates externally with elbow flexed at the side) Deltoid[a] (arm raised laterally 30°–45° from the side)	Lateral arm, medial scapula
C6	Biceps	Palmar thumb/index finger Dorsal hand/lateral forearm	Biceps[a] (arm flexed at the elbow in supination) Pronator teres (forearm pronated)	Lateral forearm, thumb/index fingers
C7	Triceps	Middle finger Dorsal forearm	Triceps[a] (forearm extension, flexed at elbow) Wrist/finger extensors[a]	Posterior arm, dorsal forearm, dorsal hand
C8	Finger flexors	Palmar surface of little finger Medial hand and forearm	Abductor pollicis brevis (abduction of thumb) First dorsal interosseous (abduction of index finger) Abductor digiti minimi (abduction of little finger)	Fourth and fifth fingers, medial hand and forearm
T1	Finger flexors	Axilla, medial arm, anteromedial forearm	Abductor pollicis brevis (abduction of thumb) First dorsal interosseous (abduction of index finger) Abductor digiti minimi (abduction of little finger)	Medial arm, axilla

[a]These muscles receive the majority of innervation from this root.

Source: From JW Engstrom: Back and neck pain, in *Harrison's Principles of Internal Medicine*, 21st ed. New York, NY: McGraw Hill; 2022, Table 17-4, p. 127.