Fang LC et al: History, physical examination, and the virtual visit. An evidence-based approach, in *Braunwald's Heart Disease. A Textbook of Cardiovascular Medicine*, 12th ed, RO Bonow et al (eds). Philadelphia, Elsevier/Saunders, 2022, p. 123.

Jani V et al: The discerning ear: Cardiac auscultation in the era of artificial intelligence and telemedicine. Eur Heart J Digit Health 2:456, 2021.

247 Electrocardiography

Ary L. Goldberger

An *electrocardiogram* (ECG or EKG) is a graphical representation of electrical activity generated by the heart. The signals, detected by means of metallic electrodes attached to the extremities and chest wall, are amplified and recorded by the *electrocardiograph* device. ECG leads are configured to display the instantaneous *differences* in electrical potentials between specific sets of electrodes. The utility of the ECG derives from its immediate availability as a noninvasive, inexpensive, and highly versatile test. In addition to its use in detecting arrhythmias, conduction disturbances, and myocardial ischemia/infarction, the ECG may reveal findings related to life-threatening metabolic disturbances, drug toxicities, and increased susceptibility to sudden cardiac arrest **(see also Chaps. 317 and 420)**. The importance of electrocardiologic abnormalities in the diagnosis, prognosis, and management of muscular dystrophies and other hereditary neuromuscular diseases is discussed separately **(see Chap. 360)**.

ELECTROPHYSIOLOGIC BACKGROUND

Depolarization of the heart is the initiating event for cardiac contraction. The electrical currents that spread through the heart are produced by three components: cardiac pacemaker cells, specialized conduction tissue, and the heart muscle itself. The ECG records only the depolarization (stimulation) and repolarization (recovery) electrical activity generated by the "working" atrial and ventricular myocardium **(see also Chaps. 251 and 253)**.

The stimulus initiating the normal heartbeat originates in the *sinoatrial* (SA) *node* **(Fig. 247-1)**, which possesses spontaneous automaticity. Spread of the depolarization wave through the right and left atria induces contraction of these chambers. Next, the impulse stimulates specialized conduction tissues in the atrioventricular (AV) nodal and His-bundle areas; together, these two regions constitute the AV junction. The bundle of His bifurcates into two main divisions, the right and left bundle branches, which rapidly transmit depolarization wavefronts in a synchronous way to the right and left ventricular myocardium via the Purkinje fibers. The main left bundle fans out into left anterior and left posterior fascicular subdivisions. The depolarization wavefronts then spread through the ventricular wall, from endocardium to epicardium, triggering coordinated ventricular contraction. Since the cardiac depolarization and repolarization wavefronts have direction and magnitude, they can be represented by vectors.

BASIC ECG WAVEFORMS AND INTERVALS

The ECG waveforms are labeled alphabetically, beginning with the P wave, which represents atrial depolarization **(Fig. 247-2)**. The QRS complex represents ventricular depolarization; the ST-T-U complex (ST segment, T wave, and U wave) represents ventricular repolarization. The J point is the junction between the end of the QRS complex and the beginning of the ST segment. Atrial repolarization waveforms ($ST\text{-}T_a$) are usually too low in amplitude to be detected, but they may become apparent in acute pericarditis, atrial infarction, and AV heart block syndromes.

The QRS-T waveforms of the surface ECG correspond to sequential phases of simultaneously obtained ventricular *action potentials*, the intracellular recordings from single myocardial fibers **(Chap. 251)**. The rapid upstroke (phase 0) of the action potential corresponds to the onset of QRS. The plateau (phase 2) corresponds to the isoelectric ST segment, and active repolarization (phase 3) corresponds to the inscription of the T wave. Factors that decrease the slope of phase 0 by impairing the influx of Na^+ (e.g., hyperkalemia and drugs such as flecainide) tend to increase QRS duration. Factors that prolong phase 2 or 3 (e.g., amiodarone, hypocalcemia) increase the QT interval. In contrast, factors (e.g., hypercalcemia, digoxin) associated with shortening of ventricular repolarization duration abbreviate the QT. The hereditary short QT syndrome and its relationship to sudden cardiac arrest are discussed in **Chap. 262**.

The ECG is usually recorded on graph paper divided into a grid of 1-mm^2 boxes. When the recording (sweep) speed is 25 mm/s, the smallest (1 mm) horizontal divisions correspond to 40 ms (0.04 s), with heavier lines at intervals of 200 ms (0.20 s). Vertically, the ECG graph measures the amplitude of a specific wave or deflection (1 mV = 10 mm with standard calibration; the voltage criteria for hypertrophy mentioned below are given in millimeters). There are four major sets of ECG intervals: RR, PR, QRS, and QT/QT_c (Fig. 247-2). The instantaneous heart rate (beats per minute) can be computed from the interbeat (RR) interval by dividing the number of large (0.20 s) time units

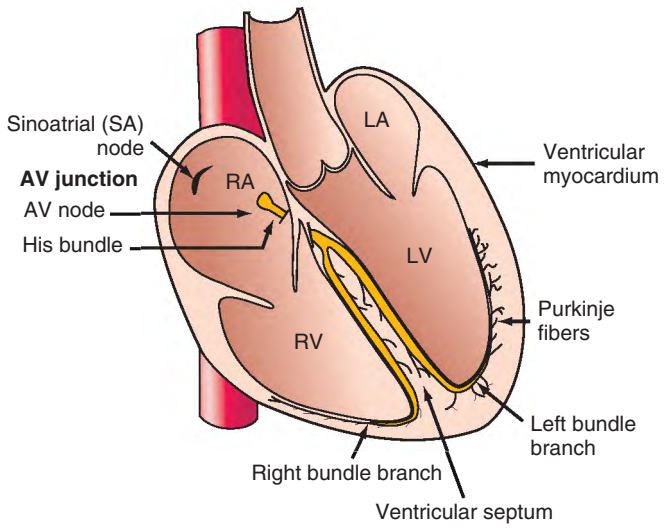

FIGURE 247-1 Schematic of the cardiac conduction system. AV, atrioventricular; LA, left atrium; LV, left ventricle; RA, right atrium; RV, right ventricle.

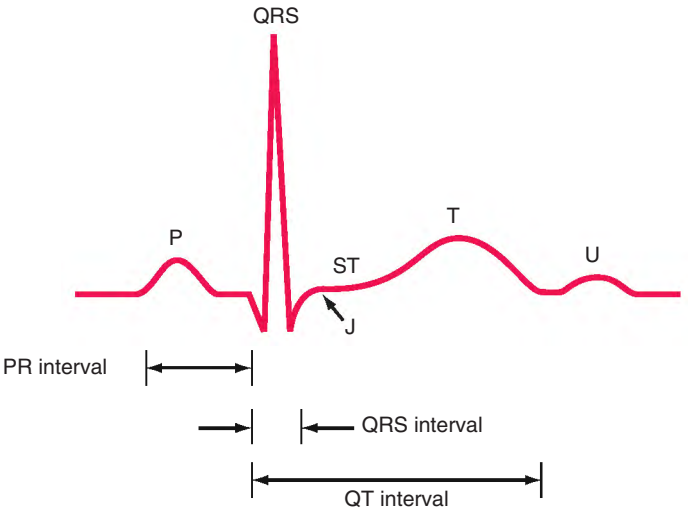

FIGURE 247-2 Basic ECG waveforms and intervals. Not shown is the RR interval, the time between consecutive QRS complexes.

between consecutive R waves into 300 or the number of small (40 ms) segments into 1500. The PR interval measures the time (normally 120–200 ms) between atrial and ventricular depolarization, which includes the physiologic delay imposed by stimulation of cells in the AV junction area. The QRS interval (normally 100–110 ms or less) reflects the duration of ventricular depolarization. The QT interval subtends both ventricular depolarization and (primarily) repolarization times and varies inversely with the heart rate. A variety of formulas has been proposed for computing a rate-corrected QT interval, termed QT_c, but without formal consensus. The classic "square root" formula ($QT_c = QT/\sqrt{RR}$, computed in second units) has been criticized for systematic errors at both lower and higher heart rates. One alternative is the Framingham formula (given here for units of milliseconds): $QT_c = QT + 0.154\,(1000 - RR)$. The following upper normal limits (based visually on the longest QT) have been proposed: QT_c of 460 ms in women and 450 ms in men. Lower limits are less well defined. Visual or electronic QT/QT_c measurements should be assessed in light of inherent limitations in their precise determination from standard ECGs waveforms.

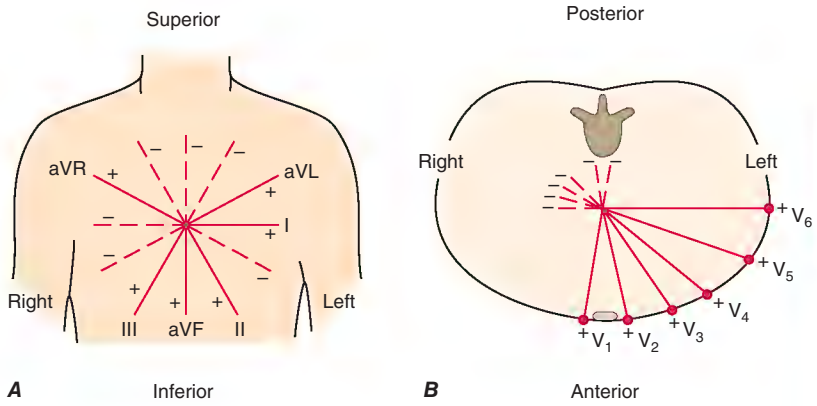

FIGURE 247-3 The six frontal plane (*A*) and six horizontal plane (*B*) leads provide a three-dimensional representation of cardiac electrical activity.

ECG LEADS

The 12 conventional ECG leads are divided into two groups: six limb (extremity) leads and six chest (precordial) leads. The limb leads record potentials transmitted onto the *frontal plane* (Fig. 247-3*A*); the chest leads record potentials transmitted onto the *horizontal plane* (Fig. 247-3*B*).

The orientation and polarity of the frontal plane leads are represented on a hexaxial diagram (Fig. 247-4). The six chest leads are obtained by exploring electrodes as shown in Fig. 247-5.

Each lead is analogous to a different video camera angle "looking" at the same events—atrial and ventricular depolarization and repolarization—from different spatial orientations. The 12-lead ECG can be supplemented with additional leads in special circumstances. For example, right precordial leads V_3R to V_6R are useful in detecting evidence of acute right ventricular ischemia/infarction. Bedside monitors and ambulatory ECGs (e.g., Holter monitors, event recorders, patch electrode and other medical wearable devices) usually employ only one or two modified leads. The standard ECG leads are configured such that a positive (upright) deflection is recorded in a lead if a wave of depolarization spreads toward the positive pole of that lead, and a negative deflection is recorded if the wave spreads toward the negative pole. If the *mean* orientation of the depolarization vector is at right angles to a particular lead axis, a biphasic (equally positive and negative) deflection will be inscribed.

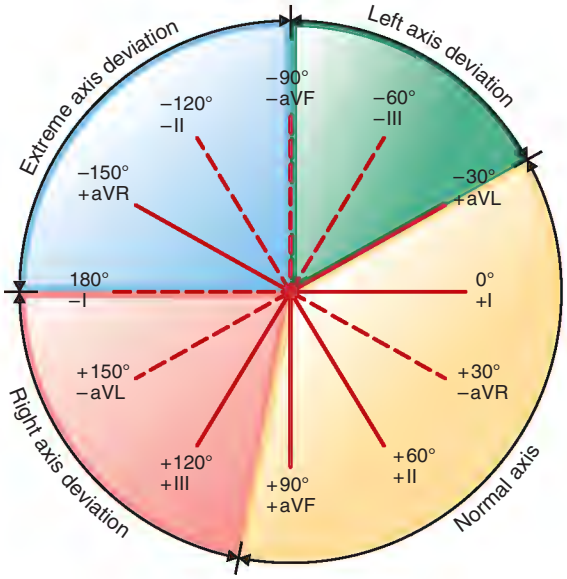

FIGURE 247-4 The frontal plane (limb or extremity) leads are represented on a hexaxial diagram. Each ECG lead has a specific spatial orientation and polarity. The positive pole of each lead axis (*solid line*) and the negative pole (*hatched line*) are designated by their angular position relative to the positive pole of lead I (0°). The mean electrical axis of the QRS complex is measured with respect to this display.

GENESIS OF THE NORMAL ECG

P WAVE

The normal atrial depolarization vector is oriented downward and toward the subject's left, reflecting the spread of depolarization from the sinus node to the right and then the left atrial myocardium. Since this vector points toward the positive pole of lead II and toward the negative pole of lead aVR, the sinus-generated P wave will be positive in lead II and negative in aVR. By contrast, activation of the atria from an ectopic pacemaker in the lower part of either atrium or in the AV junction region may produce retrograde P waves (negative in II, positive in aVR). The normal P wave in lead V_1 may be biphasic with a positive component reflecting right atrial depolarization, followed by a small (<1 mm^2) negative component reflecting left atrial depolarization.

QRS COMPLEX

Normal ventricular depolarization proceeds as a rapid, continuous spread of activation wave fronts. This complex process can be divided

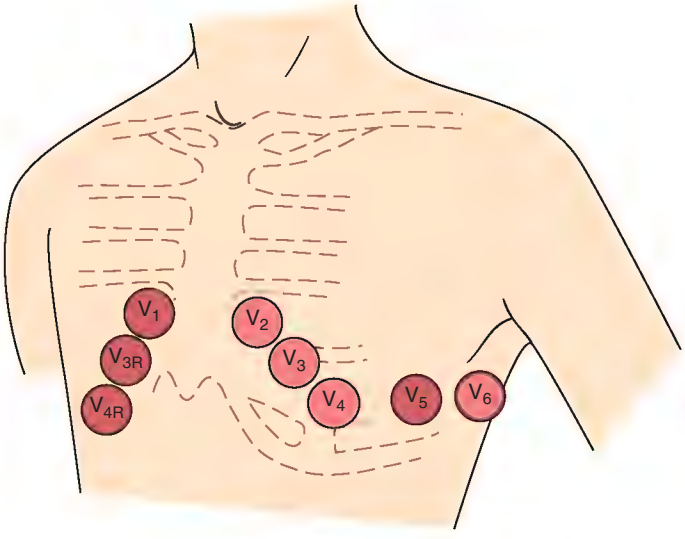

FIGURE 247-5 The horizontal plane (chest or precordial) leads are obtained with electrodes in the locations shown. Additional posterior leads are sometimes placed on the same horizontal plane as V_4 to facilitate detection of acute posterolateral infarction (V_7, midaxillary line; V_8, posterior axillary line; and V_9, posterior scapular line). Right chest leads (V_3R–V_6R) may enhance detection of right ventricular involvement in the context of inferior infarction.

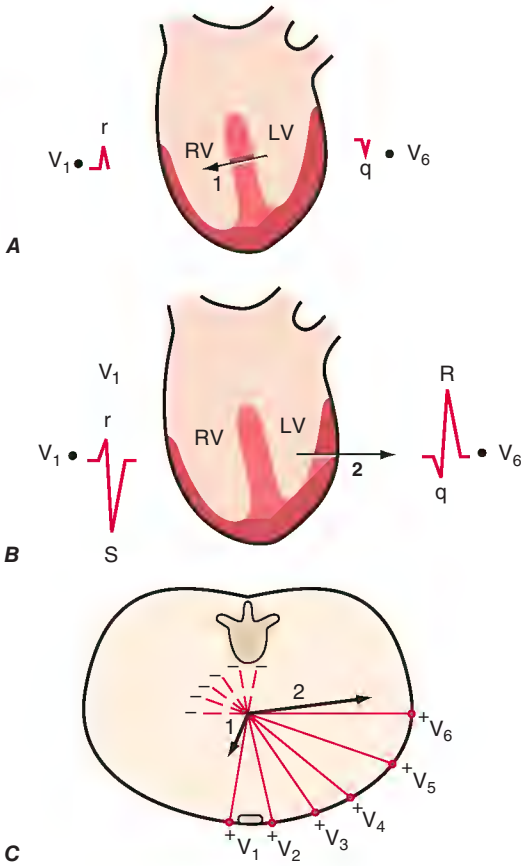

FIGURE 247-6 Ventricular depolarization can be divided into two major phases, each represented by a vector. *A.* The first phase (*arrow 1*) denotes depolarization of the ventricular septum, beginning on the left side and spreading to the right. This process is represented by a small "septal" r wave in lead V_1 and a small septal q wave in lead V_6. ***B.*** Simultaneous depolarization of the left and right ventricles (LV and RV) constitutes the second phase. Vector 2 is oriented to the left and posteriorly, reflecting the electrical predominance of the LV. ***C.*** Vectors (*arrows*) representing these two phases are shown in reference to the horizontal plane leads. *(Reproduced with permission from AL Goldberger et al: Goldberger's Clinical Electrocardiography: A Simplified Approach, 10th ed. Philadelphia, Elsevier, 2024.)*

into two major sequential phases, and each can be represented by a mean vector **(Fig. 247-6)**. The first and shortest phase is depolarization of the interventricular septum, proceeding from the left to the right and anteriorly (vector 1). The second and major phase results from the simultaneous depolarization of the right and left ventricles (vector 2). This phase is normally dominated by the more massive left ventricle, so that vector 2 points leftward and posteriorly. Therefore, a right precordial lead (V_1) will record this biphasic depolarization process with a small positive deflection (septal r wave) followed by a larger negative deflection (S wave). A left precordial lead, for example, V_6, will record the same sequence with a small negative deflection (septal q wave) followed by a relatively tall positive deflection (R wave). Intermediate leads show a relative increase in R-wave amplitude (normal R-wave progression) and a decrease in S-wave amplitude progressing across the chest from right to left. The lead where the R and S waves are of about equal amplitude is referred to as the *transition zone* (usually V_3 or V_4) **(Fig. 247-7)**.

The QRS pattern in the extremity leads may vary considerably from one normal subject to another depending on the *electrical axis* of the QRS, which describes the mean orientation of the QRS vector with reference to the six frontal plane leads. Normally, the QRS axis ranges from −30° to +100° (Fig. 247-4). An axis more negative than −30° is referred to as *left axis deviation*, and an axis more positive than +90 to +100° is referred to as *right axis deviation*. Left axis deviation may occur as a normal variant but is more commonly associated with left ventricular hypertrophy, a block in the anterior fascicle of the left bundle system (left anterior fascicular block or hemiblock), or inferior myocardial infarction. Right axis deviation also may occur as a normal variant (particularly in children and young adults), as a spurious finding due to reversal of the left and right arm electrodes, or in conditions such as right ventricular overload (acute or chronic), lateral infarction, dextrocardia, left pneumothorax, and left posterior fascicular block.

T WAVE AND U WAVE

Normally, the mean T-wave vector is oriented roughly concordant with the mean QRS vector (within about 45° in the frontal plane). Since depolarization and repolarization are electrically opposite processes, this normal QRS–T-wave vector concordance indicates that repolarization normally must proceed in the reverse direction from depolarization (i.e., from ventricular epicardium to endocardium). The normal U wave is a small, rounded deflection (≤1 mm) that follows the T wave and usually has the same polarity as the T wave. An abnormal increase in U-wave amplitude is most commonly due to hypokalemia or drugs (e.g., dofetilide, amiodarone, sotalol, quinidine). Very prominent U waves, as part of prolonged ventricular repolarization syndromes, are a marker of increased susceptibility to *torsades de pointes* **(Chap. 253)**.

MAJOR ECG ABNORMALITIES

CARDIAC ENLARGEMENT AND HYPERTROPHY

Right atrial overload (acute or chronic) may lead to an increase in P-wave amplitude (≥2.5 mm) **(Fig. 247-8)**, previously referred to as "P-pulmonale." Left atrial overload typically produces a biphasic P wave in V_1 with a broad negative component or a broad (≥120 ms), often with a notched P wave in one or more limb leads (Fig. 247-8). This pattern, historically referred to as "P-mitrale," may occur with *interatrial conduction delays* in the absence of actual atrial enlargement, leading to the more general designation of *left atrial abnormality*.

Right ventricular hypertrophy due to a sustained, severe pressure load (e.g., with pulmonic valve stenosis or certain pulmonary artery hypertension syndromes) is characterized by a relatively tall R wave in lead V_1 (R ≥ S wave), usually with right axis deviation **(Fig. 247-9)**; alternatively, there may be a qR pattern in V_1 or V_3R. ST depression and T-wave inversion in the right to mid-precordial leads are also

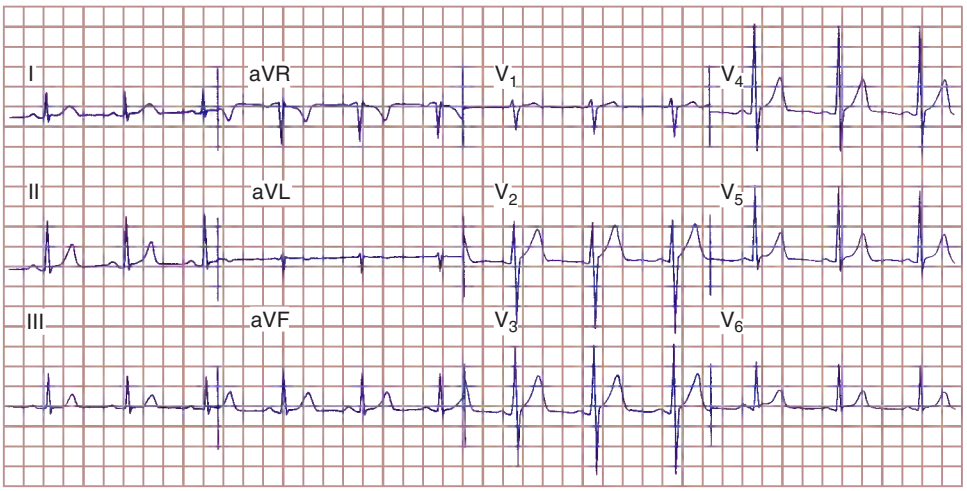

FIGURE 247-7 Normal electrocardiogram from a healthy male subject. Sinus rhythm is present with a heart rate of 75 beats per minute. PR interval is 160 ms; QRS interval (duration) is 80 ms; QT interval is 360 s; QT_c (Framingham formula) is about 390 ms; the mean QRS axis is about +70°. The precordial leads show normal R-wave progression with the transition zone (R wave ≈ S wave) in lead V_3.

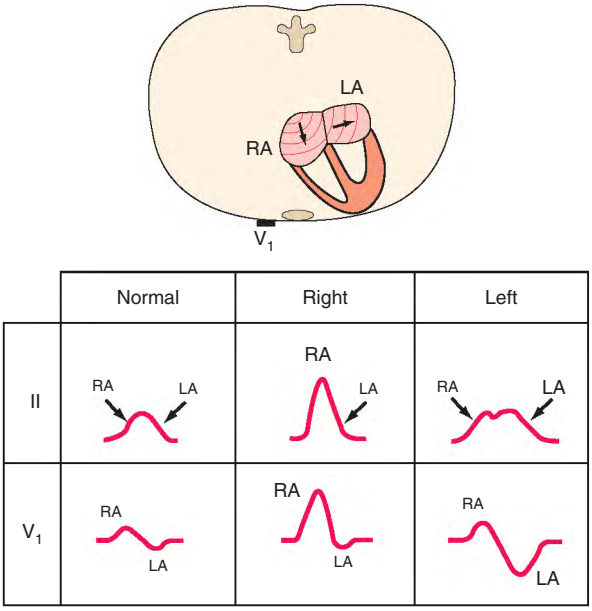

FIGURE 247-8 Right atrial (RA) overload may cause tall, peaked P waves in the limb or precordial leads. Left atrial (LA) abnormality may cause broad, often notched P waves in the limb leads and a biphasic P wave in lead V_1 with a prominent negative component representing delayed depolarization of the LA. *(Reproduced with permission from MK Park, WG Guntheroth: How to Read Pediatric ECGs, 4th ed. St. Louis, Mosby/Elsevier, 2006.)*

often present. This pattern, formerly called right ventricular "strain," is attributable to repolarization abnormalities in acutely or chronically overloaded muscle. Prominent S waves may occur in the left lateral precordial leads. Right ventricular hypertrophy due to ostium secundum atrial septal defects, with the accompanying right ventricular volume overload, is commonly associated with an incomplete or complete right bundle branch block pattern in concert with a rightward QRS axis.

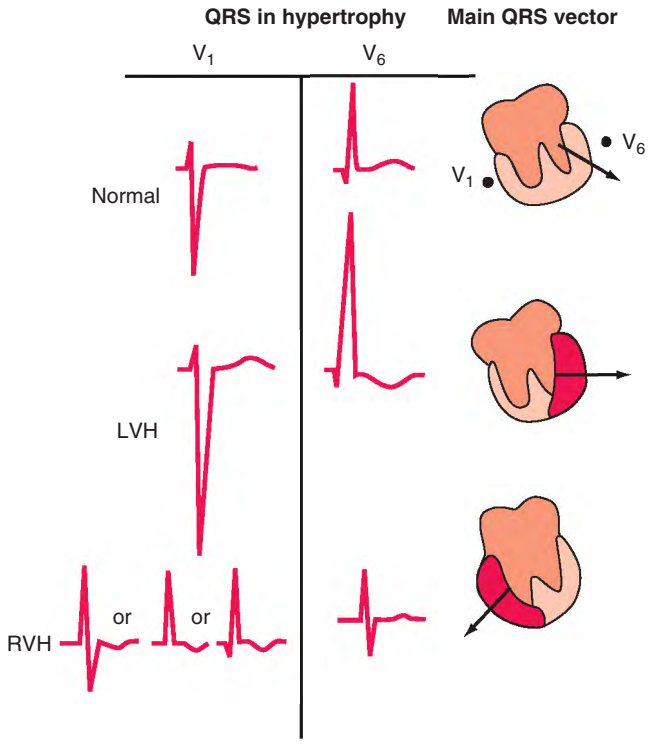

FIGURE 247-9 Left ventricular hypertrophy (LVH) increases the amplitude of electrical forces directed to the left and posteriorly. In addition, repolarization abnormalities may cause ST-segment depression and T-wave inversion in leads with a prominent R wave. Right ventricular hypertrophy (RVH) may shift the QRS vector to the right; this effect usually is associated with an R, RS, or qR complex in lead V_1. T-wave inversions may be present in right precordial leads.

Acute cor pulmonale due to pulmonary thromboembolism **(Chap. 290)** or acute respiratory distress syndromes (e.g., COVID-19) may be associated with a normal ECG or a variety of abnormalities. Sinus tachycardia is the most common arrhythmia, although other tachyarrhythmias, such as atrial fibrillation or flutter, may occur. The QRS axis may shift to the right, sometimes in concert with the so-called $S_1Q_3T_3$ pattern (prominence of the S wave in lead I and the Q wave in lead III, with T-wave inversion in lead III). Acute right ventricular dilation also may be associated with slow R-wave progression and ST-T abnormalities in V_1 to V_4 simulating acute anterior infarction. A right ventricular conduction disturbance may appear.

Chronic cor pulmonale due to obstructive lung disease **(Chap. 307)** usually does not produce the classic ECG patterns of right ventricular hypertrophy noted above. Instead of tall right precordial R waves, emphysema is more typically associated with diminished r waves in right to mid-precordial leads (slow R-wave progression) due in part to downward displacement of the diaphragm and the heart. Low-voltage complexes are commonly present, owing to hyperaeration.

Multiple voltage criteria for *left ventricular hypertrophy* (Fig. 247-9) have been proposed based on the presence of tall left precordial R waves and deep right precordial S waves (e.g., SV_1 + [RV_5 or RV_6] >35 mm). Repolarization abnormalities (ST depression with T-wave inversions, formerly called the left ventricular "strain" pattern) may appear in leads with prominent R waves. However, prominent precordial voltages occur as a common normal variant, especially in athletic or young individuals. Left ventricular hypertrophy may increase limb lead voltage with or without increased precordial voltage (e.g., RaVL + SV_3 >20 mm in women and >28 mm in men). The presence of left atrial abnormality increases the likelihood of underlying left ventricular hypertrophy in cases with borderline voltage criteria. Left ventricular hypertrophy often progresses to incomplete or complete left bundle branch block. The sensitivities of conventional voltage criteria for left ventricular hypertrophy are low in middle age to older adults and may be decreased further in obese persons and smokers, as well as with right bundle branch block. ECG evidence for left ventricular hypertrophy is a major noninvasive marker of increased risk of cardiovascular morbidity and mortality rates, including sudden cardiac death. However, because of false-positive and false-negative diagnoses, the ECG is of limited utility in diagnosing atrial or ventricular enlargement. More definitive anatomic and functional information is provided by echocardiographic and cardiac magnetic resonance imaging studies **(Chaps. 248 and A9)**.

BUNDLE BRANCH BLOCKS AND RELATED PATTERNS

Intrinsic impairment of conduction in either the right or the left bundle system (intraventricular conduction disturbances) leads to prolongation of the QRS interval. With complete bundle branch blocks, the widest QRS interval is ≥120 ms in duration; with incomplete blocks, the QRS interval is between about 110 and 120 ms. The QRS vector usually is oriented in the direction of the myocardial region where depolarization is delayed **(Fig. 247-10)**. Thus, with right bundle branch block, the terminal QRS vector is oriented to the right and anteriorly (rSR′ in V_1 and qRS in V_6, typically). Left bundle branch block alters both early and later phases of ventricular depolarization. The major QRS vector is directed to the left and posteriorly. In addition, the normal early left-to-right pattern of septal activation is disrupted such that septal depolarization proceeds from right to left as well. As a result, left bundle branch block generates wide, predominantly negative (QS) complexes in lead V_1 and entirely positive (R) complexes in V_6. Waveform patterns identical to those of left bundle branch block, preceded by a sharp (sometimes very low amplitude) spike, are seen in most cases of electronic right ventricular pacing due to the relative delay in left ventricular activation.

Bundle branch block may occur in a variety of conditions. In subjects without structural heart disease, right bundle branch block is seen more commonly than left bundle branch block. Right bundle branch block also occurs with heart disease, both congenital (e.g., atrial septal defect) and acquired (e.g., valvular, ischemic). Left bundle branch block is often a marker of one of four underlying conditions associated with increased risk of cardiovascular morbidity and mortality rates: coronary

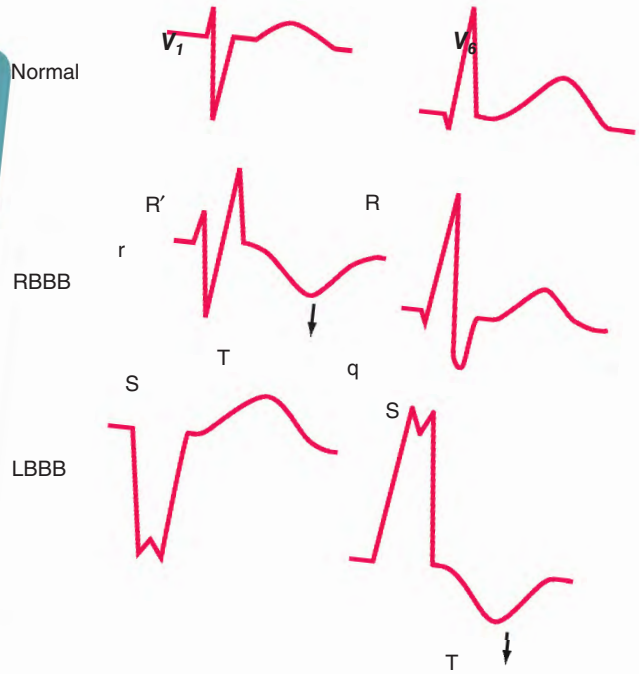

FIGURE 247-10 Comparison of typical QRS-T patterns in right bundle branch block (RBBB) and left bundle branch block (LBBB) with the normal pattern in leads V_1 and V_6. Note the secondary T-wave inversions (*arrows*) in leads with an rSR′ complex with RBBB and in leads with a wide R wave with LBBB.

heart disease (frequently with impaired left ventricular function), hypertensive heart disease, aortic valve disease (including after transcatheter aortic valve replacement), and cardiomyopathy. Bundle branch blocks may be chronic or intermittent. A bundle branch block may be rate-related, most commonly observed when the heart rate exceeds some critical value.

Bundle branch blocks and depolarization abnormalities secondary to artificial pacemakers not only affect ventricular depolarization (QRS) but also are characteristically associated with *secondary repolarization* (ST-T) abnormalities. With bundle branch blocks, the T wave is typically opposite in polarity to the last deflection of the QRS (Fig. 247-10). This discordance of the QRS–T-wave vectors is caused by the altered sequence of repolarization that occurs as a consequence of altered depolarization. In contrast, *primary repolarization* abnormalities are independent of QRS changes and are related instead to actual alterations in the electrical properties of the myocardial fibers themselves (e.g., in the resting membrane potential or action potential duration), not just to changes in the sequence of repolarization. Ischemia, electrolyte imbalance, and drugs such as digoxin all cause such primary ST–T-wave changes. Primary and secondary T-wave changes may coexist. For example, T-wave inversions in the right precordial leads with left bundle branch block or in the left precordial leads with right bundle branch block may be important markers of underlying ischemia or other abnormalities. A distinctive abnormality simulating right bundle branch block with ST-segment elevations in the right chest leads is seen with the Brugada pattern **(Chap. 262)**.

Partial blocks in the left bundle system (left anterior or posterior fascicular blocks; formerly called hemiblocks) generally do not prolong the QRS duration substantially. Instead, they are associated with shifts in the frontal plane QRS axis (leftward or rightward, respectively). Left anterior fascicular block (QRS axis more negative than −45°) is probably the most common cause of marked left axis deviation in adults. In contrast, left posterior fascicular block (QRS axis more rightward than +110–120°) is extremely rare as an isolated finding and requires exclusion of other factors causing right axis deviation. Intraventricular conduction delays also can be caused by factors extrinsic (toxic) to the conduction system that slow ventricular conduction, particularly hyperkalemia or drugs (e.g., class 1 antiarrhythmic agents, tricyclic antidepressants, phenothiazines). Prolongation of QRS duration does not necessarily indicate a conduction delay but may be due to *preexcitation* of the ventricles via a bypass tract, as in Wolff-Parkinson-White (WPW) patterns **(Chap. 256)** and related variants.

MYOCARDIAL ISCHEMIA AND INFARCTION

(See also Chap. 286) The ECG is central to the diagnosis of acute and chronic ischemic heart disease. Ischemia exerts complex time-dependent effects on the electrical properties of myocardial cells. Severe, acute ischemia lowers the resting membrane potential and shortens the duration of the action potential. Such changes cause a voltage gradient between normal and ischemic zones. As a consequence, current flows between those regions. These *currents of injury* are represented on the surface ECG by deviation of the ST segment **(Fig. 247-11)**. When the acute ischemia is *transmural*, the ST vector usually is shifted in the direction of the outer (epicardial) layers, producing ST elevations and sometimes, in the earliest stages of ischemia, tall, positive so-called hyperacute T waves over the ischemic zone. With ischemia confined primarily to the *subendocardium*, the ST vector typically shifts toward the subendocardium and ventricular cavity, so that overlying (e.g., anterior precordial) leads show ST-segment depression (with ST elevation in lead aVR). Multiple factors affect the amplitude of acute ischemic ST deviations. Profound ST elevation or depression in multiple leads usually indicates very severe ischemia. The division of acute myocardial infarction due to obstructive coronary artery disease into ST-segment elevation and non-ST elevation types is useful since the consistent efficacy of emergency (minutes to hours) reperfusion therapy is limited to the former group. Indications for acute reperfusion therapy in non-ST elevation myocardial infarction are a focus of ongoing investigation **(Chap. 285)**. Takotsubo syndrome, as well as other causes of myocardial infarction without atherosclerotic coronary disease, can simulate the patterns of acute or evolving ST-segment elevation or non-ST-segment elevation infarction **(Chap. 285)**.

The ECG leads are usually more helpful in localizing regions of ST elevation than non-ST elevation ischemia. For example, acute transmural anterior (including apical and lateral) wall ischemia is reflected by ST elevations or increased T-wave positivity in one or more of the precordial leads (V_1–V_6) and leads I and aVL. Inferior wall ischemia produces changes in leads II, III, and aVF. "Posterior" wall ischemia (almost always associated with lateral or inferior involvement) may be indirectly recognized by *reciprocal* ST depressions in leads V_1 to V_3 (thus constituting an ST elevation "equivalent" acute coronary syndrome). Acute right ventricular ischemia usually produces ST elevations in right-sided chest leads (Fig. 247-5). When ischemic ST elevations occur as the earliest sign of acute infarction, they typically are followed within a period ranging from hours to days by evolving T-wave inversions and often by Q waves occurring in the same lead distribution. Reversible transmural

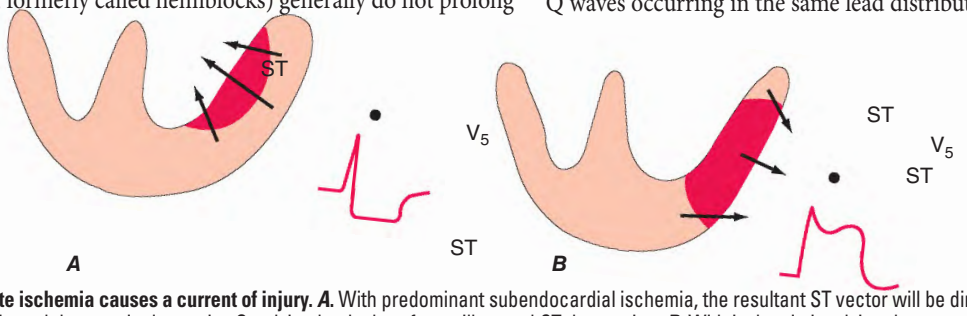

FIGURE 247-11 Acute ischemia causes a current of injury. *A.* With predominant subendocardial ischemia, the resultant ST vector will be directed toward the inner layer of the affected ventricle and the ventricular cavity. Overlying leads therefore will record ST depression. ***B.*** With ischemia involving the outer ventricular layer (transmural or epicardial injury), the ST vector will be directed outward. Overlying leads will record ST elevation.

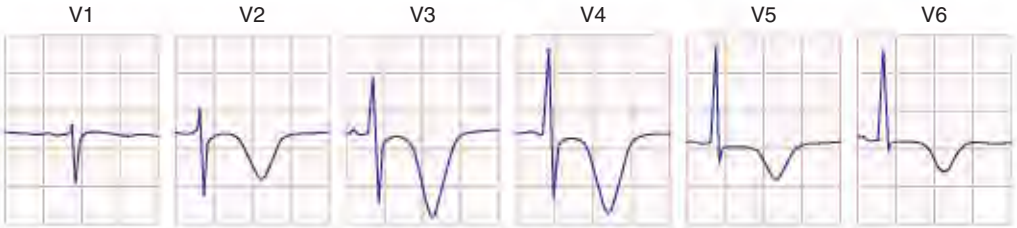

FIGURE 247-12 Severe anterior wall ischemia (with or without infarction) may cause prominent T-wave inversions in the precordial leads and in leads I and aVL. This pattern (sometimes referred to as the Wellens T wave sign) is usually associated with a high-grade stenosis of the left anterior descending coronary artery.

ischemia, for example, due to coronary vasospasm (Prinzmetal's angina) may cause transient ST-segment elevations without development of Q waves. Depending on the severity and duration of ischemia, ischemic ST elevations may resolve completely in minutes or be followed by T-wave inversions that persist for hours or even days. Patients with ischemic chest pain who present with deep T-wave inversions in multiple precordial leads (e.g., V_1–V_4, and sometimes I and aVL) with or without cardiac enzyme elevations typically have severe obstruction in the left anterior descending coronary artery **(Fig. 247-12)**.

With infarction, depolarization (QRS) changes often accompany repolarization (ST-T) abnormalities. Necrosis of sufficient myocardial tissue may lead to decreased R-wave amplitude or abnormal Q waves (even in the absence of transmural ischemia) in the anterior or inferior leads **(Fig. 247-13)**. Abnormal Q waves were once considered markers of transmural myocardial infarction, whereas subendocardial infarcts were thought not to produce Q waves. However, transmural infarcts may occur without Q waves, and subendocardial (nontransmural) infarcts may be associated with Q waves. Therefore, evolving or chronic infarcts are more appropriately classified as "Q-wave" or "non-Q-wave" **(Chap. A7)**. Loss of depolarization forces due to posterior or lateral infarction may cause reciprocal increases in R-wave amplitude in leads V_1 and V_2 without diagnostic Q waves in any of the conventional leads. (Additional leads V_7–V_9 may show acute changes.) In the weeks and months after infarction, these ECG changes may persist or begin to resolve. Complete normalization of the ECG after Q-wave infarction is uncommon but may occur, particularly with smaller infarcts. In contrast, ST-segment elevations that persist for several weeks or more after a Q-wave infarct usually correlate with a severe underlying wall motion disorder, although not necessarily a frank ventricular aneurysm.

The ECG has important limitations in both sensitivity and specificity in the diagnosis of acute and chronic ischemic heart disease. Although a single normal ECG does not exclude ischemia or even acute infarction, a normal ECG *throughout* the course of an acute infarct is distinctly uncommon. Prolonged chest pain without diagnostic ECG changes therefore should always prompt a careful search for other noncoronary causes of chest pain **(Chap. 15)**. Furthermore, the diagnostic changes of acute or evolving ischemia are often masked by the presence of left bundle branch block, electronic ventricular pacemaker patterns, and WPW preexcitation. However, clinicians may also overdiagnose ischemia or infarction based on the presence of ST-segment elevations or depressions; T-wave inversions; tall, positive T waves; or Q waves *not* related to ischemic heart disease (*pseudoinfarct* patterns). For example, ST-segment elevations simulating acute ischemia/infarction may occur with acute pericarditis or myocarditis, including COVID-19 infections, as a normal variant (including the typical "early repolarization" pattern), or in a variety of other conditions **(Table 247-1)**. Similarly, tall T waves do not invariably represent hyperacute ischemic changes but may also be caused by normal variants, hyperkalemia, or cerebrovascular injury, among other causes.

ST-segment elevations and tall, positive T waves are common findings in leads V_1 and V_2 in left bundle branch block or left ventricular hypertrophy in the absence of ischemia. The differential diagnosis of Q waves includes physiologic or positional variants, ventricular hypertrophy, acute or chronic noncoronary myocardial injury, hypertrophic cardiomyopathy, and ventricular conduction disorders. Ventricular hypertrophy, hypokalemia, drugs such as digoxin, and a variety of other factors may cause ST-segment depression mimicking subendocardial ischemia. Prominent T-wave inversion may occur with

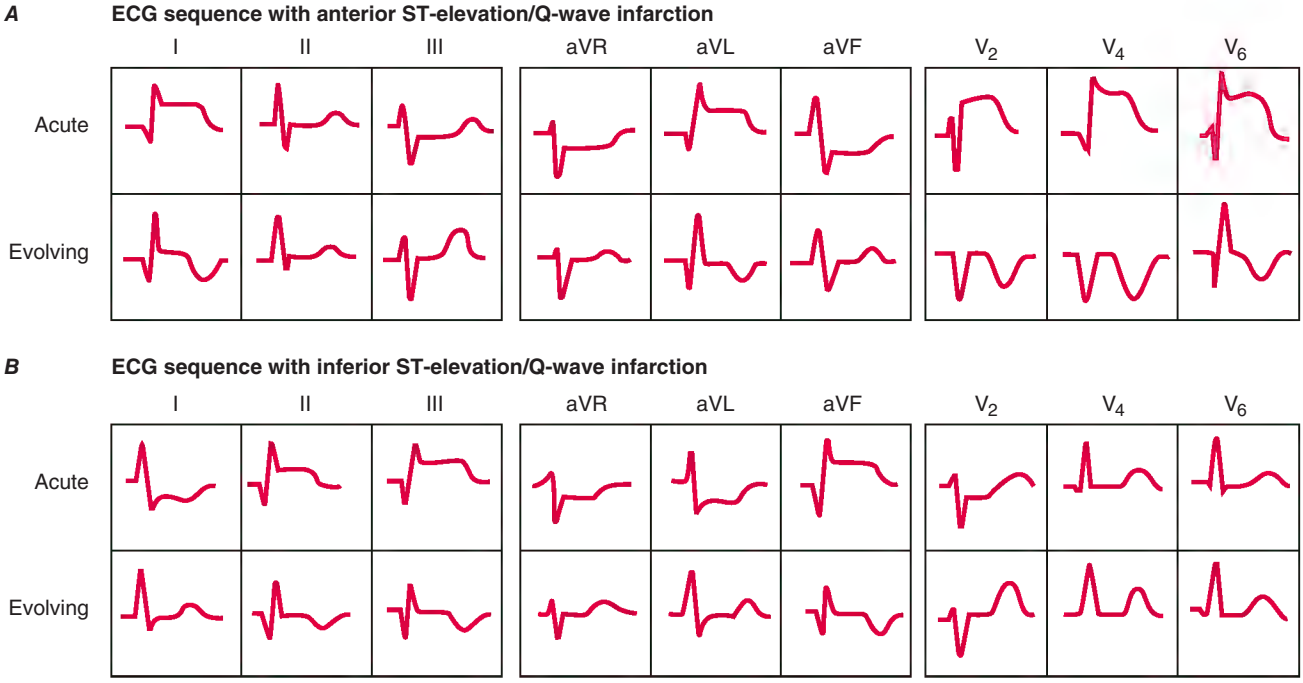

FIGURE 247-13 Sequence of depolarization and repolarization changes with acute and evolving anterior (*A*) and (*B*) inferior ST-elevation/Q-wave infarctions. With anterior infarcts, ST elevation in leads I and aVL and the precordial leads may be accompanied by reciprocal ST depressions in leads II, III, and aVF. Conversely, acute inferior (or posterolateral) infarcts may be associated with reciprocal ST depressions in leads V_1 to V_3. *(Reproduced with permission from AL Goldberger et al: Goldberger's Clinical Electrocardiography: A Simplified Approach, 10th ed. Philadelphia, Elsevier, 2024.)*

TABLE 247-1 Differential Diagnosis of ST-Segment Elevations

Myocardial ischemia/infarction
Noninfarction transmural ischemia (e.g., Prinzmetal's syndrome)
Acute myocardial infarction
Due to atherosclerotic coronary occlusion
Due to nonatherosclerotic causes (e.g., takotsubo syndrome, coronary dissection)
Post-myocardial infarction (left ventricular motion abnormality/aneurysm)
Acute pericarditis
Normal variants (including benign "early repolarization" patterns)
Left ventricular hypertrophy/left bundle branch block[a]
Other (rarer)
Acute pulmonary embolism[a]
Brugada patterns (right bundle branch block–like morphology with ST elevations in right precordial leads)
Class 1C antiarrhythmic drugs[a]
DC cardioversion (transient)
Hypercalcemia[a]
Hyperkalemia[a]
Hypothermia (J [Osborn] waves)
Nonischemic myocardial injury
Myocarditis syndromes (infectious and noninfectious)
Tumor invading left ventricle
Trauma to ventricles

[a]Usually localized to V_1–V_2 or V_3.

Source: Modified from AL Goldberger et al: *Goldberger's Clinical Electrocardiography: A Simplified Approach,* 10th ed. Elsevier, 2024.

ventricular hypertrophy, cardiomyopathies, myocarditis, and "stress cardiomyopathies" associated with takotsubo syndrome and cerebrovascular injury (particularly intracranial bleeds), among others causes. Diagnostic confusion may also occur when nonischemic T-wave inversions ("cardiac memory" effect) appear in normally conducted beats in patients with intermittent wide QRS complexes, most commonly due to ventricular pacing or to left bundle branch block.

METABOLIC FACTORS AND DRUG EFFECTS

A variety of metabolic abnormalities and pharmacologic agents alter the ECG and, in particular, cause changes in repolarization (ST-T-U) and sometimes QRS prolongation. Certain life-threatening electrolyte disturbances may be diagnosed initially and monitored from the ECG. *Hyperkalemia* produces a sequence of changes **(Fig. 247-14)**, usually beginning with narrowing and peaking (tenting) of the T waves. Further elevation of extracellular K^+ leads to AV conduction disturbances, diminution in P-wave amplitude, and widening of the QRS interval. Severe hyperkalemia eventually causes cardiac arrest with a slow sinusoidal type of mechanism ("sine-wave" pattern) followed by asystole. *Hypokalemia* **(Fig. 247-15)** prolongs ventricular repolarization, often with prominent U waves. Prolongation of the QT interval is also seen with drugs that increase the duration of the ventricular action potential: class 1A antiarrhythmic agents and related drugs (e.g., quinidine, procainamide, tricyclic antidepressants, phenothiazines) and class III agents (e.g., amiodarone [Fig. 247-15], dofetilide, sotalol, ibutilide). Systemic *hypothermia* (Fig. 247-15) also prolongs repolarization, usually with a distinctive convex elevation of the J point (Osborn wave) and bradycardia. Marked QT prolongation, sometimes with deep, wide T-wave inversions, may occur with intracranial bleeds, particularly subarachnoid hemorrhage ("CVA T-wave" pattern) (Fig. 247-15). *Hypocalcemia* typically prolongs the QT interval (ST portion), whereas *hypercalcemia* shortens it **(Fig. 247-16)**. Digitalis glycosides also shorten the QT interval, often with a characteristic "scooping" of the ST–T-wave complex (*digitalis effect*).

NONSPECIFIC ST-T CHANGES AND LOW QRS VOLTAGE

Many other factors are associated with ECG changes, particularly alterations in ventricular repolarization. T-wave flattening, minimal T-wave inversions, or slight ST-segment depression ("nonspecific ST–T-wave changes") may occur with a variety of electrolyte and acid-base disturbances, infectious or inflammatory processes, central nervous system disorders, endocrine abnormalities, many drugs, ischemia, hypoxia, and virtually any type of cardiopulmonary abnormality, in addition to physiologic changes (e.g., with posture or after meals). Low QRS voltage is arbitrarily defined as peak-to-trough QRS amplitudes of ≤5 mm in the six limb leads and/or ≤10 mm in the chest leads. Multiple factors may be responsible. Among the most serious include pericardial **(Fig. 247-17)** or pleural effusions, chronic obstructive pulmonary disease, cardiac amyloid, and anasarca.

ELECTRICAL ALTERNANS SYNDROMES

Electrical alternans—a beat-to-beat alternation in one or more components of the ECG signal—is a common type of nonlinear cardiovascular response to a variety of hemodynamic and electrophysiologic perturbations. Total electrical alternans (P-QRS-T) with sinus tachycardia is a relatively specific sign of pericardial effusion, usually with cardiac tamponade (Fig. 247-17). In contrast, pure repolarization

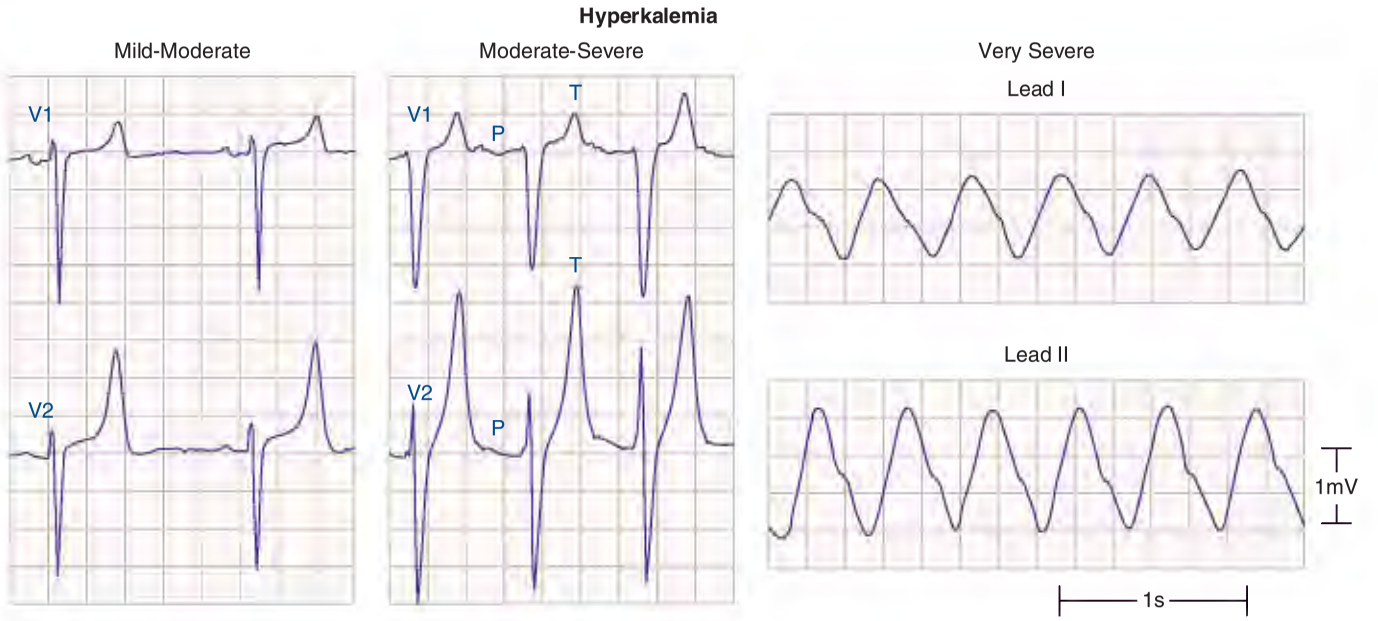

FIGURE 247-14 The earliest ECG change with hyperkalemia is usually peaking ("tenting") of the T waves. With further increases in the serum potassium concentration, the QRS complexes widen, the P waves decrease in amplitude and may disappear, and finally a sine-wave pattern leads to asystole unless emergency therapy is given. *(Reproduced with permission from AL Goldberger et al: Goldberger's Clinical Electrocardiography: A Simplified Approach, 10th ed. Philadelphia, Elsevier, 2024.)*

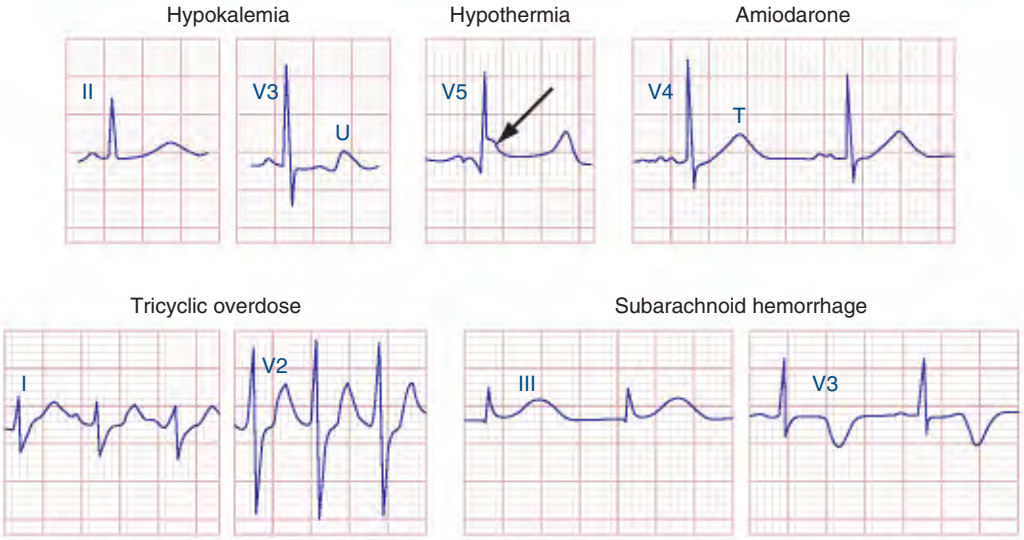

FIGURE 247-15 A variety of metabolic derangements, drug effects, and other factors may prolong ventricular repolarization with QT prolongation or prominent U waves. Prominent repolarization prolongation, particularly if due to hypokalemia, inherited "channelopathies," or certain pharmacologic agents, indicates increased susceptibility to *torsades des pointes* ventricular tachycardia **(Chap. 261)**. Marked systemic hypothermia is associated with a distinctive convex "hump" at the J point (Osborn wave, *arrow*) attributed to altered transmural ventricular action potential characteristics. Note QRS and QT prolongation along with sinus tachycardia in the case of tricyclic antidepressant overdose.

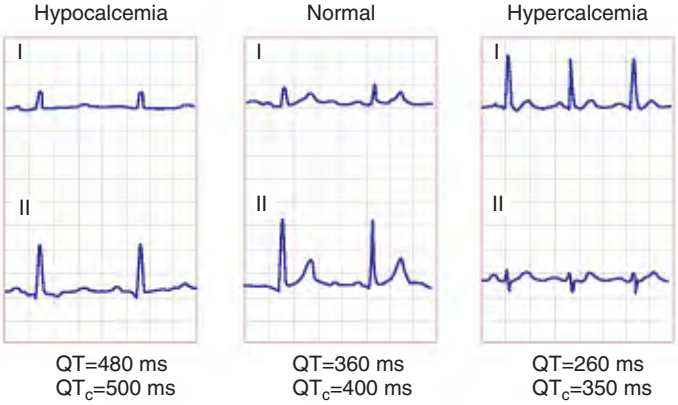

FIGURE 247-16 Prolongation of the Q-T interval (ST-segment portion) is typical of hypocalcemia. Hypercalcemia may cause abbreviation of the ST segment with relative or absolute shortening of the QT interval.

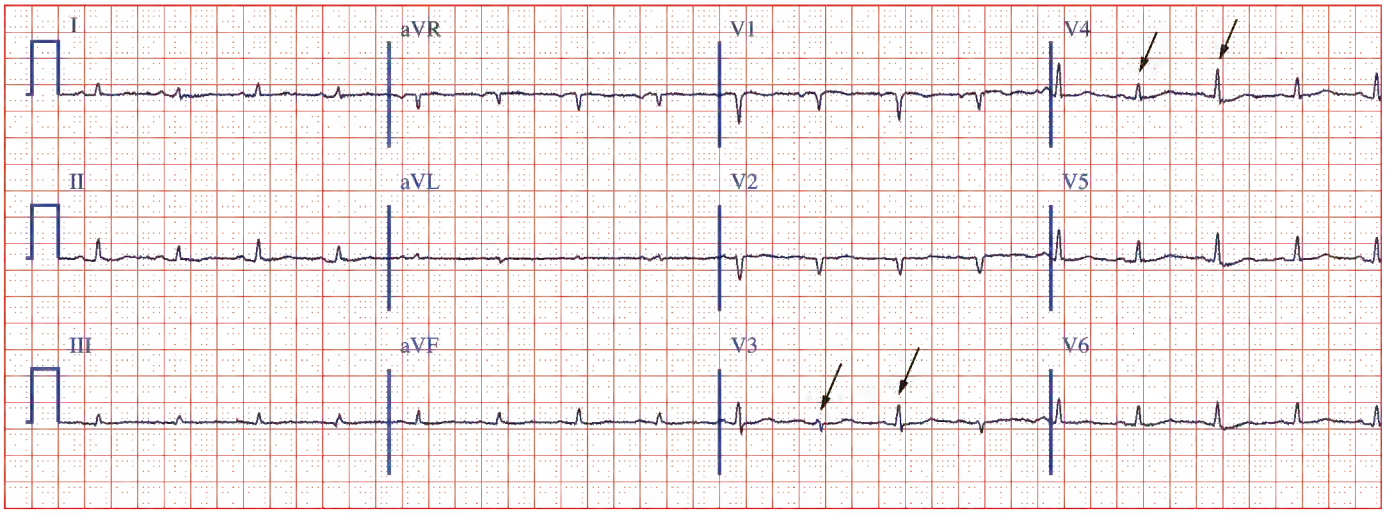

FIGURE 247-17 Classic triad of findings for pericardial effusion with cardiac tamponade: (1) sinus tachycardia; (2) low QRS voltages and (3) electrical alternans (best seen in leads V_3 and V_4 in this case; *arrows*). This triad is highly suggestive of pericardial effusion, usually with tamponade physiology, but is of limited sensitivity. *(Adapted from LA Nathanson et al: ECG Wave-Maven. ecg.bidmc.harvard.edu.)*