FURTHER READING

American Thoracic Society/European Respiratory Society: Consensus classification of the idiopathic interstitial pneumonias. Am J Respir Crit Care Med 165:277, 2002.

Raghu G et al; ATS/ERS/JRS/ALAT Committee on Idiopathic Pulmonary Fibrosis: An official ATS/ERS/JRS/ALAT statement: Idiopathic pulmonary fibrosis: Evidence-based guidelines for the diagnosis and management. Am J Respir Crit Care Med 183:788, 2011.

Travis WD et al: Idiopathic nonspecific interstitial pneumonia: Report of an American Thoracic Society project. Am J Respir Crit Care Med 177:1338, 2008.

Travis WD et al: An official American Thoracic Society/European Respiratory Society Statement: Ten decade update on IIP's, potential areas for future investigation are proposed (ATS/ERS update of the international multidisciplinary classification of the idiopathic interstitial pneumonias. Am J Respir Crit Care Med 188:733, 2013.

305 Disorders of the Pleura

Khalid Ismail, Hilary J. Goldberg, Rebecca M. Baron

The pleural space lies between the lung and the chest wall and normally contains a very thin layer of fluid, which serves as a coupling system. This space is maintained around −3 to −5 cmH_2O because of a constant balance between the elastic recoil of the lung, with its attached visceral pleura, and the counter expansion of the chest wall with attached parietal pleura. Invasion of this space with organisms, inflammatory or cancer cells, or introduction of air, blood, or chyle can lead to significant disease.

PLEURAL EFFUSION

A pleural effusion is present when there is an excess quantity of fluid in the pleural space.

Etiology Under normal conditions, fluid enters the pleural space from the capillaries in the parietal pleura and is removed via the lymphatics in the parietal pleura. Fluid also can enter the pleural space from the interstitial spaces of the lung via the visceral pleura or from the peritoneal cavity via small holes in the diaphragm. The lymphatics have the capacity to absorb 20 times more fluid than is formed normally. Hydrostatic and oncotic pressures play a fundamental role. A pleural effusion develops when there is disturbance in hydrostatic-oncotic balance, leading to pleural fluid formation that overwhelms fluid removal by the lymphatics. It is estimated that 1.5 million Americans per year develop pleural effusion. The most common presentation is that of shortness of breath and occasionally chest pain.

Diagnostic Approach Patients suspected of having a pleural effusion should undergo chest imaging to evaluate its extent. Although chest x-ray with lateral decubitus films have been the standard diagnostic modality (and remains so in some parts of the world), advances in chest ultrasound and computed tomography (CT) imaging have made them invaluable, for both identifying characteristics of the effusion and guiding pleural sampling and/or drainage. When a patient is found to have a pleural effusion, an effort should be made to determine the cause (Fig. 305-1). The first step is to determine whether the effusion is a transudate or an exudate, which requires thoracentesis. A transudative pleural effusion occurs when systemic factors (hydrostatic-oncotic pressures) that influence the formation and absorption of pleural fluid are altered. The leading causes of transudative pleural effusions in the United States are left ventricular failure and cirrhosis. An exudative pleural effusion occurs when local factors that influence the formation and absorption of pleural fluid are altered. The leading causes of exudative pleural effusions are bacterial pneumonia, malignancy, viral infection, and pulmonary embolism (Table 305-1). The primary reason for making this differentiation is that additional diagnostic procedures are indicated with exudative effusions to define the cause.

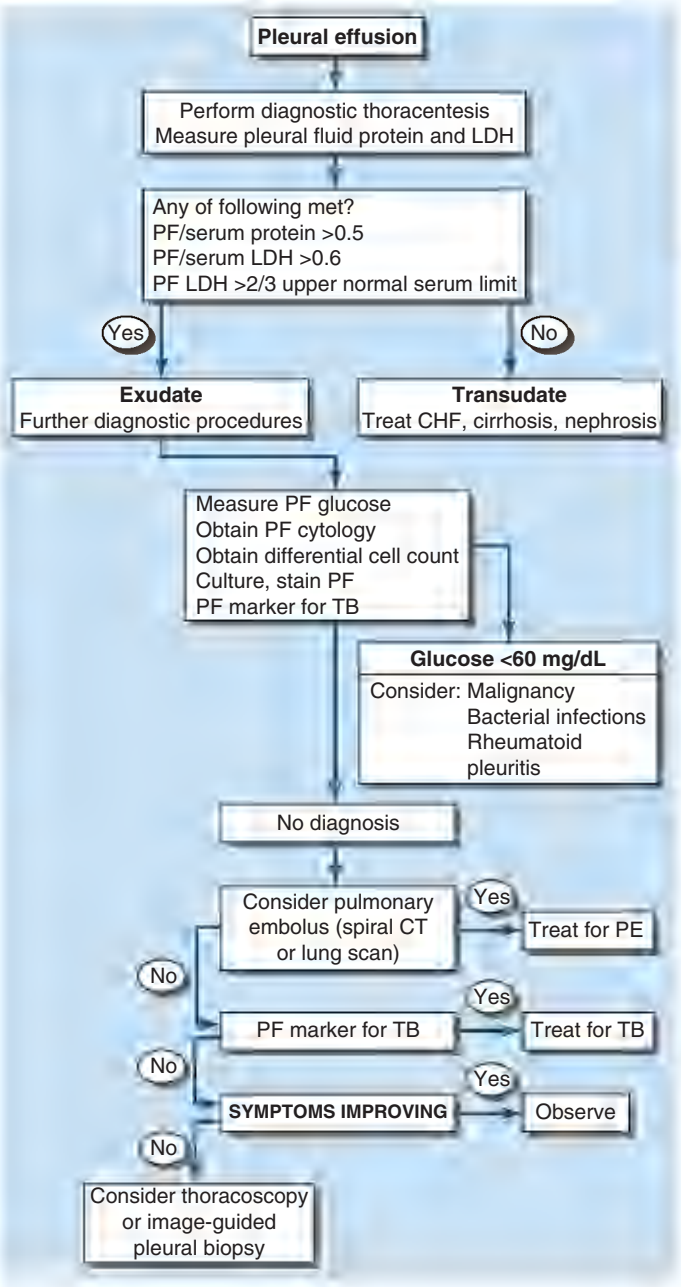

FIGURE 305-1 Approach to the diagnosis of pleural effusions. CHF, congestive heart failure; CT, computed tomography; LDH, lactate dehydrogenase; PE, pulmonary embolism; PF, pleural fluid; TB, tuberculosis.

Transudative and exudative pleural effusions are distinguished by measuring the lactate dehydrogenase (LDH) and protein levels in the pleural fluid. Exudative pleural effusions meet at least one of the following criteria, whereas transudative pleural effusions meet none:

1. Pleural fluid protein/serum protein >0.5
2. Pleural fluid LDH/serum LDH >0.6
3. Pleural fluid LDH more than two-thirds the normal upper limit for serum

These criteria misidentify ~25% of transudates as exudates ("pseudoexudates"), often felt to be related to a "diuresed transudate." If one or more of the exudative criteria are met and the patient is clinically thought to have a condition producing a transudative effusion, alternative criteria can be used. Serum to pleural fluid protein gradient (SPPG) and serum to pleural fluid albumin gradient (SPAG) >3.1 g/dL and

TABLE 305-1 Differential Diagnoses of Pleural Effusions

Transudative Pleural Effusions

1. Congestive heart failure
2. Cirrhosis
3. Nephrotic syndrome
4. Peritoneal dialysis
5. Superior vena cava obstruction
6. Myxedema
7. Urinothorax

Exudative Pleural Effusions

1. Neoplastic diseases
   a. Metastatic disease
   b. Mesothelioma
2. Infectious diseases
   a. Bacterial infections
   b. Tuberculosis
   c. Fungal infections
   d. Viral infections
   e. Parasitic infections
3. Pulmonary embolization
4. Gastrointestinal disease
   a. Esophageal perforation
   b. Pancreatic disease
   c. Intraabdominal abscesses
   d. Diaphragmatic hernia
   e. After abdominal surgery
   f. Endoscopic variceal sclerotherapy
   g. After liver transplant
5. Collagen vascular diseases
   a. Rheumatoid pleuritis
   b. Systemic lupus erythematosus
   c. Drug-induced lupus
   d. Sjögren syndrome
   e. Granulomatosis with polyangiitis (Wegener)
   f. Churg-Strauss syndrome
6. Post–coronary artery bypass surgery
7. Asbestos exposure
8. Sarcoidosis
9. Uremia
10. Meigs' syndrome
11. Yellow nail syndrome
12. Drug-induced pleural disease
    a. Nitrofurantoin
    b. Dantrolene
    c. Methysergide
    d. Bromocriptine
    e. Procarbazine
    f. Amiodarone
    g. Dasatinib
13. Trapped lung
14. Radiation therapy
15. Post–cardiac injury syndrome
16. Hemothorax
17. Iatrogenic injury
18. Ovarian hyperstimulation syndrome
19. Pericardial disease
20. Chylothorax

>1.2 g/dL, respectively, together can identify pseudoexudates with 100% sensitivity in heart failure and 99% sensitivity in hepatothorax. Elevated pleural fluid cholesterol has also been used, especially when combined with elevated LDH, to favor a true exudate. In addition to describing the appearance of pleural fluid, the following pleural fluid tests should be obtained: glucose level, differential cell count, microbiologic studies, and cytology. More disease-specific diagnostic tests can be obtained depending on the clinical scenario (see examples in **Table 305-2**).

TABLE 305-2 Disease-Specific Pleural Fluid Tests

SUSPECTED DISEASE	TESTS
Pancreatic disease or esophageal rupture	Pleural fluid amylase
Drug-induced pleural effusion	Pleural fluid eosinophils
Congestive heart failure	Pleural fluid N-terminal pro-brain natriuretic peptide (NT-proBNP)
Chylothorax	Pleural fluid cholesterol and triglycerides
Hemothorax	Pleural fluid hematocrit
Rheumatoid disease	Pleural fluid glucose and pH
Amyloidosis	Congo red staining
Lymphoma	Flow cytometry

Effusion Due to Heart Failure The most common cause of pleural effusion is left ventricular dysfunction. Elevated left atrial pressure with elevated pulmonary venous pressure leads to increased amounts of fluid in the lung interstitial spaces exiting in part across the visceral pleura (a classic example of increased hydrostatic pressure), and this overwhelms the capacity of the lymphatics in the parietal pleura to remove the fluid. In patients with heart failure, a diagnostic thoracentesis should be performed if the effusions are not bilateral and comparable in size, if the patient is febrile, or if the patient has pleuritic chest pain, to verify that the patient has a transudative effusion. Otherwise, the patient's heart failure is treated. If the effusion persists despite therapy, a diagnostic thoracentesis should be performed. A pleural fluid N-terminal pro-brain natriuretic peptide (NT-proBNP) level >1500 pg/mL is suggestive of an effusion that is secondary to congestive heart failure and correlates well with serum values.

Parapneumonic Effusion Parapneumonic effusions (PPEs) can be seen in up to 50% of patients with community-acquired pneumonia and are generally the most common cause of exudative pleural effusion in the United States. PPEs are usually reactive (i.e., no organisms identified on culture). In 10% of patients with PPE, infection of the pleural space sets in, leading to a complicated PPE or an empyema, which refers to a fibrinopurulent or grossly purulent effusion, respectively.

Patients with aerobic bacterial pneumonia and pleural effusion may present with an acute febrile illness consisting of pleuritic chest pain, sputum production, and leukocytosis. Patients with anaerobic infections can present with a subacute illness with weight loss, leukocytosis, mild anemia, and a history of some factor that predisposes them to aspiration. These patients can have minimal parenchymal infiltrates with a large effusion.

The possibility of a PPE should be considered whenever a patient with bacterial pneumonia is initially evaluated. Thoracentesis is usually indicated to exclude infection of the pleural space if significant pleural fluid is present. The presence of free-flowing pleural fluid can be demonstrated with a lateral decubitus radiograph, CT of the chest, or ultrasound **(Fig. 305-2*A*, *C*)**. Traditionally, a minimum of 10 mm of free fluid on a lateral decubitus film suggests the safety of thoracentesis. Presently, CT/ultrasound guidance permits a better determination, both for safety of thoracentesis as well as likelihood of a complicated PPE (usually indicated by loculation or septations in the fluid; **Fig. 305-2*B*, *D***) that might make bedside thoracentesis more challenging. Factors indicating the likely need for evacuation of the pleural space by more advanced intervention (in increasing order of importance) include the following:

1. Loculated pleural fluid
2. Pleural fluid pH <7.20
3. Pleural fluid glucose <3.3 mmol/L (<60 mg/dL)
4. Positive Gram's stain or culture of the pleural fluid
5. Presence of gross pus in the pleural space

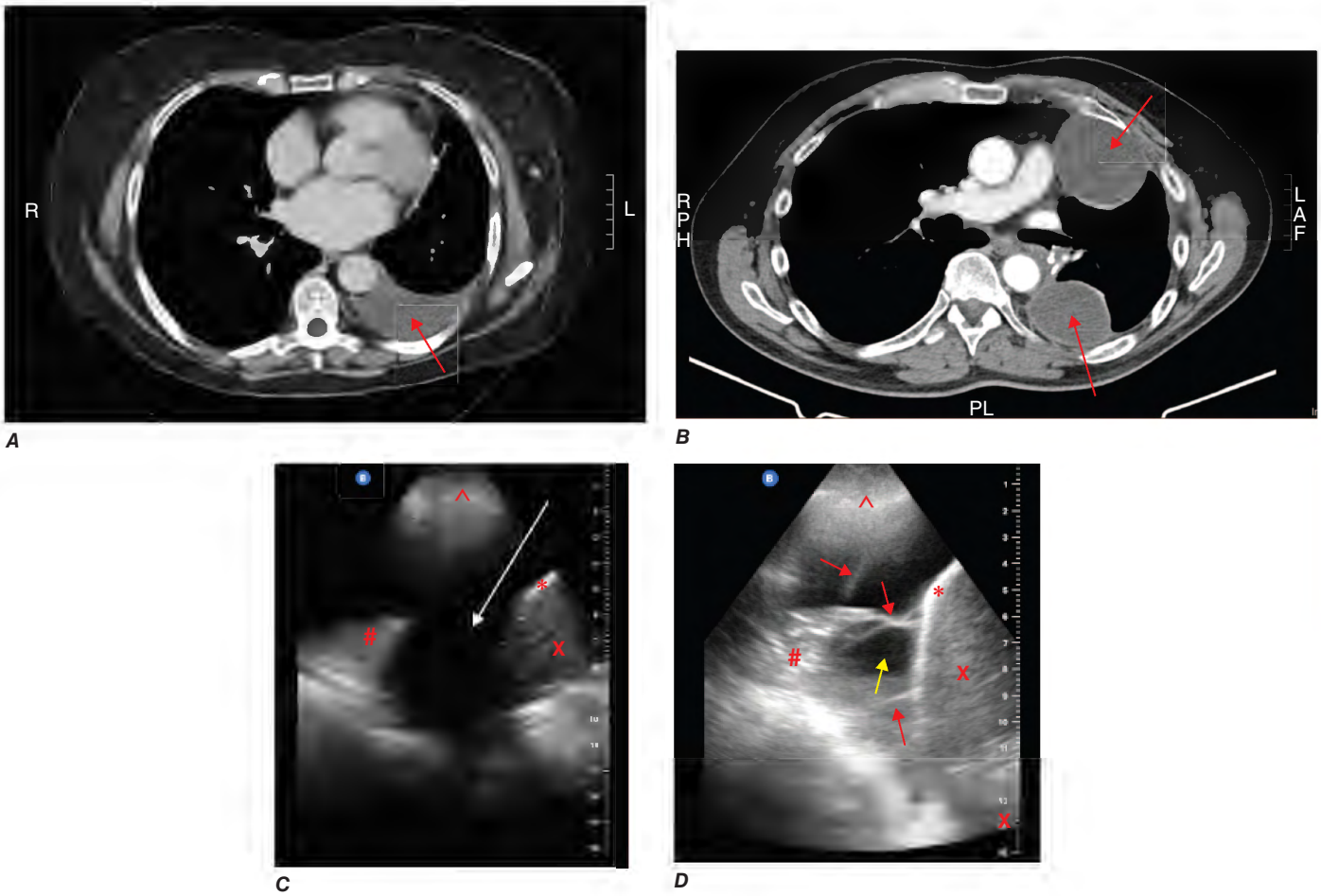

FIGURE 305-2 ***A.*** CT scan from a patient with simple pleural effusion, demonstrating free-flowing fluid in the left pleural space (red arrow). ***B.*** CT scan from a patient with loculated pleural effusion, demonstrating two pockets of fluids (*red arrows*). ***C.*** Ultrasound image of a simple pleural effusion, demonstrating free-flowing fluid (*arrow*), atelectatic lung (#), chest wall (^), diaphragm (*), and liver (x). ***D.*** Ultrasound image of a complex pleural effusion, with loculations (*yellow arrow*) and septations (*red arrows*), diaphragm (*), consolidated lung (#), chest wall (^), and liver (x).

An elevated pleural fluid LDH (>900 IU/L) is another feature that suggests the need for pleural fluid evacuation.

Effusions can progress from exudative to fibrinopurulent to an organizing phase (pleural peel) (Fig. 305-3). If the fluid is fibrinopurulent and cannot be completely drained by thoracentesis, consideration should be given to insertion of a chest tube for drainage and possible instillation of the combination of a fibrinolytic agent (e.g., tissue plasminogen activator, 10 mg) and deoxyribonuclease (5 mg), or performing a thoracoscopy with the breakdown of adhesions if chest tube drainage does not completely evacuate the pleural space. Surgical decortication should be considered when these measures are ineffective.

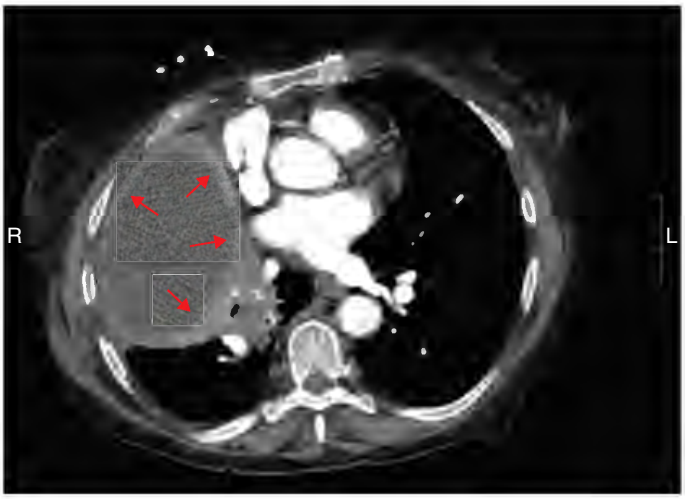

FIGURE 305-3 CT scan from a patient with empyema. Note thick pleural rind with that enhances with contrast (*red arrows*).

Trapped lung (i.e., a lung that cannot re-expand) might develop if a fibrous restrictive peel forms around the visceral pleura, usually in the setting of long-standing pleuro-pulmonary pathology. Although measuring pleural pressure at the time of thoracentesis (pleural manometry) can help confirm trapped lung, a thick pleural rind, presence of air on chest imaging after thoracentesis (termed pneumothorax ex vacuo), and recurrence of effusion shortly after drainage are suggestive of a lung that will not re-expand without decortication.

Effusion Secondary to Malignancy Malignant pleural effusions are the second most common type of exudative pleural effusion. The three tumors that cause ~75% of all malignant pleural effusions are lung carcinoma, breast carcinoma, and lymphoma. Its presence usually portends poor prognosis (<6-month survival). Most patients complain of dyspnea, which is frequently out of proportion to the size of the effusion. The pleural fluid is usually an exudate (although it can rarely be a transudate), and its glucose level may be reduced if the tumor burden in the pleural space is high.

The diagnosis usually is made via cytology of the pleural fluid. If the initial cytologic examination is negative, CT- or ultrasound-guided needle biopsy of pleural thickening or nodules can confirm the diagnosis. Ultimately, thoracoscopic biopsy is most definitive if malignancy is strongly suspected.

Patients with a malignant pleural effusion are treated symptomatically for the most part, since the presence of the effusion indicates disseminated disease, and most malignancies associated with pleural effusion are not curable with chemotherapy. If the patient's lifestyle

is compromised by dyspnea and if the dyspnea is not relieved with a therapeutic thoracentesis, one of the following procedures should be considered: (1) insertion of a small indwelling catheter for regular home drainage (improves dyspnea) or (2) tube thoracostomy with the instillation of a sclerosing agent (chemical pleurodesis) versus thoracoscopy with drainage of the effusion and surgical pleurodesis.

Mesothelioma Malignant mesotheliomas are primary tumors that arise from the mesothelial cells that line the pleural cavity; most are related to asbestos exposure. Incidence has dropped because of asbestos remediation measures. Patients with mesothelioma often present with chest pain and shortness of breath. The chest radiograph reveals a pleural effusion, generalized pleural thickening, and a shrunken hemithorax. The diagnosis is usually established with image-guided needle biopsy or thoracoscopy.

Hepatic Hydrothorax Pleural effusions occur in ~5% of patients with cirrhosis and ascites. The predominant mechanism is the direct movement of peritoneal fluid through small openings in the diaphragm into the pleural space. Ascites is common, and the effusion is usually right-sided and often large enough to produce severe dyspnea. Like ascitic fluid, it is usually low in protein (transudative) but can develop into a spontaneous bacterial empyema. Treatment is that of ascites, but if recurrent or persistent, pleurodesis, transjugular intrahepatic portosystemic shunt, or liver transplant might be required.

Effusion Secondary to Pulmonary Embolism The diagnosis most commonly overlooked in the differential diagnosis of a patient with an undiagnosed pleural effusion is pulmonary embolism. Dyspnea is the most common symptom. The pleural fluid is almost always an exudate. The diagnosis is established most often by CT angiography **(Chap. 290)**. Treatment of a patient with a pleural effusion secondary to pulmonary embolism is the same as it is for any patient with pulmonary emboli. If the pleural effusion increases in size after anticoagulation, the patient may have recurrent emboli or another complication, such as a hemothorax or a pleural infection.

Tuberculous Pleuritis/Effusion (See also Chap. 183) In many parts of the world, the most common cause of an exudative pleural effusion is tuberculosis (TB), but tuberculous effusions are relatively uncommon in the United States. Tuberculous pleural effusions usually are associated with primary TB and are thought to be due primarily to a hypersensitivity reaction to tuberculous protein in the pleural space. Patients with tuberculous pleuritis present with fever, weight loss, dyspnea, and/or pleuritic chest pain. The pleural fluid is exudative and predominantly lymphocytic. The diagnosis is suggested by demonstrating high levels of TB markers in the pleural fluid (adenosine deaminase >40 IU/L or interferon γ >140 pg/mL).

Diagnosis is established by culture of the pleural fluid for acid-fast bacilli, needle biopsy of the pleura, or thoracoscopy. Guided percutaneous needle biopsy has largely replaced closed needle biopsy, except in parts of the world where TB is prevalent. The culture yield of pleural biopsy is higher than that of pleural fluid. The recommended treatment of pleural and pulmonary TB is identical **(Chap. 183)**.

Effusion Secondary to Viral Infection Viral infections are probably responsible for a sizable percentage of undiagnosed exudative pleural effusions. In many series, no diagnosis is established for ~20% of exudative effusions, and these effusions usually resolve spontaneously with no long-term residua. The importance of these effusions is that one should not be too aggressive in trying to establish a diagnosis for the undiagnosed effusion if the patient is improving clinically.

Chylothorax A chylothorax occurs when the thoracic duct is disrupted and chyle accumulates in the pleural space. The most common cause of chylothorax is trauma (most frequently thoracic surgery), but it also may result from tumors in the mediastinum. Patients with chylothorax may present with dyspnea, and a large pleural effusion is often present on the chest radiograph. Thoracentesis usually reveals milky fluid, and biochemical analysis reveals a triglyceride level that exceeds 1.2 mmol/L (110 mg/dL). Patients with chylothorax and no obvious trauma should have a lymphangiogram and a chest CT scan to assess the mediastinum for lymphadenopathy. The treatment of choice for most chylothoraces is insertion of a chest tube plus the administration of octreotide and modification of diet to eliminate enteral fat intake. If these modalities fail, percutaneous transabdominal thoracic duct blockage effectively controls most chylothoraces. An alternative treatment is ligation of the thoracic duct. Patients with chylothoraces should not undergo prolonged tube thoracostomy with chest tube drainage because this can lead to malnutrition and immunologic incompetence.

Hemothorax When a diagnostic thoracentesis reveals bloody pleural fluid, a hematocrit should be obtained on the pleural fluid. If the hematocrit is more than one-half of that in the peripheral blood, the patient is considered to have a hemothorax. Most hemothoraces are the result of trauma; other causes include rupture of a blood vessel or tumor. Most patients with hemothorax should be treated with tube thoracostomy, which allows continuous quantification of bleeding. If the bleeding emanates from a laceration of the pleura, apposition of the two pleural surfaces is likely to stop the bleeding. If the pleural hemorrhage exceeds 200 mL/h, consideration should be given to angiographic coil embolization, thoracoscopy, or thoracotomy.

Miscellaneous Causes of Pleural Effusion There are many other causes of pleural effusion (Table 305-2). Key features of some of these conditions are as follows: If the pleural fluid amylase level is elevated, the diagnosis of esophageal rupture or pancreatic disease is likely. If the patient is febrile, has predominantly polymorphonuclear cells in the pleural fluid, and has no pulmonary parenchymal abnormalities, an intraabdominal abscess should be considered. The diagnosis of an asbestos pleural effusion is one of exclusion. Benign ovarian tumors can produce ascites and a pleural effusion (Meigs' syndrome), as can the ovarian hyperstimulation syndrome. Several drugs can cause pleural effusion; the associated fluid may be eosinophilic. Pleural effusions commonly occur after coronary artery bypass graft (CABG) surgery. Effusions occurring within the first weeks after CABG are typically left-sided and bloody, with large numbers of eosinophils, and respond to one or two therapeutic thoracenteses. Effusions occurring after the first few weeks of CABG are typically left-sided and clear yellow, with lymphocytic predominance, and tend to recur. Other medical manipulations that induce pleural effusions include abdominal surgery; radiation therapy; liver, lung, or heart transplantation; and complications of the intravascular insertion of central lines.

PNEUMOTHORAX

Pneumothorax is the presence of gas in the pleural space. A spontaneous pneumothorax is one that occurs without antecedent trauma to the thorax. A primary spontaneous pneumothorax occurs in the absence of underlying lung disease, whereas a secondary pneumothorax occurs in its presence. A traumatic pneumothorax results from penetrating or nonpenetrating chest injuries. A tension pneumothorax is a pneumothorax in which the pressure in the pleural space is positive throughout the respiratory cycle.

Primary Spontaneous Pneumothorax Primary spontaneous pneumothoraces are usually due to rupture of apical pleural blebs, small cystic spaces that lie within or immediately under the visceral pleura. Approximately one-half of patients with an initial primary spontaneous pneumothorax will have a recurrence. Conservative management with careful observation can be considered in adults who are asymptomatic or minimally symptomatic. Outpatient observational management is an option for low-risk patients with a good support system. Otherwise, the initial recommended treatment is needle aspiration or tube drainage. If the lung does not expand or if the patient has a recurrent pneumothorax, thoracoscopy with stapling of blebs and pleurodesis is usually indicated. Thoracoscopy or thoracotomy with surgical pleurodesis is almost 100% successful in preventing recurrences.

Secondary Pneumothorax Most secondary pneumothoraces are due to chronic obstructive pulmonary disease, but pneumothoraces have been reported with virtually every lung disease. Pneumothorax in patients with lung disease can be more life-threatening than it is in normal individuals because of the lack of pulmonary reserve in these