FIGURE 29-1 Delirium management and prevention: a checklist for hospitalized patients. Effective management of delirium relies on broad efforts to promote wakefulness (***A***) and sleep (***B***). CPO, continuous pulse oximetry.

In some instances, patients pose a threat to their own safety or to the safety of staff members, and acute management is required. Bed alarms and personal sitters are more effective and much less disorienting than physical restraints. Chemical restraints should be avoided, but when necessary, very-low-dose typical or atypical antipsychotic medications administered on an as-needed basis can be used, recognizing that multiple clinical trials have consistently shown that these medications are ineffective in preventing or treating delirium. Therefore, they should be reserved for patients who display severe agitation and significant potential to harm themselves or staff. The association of antipsychotic drug use in the elderly with increased mortality rates underscores the importance of using these medications judiciously and only as a last resort. Benzodiazepines often worsen confusion through their sedative properties. Although many clinicians use benzodiazepines to treat acute confusion, their use should be limited to cases in which delirium is caused by alcohol or benzodiazepine withdrawal.

PREVENTION

In light of the high morbidity associated with delirium and the tremendously increased health care costs that accompany it, development of an effective strategy to prevent delirium in hospitalized patients is extremely important. Successful identification of high-risk patients is the first step, followed by initiation of appropriate interventions. Increasingly, hospitals are using nursing or physician-administered tools to screen for high-risk individuals, triggering simple standardized protocols used to manage risk factors for delirium, including sleep-wake cycle reversal, immobility, visual impairment, hearing impairment, sleep deprivation, and dehydration. No specific medications have been definitively shown to be effective for delirium prevention, including trials of cholinesterase inhibitors and antipsychotic agents. Melatonin and its agonist ramelteon have shown some promising results in small preliminary trials. Recent studies in the ICU have focused both on identifying sedatives, such as dexmedetomidine, that are less likely to lead to delirium in critically ill patients and on developing protocols for daily awakenings in which infusions of sedative medications are interrupted and the patient is reorientated by the staff. All hospitals and health care systems should work toward decreasing the incidence of delirium and promptly recognizing and treating the disorder when it occurs.

FURTHER READING

Goldberg TE et al: Association of delirium with long-term cognitive decline: A meta-analysis. JAMA Neurol 77:1, 2020.

Kunicki ZJ et al: Six-year cognitive trajectory in older adults following major surgery and delirium. JAMA Int Med 183:442, 2023.

Livingston G et al: Dementia prevention, intervention, and care: 2020 report of the Lancet Commission. Lancet 396:413, 2020.

Ng KT et al: The effect of dexmedetomidine on delirium and agitation in patients in intensive care: Systematic review and meta-analysis with trial sequential analysis. Anesthesia 74:380, 2019.

Smit L et al: Efficacy of haloperidol to decrease the burden of delirium in adult critically ill patients: The EuRIDICE randomized clinical trial. Crit Care 27:413, 2023.

30 Coma

S. Andrew Josephson, Allan H. Ropper, Stephen L. Hauser

Coma is among the most common neurologic emergencies encountered in general medicine and requires an organized approach. It accounts for a substantial portion of emergency department visits and occurs on all services in the hospital.

There exists a continuum of states of reduced alertness, the most severe form being coma, defined as a deep sleeplike state with eyes closed, from which the patient cannot be aroused. Stupor refers to a lower threshold for arousability, in which the patient can be transiently awakened by vigorous stimuli, accompanied by motor behavior that leads to avoidance or withdrawal from noxious stimuli. Drowsiness simulates light sleep and is characterized by easy arousal that may persist for brief periods. Stupor and drowsiness are usually accompanied by some degree of confusion when the patient is alerted (Chap. 29). A precise narrative description of the level of arousal and of the type of responses evoked by various stimuli as observed at the bedside is preferable to use of more ambiguous terms such as lethargy, semicoma, or obtundation.

Several conditions that render patients unresponsive and simulate coma are considered separately because of their special significance. The *vegetative state* signifies an awake-appearing but nonresponsive

state, usually encountered in a patient who has emerged from coma. In the vegetative state, the eyelids typically open periodically, giving the appearance of wakefulness. Respiratory and autonomic functions are retained. Yawning, coughing, swallowing, and limb and head movements persist, but there are few, if any, meaningful responses to the external and internal environment. There are typically accompanying signs that indicate extensive damage in both cerebral hemispheres, e.g., decerebrate or decorticate limb posturing and absent responses to visual stimuli (see below). In the related but less severe *minimally conscious state*, the patient displays rudimentary vocal or motor behaviors, often spontaneous, but sometimes in response to touch, visual stimuli, or command. Cardiac arrest with cerebral hypoperfusion and head trauma are the most common causes of the vegetative and minimally conscious states **(Chap. 318)**.

The prognosis for regaining meaningful mental faculties once the vegetative state has supervened for several months is poor, and after a year, almost nil; hence the term *persistent vegetative state*. Most reports of dramatic recovery, when investigated carefully, are found to yield to the usual rules for prognosis, but there have been rare instances in which recovery has occurred to a severely disabled condition and, particularly in childhood cases, to an even better state. Patients in the minimally conscious state carry a better prognosis for some recovery compared to those in a persistent vegetative state, but even in these patients, dramatic recovery after 12 months is unusual.

The possibility of incorrectly attributing meaningful behavior to patients in the vegetative and minimally conscious states creates problems and anguish for families and physicians. The question of whether some of these patients have the capability for cognition has been investigated by functional MRI and electroencephalogram (EEG) studies that have demonstrated cerebral activation that is temporally consistent in response to verbal and other stimuli, as discussed in more detail below. This finding suggests at a minimum that some of these patients could in the future be able to communicate using technological advances and that further research could shed light on treatment approaches targeting areas of the brain and their connections that appear to be preserved in such individuals.

Several syndromes that affect alertness are prone to be misinterpreted as stupor or coma, and clinicians should be aware of these pitfalls when diagnosing coma at the bedside. Akinetic mutism refers to a partially or fully awake state in which the patient remains virtually immobile and mute but can form impressions and think, as demonstrated by later recounting of events. This condition results from damage in the regions of the medial thalamic nuclei or the frontal lobes (particularly lesions situated deeply or on the orbitofrontal surfaces) or from extreme hydrocephalus. The term *abulia* describes a milder form of akinetic mutism characterized by mental and physical slowness and diminished ability to initiate activity. It is also usually the result of damage to the medial frontal lobes and their connections **(Chap. 32)**.

Catatonia is a hypomobile and mute syndrome that occurs usually as part of a major psychiatric disorder, typically schizophrenia or major depression. Catatonic patients make few voluntary or responsive movements, although they blink, swallow, and may not appear distressed. There are nevertheless signs that the patient is responsive, although it takes a careful examination to demonstrate these features. For example, eyelid elevation is often actively resisted, blinking occurs in response to a visual threat, and the eyes move concomitantly with head rotation, all of which are inconsistent with the presence of a brain lesion causing unresponsiveness. The limbs may retain postures in which they have been placed by the examiner ("waxy flexibility," or catalepsy). There may be remarkable reversal, albeit sometimes brief, of the signs of catatonia when lorazepam is administered, validating the diagnosis. With appropriate medical therapy and recovery from catatonia, patients often have some memory of events that occurred during their stupor. Catatonia is superficially similar to akinetic mutism, but clinical evidence of cerebral damage such as hyperreflexia and hypertonicity of the limbs is lacking in the former.

The locked-in state describes a type of pseudocoma in which an awake but paralyzed patient has no means of producing speech or volitional limb movement but retains voluntary vertical eye movements and lid elevation, thus allowing the patient to communicate. The pupils are normally reactive. The usual cause is an infarction (e.g., basilar artery thrombosis) or hemorrhage of the ventral pons bilaterally that transects all descending motor (corticospinal and corticobulbar) pathways and those that control horizontal eye movements. Another awake but de-efferented state occurs as a result of total paralysis of the musculature in severe cases of neuromuscular weakness such as in forms of Guillain-Barré syndrome **(Chap. 458)**, critical illness neuropathy **(Chap. 318)**, or pharmacologic neuromuscular blockade.

THE ANATOMY AND PHYSIOLOGY OF COMA

Almost all instances of coma can be traced to either (1) widespread abnormalities of both cerebral hemispheres or (2) reduced activity of the thalamocortical alerting system, the reticular activating system (RAS), which is an assemblage of neurons located diffusely in the upper brainstem and thalamus. The proper functioning of this system, its ascending projections to the cortex, and the cortex itself are required to maintain alertness and coherence of thought. In addition to structural damage to either or both of these systems, suppression of reticulocerebral function commonly occurs by drugs, toxins, or metabolic derangements such as hypoglycemia, anoxia, uremia, and hepatic failure, or by seizures; these types of metabolic causes of coma are far more common than structural injuries.

Coma Due to Cerebral Mass Lesions and Herniation Syndromes The skull prevents outward expansion of the brain, and infoldings of the dura create compartments that restrict displacement of brain tissue within the cranium. The two cerebral hemispheres are separated by the falx and the anterior and posterior fossae by the tentorium. Herniation refers to displacement of brain tissue by an intracerebral or overlying mass into a contiguous compartment that it normally does not occupy. Coma from mass lesions, and many of its associated signs, are attributable to these tissue shifts, and certain clinical features are characteristic of specific configurations of herniation **(Fig. 30-1)**.

In the most common form of herniation, brain tissue is displaced from the supratentorial to the infratentorial compartment through the tentorial opening, referred to as transtentorial herniation. The cause is often a mass hemispheral lesion that is evident by contralateral hemiparesis and other cerebral signs. Uncal transtentorial herniation refers to impaction of the anterior medial temporal gyrus (the uncus) into the tentorial opening anterior to and adjacent to the midbrain **(Fig. 30-1*A*)**. The uncus can compress the third nerve as the nerve traverses the subarachnoid space, causing enlargement of the ipsilateral pupil as the first sign (the fibers subserving parasympathetic pupillary function are located peripherally in the nerve). The

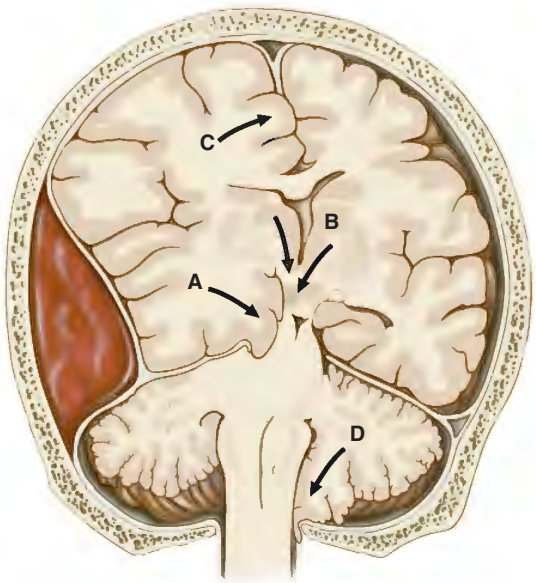

FIGURE 30-1 Types of cerebral herniation: (***A***) uncal; (***B***) central; (***C***) transfalcial; and (***D***) foraminal.

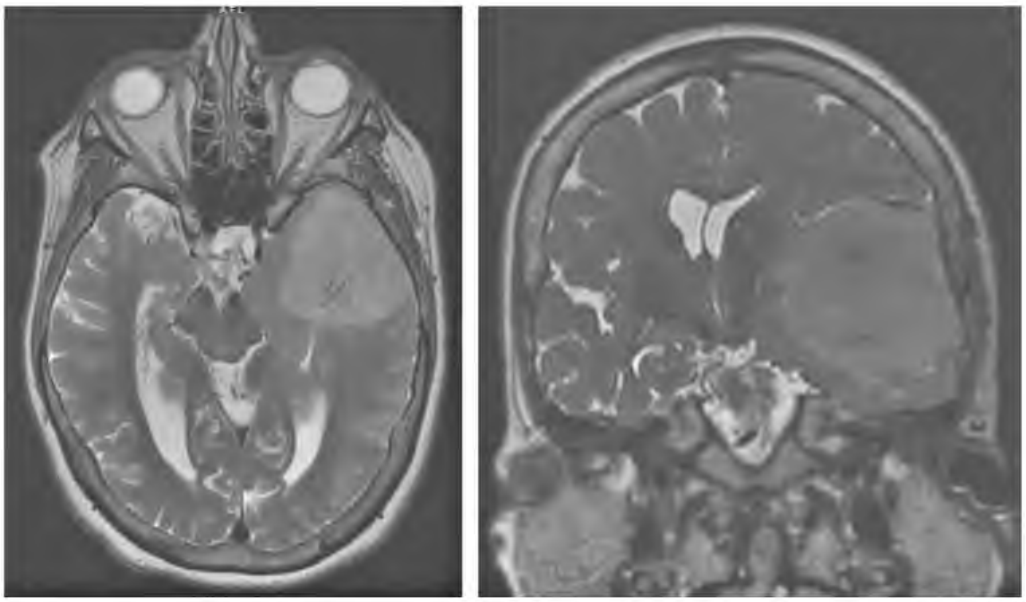

A B

FIGURE 30-2 Axial (A) and coronal (B) T2-weighted magnetic resonance images from a stuporous patient with a left third nerve palsy from a large left-sided meningioma. A. The upper midbrain is compressed and displaced horizontally away from the mass, and there is transtentorial herniation of the medial temporal lobe structures, including the uncus. **B.** The lateral ventricle opposite to the mass has become enlarged as a result of compression of the third ventricle.

coma that typically follows is due to vertical and lateral displacement of the midbrain (and therefore the RAS) against the opposite tentorial edge by the displaced parahippocampal gyrus (Fig. 30-2). An additional feature of lateral displacement can be compression of the opposite cerebral peduncle, producing a Babinski sign and hemiparesis ipsilateral to the supratentorial mass (the Kernohan-Woltman sign). Herniation may also compress the anterior and posterior cerebral arteries as they pass over the tentorial reflections, with resultant brain infarction. These distortions may also entrap portions of the ventricular system, causing hydrocephalus.

Central transtentorial herniation denotes a symmetric downward movement of the thalamic structures through the tentorial opening with compression of the upper midbrain (Fig. 30-1*B*). Miotic pupils and drowsiness are the heralding signs, in contrast to a unilaterally enlarged pupil of the uncal syndrome. Both uncal and central transtentorial herniations cause progressive compression of the brainstem and RAS, with initial damage to the rostral structures in midbrain, then the pons, and finally the most caudal medulla. The result is an approximate sequence of neurologic signs that corresponds to each affected level, with respiratory centers in the brainstem often spared until late in the herniation syndrome. This orderly sequential appearance of signs is not always respected, and rapid deterioration reflecting disruption of many brainstem functions can occur. Other forms of herniation include transfalcial herniation (displacement of the cingulate gyrus under the falx and across the midline, Fig. 30-1*C*) and foraminal herniation (downward forcing of the cerebellar tonsils into the foramen magnum, Fig. 30-1*D*), which causes early compression of the medulla and respiratory arrest.

Coma Due to Metabolic, Drug, and Toxic Disorders Many systemic metabolic abnormalities cause coma by interrupting the delivery of energy substrates (e.g., oxygen, glucose) or by altering neuronal excitability (drugs and alcohol, anesthetics, and epilepsy). These are the most common causes of coma in general practice and in large case series. The metabolic abnormalities that produce coma in milder forms may induce a confusional state (metabolic encephalopathy).

Cerebral neurons are dependent on cerebral blood flow (CBF) and the delivery of oxygen and glucose. Brain stores of glucose are able to provide energy for ~2 min after blood flow is interrupted, and oxygen stores last 8–10 s after the cessation of blood flow. Simultaneous hypoxia and ischemia exhaust glucose more rapidly. The EEG rhythm in these circumstances becomes diffusely slowed, typical of metabolic encephalopathies, and as substrate delivery worsens, eventually brain electrical activity ceases.

Unlike systemic hypoxia-ischemia, which first causes a metabolic encephalopathy due to reduced energy substrate but ultimately causes neuronal destruction, most metabolic disorders such as hypoglycemia, hyponatremia, hyperosmolarity, hypercapnia, hypercalcemia, and hepatic and renal failure cause no or only minor neuropathologic changes in the brain. The reversible effects of these conditions are not fully understood but may result from impaired energy supplies, changes in ion fluxes across neuronal membranes, and neurotransmitter abnormalities. In hepatic encephalopathy (HE), high ammonia concentrations have been proposed to lead to increased synthesis of glutamine in astrocytes and osmotic swelling of the cells, mitochondrial energy failure, production of reactive nitrogen and oxygen species, increases in the inhibitory neurotransmitter γ-aminobutyric acid (GABA), and synthesis of putative "false" neurotransmitters, none of which has provided a fully adequate explanation for confusion and stupor. Over time, development of a diffuse astrocytosis is typical of chronic HE. Which, if any, of these is mainly responsible for hepatic coma is not known.

The mechanism of the encephalopathy of renal failure is also uncertain and likely to be multifactorial; unlike ammonia, urea does not produce central nervous system (CNS) depression when infused into normal persons. Contributors to uremic encephalopathy may include accumulation of neurotoxic substances such as creatinine, guanidine, and related compounds; depletion of catecholamines; altered glutamate and GABA tone; increases in brain calcium; and inflammation with disruption of the blood-brain barrier.

Coma and seizures are common accompaniments of large shifts in sodium and water balance in the brain. These changes in osmolarity arise from systemic medical disorders, including diabetic ketoacidosis, the nonketotic hyperosmolar state, and hyponatremia from any cause (e.g., water intoxication, excessive secretion of antidiuretic hormone, or atrial natriuretic peptides). Sodium levels <125 mmol/L, especially if achieved quickly, induce confusion, and levels <119 mmol/L, when arrived at acutely, are typically associated with coma and convulsions. In hyperosmolar coma, the serum osmolarity is generally >350 mosmol/L. Hypercapnia depresses the level of consciousness in proportion to the rise in carbon dioxide (CO_2) in the blood. In all of these metabolic encephalopathies, the degree of neurologic change depends on the

rapidity with which the serum changes occur. The pathophysiology of other metabolic encephalopathies such as those due to hypercalcemia, hypothyroidism, vitamin B_{12} deficiency, and hypothermia are incompletely understood but must reflect derangements of synaptic function, cellular biochemistry, membrane function, or neurotransmitters.

Coma due to drugs and toxins is typically reversible and leaves no residual damage provided there has not been hypoxia or severe hypotension. Many drugs and toxins are capable of depressing nervous system function. Some produce coma by affecting both the RAS and the cerebral cortex. The combination of cortical and brainstem signs, which occurs occasionally in certain drug overdoses, may lead to an incorrect diagnosis of structural brainstem disease. Overdose of medications that have atropinic actions produces signs such as dilated pupils, tachycardia, and dry skin; opiate overdose produces pinpoint pupils <1 mm in diameter. Some drug intoxications, typified by barbiturates, can mimic all of the signs of brain death; thus, toxic etiologies must be excluded prior to making a diagnosis of brain death.

Epileptic Coma Generalized electrical seizures are associated with coma, even in the absence of motor convulsions (a condition termed "nonconvulsive status epilepticus"). As a result, EEG monitoring is often used in the evaluation of unexplained coma to exclude this potentially treatable etiology. The self-limited coma that follows a seizure, the postictal state, may be due to exhaustion of energy reserves or effects of locally toxic molecules that are the by-product of seizures. The postictal state produces continuous, generalized slowing of the background EEG activity similar to that of metabolic encephalopathies. It typically lasts for a few minutes but in some cases can be prolonged for hours or, even rarely, for days.

Coma Due to Widespread Structural Damage to the Cerebral Hemispheres This category, comprising several unrelated disorders, results from extensive bilateral structural cerebral damage. The clinical appearance simulates a metabolic encephalopathy. Hypoxia-ischemia is perhaps the best characterized form of this type of injury, in which it is not possible initially to distinguish the acute reversible effects of oxygen deprivation of the brain from the subsequent effects of neuronal damage. Similar cerebral damage may be produced by disorders that occlude widespread small blood vessels throughout the brain; examples include thrombotic thrombocytopenic purpura, hyperviscosity, and cerebral malaria. Diffuse white matter damage from cranial trauma, the delayed effects of some opioid intoxications, or inflammatory demyelinating diseases can cause a similar coma syndrome.

APPROACH TO THE PATIENT

Coma

Acute respiratory and cardiovascular problems should be attended to prior to neurologic assessment. In most instances, a complete medical evaluation, except for vital signs, fundoscopy, systemic trauma survey, and examination for nuchal rigidity, may be deferred until the neurologic evaluation has established the severity and nature of coma. **A video examination of the comatose patient is shown in Chap. V4. The approach to the patient with coma from cranial trauma is discussed in Chap. 454.**

HISTORY

The cause of coma may be immediately evident as in cases of trauma, cardiac arrest, or observed drug ingestion. In the remainder, certain points are useful: (1) the circumstances and rapidity with which neurologic symptoms developed; (2) antecedent symptoms (confusion, weakness, headache, fever, seizures, dizziness, double vision, or vomiting); (3) the use of medications, drugs, or alcohol; and (4) chronic liver, kidney, lung, heart, or other medical disease. Direct interrogation of family, observers, and emergency medical technicians on the scene, in person or by telephone, is an important part of the evaluation when possible.

GENERAL PHYSICAL EXAMINATION

Signs of head trauma raise the possibility of coexisting spinal cord injury, and in such cases, immobilization of the cervical spine is essential to prevent further injury. Fever suggests a systemic infection, bacterial meningitis, encephalitis, heat stroke, neuroleptic malignant syndrome, malignant hyperthermia due to anesthetics, or anticholinergic drug intoxication. Only rarely is fever attributable to a lesion that has disturbed hypothalamic temperature-regulating centers ("central fever"), and this diagnosis should only be considered after an exhaustive search for other causes fails to reveal an alternative explanation. A slight elevation in temperature may follow vigorous convulsions. Hypothermia is observed with exposure to cold ambient temperature, drowning, alcohol, barbiturate, sedative, or phenothiazine intoxication; hypoglycemia; peripheral circulatory failure; or extreme hypothyroidism. Hypothermia itself causes coma when the temperature is <31°C (87.8°F) regardless of the underlying etiology; less dramatically, low body temperatures can also cause coma in some instances. Tachypnea may indicate systemic acidosis or pneumonia. Aberrant respiratory patterns that reflect brainstem disorders are discussed below. Marked hypertension suggests hypertensive encephalopathy, cerebral hemorrhage, large cerebral infarction, or head injury. Hypotension is characteristic of coma from alcohol or barbiturate intoxication, internal hemorrhage or myocardial infarction causing poor delivery of blood to the brain, sepsis, profound hypothyroidism, or Addisonian crisis. The funduscopic examination can detect increased intracranial pressure (ICP) (papilledema), subarachnoid hemorrhage (subhyaloid hemorrhages), and hypertensive encephalopathy (exudates, hemorrhages, vessel-crossing changes, papilledema). Cutaneous petechiae suggest thrombotic thrombocytopenic purpura, meningococcemia, or a bleeding diathesis associated with an intracerebral hemorrhage. Cyanosis and reddish or anemic skin coloration are other indications of an underlying systemic disease or carbon monoxide as responsible for the coma.

NEUROLOGIC EXAMINATION

The patient is ideally first observed without intervention by the examiner. Spontaneously moving about the bed, reaching up toward the face, crossing legs, yawning, swallowing, coughing, and moaning reflect a drowsy state that is close to normal awakeness. Lack of restless movements on one side or an externally rotated leg suggests hemiplegia (or hip fracture). Subtle, intermittent twitching movements of a foot, finger, or facial muscle may be the only sign of seizures. Multifocal myoclonus usually indicates a metabolic disorder, particularly uremia, hypoxemia, drug intoxication, or rarely a prion disease **(Chap. 449)**. In a drowsy and confused patient, bilateral asterixis is a sign of metabolic encephalopathy or drug intoxication.

Decorticate rigidity and decerebrate rigidity, or "posturing," describe stereotyped arm and leg movements occurring spontaneously or elicited by sensory stimulation. Flexion of the elbows and wrists and supination of the arm (decorticate posturing) classically suggest bilateral damage rostral to the midbrain, whereas extension of the elbows and wrists with pronation (decerebrate posturing) indicates damage to motor tracts caudal to the midbrain. However, these localizations have been adapted from animal work and cannot be applied with precision to coma in humans. In fact, acute and widespread cerebral disorders of any type, regardless of location, frequently cause limb extension.

LEVEL OF AROUSAL

A sequence of increasingly intense stimuli is first used to determine the threshold for arousal and the motor response of each side of the body. The results of testing may vary from minute to minute, and serial examinations are useful. Tickling the nostrils with a cotton wisp is a moderate stimulus to arousal—all but deeply stuporous and comatose patients will move the head away and arouse to some degree. An even greater degree of responsiveness is present if the patient uses the hand to remove an offending stimulus. Pressure

on bony prominences and pinprick stimulation, when necessary, are humane forms of noxious stimuli; pinching the skin causes ecchymoses and is generally not performed but may be useful in eliciting abduction withdrawal movements of the limbs. Posturing in response to noxious stimuli indicates severe damage to the corticospinal system, whereas abduction-avoidance movement of a limb is usually purposeful and denotes an intact corticospinal system. Posturing may also be unilateral and coexist with purposeful limb movements, reflecting incomplete damage to the motor system.

BRAINSTEM REFLEXES

Assessment of brainstem function allows localization of the lesion in coma **(Fig. 30-3)**. Patients with preserved brainstem reflexes typically have a bihemispheric localization to coma, including toxic or drug intoxication, whereas patients with abnormal brainstem reflexes either have a lesion in the brainstem or a herniation syndrome from a cerebral mass lesion impacting the brainstem secondarily. The most important brainstem reflexes are pupillary size and reaction to light, spontaneous and elicited eye movements, corneal responses, and the respiratory pattern.

Pupillary Signs Pupillary reactions are examined with a bright, diffuse light. Reactive and round pupils of midsize (2.5–5 mm) essentially exclude upper midbrain damage, either primary or secondary to compression from herniation. A response to light may be difficult to appreciate in pupils <2 mm in diameter, and bright room lighting may mute pupillary reactivity. One enlarged (>6 mm) and poorly reactive pupil signifies compression of the third nerve from the effects of a cerebral mass above. Enlargement of the pupil contralateral to a hemispheral mass may occur but is infrequent. An oval and slightly eccentric pupil is a transitional sign that accompanies early midbrain–third nerve compression. The most extreme pupillary sign, bilaterally dilated and unreactive pupils, indicates severe midbrain damage, usually from compression by a supratentorial mass. Ingestion of drugs with anticholinergic activity, the use of mydriatic eye drops, nebulizer treatments that inadvertently spray into the eye, and direct ocular trauma are other causes of pupillary enlargement.

Reactive and bilaterally small (1–2.5 mm) but not pinpoint pupils are seen in metabolic encephalopathies or in deep bilateral hemispheral lesions such as hydrocephalus or thalamic hemorrhage. Even smaller reactive pupils (<1 mm) characterize opioid overdoses but also occur with extensive pontine hemorrhage. The response to naloxone and the presence of reflex eye movements (see below) assist in distinguishing between these. Unilateral miosis in coma has been attributed to dysfunction of sympathetic efferents originating in the posterior hypothalamus and descending in the tegmentum of the brainstem to the cervical cord. It is an occasional finding in patients with a large cerebral hemorrhage that affects the thalamus.

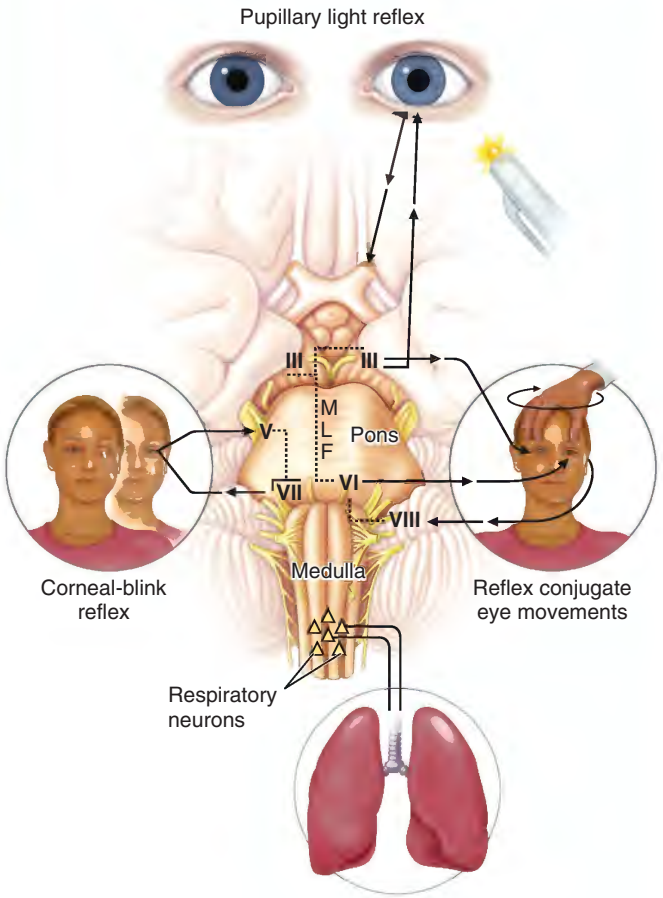

FIGURE 30-3 Examination of brainstem reflexes in coma. Midbrain and third nerve function are tested by pupillary reaction to light, pontine function by spontaneous and reflex eye movements and corneal responses, and medullary function by respiratory and pharyngeal responses. Reflex conjugate, horizontal eye movements are dependent on the medial longitudinal fasciculus (MLF) interconnecting the sixth and contralateral third nerve nuclei. Head rotation (oculocephalic reflex) or caloric stimulation of the labyrinths (oculovestibular reflex) elicits contraversive eye movements (for details, see text).

Ocular Movements The eyes are first observed by elevating the lids and observing the resting position and spontaneous movements of the globes. Horizontal divergence of the eyes at rest is normal in drowsiness. As coma deepens, the ocular axes may become parallel again.

Spontaneous eye movements in coma often take the form of conjugate horizontal roving. This finding alone exonerates extensive damage in the midbrain and pons and has the same significance as normal reflex eye movements (see below). Conjugate horizontal ocular deviation to one side indicates damage to the frontal lobe on the same side or less commonly the pons on the opposite side. This phenomenon is summarized by the following maxim: *The eyes look toward a hemispheral lesion and away from a brainstem lesion*. Seizures involving the frontal lobe drive the eyes to the opposite side, simulating a pontine destructive lesion. The eyes may occasionally turn paradoxically away from the side of a deep hemispheral or thalamic lesion ("wrong-way eyes"). The eyes more often turn down and inward with thalamic and upper midbrain lesions, typically thalamic hemorrhage. "Ocular bobbing" describes brisk downward and slow upward movements of the eyes associated with loss of horizontal eye movements and is diagnostic of bilateral pontine damage, usually from thrombosis of the basilar artery. "Ocular dipping" is a slower, arrhythmic downward movement followed by a faster upward movement in patients with normal reflex horizontal gaze; it usually indicates diffuse cortical anoxic damage.

The oculocephalic reflex, elicited after establishing there is no cervical spinal cord injury, is examined by moving the head from side to side or vertically and observing eye movements in the direction opposite to the head movement. The reflex depends on the integrity of the ocular motor nuclei and their interconnecting tracts that extend from the midbrain to the pons and medulla (Fig. 30-3). The movements, called somewhat inaccurately "doll's eyes," are normally suppressed in the awake patient with intact frontal lobes. The ability to elicit an oculocephalic reflex therefore reflects both reduced cortical influence on the brainstem and intact brainstem pathways. The opposite, an absence of reflex eye movements, usually signifies damage within the brainstem but can result from overdoses of certain drugs. In this circumstance, normal pupillary size and light reaction distinguishes most drug-induced comas from structural brainstem damage.

Thermal, or "caloric," stimulation of the vestibular apparatus (oculovestibular response) provides a more intense stimulus for the oculocephalic reflex but provides essentially the same information. The test is performed by irrigating the external auditory canal with

cold water in order to induce convection currents in the labyrinths. After a brief latency, the result is tonic deviation of both eyes to the side of cold-water irrigation. In comatose patients, nystagmus in the opposite direction may not occur. The acronym "COWS" has been used to remind generations of medical students of the direction of nystagmus—cold water opposite, warm water same—but since nystagmus is often absent in the opposite direction due to frontal lobe dysfunction in coma, this mnemonic does not often hold true in this situation.

The corneal reflex, elicited by touching the cornea with a wisp of cotton and observing bilateral lid closure, depends on the integrity of pontine pathways between the fifth (afferent) and both seventh (efferent) cranial nerves; it is a useful test of pontine function. CNS-depressant drugs diminish or eliminate the corneal responses soon after reflex eye movements are paralyzed but before the pupils become unreactive to light. The corneal response may be lost for a time on the side of an acute hemiplegia.

Respiratory Patterns These are of less localizing value in comparison to other brainstem signs. Shallow, slow, but regular breathing suggests metabolic or drug-induced depression of the medullary respiratory centers. Cheyne-Stokes respiration in its typical cyclic form, ending with a brief apneic period, signifies bihemispheral damage or metabolic suppression and commonly accompanies light coma. Rapid, deep (Kussmaul) breathing usually implies metabolic acidosis but may also occur with pontomesencephalic lesions. Agonal gasps are the result of lower brainstem (medullary) damage and are recognized as the terminal respiratory pattern of severe brain damage. Other cyclic breathing patterns have been described but are of lesser significance.

LABORATORY STUDIES AND IMAGING

The studies that are most useful in the diagnosis of coma are chemical-toxicologic analyses of blood and urine, cranial CT or MRI, EEG, and cerebrospinal fluid (CSF) examination. Arterial blood gas analysis is helpful in patients with lung disease and acid-base disorders. The metabolic aberrations commonly encountered in clinical practice are usually revealed by measurement of electrolytes, glucose, calcium, magnesium, osmolarity, and renal (blood urea nitrogen) and hepatic (including NH_3) function. Toxicologic analysis may be necessary in cases of acute coma when the diagnosis is not immediately clear. However, the presence of exogenous drugs or toxins, especially alcohol, does not exclude the possibility that other factors, including head trauma, are contributing to the clinical state. An ethanol level of 43 mmol/L (0.2 g/dL) in nonhabituated patients generally causes impaired mental activity; a level of >65 mmol/L (0.3 g/dL) is associated with stupor. The development of tolerance may allow some individuals who chronically ingest alcohol to remain awake at levels >87 mmol/L (0.4 g/dL).

The availability of cranial CT and MRI has focused attention on causes of coma that are detectable by imaging (e.g., hemorrhage, tumor, or hydrocephalus). Resorting primarily to this approach, although at times expedient, is imprudent because most cases of coma (and confusion) are metabolic or toxic in origin. Furthermore, a normal CT scan does not exclude an anatomic lesion as the cause of coma; for example, early bilateral hemisphere infarction, acute brainstem infarction, encephalitis, meningitis, mechanical shearing of axons as a result of closed head trauma, sagittal sinus thrombosis, hypoxic injury, and subdural hematoma isodense to adjacent brain are some of the disorders that may not be detected. Sometimes imaging results can be misleading such as when small subdural hematomas or old strokes are found, but the patient's coma is due to intoxication. Additional imaging with CT angiography or MRI can be obtained if acute posterior circulation stroke is considered.

The EEG **(Chap. 436)** provides clues in metabolic or drug-induced states but is rarely diagnostic in these disorders. However, it is the essential test to reveal coma due to nonconvulsive seizures and shows fairly characteristic patterns in some conditions including herpesvirus encephalitis and prion disease. The EEG may be further helpful in disclosing generalized slowing of the background activity, a reflection of the severity of an encephalopathy. Predominant high-voltage slowing (δ or triphasic waves) in the frontal regions is typical of metabolic coma, as from hepatic failure, and widespread fast (β) activity implicates overdose with sedative drugs (e.g., benzodiazepines). A special pattern of "alpha coma," defined by widespread, variable, 8- to 12-Hz activity, superficially resembles the normal α rhythm of waking but, unlike normal α activity, is not altered by environmental stimuli. Alpha coma results from pontine or diffuse cortical damage and is associated with a poor prognosis. A unique EEG pattern in adults of "extreme delta brush" is characteristic of the anti–*N*-methyl-D-aspartate (NMDA) receptor form of autoimmune encephalitis. Normal α activity on the EEG, which is suppressed by stimulating the patient, also alerts the clinician to the locked-in syndrome, functional disorder, or catatonia.

Lumbar puncture should be performed if no cause is readily apparent, as examination of the CSF remains indispensable in the diagnosis of various forms of meningitis and encephalitis. An imaging study is generally performed prior to lumbar puncture to exclude a large intracranial mass lesion, which could lead to herniation with lumbar puncture. Blood cultures and administration of antimicrobials should precede the imaging study if infectious meningitis is suspected **(Chap. 143)**.

DIFFERENTIAL DIAGNOSIS OF COMA

(Table 30-1) The causes of coma can be divided into three broad categories: those without focal neurologic signs (e.g., metabolic and toxic encephalopathies); those with prominent focal signs (e.g., stroke, cerebral hemorrhage); and meningitis syndromes, characterized by fever or stiff neck and an excess of cells in the spinal fluid (e.g., bacterial meningitis, subarachnoid hemorrhage, infectious or

TABLE 30-1 Differential Diagnosis of Coma

1. Diseases that cause no focal brainstem or lateralizing neurologic signs (CT scan is often normal)
   a. Intoxications: alcohol, sedative drugs, opiates, etc.
   b. Metabolic disturbances: anoxia, hyponatremia, hypernatremia, hypercalcemia, diabetic acidosis, nonketotic hyperosmolar hyperglycemia, hypoglycemia, uremia, hepatic coma, hypercarbia, Addisonian crisis, hypo- and hyperthyroid states, profound nutritional deficiency
   c. Severe systemic infections: pneumonia, septicemia, typhoid fever, malaria, Waterhouse-Friderichsen syndrome
   d. Shock from any cause
   e. Status epilepticus, nonconvulsive status epilepticus, postictal states
   f. Hyperperfusion syndromes including hypertensive encephalopathy, eclampsia, posterior reversible encephalopathy syndrome (PRES)
   g. Severe hyperthermia, hypothermia
   h. Concussion
   i. Acute hydrocephalus
2. Diseases that cause focal brainstem or lateralizing cerebral signs (CT scan is typically abnormal)
   a. Hemispheral hemorrhage (basal ganglionic, thalamic) or infarction (large middle cerebral artery territory) with secondary brainstem compression
   b. Brainstem infarction due to basilar artery thrombosis or embolism
   c. Brain abscess, subdural empyema
   d. Epidural and subdural hemorrhage, brain contusion
   e. Brain tumor with surrounding edema
   f. Cerebellar and pontine hemorrhage and infarction
   g. Widespread traumatic brain injury
   h. Metabolic coma (see above) in the setting of preexisting focal damage
3. Diseases that cause meningeal irritation with or without fever, and with an excess of white blood cells or red blood cells in the CSF
   a. Subarachnoid hemorrhage from ruptured aneurysm, arteriovenous malformation, trauma
   b. Infectious meningitis and meningoencephalitis
   c. Paraneoplastic and autoimmune encephalitis
   d. Carcinomatous and lymphomatous meningitis

autoimmune/paraneoplastic encephalitis). Causes of sudden coma include drug ingestion, cerebral hemorrhage, trauma, cardiac arrest, epilepsy, and basilar artery occlusion. Coma that appears subacutely is usually related to a preexisting medical or neurologic problem or, less often, to secondary brain swelling surrounding a mass such as tumor or cerebral infarction.

The diagnosis of coma due to cerebrovascular disease can be difficult but is generally disclosed by cerebral imaging **(Chap. 437)**. The most common diseases in this category are (1) basal ganglia and thalamic hemorrhage (acute but not instantaneous onset, vomiting, headache, hemiplegia, and characteristic eye signs); (2) pontine hemorrhage (sudden onset, pinpoint pupils, loss of reflex eye movements and corneal responses, ocular bobbing, posturing, and hyperventilation); (3) cerebellar hemorrhage (occipital headache, vomiting, gaze paresis, and inability to stand and walk); (4) basilar artery thrombosis (neurologic prodrome or transient ischemic attack warning spells, diplopia, dysarthria, vomiting, eye movement and corneal response abnormalities, and asymmetric limb paresis); and (5) subarachnoid hemorrhage (precipitous coma after sudden severe headache and vomiting). The most common large-vessel stroke, unilateral infarction in the territory of the middle cerebral artery, does not cause coma, but edema surrounding large infarctions may expand over several days and cause coma from mass effect.

The syndrome of acute hydrocephalus accompanies many intracranial diseases, particularly subarachnoid hemorrhage. It is characterized by headache and sometimes vomiting that may progress quickly to coma with extensor posturing of the limbs, bilateral Babinski signs, small unreactive pupils, and impaired oculocephalic movements in the vertical direction. At times, the coma may be featureless without lateralizing signs, although papilledema is often present.

BRAIN DEATH

Brain death is a state of irreversible cessation of all cerebral and brainstem function with preservation of cardiac activity and maintenance of respiratory and somatic function by artificial means. It is the only type of brain damage recognized as morally, ethically, and legally equivalent to death. Criteria have been advanced for the diagnosis of brain death, and it is essential to adhere to consensus standards as multiple studies have shown variability in local practice. Given the implications of the diagnosis, clinicians must be thorough and precise in determining brain death. It is advisable to delay clinical testing for at least 24 h if a cardiac arrest has caused brain death or if the inciting disease is not known. Some centers advocate a brief period of observation between two examiners' tests during which the clinical signs of brain death are sustained.

Established criteria contain two essential elements, after assuring that no confounding factors (e.g., hypothermia, drug intoxication) are present: (1) widespread cortical destruction that is reflected by deep coma and unresponsiveness to all forms of stimulation; and (2) global brainstem damage as demonstrated by absent pupillary light reaction, absent corneal reflexes, loss of oculovestibular reflexes, and destruction of the medulla, manifested by complete and irreversible apnea. Diabetes insipidus is often present but may only develop hours or days after the other clinical signs of brain death appear and is not used as a criterion. The pupils are usually midsized but may be enlarged. Loss of deep tendon reflexes is not required because the spinal cord remains functional. Occasionally, other reflexes that originate from the spine may be present and should not preclude a diagnosis of brain death.

Demonstration that apnea is due to medullary damage requires that the P_{CO_2} be high enough to stimulate respiration during a test of spontaneous breathing. Apnea testing can be done by the use of preoxygenation with 100% oxygen prior to and following removal of the ventilator. CO_2 tension increases ~0.3–0.4 kPa/min (2–3 mmHg/min) during apnea. Apnea is confirmed if no respiratory effort has been observed in the presence of a sufficiently elevated P_{CO_2}. The apnea test is usually stopped if there is cardiovascular instability and alternative means of testing can be employed.

An isoelectric EEG may be used as an optional confirmatory test for total cerebral damage. Radionuclide brain scanning, cerebral angiography, or transcranial Doppler measurements may be used to demonstrate the absence of blood flow when a confirmatory study is desired.

It is largely accepted in Western society that the ventilator can be disconnected from a brain-dead patient and that organ donation is subsequently possible. Good communication between the physician and the family is important with appropriate preparation of the family for brain death testing and diagnosis.

TREATMENT

Coma

The immediate goal in a comatose patient is prevention of further nervous system damage. Hypotension, hypoglycemia, hypercalcemia, hypoxia, hypercapnia, and hyperthermia should be corrected rapidly. Hyponatremia should be corrected slowly to avoid injury from osmotic demyelination **(Chap. 318)**. An oropharyngeal airway is adequate to keep the pharynx open in a drowsy patient who is breathing normally. Tracheal intubation is indicated if there is apnea, upper airway obstruction, hypoventilation, or emesis, or if the patient is at risk for aspiration. Mechanical ventilation is required if there is hypoventilation or a need to induce hypocapnia in order to lower ICP. The management of raised ICP is discussed in **Chap. 318**. IV access is established and naloxone and dextrose are administered if opioid overdose or hypoglycemia are possibilities; thiamine is given along with glucose to avoid provoking Wernicke's encephalopathy in malnourished patients. In cases of suspected ischemic stroke including basilar thrombosis with brainstem ischemia, IV tissue plasminogen activator or mechanical embolectomy is often used after cerebral hemorrhage has been excluded and when the patient presents within established time windows for these interventions **(Chap. 438)**. Physostigmine may awaken patients with anticholinergic-type drug overdose but should be used only with careful monitoring; many physicians believe that it should only be used to treat anticholinergic overdose–associated cardiac arrhythmias. The use of benzodiazepine antagonists offers some prospect of improvement after overdose; however, these drugs are not commonly used empirically in part due to their tendency to provoke seizures. Certain other toxic and drug-induced comas have specific treatments such as fomepizole for ethylene glycol ingestion.

Administration of hypotonic IV solutions should be monitored carefully in any serious acute brain illness because of the potential for exacerbating brain swelling. Cervical spine injuries must not be overlooked, particularly before attempting intubation or evaluation of oculocephalic responses. Fever and meningismus indicate an urgent need for examination of the CSF to diagnose meningitis. Whenever acute bacterial meningitis is suspected, antibiotics including at least vancomycin and a third-generation cephalosporin are typically administered rapidly along with dexamethasone **(see Chap. 143)**.

PROGNOSIS

Some patients, especially children and young adults, may have ominous early clinical findings such as abnormal brainstem reflexes and yet recover; early prognostication outside of brain death therefore is unwise. Metabolic comas have a far better prognosis than traumatic or ischemic ones. Systems for estimating prognosis in adults should be taken as approximations, and medical judgments must be tempered by factors such as age, underlying systemic disease, and general medical condition. In an attempt to collect prognostic information from large numbers of patients with head injury, the Glasgow Coma Scale was devised; it has predictive value in cases of brain trauma **(Chap. 454)**, but not in most other causes of coma. For anoxic coma, clinical signs such as the pupillary and motor responses after 1 day, 3 days, and 1 week have predictive value; however, in the setting of therapeutic hypothermia, these prediction rules are less reliable,

and therefore, serial examinations and multimodal prognostication approaches are advised. For example, the absence of the cortical responses of the somatosensory evoked potentials has been shown to be a strong indicator of poor outcome following hypoxic injury, as has high elevations of serum neuron-specific enolase drawn at established intervals after anoxia.

The poor outcome of persistent vegetative and minimally conscious states has already been mentioned, but reports of a small number of patients displaying cortical activation on functional MRI in response to salient stimuli have begun to alter the perception of such individuals. In one series, about 10% of vegetative patients (mainly following traumatic brain injury) could activate their frontal or temporal lobes in response to requests by an examiner to imagine certain visuospatial tasks. Another series demonstrated that up to 15% of patients with various forms of acute brain injury and absence of behavioral responses to motor commands showed EEG activation in response to these commands. It is prudent to avoid generalizations from these findings, but the need for future studies of novel techniques to help communication and possibly recovery is needed.

FURTHER READING

Claasen J et al: Detection of brain activation in unresponsive patients with acute brain injury. N Engl J Med 380:2497, 2019.

Edlow JA et al: Recovery from disorders of consciousness: Mechanisms, prognosis and emerging therapies. Nat Rev Neurol 17:135, 2021.

Greer DM et al: Pediatric and adult brain death/death by neurologic criteria consensus guideline: Report of the AAN guidelines subcommittee, AAP, CNS, and SCCM. Neurology 101:1112, 2023.

Posner JB et al: *Plum and Posner's Diagnosis of Stupor and Coma*, 5th ed. New York, Oxford University Press, 2019.

Wijdicks EFM: Predicting the outcome of a comatose patient at the bedside. Pract Neurol 20:26, 2020.

31 Dementia

Gil D. Rabinovici, William W. Seeley, Bruce L. Miller

Dementia, a syndrome with many causes, affects over 6 million people in the United States and results in a total annual health care cost in excess of $300 billion. Dementia is defined as an acquired deterioration in cognitive abilities that impairs the successful performance of activities of daily living. Episodic memory, the ability to recall events specific in time and place, is the cognitive function most commonly lost; 10% of persons age >70 years and 20–40% of individuals age >85 years have clinically identifiable memory loss. In addition to memory, dementia may erode other mental faculties, including language, visuospatial, praxis, calculation, judgment, and problem-solving abilities. Neuropsychiatric and social deficits also arise in many dementia syndromes, manifesting as depression, apathy, anxiety, hallucinations, delusions, agitation, insomnia, sleep disturbances, compulsions, or disinhibition. The clinical course may be slowly progressive, as in *Alzheimer's disease (AD)*; static, as in anoxic encephalopathy; or may fluctuate from day to day or minute to minute, as in *dementia with Lewy bodies (DLB)*. Most patients with AD, the most prevalent form of dementia, begin with episodic memory impairment, but in other dementias, such as *frontotemporal dementia (FTD)*, memory loss is not typically a presenting feature. When dementia is caused by a progressive neurodegenerative disease, it is preceded by a prodromal clinical stage called *mild cognitive impairment (MCI)*, in which individuals experience cognitive decline but remain independent in most daily activities. Increasingly, a *preclinical* stage is recognized for AD and other dementing illnesses, in which brain pathology is present but clinical symptoms are not yet manifest. **Focal cerebral disorders are discussed in Chap. 32 and illustrated in a video library in Chap. V2; detailed discussions of AD can be found in Chap. 442; FTD and related disorders in Chap. 443; vascular dementia in Chap. 444; DLB in Chap. 445; Huntington's disease (HD) in Chap. 447; and prion diseases in Chap. 449.**

FUNCTIONAL ANATOMY OF THE DEMENTIAS

Dementia syndromes result from the disruption of specific large-scale neuronal networks by initially focal brain lesions, including neurodegenerative changes and vascular injury. Ultimately, the location and severity of synaptic and neuronal loss combine to produce the clinical features **(Chap. 32)**. Behavior, mood, and attention are also modulated by ascending noradrenergic, serotonergic, and dopaminergic pathways, whereas cholinergic signaling is critical for attention and memory functions. The dementias differ in the underlying molecular pathology and relative neurotransmitter deficit profiles; accordingly, accurate diagnosis guides effective therapy.

AD typically begins in the entorhinal region of the medial temporal lobe, spreads to the hippocampus and other limbic structures, moves through the basal temporal areas, and then into lateral and posterior temporal and parietal neocortex, eventually causing a more widespread degeneration. Vascular dementia is associated with focal damage in a variable patchwork of cortical and subcortical regions or white matter tracts that disconnects nodes within distributed networks. In keeping with its anatomy, AD typically presents with episodic memory loss accompanied later by aphasia, executive dysfunction, or navigational problems. In contrast, dementias that begin in frontal or subcortical regions, such as FTD or HD, are less likely to begin with memory problems and more likely to present with difficulties with judgment, mood, executive control, movement, and behavior.

Lesions of frontal-striatal[1] pathways produce specific and predictable effects on behavior. The dorsolateral prefrontal cortex has connections with a central band of the caudate nucleus. Lesions of either the caudate or dorsolateral prefrontal cortex, or their connecting white matter pathways, may result in executive dysfunction, manifesting as poor organization and planning, decreased cognitive flexibility, and impaired working memory. The lateral orbital frontal cortex connects with the ventromedial caudate, and lesions of this system cause impulsiveness, distractibility, and disinhibition. The anterior cingulate cortex and adjacent medial prefrontal cortex project to the nucleus accumbens, and interruption of this system produces apathy, poverty of speech, emotional blunting, or even akinetic mutism. All corticostriatal systems also include topographically organized projections through the globus pallidus and thalamus, and damage to these nodes can likewise reproduce the clinical syndrome associated with the corresponding cortical or striatal injuries. Lesions in nodes of the dominant hemisphere speech and language networks can present as a primary progressive aphasia, with deficits in naming, word retrieval, motor speech, grammar, and comprehension of single words or more complex phrases **(Chap. 443)**. Involvement of brainstem nuclei and cerebellar structures can further contribute to cognitive, behavioral, motor and autonomic manifestations.

THE CAUSES OF DEMENTIA

The single strongest risk factor for dementia is increasing age. The prevalence of disabling memory loss increases with each decade over age 50 and is usually associated with the microscopic changes of AD at autopsy. Yet some centenarians have intact memory function and no evidence of clinically significant dementia. Whether dementia is an inevitable consequence of normal human aging remains controversial, although the prevalence increases with every decade of life.

The many causes of dementia are listed in **Table 31-1**. The frequency of each condition depends on the age group under study, access of the

[1]The striatum comprises the caudate/putamen.