319 Approach to the Patient with Renal Disease or Urinary Tract Disease

Julian L. Seifter

The upper urinary tract consists of the kidneys, their vasculature, the renal parenchyma, and its collecting system. The lower urinary tract is composed of the peristaltic ureters from each kidney; the bladder, which receives and stores urine from each ureter; and the urethra, which, upon bladder contraction, excretes the final urine. The excretory system begins with a plasma ultrafiltrate from renal cortical glomeruli, modified by the renal tubules of the nephron, and ends with the excretion of urinary water and solutes.

Disease at any level of these functional structures may be asymptomatic at patient presentation or may cause nonspecific complaints such as fatigue. There may be signs that are highly specific for a site of dysfunction (such as proteinuria or polyuria), or referable to a structure (but not diagnostic of a particular disease), or highly characteristic of a specific diagnosis (such as polycystic kidney disease). Patients with a disorder of the kidney may present without symptoms but with signs of urinary tract disease (such as painless microhematuria or an incidental mass noted on an abdominal imaging study).

It is especially important to perform renal testing in patients with systemic disease; for example, routine screening for microalbuminuria and an estimated glomerular filtration rate (eGFR) in diabetes mellitus (DM). One should look at renal function when a patient's history includes known risk for renal or urinary tract complications, for example, lithium for psychiatric treatment, occupational use of lead, or, in the case of bladder cancer, exposure to aniline dyes. This chapter will address an approach to patients with and without known history of kidney disease, as well as those who have one of a wide variety of systemic illnesses that involve the kidney or the lower urinary tract.

To begin with the evaluation of renal disorders, note that it is time-consuming and wasteful to do random testing prematurely, which would generate a very long list of potential diagnoses. A better approach is to review the evidence from the history, physical examination, and basic laboratory studies to arrive at a logical basis for targeted tests that would identify a particular disease process (Table 319-1). The findings are influenced by the regions of the kidney that are involved and by factors such as family history, toxic exposures, the patient's birth weight for gestational age, and time course of any findings. As a rule, kidney diseases that begin primarily with glomerular dysfunction have albuminuria as the hallmark, whereas kidney diseases that begin in the tubular structures may present primarily with electrolyte disorders or disorders of dilution and concentration of the urine. In both glomerular and tubular disorders, upon progressing to chronic disease, the distinction is more difficult because glomerular diseases eventually affect the tubular interstitium and tubular diseases progress to glomerular dysfunction and scarring.

The complement cascade (a name suggestive of the torrents of a waterfall) has been implicated in a number of diseases via successive steps of activation and amplification of proinflammatory complement proteins. The complement cascade has three pathways, the classical, the alternative, and the lectin-binding, each of which can cause disease if the pathway is dysregulated. In the alternative pathway, the activating signal for producing complement to augment (i.e., complement) the inflammatory response is the presence of circulating antigen-antibody immune complexes. The sites of inflammation are tissue deposits of these complexes. Though immune complex deposition is not specific to the kidney, as a pathologic finding, its presence has great diagnostic and mechanistic value for many forms of systemic and nonsystemic renal disease, encompassing glomerular, tubular, and vascular structures. In the process of stepwise activation of complement, components are released into the circulation primarily from hepatocytes.

Complement component C3 is an important protein in the classical, alternative, and lectin pathways. In the presence of C3 convertase, C3 yields C3a and C3b, the latter of which has further proinflammatory effects: an amplification loop for C3, production of C4 and C5, activation of antibody production, formation of the membrane attack complex (C5b-9), and augmentation of immune complex clearance. In the alternative complement cascade, the heightened proinflammatory response, as seen in a positive feedback loop, circumvents proinflammatory excess by several inhibitory effects of hereditary factors D, H and I. An unsuppressed proinflammatory cycle could lead to life-threatening endothelial damage, which underlies the damage caused by interaction with the coagulation cascade causing thrombotic microangiopathies (TMAs), including thrombotic thrombocytopenic purpura (TTP). The latter is deficient in AdamTS13, an enzyme that inhibits shortening of Von Willebrand factor (VWF), polymer that in its normal length attracts platelets and thus prevents clotting. Failure to find a low level of AdamTS13 in the blood introduces the possibility of atypical HUS. These disease

TABLE 319-1 Acute Kidney Injury

FEATURES	PRERENAL	RENAL	POSTRENAL
Context	Heart failure, hepatic failure, burns, shock, post-op, dehydration, renovascular disease, vascular, drugs	ATN, bilateral cortical necrosis, AIN, crush injuries, myoglobulinuria, hemoglobinuria, ischemia, sepsis, recent contrast drugs	Bladder outlet obstruction, obstruction of solitary kidney, abdominal mass, bilateral stones, drugs
Urine output	Oliguria (usually <500 mL/d) Anuria	Oliguria Normal Polyuria	Anuria Polyuria Both
Clinical history and exam	Trauma, shock, hypotension, burns, GI, sweat, or renal losses	Rhabdomyolysis, hemolysis, thrombotic microangiopathy, AIN, atheroemboli	Extrinsic ureteral obstruction retroperitoneal disease, bladder outlet or urethral obstruction by prostate or cervical cancer
Urinalysis	Concentrated acid urine, hyaline casts, crystalluria	"Muddy brown" granular casts, hematuria, dysmorphic RBCs, RBC casts in GN, WBC casts in AIN, eosinophils in atheroemboli	Intrarenal obstruction by uric acid or CaPhos in tumor lysis syndrome, blood clots in lower urinary tract bleeding, CaOx after ethylene glycol ingestion
Urine chemistry	Low FENa ≤1%, U/P Cr ≥40, UNa ≤10, U/P Osm ≥1	FENa 1–3%, U/P Cr ≤40, UOsm ~isosmotic	Early looks like prerenal, late looks like renal
Laboratory studies	High BUN/Cr ratio, usually hypercatabolic with increased uric acid; may have hyper- or hyponatremia	May have eosinophilia in allergic AIN, high phosphate, low Ca, high PTH, metabolic acidosis	Hydronephrosis on ultrasound, extrinsic or intrinsic diseases on CT scan, tumors on MRI

Abbreviations: AIN, acute interstitial nephritis; ATN, acute tubular necrosis; BUN, blood urea nitrogen; Ca, calcium; CaPhos, calcium phosphate; Cr, creatinine; CT, computed tomography; FENa, fractional excretion of sodium, GI, gastrointestinal; GN, glomerulonephritis; MRI, magnetic resonance imaging; PTH, parathyroid hormone; RBC, red blood cell; U/P, urine/plasma; WBC, white blood cell.

syndromes consist of the triad of microangiopathic hemolytic anemia (with schistocytes, high serum lactate dehydrogenase, and low haptoglobin), thrombocytopenia, and end-organ dysfunction (skin, gastrointestinal, renal, and central nervous systems). Some hereditary diseases have now been recognized as dysregulation of the complement cascade, with a failure to modulate a complement-mediated inflammatory response. Investigations of immune complex disease such as lupus (systemic lupus erythematosus [SLE]), syphilis, and cryoglobulinemia have shed light on the role of complement in the activity of these disorders. Many inhibitors including C3 and C5 convertase have been investigated because of potential drug therapies to correct dysregulation. Serum complement is usually low in these immune complex diseases.

In the following discussion, the focus is on symptoms and signs that constitute the major syndromes observed in the patient with kidney or lower urinary tract disease. These syndromes are the foundation for the diagnosis of particular diseases. Emphasis will be on new classifications of disease, a better understanding of the role of complement and its dysregulation in nephrologic disorders, use of biomarkers, and the impact of genomic knowledge on the expression, identification, and treatment of disorders.

NEPHRITIC SYNDROMES

Nephritis literally means an inflammatory condition of the kidney. Nephritic inflammation may occur in association with infection, allergic response to medications, systemic autoimmune disorders, or toxic exposures. The kidneys may be one of many organs, or the only organ, involved in the inflammatory disorder. Inflammation with enlargement of the kidneys is often associated with point tenderness over the flank and sometimes exquisite costovertebral angle tenderness, requiring gentle palpation for diagnosis.

Nephritic syndromes can be further subdivided depending on the inflamed structures within the kidney, including glomerular, tubulointerstitial, and vascular; and on the time course of progression of the inflammatory process, which may be acute, subacute, or chronic.

GLOMERULONEPHRITIS

Classification of glomerulonephritis (GN) has been challenging because of overlapping features of infection-related and immunologic-mediated pathology. GN is associated with hypertension, volume expansion, and an abnormal urinalysis. In most cases, the volume expansion manifests as edema and hypertension; in the child, ascites may develop; and in the elderly, restlessness and anxiety may be the first signs of incipient acute pulmonary edema. There may be orthopnea at night or dyspnea on exertion, with or without significant peripheral edema. Acute GN is usually associated with low urine output (oliguria) or, at times, complete anuria, low urine sodium content, and concentrated urine, resulting in the retention of salt and water. It is vital to observe a spun urinary sediment to diagnose active GN.

The disease presentation may be acute or subacute, occurring over days or weeks, as in postinfectious GN, or as a chronic, smoldering process with inexorable progression to chronic kidney failure over several months to years. The pathologic correlate of these presentations—the relative amount of acute inflammatory, proliferative, or necrotizing lesions in renal tissue versus chronic sclerotic and atrophic findings on renal biopsy—reflects the acuity versus chronicity of disease. Therefore, in these progressive destructive conditions, early diagnosis is critical, and treatment for acute reversible disease should be instituted as quickly as possible.

The evaluation of the findings on history, physical examination, and urinalysis in narrowing diagnostic possibilities for a specific etiology of the glomerular syndromes is demonstrated in Fig. 319-1. The nephritic urinalysis shows hematuria, proteinuria, cells or clumps of cells, and cellular casts in the spun urinary sediment. The cells in the urine are usually a mixture of red blood cells (hematuria) and inflammatory cells (pyuria), including polymorphonuclear (PMN) leukocytes. Microscopic hematuria is invisible to the naked eye, as opposed to macroscopic hematuria, which is often described as cola or "tea-colored" urine, caused by hemoglobin entering an acid urine, forming hematin. The process of urinary erythrocytes crossing the glomerular membrane barrier causes the red blood cells to become misshapen or dysmorphic. It is unusual in these nephritic syndromes to see blood clots or gross hematuria, a term used for overtly blood-red urine that is often accompanied by dysuria and characterizes trauma and other syndromes of lower urinary tract bleeding. However, in episodes of immunoglobulin A (IgA) nephropathy, glomerular hematuria is often gross as red blood cells traverse diseased glomerular basement membrane (GBM).

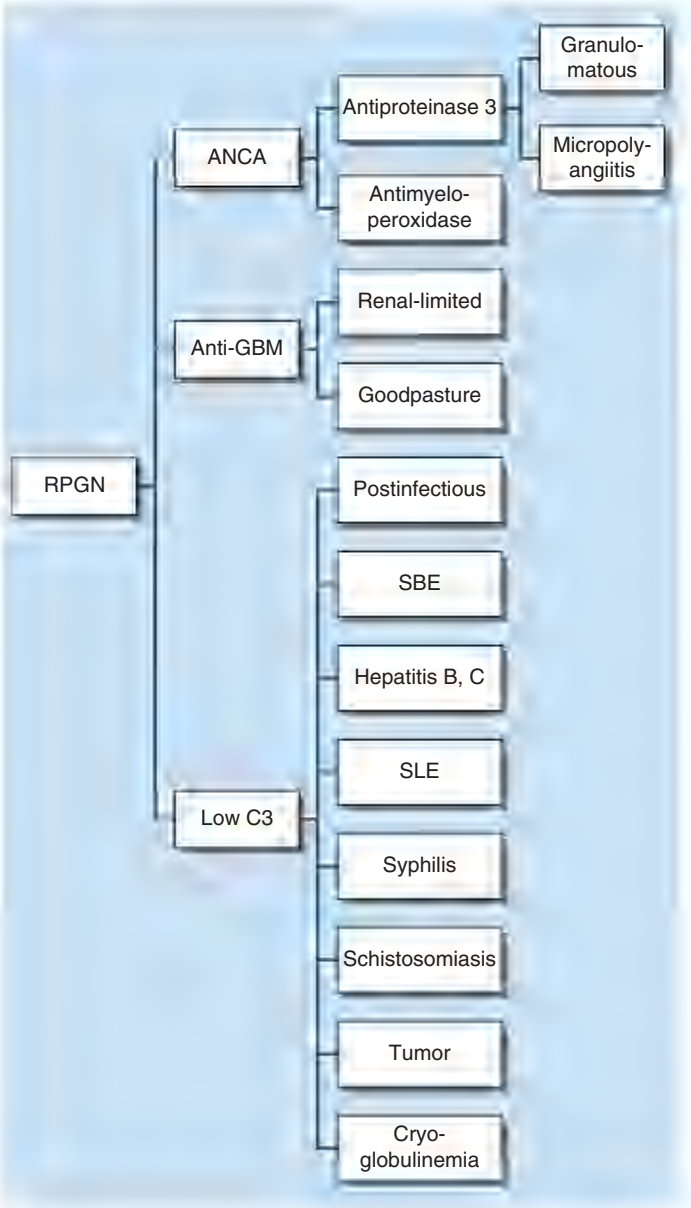

FIGURE 319-1 Rapidly progressive glomerulonephritis (RPGN). The syndrome of RPGN is diagnosed clinically. The three major categories are the antineutrophilic cytoplasmic antibodies (ANCAs; ANCA-positive vasculitides), anti–glomerular basement membrane antibody-positive (anti-GBM), and immune complex disorders with low C3 complement. C3 is synthesized in the liver, bound to circulating infectious or neoplastic antigens with their antibody complexes, deposited in the glomerular subendothelium, and associated with nonrenal manifestations. Syphilis is usually accompanied by vasculitis, and cryoglobulins may be seen in the setting of hepatitis C or myeloma and often lower C4 as well. SBE, subacute bacterial endocarditis; SLE, systemic lupus erythematosus.

Postinfectious Glomerulonephritis In postinfectious glomerulonephritis (PIGN), the classic example of acute GN, the immune response involves formation of antibody-bacterial antigen complexes within the circulation, usually 10 days to 3 weeks after infection of the pharynx or skin (as in impetigo) by specific nephritogenic strains of β-hemolytic group A streptococci. The deposition of these immune complexes amplifies and activates the complement cascade, causing an intense inflammatory response that accounts for the active (nephritic) sediment in the urine and decreased circulating C3 levels in the blood. The cellular proliferation is intense enough to minimize filtering

surface area, causing a prerenal retention of Na^+ and water, oliguria, and sometimes anuria. Pathologically, the proliferation disrupts capillary blood flow, hence the description of "bloodless capillaries" for this condition.

In the general population, the incidence of PIGN has decreased given the widespread availability of antibiotics, specifically the penicillins and sulfa drugs. At the time of presentation with renal findings, there may be no ongoing infection, but rather a continued immune response to specific bacterial antigens. Antibiotics may not be necessary if the infection has resolved. Evidence indicating the initial infection may still be present in the form of titers of streptozyme, anti–streptolysin O, and anti–deoxyribonuclease B. Upon deposition, the circulating immune complexes bind and activate C3 complement, which, with other cytokines, causes a proliferative pattern of injury with subendothelial glomerular deposits. Taken together, there is increased clearance of total hemolytic complement and C3, causing hypocomplementemia. Over time, subepithelial deposits known as humps develop and proteinuria increases. As subendothelial deposits clear, nephritic signs disappear. Infective endocarditis, both acute and subacute, may also result in circulating immune complexes even while the patient remains on antibiotic treatment. These glomerulonephritic conditions are also recognized clinically by low C3 complement levels in the blood.

In PIGN, the postinfectious cases should be distinguished from cases of *infection-associated* GN that occur during an ongoing infection, such as a staphylococcal (often methicillin-resistant *Staphylococcus aureus*) abscess, osteomyelitis, or empyema, which are treated with antibiotics and purulent drainage and are characteristically associated with IgA deposition in the glomeruli. PIGN is also to be distinguished from synpharyngitic hematuria, another glomerular syndrome that frequently produces a heavier excretion of red blood (gross hematuria), which may appear to the patient as a frightening hemorrhage. The patient may present with this concern, so it is important for the clinician to recognize that as little as 10–20 mL of blood will turn a liter of urine red. Synpharyngitic hematuria, usually occurring simultaneously with, or 1–3 days into, a viral pharyngitis, is most often related to IgA nephropathy (IgAN) rather than PIGN. Though C3 complement is deposited in both PIGN and IgAN, only PIGN is associated with low complement levels in the blood.

IgAN is one of the leading causes of renal failure worldwide and is a common type of GN that is caused by the mesangial deposition of C3 binding to excess galactose-deficient IgA-1 immunoglobulin. This results in damage to the basement membrane, manifesting as hematuria and renal insufficiency. Although IgAN is a common disease, particularly in Asia, data on prevalence are often based on clinical assumptions rather than kidney biopsy and, therefore, are inaccurate. Treatment is based on each patient's personal presentation, but all patients need management of hypertension and proteinuria, often with anti–angiotensin II inhibitors. Because of its association with viral infections, IgAN has historically been treated with removal of lymphoid tissue with strategies such as tonsillectomy. Other treatments have included fish oils and corticosteroids. However, recent advances in understanding the lectin and alternative pathways of complement have led to investigation of targeted therapies based on kidney biopsies showing IgA-1 and glomerular deposition of mannan-binding lectin, which occurs in 50% of patients with IgAN. Complement blockers, B-cell therapies, and plasma cell therapies are currently either in use or being further investigated to treat patients with a genetic predisposition for high levels of galactose-deficient IgA-1 in order to antagonize development of autoantibodies to the abnormal IgA1 or to interfere with the proinflammatory complement binding to the largely mesangial deposits of the immune complexes. Avacopan, a selective C5a receptor inhibitor effective in treating antineutrophil cytoplasmic antibody-associated (ANCA)-vasculitis, lowers proteinuria in IgAN nephropathy.

The U.S. Food and Drug Administration has recently approved an oral dual endothelin 1 and angiotensin II receptor antagonist for the reduction of proteinuria in adults with primary IgAN at high risk for rapid disease progression. These individuals typically have a urine protein-to-creatinine ratio of >1.5 g/g and decreased GFR. Patients with chronic kidney disease and either micro- or macrohematuria as a sign of disease have been less likely to receive a renal biopsy than patients with azotemia or proteinuria. Increasing appreciation that patients with IgAN have a more rapid GFR decline to end-stage kidney disease has encouraged greater use of renal pathology to guide a more aggressive management strategy. Attention to risk factors and advances in development of novel pharmacologic approaches based on a better understanding of the pathogenesis of IgAN have led to greater judgement to perform a renal biopsy for diagnosis and treatment. Increasing appreciation that patients with IgAN, particularly those of African ancestry with high-risk APOL1 alleles have a more rapid GFR decline, and clinicians are encouraged to make use of renal pathology to guide a more aggressive management strategy.

Rapidly Progressive Glomerulonephritis (RPGN) Rapidly progressive glomerulonephritis (RPGN) is a syndrome arising from a variety of causes (Fig. 319-1). Pathologically, it is associated with a proliferation of glomerular parietal epithelial cells and inflammatory cells, known as cellular crescents, that surround and compress the capillaries, reducing the filtration surface area. Over time, the crescents become fibrotic and atrophic with global loss of the glomerular tuft. When >50% of glomeruli are affected (diffuse), this highly destructive process usually leads to global glomerulosclerosis. When <50% of glomeruli are acutely affected (focal) and only part of each glomerulus (segment) is involved, a condition known as focal and segmental necrotizing GN develops, with or without crescents. When such lesions heal, focal segmental glomerulosclerosis (FSGS) results. This pathological finding on biopsy must be distinguished from the primary podocytopathy (FSGS that causes nephrotic syndrome) and from adaptive changes seen in most progressive chronic kidney diseases. Recognition of RPGN and choice of appropriate therapy are extremely important because, if left unchecked, the capillaritis can lead to complete and irreversible loss of kidney function, as well as fatal pulmonary hemorrhage when associated with lung vasculitis.

In the case of RPGN, one may see the typical signs of the nephritic syndrome, usually with subnephrotic proteinuria, although other clues to diagnosis may be present in pulmonary-renal syndromes, where the patient may present with hemoptysis, interstitial lung disease, epistaxis, or upper airway symptoms of sinusitis or nasal congestion. Blood testing, including at least three necessary immunologic studies, help narrow the differential diagnosis. The antineutrophil cytoplasmic antibody (ANCA) test, particularly anti-proteinase-3 antibodies (cANCA) or anti-myeloperoxidase (pANCA), is diagnostic for the pauci-immune disorders of systemic vasculitis, such as granulomatous vasculitis (formerly known as Wegener's granulomatosis), giant cell arteritis, and microscopic polyangiitis, which are particularly associated with pulmonary and upper respiratory disease. In ANCA-positive diseases, the kidney and peripheral vessels are the target of autoantibodies, which attract complement and result in inflammatory vasculitis. Churg-Strauss syndrome, which is both granulomatous and eosinophilic, is a vasculitis associated with asthma.

By contrast, a positive test for anti-GBM antibodies, with or without a positive ANCA, would be consistent with renal-limited anti-GBM disease. One key distinction between ANCA-positive vasculitis and anti-GBM disease is that the vasculitides may recur, even subclinically historically at different times, whereas onset of anti-GBM is usually a single acute fulminant presentation that must be diagnosed rapidly with the ANCA and anti-GBM studies and renal pathology and treated promptly with plasma exchange followed by anti-inflammatory medication and cyclophosphamide or rituximab as immunotherapy to preserve kidney function. A positive anti-GBM test, when associated with pulmonary hemorrhage, is consistent with Good pasture disease, which is a disorder most often seen in an elderly population or in young males who smoke or have a history of inhaling hydrocarbon solvents. Not infrequently, both anti-GBM and ANCA are present with pathology showing pauci-immune disease, where the proposed role of ANCA is to expose the GBM epitope. This disorder should be treated in the same way as ANCA itself. The goal of plasmapheresis is to

remove all of the GBM autoantibody, which may take weeks to months. The circulating IgG anti-GBM, complexed in situ with C3 complement, is directed at an epitope in the α3 chain of the non-collagenous domain of Type 4 collagen in the basement membrane. This occurs at the site absent in hereditary nephritis. People with hereditary nephritis do not develop anti-GBM disease; however, if they receive a kidney in which the donor kidney contains the missing antigen, they may present with fulminant anti-GBM disease.

The immune complex diseases that may also manifest as RPGN may have low circulating levels of the third component of complement (C3) secondary to focal or diffuse immune complex deposits in the glomerular capillary subendothelial space. Certain of these disorders, such as SLE and cryoglobulinemia, can present with pulmonary hemorrhage. Patients with cryoglobulinemia often have low C4 complement and a high rheumatoid factor, and the syndrome may be caused by paraproteinemias or hepatitis C. Another cause of crescentic RPGN but with normal levels of C3 complement is a form of IgA vasculitis (Henoch-Schönlein purpura), a syndrome of skin vasculitis characterized by palpable purpura, gastrointestinal bleeding, arthralgias, and pulmonary hemorrhage. The C3 complement (also an acute-phase reactant) is detected on the kidney biopsy, particularly with galactose-deficient IgA1, in the mesangium rather than the capillary loops, and is associated with mesangial cell proliferation but not with low serum levels of C3 or IgA. The diagnostic tests and distinct diseases associated with these immune complex disorders are shown in Fig. 319-1.

ACUTE TUBULOINTERSTITIAL NEPHRITIS

Tubulointerstitial nephritis (TIN) comprises inflammatory disorders of the renal tubules and interstitium that may be caused by infection, autoimmune disease, or allergic immunologic responses to certain drugs **(Fig. 319-2)** and that have a time course ranging from days to weeks or months.

Acute allergic immune tubulointerstitial nephritis (ATIN) usually develops 1 day to 2 weeks following an exposure, change in dose, or re-exposure to an offending drug (anamnestic response) and may be associated with rapid and potentially reversible loss of kidney function, making early diagnosis imperative. Associated heavy glomerular proteinuria sometimes occurs with the use of nonsteroidal anti-inflammatory drugs (NSAIDs) or ampicillin, whereas protein secreted by the proximal tubule (β_2-microglobulinuria) indicates tubular disease. Clinically, there may be fever, rash, and eosinophilia, any of which is typical with certain types of penicillins, cephalosporins, fluoroquinolones, and some biologic cancer drugs that act as checkpoint inhibitors (CPIs), but are atypical for NSAIDs. Patients who recover from CPI-induced acute kidney injury (AKI) may resume treatment with the inhibitor. The urinalysis usually shows pyuria and at times eosinophiluria, but the most characteristic cell types are activated T lymphocytes, eosinophils, and plasma cells, along with white blood cell casts. A cyto-centrifuged urine sample in a small test tube, when exposed to centrifugal forces, sprays sediment onto a slide mounted perpendicular to the tube's aperture. The slide, then stained with Giemsa, best demonstrates these cell types.

The patient may experience symptoms of polyuria, tender kidneys, and signs of tubular dysfunction, including nephrogenic diabetes insipidus, hypo- or hyperkalemia, and hyperchloremic metabolic acidosis. Common drugs that cause ATIN include proton pump inhibitors (PPIs) and sulfa drugs, especially sulfamethoxazole, as well as sulfa-containing diuretics such as acetazolamide, thiazides, furosemide, and, less frequently, bumetanide. PPIs may increase risk for ATIN in patients on CPIs. Frequently, rifampin and several other drugs cause noncaseating granulomatous interstitial nephritis. In caseating granulomas resulting from hematogenous spread of *Mycobacterium tuberculosis*, the first granulomas appear connected to the glomeruli in the cortex, where oxygen tension is at its highest. Granulomatous tubulointerstitial nephritis may occur in sarcoidosis and histoplasmosis.

Systemic infections including bacterial, viral, fungal, and parasitic may induce tubulointerstitial nephritis and were first described pathologically in the preantibiotic era as Councilman's nephritis in the course of scarlet fever. Autoimmune interstitial nephritis is seen in diseases such as lupus nephritis, ANCA-positive vasculitis, and other rheumatic disorders including Sjögren's syndrome, which may present with dry eyes as part of sicca syndrome. In a patient with photophobia and red painful eyes, the clinician should look at renal function and the urinalysis for evidence of tubulointerstitial nephritis uveitis syndrome.

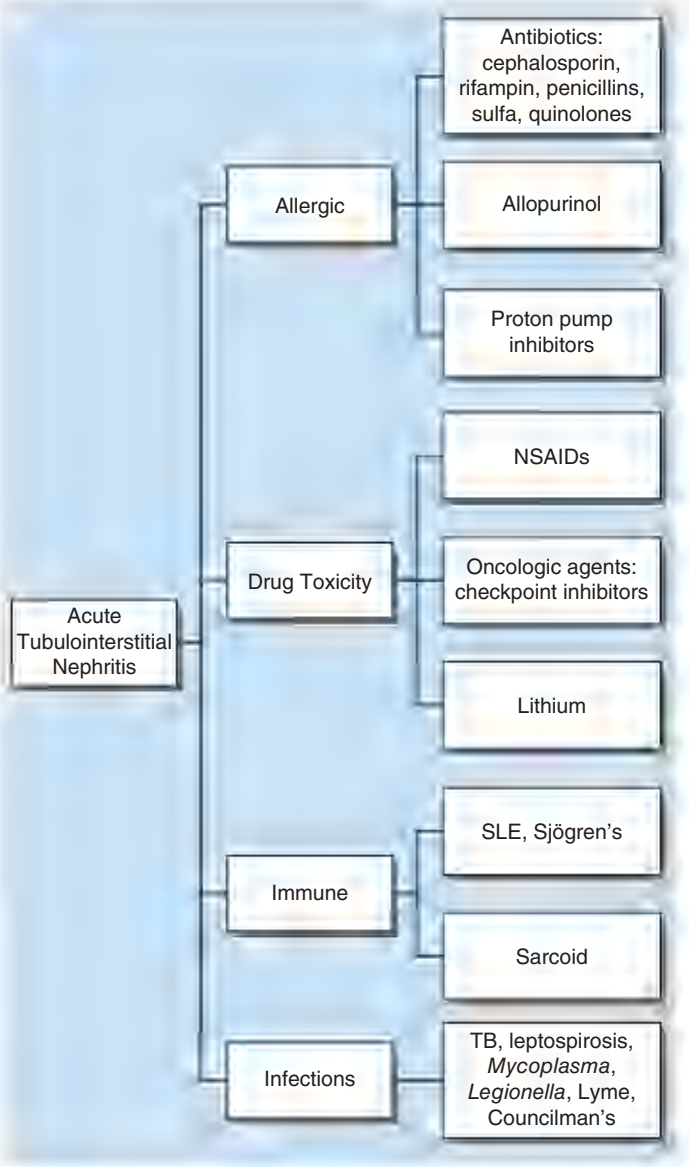

FIGURE 319-2 Acute tubulointerstitial nephritis. Diseases resulting from injury to the tubular and interstitial components of the renal cortex and medulla are shown. NSAID, nonsteroidal anti-inflammatory drug; SLE, systemic lupus erythematosus; TB, tuberculosis.

CHRONIC TUBULOINTERSTITIAL NEPHRITIS

Noninflammatory interstitial diseases are often caused by toxic exposures that damage the tubular interstitial structures. For example, a cancer patient on ifosfamide may develop Fanconi's syndrome, indicating proximal tubule damage. Heavy-metal exposures such as cadmium, lead, and mercury from old dental fillings may lead to proximal tubule injury and, once again, Fanconi's syndrome. A patient with hypomagnesemia and AKI may have had past exposure to platinum-containing chemotherapeutic agents, and a patient with nephrogenic diabetes insipidus, unresponsive to antidiuretic hormone, may have had treatment with lithium, analgesics, or chemotherapy. Hypokalemia and interstitial disease are consistent with a past history of exposure to aminoglycosides or amphotericin B. The patient with the former may complain of hearing loss, and the patient with the latter may present with hypokalemia and renal tubular acidosis (RTA).

Chronic interstitial diseases should be suspected in cases of paraproteinemia (light-chain nephropathy or amyloidosis) and in patients who ingest herbal remedies containing aristolochic acid, as occurs commonly in China and has been determined to be the cause of Balkan nephropathy. Perhaps the most common cause of chronic interstitial nephritis is prolonged analgesic use to treat chronic pain (not only NSAIDs but also acetaminophen or combinations of phenacetin, aspirin, and caffeine) as part of the analgesic syndrome. Clinicians should inquire about a prior history of pain and also gastrointestinal symptoms that may precede the kidney disease; the analgesic drugs often go unreported by the patient. It is important to recognize this syndrome because, if the drugs are not discontinued, a later development may be uroepithelial cancers of the distal ureter and urinary bladder. Lithium after prolonged use can also cause chronic interstitial nephritis along with nephrogenic diabetes insipidus and slowly progressive kidney failure.

Patients who have hypercalcemia or hyperoxaluria may develop nephrocalcinosis (a form of interstitial nephritis) that is characterized by calcifications within the renal parenchyma, often at the cortical medullary boundary. When nephrocalcinosis and nephrolithiasis are concurrent, the most common etiologies include hypercalcemic disorders, particularly primary hyperparathyroidism, and congenital medullary sponge disease (tubular ectasia), as well as hereditary distal RTA. In patients with DM, chronic analgesic use, or sickle cell diseases, the phenomenon of papillary necrosis is associated with chronic interstitial damage characterized by nephrogenic diabetes insipidus. For example, phenacetin toxicity is a result of the drug concentrating in the medulla due to the normal urinary concentrating mechanism; ironically, the first function lost because of medullary toxicity is the ability to concentrate the urine. In the ensuing papillary necrosis, the patient may observe solids in the urine, which are sloughed tissue from the ischemic medulla. When a patient with inflammatory bowel disease or one who has had gastric bypass procedures such as the Roux-en-Y develops kidney injury, with or without calcium oxalate kidney stones, a 24-h urine oxalate measurement must be determined to diagnose intestinal hyperoxaluria, which otherwise may lead to nephrocalcinosis. Chronic bacterial pyelonephritis is not a common cause of chronic renal failure, as it rarely affects both kidneys. Acute pyelonephritis in a solitary kidney or transplanted kidney may cause AKI.

PROTEINURIC STATES AND NEPHROTIC SYNDROME

Proteinuric States Some patients notice generalized edema and foamy urine, manifestations of albuminuria. Proteinuria is not synonymous with nephrotic syndrome (NS). In DM, the urinary loss of 30–300 mg/d of microalbuminuria (MALB) defines excessive albuminuria. Glomerular proteinuria, which typically occurs after years of small-vessel disease (explaining the likelihood of coincident small-vessel retinopathy), predicts future development of progressive renal failure and NS. The rate of renal progression is greater with hypertension, obesity, and poor glucose control. Further risks are partial nephrectomy, hepatitis C, and FSGS in patients of African ancestry, possibly related to predisposition by and prevalence of *APOL1* gene mutations. APOL1-mediated kidney disease is caused by two risk variants of the *APOL1* gene. Gene expression occurs only when a second hit of infection or inflammation triggers damage to podocytes and glomerular endothelial cells, creating channels in those cells that result in dysfunction and proteinuria.

Because treatment of patients with MALB is indicated, the clinician caring for diabetic patients should screen regularly for the presence of small amounts of albumin in the urine, which can be detected as microalbuminuria by radioimmunoassay. Subnephrotic albuminuria is characteristic of focal diseases of the kidney with <50% of glomeruli involved, whereas NS is likely when disease is diffuse, involving most glomeruli. Lower levels of albuminuria are characteristic of GN, as discussed above.

Microalbuminuria is beneath detection by urinary dipstick protein analysis. Any detectable albuminuria on dipstick is called overt proteinuria and, when detected at the highest level on the strip, is consistent with nephrotic proteinuria. The dipstick measurement picks up only the most acidic proteins like albumin but not proteins with a higher isoelectric point, most notably kappa and lambda light chains found in multiple myeloma. A patient being evaluated for renal disease should have either a timed direct measure of albumin or protein or, at least, a urinary microalbumin-to-creatinine ratio. The filtration of light chains may cause glomerular damage and albuminuria (kappa light-chain nephropathy or lambda AL amyloid) but does not reliably indicate glomerular damage because their charge and molecular weight allow them to freely cross the glomerular barrier. Such filtration is considered overflow proteinuria.

A laboratory measurement of albumin or total protein concentration should be normalized to urine creatinine concentration as a ratio in order to discount the effects of urinary dilution or concentration. It is also important to note that the ratio of total protein concentration to creatinine concentration is not specific for albumin excretion and may indicate the presence of light chains. The detection of light chains requires serum or urine protein immunoelectrophoresis.

Nephrotic Syndrome NS has three defining features: edema, hypoalbuminemia (<3.5 g/dL), and proteinuria >3.5 g/d. This syndrome is often associated with lipid abnormalities such as high low-density lipoprotein, low high-density lipoprotein, and lipiduria. The urine may contain large tubular epithelial cells that are engulfed with lipids in a recognizable shape under polarized light. These oval fat bodies may also contain cholesterol monohydrate crystals, which appear as Maltese crosses. Under low light, the refractile lipid may be seen as fatty casts.

Clinically, patients present with generalized edema, and in contrast to heart failure with orthopnea, facial, eyelid, and periorbital swelling is observed in NS. Penile and scrotal edema can be severe enough to obstruct urethral urine flow in men. In some cases, edema may form large bullae that may rupture, predisposing to ulceration and cellulitis. The skin becomes smooth and may appear to "weep." Additionally, patients may present with hoarseness caused by vocal cord edema. Occasionally, nephrotic range proteinuria is not associated with edema (i.e., in the case of HIV-associated nephropathy [HIVAN], which is more common in African Americans with HIV infection). In these cases, rapid loss of renal function may occur due to implosion of the glomerular capillary by proliferation of visceral epithelial cells that crush the glomerular loops, decreasing capillary flow and filtering surface area (collapsing glomerulopathy). This glomerulopathy is a severe, treatment-resistant form of FSGS. Very heavy proteinuria is often noted in this syndrome.

Other secondary forms of FSGS, more often not associated with NS, include remnant kidney after partial surgical removal, adaptive injury, chronic hypoxemia from chronic lung or congenital heart disease, sickle cell diseases, recurrent vasculitis with healing of some glomeruli, obesity, and congenital urogenital anomalies. Secondary forms of FSGS are shown in **Fig. 319-3**.

NS is a hypercatabolic state with negative nitrogen balance due to proximal tubule absorption and lysosomal catabolism exceeding hepatic albumin synthesis. A characteristic finding of rapid-onset hypoalbuminemia in NS is horizontal linear white lines in the nail bed, known as Muehrcke's lines. When NS in the adult occurs abruptly, with severe elevation of cholesterol, one must consider glomerular epithelial injury (podocytopathy), which may be idiopathic minimal change disease (MCD), a name historically based on the appearance of renal tissue on light microscopy and which is often preceded by an upper respiratory infection, allergies, or immunization. Secondary causes of MCD are Hodgkin's lymphoma or other lymphoproliferative disorders. MCD can occur at any age and in the adult may present with AKI as well, primarily because of the underlying vascular disease and hypoalbuminemia.

Age is an important aspect in the onset of NS, in that young children <6 years of age frequently have MCD. Several gene mutations encoding for proteins of the podocyte, such as nephrin (*NPHS1*) and podocin (*NPHS2*) in the slit diaphragm, have been shown to be responsible for most cases of hereditary NS **(Table 319-2)**.

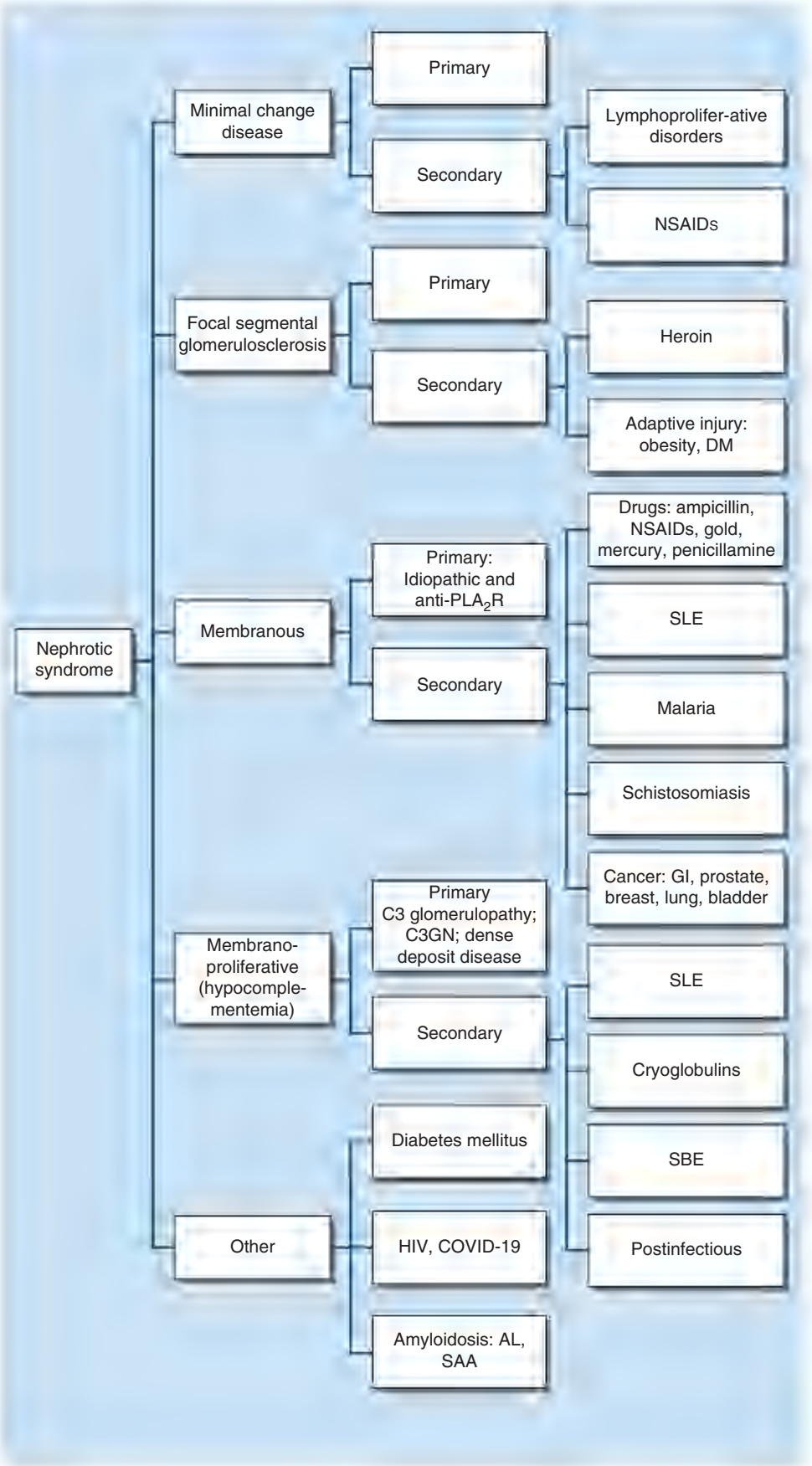

FIGURE 319-3 Nephrotic syndrome. Different pathologic syndromes are broken down into idiopathic and secondary causes. Seventy percent of primary membranous nephropathy (MN) is associated with antibodies to the integral subepithelial basement membrane antigen phospholipase A_2 receptor (PLA_2R). The former term for primary membranoproliferative glomerulonephritis has been replaced by pathologic syndromes involving complement deposition (C3 glomerulopathy and dense-deposit disease in children). AL amyloid is the form of amyloidosis secondary to λ light-chain deposition, and serum amyloid A (SAA) is the protein associated with chronic inflammatory diseases such as rheumatoid arthritis, familial Mediterranean fever, and tuberculosis. DM, diabetes mellitus; GI, gastrointestinal; NSAID, nonsteroidal anti-inflammatory drug; SBE, subacute bacterial endocarditis; SLE, systemic lupus erythematosus.

TABLE 319-2 Hereditary and Congenital Diseases

HEREDITARY GLOMERULAR DISEASES: NEPHROTIC SYNDROME OR RENAL FAILURE	HEREDITARY TUBULAR DISEASES	APOL1	CILIOPATHIES	CHANNELOPATHIES	CONGENITAL ANOMALIES
Podocyte mutations; basement membrane mutations; hereditary nephritis; X-linked and somatic mutations; *COL4A5*; Alport's syndrome with hematuria, neurosensory hearing loss, conus lentus; Fabry's disease (X-linked alpha-galactosidase deficiency)	Fanconi's syndrome with renal glycosuria, proximal tubule renal tubular acidosis (RTA), hypophosphatemia, hypouricemia; distal RTA with hearing loss, renal calcification; nephrogenic diabetes insipidus; hyper- or hypotensive disorders with hypo- or hyperkalemia; metabolic alkalosis or acidosis	Mutant allele in African-American population, leading to susceptibility to further injury in many other disorders including diabetes mellitus, IgAN	Autosomal dominant and recessive polycystic kidney disease; medullary cystic kidneys (metabolic acidosis and salt-wasting); other phenotypes	Gitelman's and Bartter's syndromes; disorders of epithelial sodium channel and proton pumps	Unilateral agenesis; dysgenetic disease; medullary sponge kidney (hematuria, stones, or infection); horseshoe kidneys (proteinuria); malposition; ureteropelvic obstruction; cystoureteral reflux (proteinuria)

In children who have a serum albumin concentration <2 g/dL, tissue ischemia may develop, causing a "nephrotic crisis," in which severe abdominal pain may be mistaken for a surgical abdomen. A 20-year-old presenting with NS may have MCD, FSGS, or membranous nephropathy (MN).

Similar to MCD, MN may be of primary or secondary etiology. Whereas NS is a cause of a hypercoagulable state, particularly when it is accompanied by severe hypoalbuminemia (<2 g/dL), MN in NS is most often associated with renal vein thrombosis (RVT) for a number of reasons, among them being urinary loss of antithrombin-3 and plasminogen, as well as hyperfibrinogenemia. RVT may present with back pain, renal failure or hematuria, increased edema in the lower extremities, or pulmonary emboli.

NS with heavy proteinuria or large kidneys on ultrasound in advanced stages of chronic kidney disease (CKD) is often noted in diabetic nephropathy, amyloid, HIVAN, and MN with RVT. MN may be the presenting finding in cases of SLE, whereas diffuse proliferative GN with low C3, when associated with SLE, occurs in patients who also have signs and symptoms of joint, skin, or systemic organ involvement. A cause of very early MN is an idiosyncratic reaction to NSAIDs, even when taken in small amounts. Many other drugs including penicillamine, mercury, and gold can cause MN. Proteinuria from any cause may present earlier, or increase, when DM, obesity, partial nephrectomy, or increased renal venous pressure exists.

Solid tumors, particularly lung, gastric, intestinal, bladder, breast, and prostate, may underlie a paraneoplastic syndrome of MN. While it is important to take a history and examine the patient carefully for signs of cancer, it is not the rule to work up every patient with MN exhaustively for the disease. Neoplastic nephropathy may be a sign of recurrent disease and may even be recognized by tumor antigens. MN also occurs in the context of many infectious diseases, including syphilis, malaria, schistosomiasis, and hepatitis B. Recently, 70% of patients with primary MN have been found to have circulating levels of an autoantibody to the phospholipase A_2 receptor (anti-PLA_2R) in the subepithelial region of the GBM. Compared to non-PLA_2R patients, fewer patients in this group have drug-induced MN and are more likely to experience spontaneous remission; one of four subclasses of immunoglobulins has been implicated in TIN and sometimes MN as part of a multiorgan disease. IgG4 increases in response to chronic exposure to an antigen; it has been associated with autoimmune diseases such as acute pancreatitis-1 (AP1) and severe and often allergic asthma and is often detected by high levels in the blood. Patients who are thought to have diabetic nephropathy on clinical grounds are often found to have an additional diagnosis, particularly MN, on renal biopsy. The increased frequency of MN in DM may indicate that glomerular hyperfiltration accentuates the proteinuria of MN or is associated with a genetic variant, *COL45A5*. Diabetic nephropathy is perhaps the most common reason for the renal patient to begin dialysis; therefore, much attention has been paid to the progressive nature of chronic failure in these patients. Risk factors include those that affect hemodynamics and blood sugar. In the poorly controlled diabetic patient, increased blood pressure, renal plasma flow, and GFR develop in single nephrons that are spared until glomerular sclerosis in other nephrons has already occurred. This finding is clinically evident by the presence of proteinuria or low GFR. The proteinuria is responsive to angiotensin II–inhibiting drugs such as angiotensin-converting enzyme inhibitors, angiotensin II receptor blockers, and renin inhibitors. Sodium-glucose cotransporter 2 (SGLT2) inhibitors in the proximal tubule of the kidney create glycosuria, improve glucose control, and have been shown to reduce the rate of progression. The more glucose filtered during periods of hyperglycemia, the greater are the renal interstitial glucose and advanced glycation end products that cause fibrosis.

Patients who have nephrotic and nephritic sediments in childhood may have membranoproliferative glomerular nephritis with low C3 as a primary disease (C3 glomerulopathy or dense-deposit disease). The adult presenting with a nephrotic and nephritic profile should be considered to have an immune complex disorder unless proven otherwise. In amyloidosis, there may be a simultaneous and severe tubular syndrome in addition to the albuminuria, consisting of nephrogenic diabetes insipidus and a hyperkalemic RTA. When NS is associated with Fanconi's syndrome (glycosuria, phosphaturia, uricosuria, and aminoaciduria), one must consider multiple myeloma in the adult.

HEMATURIA AND LOWER URINARY TRACT SYNDROMES

Since blood could enter the urinary tract from any structure, identifying the source is the necessary first step. As a rule, hematuria associated with flank pain or ureteral colic is more characteristic of a lower urinary tract source, such as a stone or an obstructing lesion. However, when flank pain without colic is noted, one has to consider swelling of the kidney and stretching of the renal capsule, as might be seen in acute urinary obstruction, kidney infection, interstitial nephritis, and, on occasion, acute glomerular nephritis. Heavy bleeding with clots is more characteristic of lower tract bleeding but could result from trauma to the kidney. In patients who have acute flank pain and hypertension, assuming the pain is due to a kidney stone may miss an occlusive vascular event from an embolus or in situ clot within the arterial blood supply. Patients who engage in strenuous exercise may develop hematuria that can be ruled out by retesting the urine after a week or two of rest. True hematuria can be distinguished from hemoglobinuria and myoglobinuria by urinalysis.

Symptoms of lower urinary tract disorders are dysuria, urinary frequency, urgency, incomplete emptying, hematuria that is most pronounced at the beginning of flow, and a poor urinary stream. Among these disorders are urinary tract infections and prostatic hypertrophy. Hematuria of recent onset noted in the fourth decade of life or beyond should undergo a urologic evaluation and most likely cystoscopic examination of the bladder. However, chronic hematuric conditions may be associated with chronic glomerular disease such as thin basement membrane, hereditary nephritis, or IgAN. This is why it is so important to search for previous examinations such as insurance, military, or employment examinations done in the past to determine if hematuria was present in order to establish chronicity.

ACUTE KIDNEY INJURY

AKI is defined by the retention of nitrogenous solutes such as urea, uric acid, and creatinine. The creatinine concentration goes up primarily related to the amount of water absorbed along the nephron. Because urea but not creatinine has a reabsorptive component, clearance of urea is less than the clearance of creatinine. With a constant catabolic rate, a decrease in glomerular filtration alone will affect the blood urea nitrogen (BUN) and creatinine proportionately. By contrast, in a disorder associated with enhanced urinary concentration (high antidiuretic hormone [ADH]), where urea and water have increased reabsorption in the process of concentrating the urine, the retention of urea nitrogen exceeds that of creatinine, accounting for an elevated BUN-to-creatinine ratio. Oliguria or oligoanuric states are often characterized as prerenal, defined as preglomerular vascular disease or low perfusion states; renal, indicating intrinsic renal disease; or postrenal, indicating obstructive nephropathy or uropathy (see Table 319-1).

Prerenal states are often related to a decreased perfusion pressure to the glomerular capillaries or some other interference with filtration. The differential diagnosis includes proliferative GN (the bloodless capillary); a preglomerular vascular disease such as scleroderma or TMA; the use of pressors for the maintenance of blood pressure; vasoconstrictive substances including cocaine, iodinated IV contrast media, hemoglobin or myoglobin, and certain antibiotics such as vancomycin, cyclosporine, and tacrolimus (calcineurin inhibitors); and other vasoconstrictive drugs, such as NSAIDs and renal nerve stimulators. Hypercalcemia and hypoxia are also vasoconstrictive. Correcting hypoxemia has a diuretic effect.

Intrinsic Renal Disease All of these disorders will decrease perfusion pressure and decrease GFR while stimulating sodium and water reabsorption. Therefore, the characteristic urinary findings are low urinary sodium excretion and concentrated urine. The urine sodium concentration is usually low and the urine to plasma creatinine concentration is usually >40. The same result could occur in bilateral renal artery stenosis, heart failure, and other circulatory collapse. If there is damage done to the renal tubules (so-called intrinsic renal disease), there may or may not be oliguria, and in fact, there could be polyuria (unresponsiveness to ADH) and sodium-wasting, potassium-wasting, and acid-base disorders, each of which may predominate. One of the most frequent causes of oliguric acute renal failure is acute tubular necrosis, caused by gram-negative sepsis, hemodynamic collapse, hemoglobinuria or myoglobinuria, and medication or toxin ingestion. Examples are crush injury, heroin and alcohol stupor, and compartment syndrome. Drug causes include NSAIDs, aminoglycosides, and chemotherapeutic drugs such as cisplatin and methotrexate.

Postrenal States Postrenal states accompanied by anuria suggest complete obstruction to the flow of urine, while polyuria and bland urinary sediment suggest incomplete obstruction combined with ADH unresponsiveness. The fractional excretion of sodium is usually >1–2%, whereas in oliguric prerenal syndromes, the fractional excretion of sodium is usually <1%. Exception to the low sodium excretion would be in the case of hyperchloremic metabolic alkalosis, where chloride is being conserved and sodium excreted with bicarbonate.

Urinary tract obstruction (UTO) is usually characterized by hydronephrosis visualized with ultrasound imaging or large volumes of urine removed by bladder catheterization, indicating bladder outlet obstruction. Exceptions to finding hydronephrosis on an imaging study include the extrinsic obstructive compression of the kidney or ureter in retroperitoneal disease; cases in which imaging was done too early, for example <4 days after obstruction; or when the patient was simultaneously obstructed and volume depleted.

As previously mentioned, acute tubular diseases that are not primarily due to inflammation can be caused by intratubular obstruction, hyperoxaluric states, or uric acid or phosphates in tumor lysis syndrome following chemotherapy for lymphoproliferative disorders. Other drug therapies that cause tubular injury include cisplatin, ifosfamide, methotrexate, aminoglycosides, and amphotericin B, and toxicity through exposure to heavy metals.

Kidney injury in the setting of systemic disease with dysfunction in other organs includes cardiorenal, pulmonary-renal, and hepatorenal syndromes. Other syndromes that typically involve the kidney include febrile illness, systemic infection with septic shock, hemodynamic collapse due to cytokines, or capillary leak syndrome. These syndromes and the endothelial origins of TMAs and hemolytic-uremic syndrome are shown in **Fig. 319-4**. Obstetric patients with abruptio placenta may develop bilateral cortical necrosis and, as a consequence, anuria and, often, irreversible renal failure. In addition, patients with atheroembolic syndrome can present with AKI or chronic progressive damage following an aortic catheterization. If the blood vessels catheterized involve the aortic arch, an encephalopathic syndrome that can mimic uremic encephalopathy may follow. As many as 70% of patients with COVID-19 who required ventilators during the early phase of the pandemic developed multiorgan failure, including AKI. AKI may also be a risk for CKD following a COVID-19 infection, but most patients return to baseline function.

CHRONIC KIDNEY DISEASE AND THE UREMIC SYNDROME

CKD, progressing over months to years, can be the long-term result of any of the aforementioned diseases. If the time course is unknown, other ways to diagnose CKD versus a more recent kidney disorder are useful (i.e., the finding of bilaterally small kidneys on a renal ultrasound). Kidneys imaged by this method are normally 10–12 cm in length. Small kidneys, <8 cm, are likely atrophic with irreversibly low function; but in some cases of CKD, such as in DM, the kidneys may be large despite kidney failure. Remarkably, even atrophic kidneys may still produce renin to sustain blood pressure and erythropoietin to minimize anemia; however, due to low calcitriol in CKD, patients develop secondary hyperparathyroidism. The normal parathyroid gland weighing 25 mg would be limited in raising parathyroid hormone (PTH) levels, such that very elevated PTH likely favors a diagnosis of CKD. Thinning of the renal cortex is also a sign of chronicity.

DM accounts for ~50% of CKD patients who progress to end-stage renal disease (ESRD). Other important causes leading to ESRD are IgAN; ischemic nephropathy without proteinuria manifesting after age 50 with hypertension and signs of other large-vessel disease, such as intermittent claudication from peripheral vascular disease; stroke; and coronary artery disease. By contrast, renal arterial disease due to fibromuscular dysplasia seen predominantly in white women in the fourth decade of life does not progress to renal failure and is a treatable form of hypertension. Other arterial diseases include polyarteritis nodosum and, in medium-sized vessels, a Kawasaki-like illness affecting children, which has had a 30-fold increase since the onset of COVID-19 as part of the multisystem inflammatory syndrome.

Hereditary and congenital diseases of the kidney are shown in Table 319-2. Autosomal dominant polycystic kidney disease (PCKD) occurs in all ethnic populations. The patient may first show signs of cysts in late teen years with hypertension, urinary or cyst infection, or pain and bleeding. Kidney stones may be seen. By the age of 30, individuals with the disorder will have ultrasound-detectable cysts. The clinician should be aware that a diagnosis of PCKD requires multiple cysts in both kidneys. Cysts are also found in the liver. The first manifestation of PCKD may be a cerebral hemorrhage, since brain aneurysms are present in a small subset of patients with this disease, most commonly in the circle of Willis. In PCKD, rapid progression of kidney failure has been observed and previously explained by the crowding out of normal nephrons by the cysts. Cyst enlargement is due to fluid secretion as well as increased growth of the cyst wall. It is helpful to measure the size of cysts and to antagonize growth with tolvaptan, an inhibitor of vasopressin type 2 receptors in the collecting duct. Vasopressin, however, is a growth factor for cysts. Risk factors for more rapid progression include African-American heritage, obesity, liver abnormalities, and hypertension.

Hereditary nephritis with many variations includes Alport syndrome, involving a gene mutation (*COL4A5*) affecting the α3 region of the noncollagenous domain of the alpha 3 chain type IV collagen in GBM. There is an X-linked pattern of genetic transmission, where

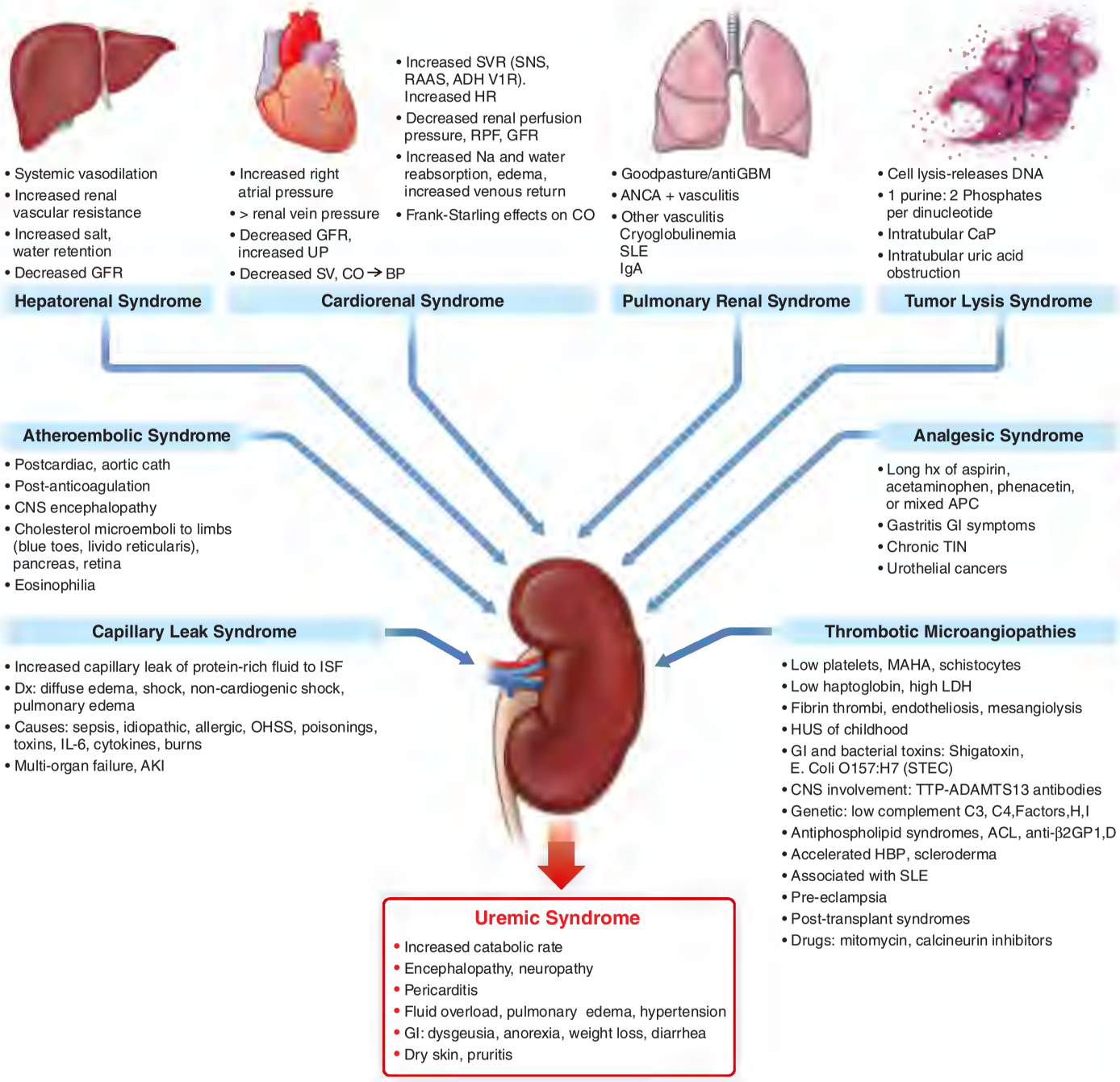

FIGURE 319-4 Categories of systemic or non-renal-based syndromes that involve the kidney and in advanced cases can cause the uremic syndrome requiring renal replacement therapy. ACL, anticardiolipin antibodies; ADH V1R, antidiuretic hormone V1 receptor; AKI, acute kidney injury; ANCA, antineutrophil cytoplasmic antibody; anti-2GP1, anti-β-2-glycoprotein-1; APC, aspirin, phenacetin, caffeine; BP, blood pressure; CaP, calcium phosphate crystals; CNS, central nervous system; CO, cardiac output; GBM, glomerular basement membrane; GFR, glomerular filtration rate; GI, gastrointestinal; HBP, high blood pressure; HR, heart rate; HUS, hemolytic-uremic syndrome; hx, history; IgA, immunoglobulin A; IL, interleukin; ISF, interstitial fluid; LDH, lactate dehydrogenase; MAHA, microangiopathic hemolytic anemia; OHSS, ovarian hyperstimulation syndrome; RAAS, renin-angiotensin-aldosterone system; RPF, renal plasma flow; SLE, systemic lupus erythematosus; SV, stroke volume; SNS, sympathetic nervous system; STEC, Shiga toxin–producing *Escherichia coli*; SVR systemic vascular resistance; TIN, tubulointerstitial nephritis; TTP, thrombotic thrombocytopenic purpura; UP, urine protein.

males may be most severely affected by renal failure in middle age. The syndrome involves hematuria, neurosensory hearing loss, and ocular deformities of the lens. A predominant symptom in hereditary nephritis is microscopic hematuria, and the pathological correlate to this is thin basement membranes. It must be distinguished from the less severe and more commonly related condition known as thin basement membrane disease as a cause of hematuria.

Certain congenital abnormalities of the kidney, such as horseshoe and ectopic kidneys, also shown in Table 319-2, consist of low nephron numbers that may result in secondary FSGS. The condition known as ureteral reflux is an abnormality involving the functional insertion of the ureter into the muscular bladder, which normally closes off the ureter upon bladder contraction. In reflux disease, the ureter cannot prevent retrograde flux of urine during micturition. In children, this may cause hypertension and, in some cases, secondary FSGS. Surgical correction of the abnormality may be curative, but the child may outgrow it in adulthood.

The stages of CKD are listed in Table 319-3 and are central in terms of planning for renal replacement therapy (dialysis and transplantation) and for assessing and slowing the rate of progression, defined as the decline in GFR over time. In CKD, the eGFR is determined by the current stable serum creatinine, which is entered into one of several equations derived from clinical trial data that compare the subject's value to actual measurements of GFR. For example, the Modification of Diet in Renal Disease (MDRD) study used radioisotope (I^{125}-iothalamate) clearance to measure true GFR. The equation

TABLE 319-3 Stages of Chronic Kidney Disease (CKD)

STAGES OF CKD, ABNORMALITY >3 MONTHS	RANGE OF eGFR	CLINICAL FEATURES	IMPORTANCE
1	>60 mL/min/1.73 m^2	Abnormal urinalysis, abnormal renal imaging	Risk of progression to later stages increases with increased proteinuria and dependent on cause of disease
2	>60 mL/min/1.73 m^2	Abnormal urinalysis, abnormal renal imaging	Mild risk of progression to later stages increases with increased proteinuria and dependent on cause of disease
3a	45–60 mL/min/1.73 m^2	Cardiovascular disease or other organ damage	Moderate risk of progression of disease. Pay attention to other vascular risk factors, high BP, lipids, smoking, weight
3b	30–45 mL/min/1.73 m^2	Proteinuria	High risk of progression
4	15–30 mL/min/1.73 m^2		High likelihood of progression to ESRD, need preparation and education regarding choices for RRT including transplant and dialysis
5	<15 mL/min/1.73 m^2		Highest risk of requiring RRT

Abbreviations: BP, blood pressure; eGFR, estimated glomerular filtration rate; ESRD, end-stage renal disease; RRT, renal replacement therapy.

contains additional factors such as age and sex to derive the current eGFR, corrected for 1.73 m^2 body surface area. This value of eGFR is not a creatinine clearance or a measurement of GFR.

There has been debate about the inclusion of corrective factors that would alter the result from that equation based on the patient's ethnicity and race. For example, it has been recommended in some centers to multiply the eGFR value by a factor of 1.2 in African-American patients in order to correct for the perceived underestimate of GFR using the MDRD equation. There is considerable objection to making this correction, which may have the effect of introducing bias based on race. Because the corrected eGFR will give a higher value to the GFR, there could be delays in discussion of renal replacement therapy and in initiation of treatment. Consequently, the correction has fallen out of favor. Recently, an alternative, the Chronic Kidney Disease Epidemiology Collaboration (CKD-EPI), has been used that excludes race as a parameter. Another method of estimating GFR uses cystatin-C, a known filtration marker for GFR. Levels of the patient's current cystatin-C are compared to historical values of cystatin-C from populations where the true GFR was the comparator. Both creatinine and cystatin-C methods are susceptible to error because they do not take into account renal and extrarenal clearance or, in the case of creatinine, muscle mass.

During the course of CKD, the clinician must evaluate the patient for symptoms and signs of worsening renal function. When the eGFR is <15–20 mL/min, the patient should already have had conversations about choices of eventual treatment and, if indicated, surgical preparation for peritoneal dialysis or hemodialysis. Attention should be given to the sensitive topic of transition to a lifesaving but mechanical procedure. It is also important to discuss transplantation and issues of timing. The ethical standard is for separate clinicians to evaluate the recipient and donor of a kidney transplant. Confidentiality and privacy are essential. Importantly, access to transplantation has not been offered equally to minority populations, and it is incumbent on clinicians to avoid bias by discussing the option with every patient.

Symptoms of CKD are often nonspecific and include fatigue, weakness, loss of appetite and taste, weight loss, mood changes, and metabolic encephalopathy that may involve cognitive changes such as decline in executive function and the ability to calculate and remember. Other symptoms are peripheral and autonomic neuropathies and sleep and movement disorders such as restless legs and asterixis or myoclonus. Patients with CKD lose their ability to concentrate urine and, therefore, have an obligate urine output of ~2 L. This results in nocturia since the bladder fills during the night. Ironically, the loss of nocturia may be sensed by the patient as an improvement of symptoms but actually indicates worsening oliguria. Pruritus commonly occurs. Clinical issues include changes in medications and doses. The full uremic syndrome is characterized by severe hypertension, the above-mentioned encephalopathic manifestations, gastrointestinal bleeding, pericarditis, severe electrolyte disturbances, particularly hyperkalemia, and secondary hyperparathyroidism. Anemia is frequently present, and although it may be due to iron deficiency or decreased erythropoietin, other causes of anemia should be investigated. Patients respond well to erythropoietic stimulating agents, with the goal of therapy >10 g/dL but <12 g/dL. Notably, not all patients are anemic. For example, some patients with UTO, PCKD, renal vascular disease, and renal cell carcinoma may in fact have erythrocytosis.

In NS, heavy proteinuria may persist throughout the course of CKD and carries a worse prognosis. In all kidney diseases, including the nephritic processes, renal disease may progress to late stages even when the acute inflammation has subsided; however, the underlying mechanisms of progressive renal failure involve inflammatory pathways (reflected in elevated levels of C-reactive protein and erythrocyte sedimentation rate in CKD), emphasizing the importance of managing risk factors for cardiovascular disease, such as hypertension, smoking, hyperlipidemias, diabetes mellitus, and obesity, early in the course of CKD.

Some chronic renal syndromes may present with predominant tubular dysfunction, including genetic diseases known as channelopathies. Examples are the depletion of electrolytes such as phosphorus and potassium and proximal RTA due to Fanconi's syndrome, mentioned above; hypokalemic alkalosis and volume depletion in Bartter's syndrome (mutations resulting in abnormal loop of Henle function); and electrolyte losses in Gitelman's syndrome, a defect in the thiazide-sensitive sodium-chloride transporter. Gitelman's syndrome also causes hypochloremic hypokalemic metabolic alkalosis. Bartter's and Gitelman's syndromes can be distinguished by examining the urine for the usual solutes regulated by these transporters. Thus, Bartter's syndrome is associated with hypercalciuria and the inability to put out a concentrated urine, whereas Gitelman's syndrome is associated with hypocalciuria and preserved ability to concentrate the urine. Fanconi's syndrome results in hypokalemic acidosis and can be distinguished from distal RTA, which is not associated with the loss of glucose, amino acids, and phosphate in the urine.

Disorders involving the collecting duct and its transporters of sodium, potassium, and acid base can result in syndromes that also suggest particular diagnoses. For example, polyuria due to inappropriate free water losses and insensitive to ADH is characteristic of nephrogenic diabetes insipidus, and it is common to see simultaneous defects in potassium secretion and hydrogen ion secretion with hypertension suggesting blockade of one of the sodium regulators of the epithelial sodium channel. These disorders are usually associated with hyporenin and/or hypoaldosterone states, which include UTO, type 4 RTAs in DM, amyloidosis, or Addison's disease. In contrast to this, hypokalemic metabolic alkalosis with volume expansion may suggest an adrenal adenoma, unilateral renal artery stenosis, adrenocorticotropic hormone–secreting tumors, licorice abuse, or potassium-sparing diuretics. Although genomic testing may reveal gene mutations characteristic of a disorder, such testing should not be automatic since many mutations require the presence of other high-risk conditions (a "second hit") or are only indirectly associated with the development of disease.

RENAL MASSES

Patients with renal cell carcinoma may have been diagnosed via an incidental finding in an abdominal imaging study or sometimes by a