Jensen GL et al: GLIM criteria for the diagnosis of malnutrition: A consensus report from the global clinical nutrition community. JPEN J Parenter Enteral Nutr 43:32, 2019.
Singer P et al: ESPEN practical and partially revised guideline: Clinical nutrition in the intensive care unit. Clin Nutr 42:1671, 2023.
Wischmeyer PE et al: Personalized nutrition therapy in critical care: 10 expert recommendations. Crit Care 27:261, 2023.

Section 3 Liver and Biliary Tract Disease



347 Approach to the Patient with Liver Disease

Marc G. Ghany, Jay H. Hoofnagle

A diagnosis of liver disease usually can be made accurately by careful elicitation of the patient's history, physical examination, and application of a few laboratory tests. In some circumstances, radiologic examinations are helpful or, indeed, diagnostic. Liver biopsy is considered the criterion standard in evaluation of liver disease but is now needed less for diagnosis than for grading (activity) and staging (fibrosis) of disease. Noninvasive means of assessing fibrosis stage have become increasingly helpful and may allow for avoidance of biopsy in an increasing proportion of patients. This chapter provides an introduction to diagnosis and management of liver disease, briefly reviewing the structure and function of the liver; the major clinical manifestations of liver disease; and the use of clinical history, physical examination, laboratory tests, imaging studies, and liver biopsy.

LIVER STRUCTURE AND FUNCTION

The liver is the largest organ of the body, weighing 1–1.5 kg and representing 1.5–2.5% of the lean body mass. The size and shape of the liver vary and generally match the general body shape—long and lean or squat and square. This organ is located in the right upper quadrant of the abdomen under the right lower rib cage against the diaphragm and projects for a variable extent into the left upper quadrant. It is held in place by ligamentous attachments to the diaphragm, peritoneum, great vessels, and upper gastrointestinal organs. The liver receives a dual blood supply; ~20% of the blood flow is oxygen-rich blood from the hepatic artery, and 80% is nutrient-rich blood from the portal vein arising from the stomach, intestines, pancreas, and spleen.

The majority of cells in the liver are hepatocytes, which constitute two-thirds of the organ's mass. The remaining cell types are Kupffer cells (members of the reticuloendothelial system), stellate (Ito or fat-storing) cells, endothelial and blood vessel cells, bile ductular cells, and cells of supporting structures. Viewed by light microscopy, the liver appears to be organized in lobules, with portal areas at the periphery and central veins in the center of each lobule. However, from a functional point of view, the liver is organized into acini, with both hepatic arterial and portal venous blood entering the acinus from the portal areas (zone 1) and then flowing through the sinusoids to the terminal hepatic veins (zone 3); the intervening hepatocytes constitute zone 2. The advantage of viewing the acinus as the physiologic unit of the liver is that this perspective helps to explain the morphologic patterns and zonality of many vascular and biliary diseases not explained by the lobular arrangement.

Portal areas of the liver consist of small veins, arteries, bile ducts, and lymphatics organized in a loose stroma of supporting matrix and small amounts of collagen. Blood flowing into the portal areas is distributed through the sinusoids, passing from zone 1 to zone 3 of the acinus and draining into the terminal hepatic veins ("central veins"). Secreted bile flows in the opposite direction—that is, in a countercurrent pattern from zone 3 to zone 1. The sinusoids are lined by unique endothelial cells that have prominent fenestrae of variable sizes, allowing the free flow of plasma but not of cellular elements. The plasma is thus in direct contact with hepatocytes in the subendothelial space of Disse.

Hepatocytes have distinct polarity. The basolateral side of the hepatocyte lines the space of Disse and is richly lined with microvilli; it exhibits endocytotic and pinocytotic activity, with passive and active uptake of nutrients, proteins, and other molecules. The apical pole of the hepatocyte forms the canalicular membranes through which bile components are secreted. The canaliculi of hepatocytes form a fine network, which fuses into the bile ductular elements near the portal areas. Kupffer cells usually lie within the sinusoidal vascular space and represent the largest group of fixed macrophages in the body. The stellate cells are located in the space of Disse but are not usually prominent unless activated, whereupon they produce collagen and matrix. Red blood cells stay in the sinusoidal space as blood flows through the lobules, but white blood cells can migrate through or around endothelial cells into the space of Disse and from there to portal areas, where they can return to the circulation through lymphatics.

Hepatocytes perform numerous and vital roles in maintaining homeostasis and health. These functions include the synthesis of most essential serum proteins (albumin, carrier proteins, coagulation factors, many hormonal and growth factors), the production of bile and its carriers (bile acids, cholesterol, lecithin, phospholipids), the regulation of nutrients (glucose, glycogen, lipids, cholesterol, amino acids), and the metabolism and conjugation of lipophilic compounds (bilirubin, anions, cations, drugs) for excretion in the bile or urine. Measurement of these activities to assess liver function is complicated by the multiplicity and variability of these functions. Commonly used liver "function" tests are measurements of serum bilirubin, serum albumin, and prothrombin time. The serum bilirubin level is a measure of hepatic conjugation and excretion; the serum albumin level and prothrombin time are measures of protein synthesis. Abnormalities of bilirubin, albumin, and prothrombin time are typical of hepatic dysfunction. Frank liver failure is incompatible with life, and the functions of the liver are too complex and diverse to be subserved by a mechanical pump; a dialysis membrane; or a concoction of infused hormones, proteins, and growth factors.

LIVER DISEASES

While there are many causes of liver disease (Table 347-1), these disorders generally present clinically in a few distinct patterns and are usually classified as hepatocellular, cholestatic (obstructive), or mixed. In hepatocellular diseases (such as viral hepatitis and alcoholic liver disease), features of liver injury, inflammation, and necrosis predominate. In cholestatic diseases, such as gallstone or malignant obstruction, primary biliary cholangitis (previously referred to as primary biliary cirrhosis), and some drug-induced liver diseases, features of inhibition of bile flow predominate. In a mixed pattern, features of both hepatocellular and cholestatic injury are present (such as in cholestatic forms of viral hepatitis and many drug-induced liver diseases). The pattern of onset and prominence of symptoms can rapidly suggest a diagnosis, particularly if major risk factors are considered, such as the age and sex of the patient and a history of exposure or risk behaviors.

Typical presenting symptoms of liver disease include jaundice, fatigue, itching, right-upper-quadrant pain, nausea, poor appetite, abdominal distention, and intestinal bleeding. At present, however, many patients are diagnosed with liver disease who have no symptoms and who have been found to have abnormalities in biochemical liver tests as a part of a routine physical examination or screening for blood donation or for insurance or employment. The wide availability of batteries of liver tests makes it relatively simple to demonstrate the presence of liver injury as well as to rule it out in someone in whom liver disease is suspected.

Evaluation of patients with liver disease should be directed at determining (1) the etiologic diagnosis, (2) disease severity (grading), and (3) disease stage (staging). Diagnosis should focus on the pattern of

TABLE 347-1 Liver Diseases

Inherited hyperbilirubinemia	**Liver involvement in systemic diseases**
Gilbert syndrome	Sarcoidosis
Crigler-Najjar syndrome, types I and II	Amyloidosis
Dubin-Johnson syndrome	Glycogen storage diseases
Rotor syndrome	Celiac disease
Viral hepatitis	Tuberculosis
Hepatitis A	*Mycobacterium avium-intracellulare* infection
Hepatitis B	**Cholestatic syndromes**
Hepatitis C	Benign postoperative cholestasis
Hepatitis D	Jaundice of sepsis
Hepatitis E	Total parenteral nutrition–induced jaundice
Others (Epstein-Barr virus [mononucleosis] herpesvirus, cytomegalovirus, adenovirus hepatitis)	Cholestasis of pregnancy
Cryptogenic hepatitis	Cholangitis and cholecystitis
Immune and autoimmune liver diseases	Extrahepatic biliary obstruction (stone, stricture, cancer)
Primary biliary cholangitis	Biliary atresia
Autoimmune hepatitis	Caroli disease
Sclerosing cholangitis	Cryptosporidiosis
Overlap syndromes	**Drug-induced liver disease**
Graft-versus-host disease	Hepatocellular patterns (isoniazid, acetaminophen)
Allograft rejection	Cholestatic patterns (methyltestosterone)
Genetic liver diseases	Mixed patterns (sulfonamides, phenytoin)
α_1 Antitrypsin deficiency	Micro- and macrovesicular steatosis (methotrexate, fialuridine)
Hemochromatosis	**Vascular injury**
Wilson disease	Sinusoidal obstruction syndrome
Benign recurrent intrahepatic cholestasis	Budd-Chiari syndrome
Progressive familial intrahepatic cholestasis, types I–III	Ischemic hepatitis
Others (galactosemia, tyrosinemia, cystic fibrosis, Niemann-Pick-disease, Gaucher's disease)	Passive congestion
Alcohol-related liver disease	Portal vein thrombosis
Acute fatty liver	Nodular regenerative hyperplasia
Acute alcoholic hepatitis	**Mass lesions**
Laënnec cirrhosis	Hepatocellular carcinoma
Nonalcoholic fatty liver[a]	Cholangiocarcinoma
Steatosis	Adenoma
Steatohepatitis	Focal nodular hyperplasia
Acute fatty liver of pregnancy	Metastatic tumors
	Abscess
	Cysts
	Hemangioma

[a]Also known as metabolic dysfunction–associated steatotic liver disease (MASLD).

disease presentation (hepatocellular, cholestatic, or mixed injury) as well as on the specific etiologic diagnosis. Grading refers to assessment of the severity or activity of disease—active or inactive as well as mild, moderate, or severe. Staging refers to estimation of the point in the course of the natural history of the disease, whether early or late; or precirrhotic, cirrhotic, or end-stage. This chapter introduces general, salient concepts in the evaluation of patients with liver disease that help lead to the diagnoses discussed in subsequent chapters.

CLINICAL HISTORY

The clinical history should focus on the symptoms of liver disease—their nature, patterns of onset, and progression—and on potential risk factors for liver disease. The manifestations of liver disease include constitutional symptoms such as fatigue, weakness, nausea, poor appetite, and malaise and the more liver-specific symptoms of jaundice, dark urine, light stools, itching, abdominal pain, and bloating. Symptoms can also suggest the presence of cirrhosis, end-stage liver disease, or complications of cirrhosis such as portal hypertension. Generally, the constellation of symptoms and their patterns of onset, rather than a specific symptom, point to an etiology.

Fatigue is the most common and most characteristic symptom of liver disease. It is variously described as lethargy, weakness, listlessness, malaise, increased need for sleep, lack of stamina, and poor energy. The fatigue of liver disease typically arises after activity or exercise and is rarely present or severe after adequate rest; that is, it is "afternoon" rather than "morning" fatigue. Fatigue in liver disease is often intermittent and variable in severity from hour to hour and day to day. In some patients, it may not be clear whether fatigue is due to the liver disease or due to other problems such as stress, anxiety, sleep disturbance, or a concurrent illness.

Nausea occurs with more severe liver disease and may accompany fatigue or be provoked by smelling food odors or eating fatty foods. Vomiting can occur but is rarely persistent or prominent. Poor appetite with weight loss occurs frequently in acute liver disease but is rare in chronic disease except when cirrhosis is present and advanced. Diarrhea is uncommon in liver disease except with severe jaundice, in which a lack of bile acids reaching the intestine can lead to steatorrhea.

Right-upper-quadrant discomfort or ache ("liver pain") occurs in many liver diseases and is usually marked by tenderness over the liver area. The pain arises from stretching or irritation of Glisson's capsule, which surrounds the liver and is rich in nerve endings. Severe pain is most typical of gallbladder disease, liver abscess, and severe sinusoidal obstruction syndrome (previously known as venoocclusive disease) but is also an occasional accompaniment of acute hepatitis.

Itching occurs with acute liver disease, appearing early in obstructive jaundice (from biliary obstruction) or drug-induced cholestasis and somewhat later in hepatocellular disease (acute hepatitis). Itching also occurs in chronic liver diseases—typically the cholestatic forms such as primary biliary cholangitis and sclerosing cholangitis, in which it is often the presenting symptom, preceding the onset of jaundice. However, itching can occur in any liver disease, particularly once cirrhosis develops.

Jaundice is the hallmark symptom of liver disease and perhaps the most reliable marker of severity. Patients usually report darkening of the urine before they notice scleral icterus. Jaundice is rarely detectable with a bilirubin level <43 μmol/L (2.5 mg/dL). With severe cholestasis, there will also be lightening of the color of the stools and steatorrhea. Jaundice without dark urine usually indicates indirect (unconjugated) hyperbilirubinemia and is typical of hemolytic anemia and the genetic disorders of bilirubin conjugation, the common and benign form being Gilbert syndrome and the rare and severe form being Crigler-Najjar syndrome. Gilbert syndrome affects up to 5% of the general population; the jaundice in this condition is more noticeable after fasting and with stress.

Major risk factors for liver disease that should be sought in the clinical history include details of alcohol use, medication use (including herbal compounds, birth control pills, and over-the-counter medications), personal habits, sexual activity, travel, exposure to jaundiced or other high-risk persons, injection drug use, recent surgery, remote or recent transfusion of blood or blood products, occupation, accidental exposure to blood or needlestick, and familial history of liver disease.

For assessing the risk of viral hepatitis, a careful history of sexual activity is of particular importance and should include the number of lifetime sexual partners and, for men, a history of having sex with men. Sexual exposure is a common mode of spread of hepatitis B and D but is uncommon for hepatitis C. A family history of hepatitis, liver disease, and liver cancer is also important. Maternal-infant transmission occurs with both hepatitis B and C. Vertical spread of hepatitis B can now be prevented by passive and active immunization of the infant at birth. Additionally, antiviral therapy administered in the second or third trimester of pregnancy is now recommended for mothers with levels of hepatitis B virus DNA >200,000 IU/mL. Vertical spread of hepatitis C is uncommon, but there are no reliable means of prevention. Transmission is more common among HIV-co-infected mothers and is also linked to prolonged and difficult labor and delivery, early rupture of membranes, internal fetal monitoring, and a high maternal

viral load. A history of injection drug use, even in the remote past, is of great importance in assessing the risk for hepatitis B, C, and D. Injection drug use is the single most common risk factor for hepatitis C. Transfusion with blood or blood products is no longer an important risk factor for acute viral hepatitis due to screening of blood products. However, blood transfusions received before the introduction of sensitive enzyme immunoassays for antibody to hepatitis C virus in 1992 is an important risk factor for chronic hepatitis C. Blood transfusion before 1986, when screening for antibody to hepatitis B core antigen was introduced, is also a risk factor for hepatitis B. Travel to a developing area of the world, exposure to persons with jaundice, and exposure to young children in day-care centers are risk factors for hepatitis A. Tattooing and body piercing (for hepatitis B, C, and D) and eating shellfish (for hepatitis A) are frequently mentioned but are actually types of exposure that rarely lead to infection.

Hepatitis E is one of the more common causes of jaundice in Asia and Africa but is uncommon in developed nations. In endemic areas, transmission is usually through exposure to fecally contaminated water. Non-travel-related (autochthonous) cases of hepatitis E have been described in developed countries, including the United States. These cases appear to be due to strains of hepatitis E virus that are endemic in swine and some wild animals (genotypes 3 and 4). While occasional cases are associated with eating raw or undercooked pork or game (deer and wild boars), most cases of hepatitis E occur without known exposure, predominantly in elderly men without typical risk factors for viral hepatitis. Hepatitis E infection can become chronic in immunosuppressed individuals (such as transplant recipients, patients receiving chemotherapy, or patients with HIV infection), in whom it presents with abnormal serum enzymes in the absence of markers of hepatitis B or C.

A history of alcohol intake is important in assessing the cause of liver disease and in planning management and recommendations. In the United States, for example, at least 70% of adults drink alcohol to some degree, but significant alcohol intake is less common; in population-based surveys, only 5% of individuals have more than two drinks per day, the average drink representing 11–15 g of alcohol. Alcohol consumption associated with an increased rate of alcoholic liver disease is probably more than two drinks (22–30 g) per day in women and three drinks (33–45 g) in men. Most patients with alcoholic cirrhosis have a much higher daily intake and have drunk excessively for ≥10 years before onset of liver disease. In assessing alcohol intake, the history should also focus on whether alcohol abuse or dependence is present. Alcoholism is usually defined by the behavioral patterns and consequences of alcohol intake, not by the amount. Abuse is defined by a repetitive pattern of drinking alcohol that has adverse effects on social, family, occupational, or health status. Dependence is defined by alcohol-seeking behavior, despite its adverse effects. Many alcoholics demonstrate both dependence and abuse, and dependence is considered the more serious and advanced form of alcoholism. A clinically helpful approach to diagnosis of alcohol dependence and abuse is the use of the CAGE questionnaire **(Table 347-2)**, which is recommended for all medical history-taking.

Family history can be helpful in assessing liver disease. Familial causes of liver disease include Wilson disease; hemochromatosis and α_1 antitrypsin deficiency; and the less common inherited pediatric liver diseases—that is, familial intrahepatic cholestasis, benign recurrent intrahepatic cholestasis, and Alagille syndrome. Onset of severe liver disease in childhood or adolescence in conjunction with a family history of liver disease or neuropsychiatric disturbance should lead to investigation for Wilson disease. A family history of cirrhosis, diabetes, or endocrine failure and the appearance of liver disease in adulthood suggest hemochromatosis and should prompt investigation of iron status. Abnormal iron studies in adult patients warrant genotyping of the *HFE* gene for the C282Y and H63D mutations typical of genetic hemochromatosis. In children and adolescents with iron overload, other non-*HFE* causes of hemochromatosis should be sought. A family history of emphysema should lead to investigation of α_1 antitrypsin levels and, if low, for protease inhibitor (Pi) genotype.

TABLE 347-2 CAGE Questions[a]

ACRONYM	QUESTION
C	Have you ever felt you ought to *c*ut down on your drinking?
A	Have people *a*nnoyed you by criticizing your drinking?
G	Have you ever felt *g*uilty or bad about your drinking?
E	Have you ever had a drink first thing in the morning to steady your nerves or get rid of a hangover (*e*ye-opener)?

[a]One "yes" response should raise suspicion of an alcohol use problem, and more than one is a strong indication of abuse or dependence.

PHYSICAL EXAMINATION

The physical examination rarely uncovers evidence of liver dysfunction in a patient without symptoms or abnormal laboratory findings, nor are most signs of liver disease specific to one diagnosis. Thus, the physical examination complements rather than replaces the need for other diagnostic approaches. In many patients, the physical examination is normal unless the disease is acute or severe and advanced. Nevertheless, the physical examination is important in that it can yield the first evidence of hepatic failure, portal hypertension, and liver decompensation. In addition, the physical examination can reveal signs—related either to risk factors or to associated diseases or findings—that point to a specific diagnosis.

Typical physical findings in liver disease are icterus, hepatomegaly, hepatic tenderness, splenomegaly, spider angiomata, palmar erythema, and skin excoriations. Signs of advanced disease include muscle wasting, ascites, edema, dilated abdominal veins, hepatic fetor, asterixis, mental confusion, stupor, and coma. In male patients with cirrhosis, particularly that related to alcohol use, signs of hyperestrogenemia such as gynecomastia, testicular atrophy, and loss of male-pattern hair distribution may be found.

Icterus is best appreciated when the sclera is inspected under natural light. In fair-skinned individuals, a yellow tinge to the skin may be obvious. In dark-skinned individuals, examination of the mucous membranes below the tongue can demonstrate jaundice. Jaundice is rarely detectable if the serum bilirubin level is <43 μmol/L (2.5 mg/dL) but may remain detectable below this level during recovery from jaundice (because of protein and tissue binding of conjugated bilirubin).

Spider angiomata and palmar erythema occur in both acute and chronic liver disease; these manifestations may be especially prominent in persons with cirrhosis but can develop in normal individuals and are frequently found during pregnancy. Spider angiomata are superficial, tortuous arterioles, and—unlike simple telangiectasias—typically fill from the center outward. Spider angiomata occur only on the arms, face, and upper torso; they can be pulsatile and may be difficult to detect in dark-skinned individuals.

Hepatomegaly is not a very reliable sign of liver disease because of variability in the liver's size and shape and the physical impediments to assessment of liver size by percussion and palpation. Marked hepatomegaly is typical of cirrhosis, sinusoidal obstruction syndrome, infiltrative disorders such as amyloidosis, metastatic or primary cancers of the liver, and alcoholic hepatitis. Careful assessment of the liver edge may also reveal unusual firmness, irregularity of the surface, or frank nodules. Perhaps the most reliable physical finding in the liver examination is hepatic tenderness. Discomfort when the liver is touched or pressed upon should be carefully sought with percussive comparison of the right and left upper quadrants.

Splenomegaly, which occurs in many medical conditions, can be a subtle but significant physical finding in chronic liver disease and suggests underlying cirrhosis. The availability of ultrasound (US) methods for assessment of the spleen allows confirmation of the physical finding.

Signs of advanced liver disease include muscle wasting and weight loss as well as hepatomegaly, bruising, ascites, and edema. Ascites is best appreciated by attempts to detect shifting dullness by careful percussion. US examination will confirm the finding of ascites in equivocal cases. Peripheral edema can occur with or without ascites. In patients with advanced liver disease, other factors frequently contribute

to edema formation, including hypoalbuminemia, venous insufficiency, heart failure, and medications.

Hepatic failure is defined as the occurrence of signs or symptoms of hepatic encephalopathy in a person with severe acute or chronic liver disease. The first signs of hepatic encephalopathy can be subtle and nonspecific—change in sleep patterns, change in personality, irritability, and mental dullness. Thereafter, confusion, disorientation, stupor, and eventually coma supervene. In acute liver failure, excitability and mania may be present. Physical findings include asterixis and flapping tremors of the body and tongue. Fetor hepaticus refers to the slightly sweet, ammoniacal odor that can develop in patients with liver failure, particularly if there is portal-venous shunting of blood around the liver. Other causes of coma and disorientation should be excluded, mainly electrolyte imbalances, sedative use, and renal or respiratory failure. The appearance of hepatic encephalopathy during acute hepatitis is the major criterion for diagnosis of acute liver failure and indicates a poor prognosis. In chronic liver disease, encephalopathy is usually triggered by a medical complication such as gastrointestinal bleeding, overdiuresis, uremia, dehydration, electrolyte imbalance, infection, constipation, or use of narcotic analgesics.

A helpful measure of hepatic encephalopathy is a careful mental status examination and use of the trail-making test, which consists of a series of 25 numbered circles that the patient is asked to connect as rapidly as possible using a pencil. The normal range for the connect-the-dot test is 15–30 s; it is considerably longer in patients with early hepatic encephalopathy. Other tests include drawing of abstract objects or comparison of a signature to previous examples. More sophisticated testing—for example, with electroencephalography and visual evoked potentials—can detect mild forms of encephalopathy but are rarely clinically useful.

Other signs of advanced liver disease include umbilical hernia from ascites, hydrothorax, prominent veins over the abdomen, and caput medusa, a condition that consists of collateral veins radiating from the umbilicus and results from recanulation of the umbilical vein. Widened pulse pressure and signs of a hyperdynamic circulation can occur in patients with cirrhosis as a result of fluid and sodium retention, increased cardiac output, and reduced peripheral resistance. Patients with long-standing cirrhosis and portal hypertension are prone to develop the hepatopulmonary syndrome, which is defined by the triad of liver disease, hypoxemia, and pulmonary arteriovenous shunting. The hepatopulmonary syndrome is characterized by platypnea and orthodeoxia: shortness of breath and oxygen desaturation that occur paradoxically upon the assumption of an upright position. Measurement of oxygen saturation by pulse oximetry is a reliable screening test for hepatopulmonary syndrome.

Several skin disorders and changes are common in liver disease. Hyperpigmentation is typical of advanced chronic cholestatic diseases such as primary biliary cholangitis and sclerosing cholangitis. In these same conditions, xanthelasma and tendon xanthomata occur as a result of retention and high serum levels of lipids and cholesterol. Slate-gray pigmentation of the skin is also seen with hemochromatosis if iron levels are high for a prolonged period. Mucocutaneous vasculitis with palpable purpura, especially on the lower extremities, is typical of cryoglobulinemia of chronic hepatitis C but can also occur in chronic hepatitis B.

Some physical signs point to specific liver diseases. Kayser-Fleischer rings occur in Wilson disease and consist of a golden-brown copper pigment deposited in Descemet's membrane at the periphery of the cornea; they are best seen by slit-lamp examination. Dupuytren contracture and parotid enlargement are suggestive of alcohol use disorder and alcohol-related liver disease. In metastatic liver disease or primary hepatocellular carcinoma (HCC), signs of cachexia and wasting as well as firm hepatomegaly and a hepatic bruit may be prominent.

DIAGNOSIS OF LIVER DISEASE

The key diagnostic tests of major causes of acute and chronic liver disease are outlined in **Table 347-3**, and an algorithm for evaluation of the patient with suspected liver disease is shown in **Fig. 347-1**. Specifics of diagnosis are discussed in later chapters. The most common causes of acute liver disease are viral hepatitis (particularly hepatitis A, B, and C), drug-induced liver injury, cholangitis, and alcohol-related liver disease. Liver biopsy usually is not needed for the diagnosis and management of acute liver disease, exceptions being situations where the diagnosis remains unclear despite thorough clinical and laboratory investigation. Liver biopsy can be helpful in diagnosing drug-induced liver disease and acute alcoholic hepatitis.

TABLE 347-3 Important Diagnostic Tests in Common Liver Diseases

DISEASE	DIAGNOSTIC TEST
Hepatitis A	Anti-HAV IgM
Hepatitis B	
Acute	HBsAg and anti-HBc IgM
Chronic	HBsAg and HBeAg and/or HBV DNA
Hepatitis C	Anti-HCV and HCV RNA
Hepatitis D (delta)	HBsAg and anti-HDV
Hepatitis E	Anti-HEV IgM and HEV RNA
Autoimmune hepatitis	ANA or SMA, elevated IgG levels, and compatible histology
Primary biliary cholangitis	Mitochondrial antibody, elevated IgM levels, and compatible histology
Primary sclerosing cholangitis	P-ANCA, cholangiography
Drug-induced liver disease	History of drug ingestion
Alcohol-related liver disease	History of excessive alcohol intake and compatible histology
Nonalcoholic steatohepatitis[a]	Ultrasound or CT evidence of fatty liver and compatible histology
α_1 Antitrypsin disease	Reduced α_1 antitrypsin levels, phenotype PiZZ or PiSZ
Wilson disease	Decreased serum ceruloplasmin and increased urinary copper; increased hepatic copper level
Hemochromatosis	Elevated iron saturation and serum ferritin; genetic testing for *HFE* gene mutations
Hepatocellular cancer	Elevated α-fetoprotein level (to >500 ng/mL); ultrasound or CT image of mass

[a]Also known as metabolic dysfunction–associated steatohepatitis (MASH).

Abbreviations: ANA, antinuclear antibody; anti-HBc, antibody to hepatitis B core (antigen); CT, computed tomography; HAV, HBV, HCV, HDV, HEV, hepatitis A, B, C, D, E virus; HBeAg, hepatitis B e antigen; HBsAg, hepatitis B surface antigen; P-ANCA, peripheral antineutrophil cytoplasmic antibody; SMA, smooth-muscle antibody.

The most common causes of chronic liver disease, in general order of frequency, are chronic hepatitis C, alcoholic liver disease, nonalcoholic steatohepatitis (also called metabolic dysfunction–associated steatohepatitis), chronic hepatitis B, autoimmune hepatitis, sclerosing cholangitis, primary biliary cholangitis, hemochromatosis, and Wilson disease. Hepatitis E virus is a rare cause of chronic hepatitis, with cases occurring mostly in persons who are immunosuppressed or immunodeficient. Strict diagnostic criteria have not been developed for most liver diseases, but liver biopsy plays an important role in the diagnosis of autoimmune hepatitis, primary biliary cholangitis, nonalcoholic and alcoholic steatohepatitis, and Wilson disease (with a quantitative hepatic copper level in the last instance).

Laboratory Testing Diagnosis of liver disease is greatly aided by the availability of reliable and sensitive tests of liver injury and function. A typical battery of blood tests used for initial assessment of liver disease includes measurement of levels of serum alanine (ALT) and aspartate (AST) aminotransferases, alkaline phosphatase (AlkP), direct and total serum bilirubin and albumin, and prothrombin time. The pattern of abnormalities generally points to hepatocellular versus cholestatic liver disease and helps determine whether the disease is acute or chronic and whether cirrhosis and hepatic failure are present. Based on these results, further testing over time may be necessary. Other laboratory tests may be helpful, such as γ-glutamyl transpeptidase (γGT) to define whether AlkP elevations are due to liver disease; hepatitis serology to define the type of viral hepatitis; and autoimmune markers to diagnose primary biliary cholangitis (antimitochondrial

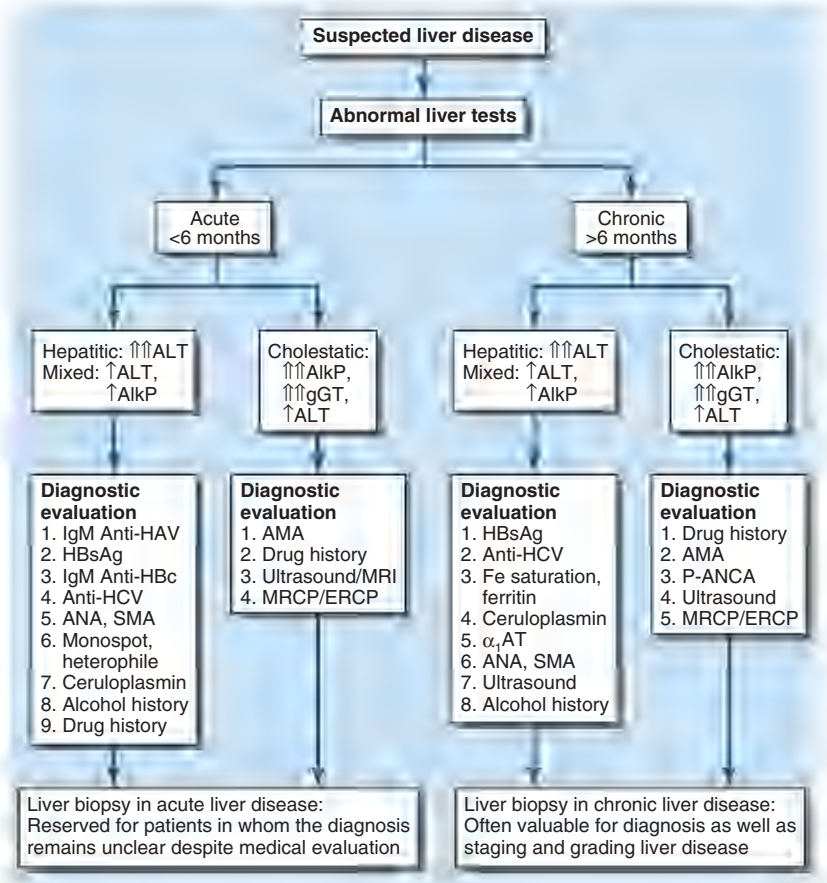

FIGURE 347-1 Algorithm for evaluation of abnormal liver tests. For patients with suspected liver disease, an appropriate approach to evaluation is initial routine liver testing—for example, measurement of serum bilirubin, albumin, alanine aminotransferase (ALT), aspartate aminotransferase (AST), and alkaline phosphatase (AlkP). These results (sometimes complemented by testing of γ-glutamyl transpeptidase [γGT]) will establish whether the pattern of abnormalities is hepatic, cholestatic, or mixed. In addition, the duration of symptoms or abnormalities will indicate whether the disease is acute or chronic. If the disease is acute and if history, laboratory tests, and imaging studies do not reveal a diagnosis, liver biopsy is appropriate to help establish the diagnosis. If the disease is chronic, liver biopsy can be helpful not only for diagnosis but also for grading of the activity and staging the progression of disease. This approach is generally applicable to patients without immune deficiency. In patients with HIV infection or recipients of bone marrow or solid organ transplants, the diagnostic evaluation should also include evaluation for opportunistic infections (e.g., with adenovirus, cytomegalovirus, *Coccidioides*, hepatitis E virus) as well as for vascular and immunologic conditions (venoocclusive disease, graft-versus-host disease). α_1AT, α_1 antitrypsin; AMA, antimitochondrial antibody; ANA, antinuclear antibody; anti-HBc, antibody to hepatitis B core (antigen); ERCP, endoscopic retrograde cholangiopancreatography; HAV, hepatitis A virus; HBsAg, hepatitis B surface antigen; HCV, hepatitis C virus; MRCP, magnetic resonance cholangiopancreatography; P-ANCA, peripheral antineutrophil cytoplasmic antibody; SMA, smooth-muscle antibody.

antibody), sclerosing cholangitis (peripheral antineutrophil cytoplasmic antibody), and autoimmune hepatitis (antinuclear, smooth-muscle, and liver-kidney microsomal antibody). A simple delineation of laboratory abnormalities and common liver diseases is given in Table 347-3.

The use and interpretation of liver function tests are summarized in Chap. 348.

Diagnostic Imaging Great advances have been made in hepatobiliary imaging, although no method is adequately accurate in demonstrating underlying cirrhosis in its early stages. Of the many modalities available for imaging the liver, US, computed tomography (CT), and magnetic resonance imaging (MRI) are the most commonly employed and are complementary to one another. In general, US and CT are highly sensitive for detecting biliary duct dilation and are the first-line options for investigating cases of suspected obstructive jaundice. All three modalities can detect a fatty liver, which appears bright on imaging studies. Modifications of CT and MRI can be used to quantify liver fat, and this information may ultimately be valuable in monitoring response to therapy in patients with fatty liver disease. Advantages, disadvantages, and clinical utility of each modality are presented in **Table 347-4**. Magnetic resonance cholangiopancreatography (MRCP) and endoscopic retrograde cholangiopancreatography (ERCP) are the procedures of choice for visualization of the biliary tree. MRCP offers several advantages over ERCP: there is no need for contrast media or ionizing radiation, images can be acquired faster, the procedure is less operator dependent, and it carries no risk of pancreatitis. MRCP is superior to US and CT for detecting choledocholithiasis but is less specific. MRCP is useful in the diagnosis of bile duct obstruction and congenital biliary abnormalities, but ERCP is considered more valuable in evaluating ampullary lesions and primary sclerosing cholangitis. ERCP permits biopsy, direct visualization of the ampulla and common bile duct, and intraductal ultrasonography and brushings for cytologic evaluation of malignancy. It also provides several therapeutic options in patients with obstructive jaundice, such as sphincterotomy, stone extraction, and placement of nasobiliary catheters and biliary stents.

Doppler US and MRI are used to assess hepatic vasculature and hemodynamics and to monitor surgically or radiologically placed vascular shunts, including

TABLE 347-4 Diagnostic Tests to Assess Liver Fat

IMAGING MODALITY	ADVANTAGES	DISADVANTAGES	CLINICAL UTILITY
Ultrasound	No radiation Widely available	Operator dependent Imprecise qualitative assessment of fat severity, particularly mild steatosis	Initial screening test for suspected liver fat
Transient elastography with controlled attenuation parameter	No radiation Point-of-care assessment of liver fat Provides semiquantitative assessment of fat severity	Requires special software No reliable cutoff for diagnosis of liver fat Imprecise qualitative assessment of fat severity	Alternate screening test for suspected liver fat if available
Computed tomography	Rapid assessment Non–operator dependent Quantitative assessment of fat severity	Requires radiation Quantification of fat requires specific protocols Imprecise quantitative assessment of fat severity, particularly mild steatosis	Not recommended for clinical assessment of liver fat due to need for radiation exposure and low sensitivity for mild fat
Magnetic resonance imaging–proton density fat fraction	Direct assessment of liver fat Highly sensitive and specific	Relatively limited accessibility	Test of choice for quantitative assessment of liver fat if available

transjugular intrahepatic portosystemic shunts. Multidetector or spiral CT and MRI with contrast enhancement are the procedures of choice for the identification and evaluation of hepatic masses, the staging of liver tumors, and preoperative assessment. With regard to mass lesions, the sensitivity of hepatic imaging continues to increase; unfortunately, specificity remains a problem, and often two and sometimes three studies are needed before a diagnosis can be reached. An emerging imaging modality for the investigation of hepatic lesions is contrast-enhanced US. This procedure permits enhancement of liver lesions in a similar fashion as contrast-enhanced, cross-sectional CT or MRI. Major advantages are real-time assessment of liver perfusion throughout the vascular phases without risk of nephrotoxicity and radiation exposure. Other advantages are its widespread availability and lower cost. Limitations include body habitus of the patient and skill of the operator.

US is the recommended modality for HCC screening. Contrast-enhanced US, CT, and MRI are appropriate for further investigation of lesions detected on screening US. The American College of Radiologists has developed a Liver Imaging Reporting and Data System (LI-RADS) to standardize the reporting and data collection of CT, MRI, and contrast-enhanced US imaging for HCC. This system allows for more consistent reporting and reduces imaging interpretation variability and errors.

Recently, several US-based elastographic techniques have been developed and approved for the measurement of hepatic stiffness, providing an indirect assessment of fibrosis and cirrhosis. The most commonly used approaches in clinical practice include transient elastography, acoustic radiation force impulse imaging, shear-wave elasticity imaging, and supersonic shear imaging. These techniques can eliminate the need for liver biopsy if the only indication for the test is the assessment of disease stage. Magnetic resonance elastography is more sensitive than US elastography but is also more expensive and requires advanced scheduling and special equipment. Finally, interventional radiologic techniques allow for the biopsy of solitary lesions, the radiofrequency ablation and chemoembolization of cancerous lesions, the insertion of drains into hepatic abscesses, the measurement of portal pressure, and the creation of vascular shunts in patients with portal hypertension. Which modality to use depends on factors such as availability, cost, and experience of the radiologist with each technique.

Liver Biopsy Liver biopsy remains the gold standard in the evaluation of patients with liver disease, particularly chronic liver disease. Liver biopsy is necessary for diagnosis in selected instances but is more often useful for assessment of the severity (grade) and stage of liver damage, prediction of prognosis, and monitoring of the response to treatment. The size of the liver biopsy sample is an important determinant of reliability; a length of 1.5–2 cm with 10 portal tracts is necessary for accurate assessment of fibrosis. Because liver biopsy is an invasive procedure and not without complications, it should be used only when it will contribute materially to decisions about management and therapy. In the future, noninvasive means of assessing disease activity (batteries of blood tests) and fibrosis (elastography and fibrosis markers) may replace liver biopsy for the staging and grading of disease.

GRADING AND STAGING OF LIVER DISEASE

Grading refers to an assessment of the severity or activity of liver disease, whether acute or chronic; active or inactive; and mild, moderate, or severe. Liver biopsy is the most accurate means of assessing severity, particularly in chronic liver disease. Serum aminotransferase levels serve as convenient and noninvasive markers for disease activity but do not always reliably reflect disease severity. Thus, normal serum aminotransferase levels in patients with hepatitis B surface antigen in serum may indicate the inactive carrier state or may reflect mild chronic hepatitis B or hepatitis B with fluctuating disease activity. Serum testing for hepatitis B e antigen and hepatitis B virus DNA can help sort out these different patterns, but these markers can also fluctuate and change over time. Similarly, in chronic hepatitis C, serum aminotransferase levels can be normal despite moderate disease activity. Finally, in both alcoholic and nonalcoholic steatohepatitis, aminotransferase levels are quite unreliable in reflecting severity. In these conditions, liver biopsy is helpful in guiding management and identifying appropriate therapy, particularly if treatment is difficult, prolonged, and expensive. Of the several well-verified numerical scales for histologic grading of chronic liver disease, the most commonly used are the METAVIR and the histology activity index.

Liver biopsy is also the most accurate means of assessing stage of disease as early or advanced and as precirrhotic or cirrhotic. Staging of disease pertains largely to chronic liver diseases in which progression to cirrhosis and end-stage disease can occur but may require years or decades. Clinical features, biochemical tests, and hepatic imaging studies are helpful in assessing stage but generally become abnormal only in the middle to late stages of cirrhosis. Noninvasive tests that suggest advanced fibrosis include mild elevations of bilirubin, prolongation of prothrombin time, slight decreases in serum albumin, and mild thrombocytopenia (which is often the first indication of worsening fibrosis). Combinations of blood test results that include clinical features, routine laboratory tests, and special laboratory tests such as serum proteins or small molecules that are affected by or involved with fibrogenesis have been used to create models for predicting advanced liver disease, but these models are not reliable enough to use on a regular basis or for repeated measures and only separate advanced from early disease **(Table 347-5)**. Recently, elastography and noninvasive breath tests using ^{13}C-labeled compounds have been proposed as a means of detecting early stages of fibrosis and liver dysfunction, but their reliability and reproducibility remain to be proven. A major limitation of noninvasive markers is that they can be affected by disease activity. Even elastography is limited in this regard, in that it measures liver stiffness, not fibrosis per se, and can be affected by inflammation, edema, hepatocyte necrosis, and intrasinusoidal cellularity (inflammatory, malignant, or sickled cells). Thus, at present, mild to moderate stages of hepatic fibrosis are detectable only by liver biopsy. In the assessment of stage, the degree of fibrosis is usually used as the quantitative measure. The amount of fibrosis is generally staged on a scale of 0 to 4+ (METAVIR scale) or 0 to 6+ (Ishak scale). The importance of staging relates primarily to prognosis, recommendation of therapy, and optimal management to prevent complications of chronic liver disease. Patients with cirrhosis are candidates for screening and surveillance for esophageal varices and HCC. Patients without advanced fibrosis need not undergo screening.

Once cirrhosis develops, other scoring systems are employed to assess compensated versus decompensated disease and prognosis. The first staging system used for this purpose was the modified Child-Pugh

TABLE 347-5 Selected Noninvasive Methods of Assessing Hepatic Fibrosis and Cirrhosis

METHOD	PARAMETERS	ADVANCED FIBROSIS	CIRRHOSIS
APRI	AST, platelet count	>1	>1.5 (1–2)
ELF	Age, hyaluronic acid, MMP-3, TIMP-1	>7.7	>9.3
FIB-4	Age, AST, ALT, platelet count	>1.45	>3.25
Fibro test[a]	Haptoglobin, α_2-macroglobulin, apolipoprotein A1, γGT, total bilirubin	>0.45	>0.63
TE	Measures speed of a shear wave generated by vibration through liver tissue	>7.3 kPa	>15 kPa (9–26.5 kPa)
ARFI	Measures speed of shear wave generated by acoustic radiation force through liver tissue	>1.3 m/s	>1.87 m/s

[a]Patented models.

Note: The cut points presented in the table were mostly derived from patients with chronic hepatitis C. The cut points for the noninvasive models and tests presented in the table vary among different liver diseases and among patients with the same disease among different populations.

Abbreviations: ALT, alanine aminotransferase; APRI, AST-to-platelet ratio; ARFI, acoustic radiation force imaging; AST, aspartate aminotransferase; ELF, enhanced liver fibrosis panel; γGT, γ-glutamyl transpeptidase; MMP-3, metalloproteinase-3; TIMP-1, tissue inhibitor of metalloproteinase-1; TE, transient elastography.